



Congenital and Disseminated Pyogenic Granuloma-like Vascular Lesions

Stephanie Mallet, Charlotte Rebelle, Isabelle Ligi, Didier Scavarda, Corinne Bouvier, Philippe Petit, Sylvie Fraitag, Michel M. Wassef, Caroline Gaudy-Marqueste, Sylvie Hesse, et al.

► To cite this version:

Stephanie Mallet, Charlotte Rebelle, Isabelle Ligi, Didier Scavarda, Corinne Bouvier, et al.. Congenital and Disseminated Pyogenic Granuloma-like Vascular Lesions. *Acta Dermato-Venereologica*, 2015, 95, pp.860-861. 10.2340/00015555-2078 . hal-01231032

HAL Id: hal-01231032

<https://amu.hal.science/hal-01231032>

Submitted on 19 Nov 2015

HAL is a multi-disciplinary open access archive for the deposit and dissemination of scientific research documents, whether they are published or not. The documents may come from teaching and research institutions in France or abroad, or from public or private research centers.

L'archive ouverte pluridisciplinaire **HAL**, est destinée au dépôt et à la diffusion de documents scientifiques de niveau recherche, publiés ou non, émanant des établissements d'enseignement et de recherche français ou étrangers, des laboratoires publics ou privés.

SHORT COMMUNICATION

Congenital and Disseminated Pyogenic Granuloma-like Vascular Lesions

Stéphanie Mallet^{1#}, Charlotte Rebelle^{2#}, Isabelle Ligi³, Didier Scavarda⁴, Corinne Bouvier⁵, Philippe Petit⁶, Sylvie Fraitag⁷, Michel Wassef⁸, Caroline Gaudy-Marqueste¹, Sylvie Hesse¹, Marie-Aleth Richard¹, Jean-Jacques Grob¹ and Nicolas André²

Departments of ¹Dermatology, ²Pediatric Oncology, ³Neonatology, ⁴Neurosurgery, ⁵Pathology, ⁶Radiology, Aix Marseille University, APHM, 264 rue Saint Pierre, FR-13885 Marseille, Departments of Pathology, ⁷Hôpital Necker-Enfants Malades, and ⁸Hôpital Lariboisière-Saint Louis, APHP, Paris, France. E-mail: stephanie.mallet@ap-hm.fr

[#]These authors have contributed equally to this paper and should be considered as first authors.

Accepted Feb 24, 2015; Epub ahead of print Feb 27, 2015

We report an exceptional case of multiple cutaneous and visceral neonatal pyogenic granuloma (PG) initially suggestive of a diffuse neonatal haemangiomatosis.

CASE REPORT

A full-term female newborn, with no significant past medical history, was referred to our department for treatment of an acute respiratory distress syndrome of neurological origin at day 8 of life. At birth, she presented with 3 small angiomatic papules and 4 subcutaneous nodules suggestive of neonatal haemangiomatosis (NH) (Fig. 1). A brain MRI revealed a highly vascularised brain stem tumour suggestive of glioma (Fig. 2), associated with 2 abnormal hepatic lesions consistent with infantile haemangiomas (IH) on ultrasound and CT scan. Methylprednisolone was started for the suspected glioma-associated oedema, and vincristine and propranolol were introduced for NH. After initial improvement, an acute intracranial hypertension related to cystic evolution of the disease necessitated surgical resection at the age of 2 months. Pathological examinations of the brain, cutaneous and

subcutaneous lesions were similar, showing a vascular lobular proliferation of capillaries highly suggestive of PG. The misdiagnosis of glioma was eliminated. The GLUT-1 antigen marker was negative, ruling out the diagnosis of NH-like infantile haemangioma (Fig. 3). Lymphatic marker (D2-40) was also negative and eliminated a multifocal lymphangioendotheliomatosis with thrombocytopaenia (MLT). Cutaneous and hepatic lesions gradually regressed. She is currently in complete remission after completing a treatment over 18 months with propranolol but a spontaneous improvement can not be excluded.

DISCUSSION

Pyogenic granuloma, also known as botryomycoma or lobular capillary haemangioma, is a very common solitary benign vascular tumour, which usually develops on normal skin at the site of minimal skin trauma. At times it occurs spontaneously, particularly in children and

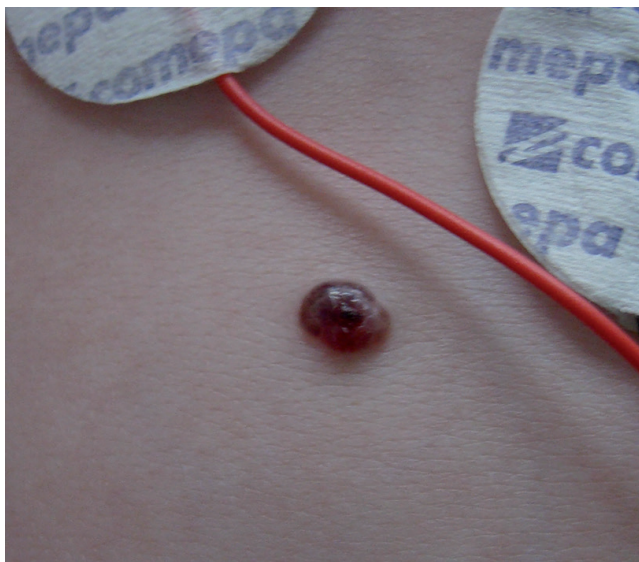


Fig. 1. Skin examination: 2 mm necrotic erythematous hemispheric papule on the abdomen.

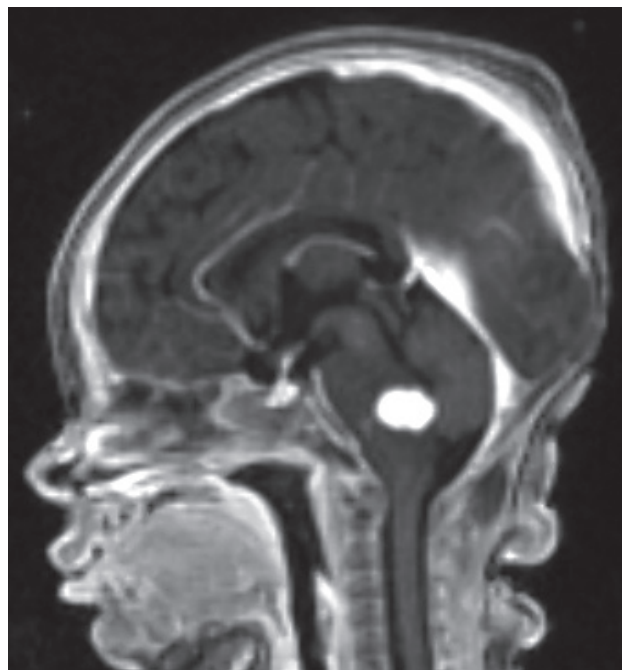


Fig. 2. Brain MRI showing a highly vascularised brain stem tumour (white spot) first suspected for glioma.

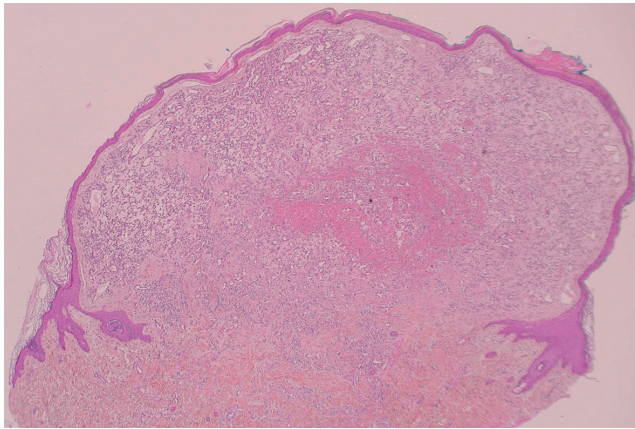


Fig. 3. Histopathologic features showing a lobular circumscribed proliferation of capillaries in the dermis, with a "collarette" of invaginated epidermis, haematoxylin-eosin stain.

pregnant women. Less than 20 cases of disseminated PG or PG-like lesions have been reported in patients suffering from extensive burns, immunosuppression or malignant diseases for individuals treated with the haematopoietic growth factor, probably through angiogenic stimulation. Occasional resolution occurred without treatment (1).

A congenital occurrence of disseminated cutaneous PG-like lesions has been previously reported in only 5 cases (1–4) (Table I). Our case is the first to document cerebral lesion in addition to cutaneous ones, which also displayed pathological features of PG with GLUT-1 negativity. This entity can be differentiated from NH-like IH through GLUT-1 immunostaining, among other things. This also illustrates that not all multifocal vascular lesions in infancy are IH and that the liver is not the only other organ to potentially scrutinise (5).

Indeed, cases similar to our own, along with MLT, Blue Rubber Bleb and others are not so uncommon that

we should overlook them, since delaying the diagnosis can lead to considerable morbidity.

These cases of congenital multiple vascular lesions are not only different from NH-like IH, which is not congenital and is GLUT-1 positive, but also are different from common, reactive and solitary PG which develop as an insignificant event in children, although they apparently share similar pathological features. To differentiate this new entity from NH-like IH and common PG, we propose the term PCD angiomas for "PG-like Congenital and Disseminated angiomas" which accounts for the following criteria: angiomatic lesions with pathological features of PG (PG-like) and congenital onset on the skin and other organs (Disseminated). Responsiveness to β -blockers is previously unknown and cannot be firmly established based on our findings.

The authors declare no conflict of interest.

REFERENCES

1. Browning JC, Eldin KW, Kozakewich HPW, Mulliken JB, Bree AF. Congenital disseminated pyogenic granuloma. *Pediatr Dermatol* 2009; 26: 323–327.
2. North PE, Waner M, James CA, Mizeracki A, Frieden IJ, Mihm MC Jr. Congenital nonprogressive hemangioma: a distinct clinicopathologic entity unlike infantile hemangioma. *Arch Dermatol* 2001; 137: 1607–1620.
3. Patrice SJ, Wiss K, Mulliken JB. Pyogenic granuloma: a clinical study of 178 cases. *Pediatr Dermatol* 1991; 8: 267–276.
4. Uyama A, Kawamura A, Akiyama H, Nakamizo S, Yamamoto K, Nagashima T, et al. A case of cerebellar capillary hemangioma with multiple cysts. *Pediatr Neurosurg* 2008; 44: 344–349.
5. Glick ZR1, Frieden IJ, Garzon MC, Mully TW, Drolet BA. Diffuse neonatal hemangiomatosis: an evidence-based review of case reports in the literature. *J Am Acad Dermatol* 2012; 67: 898–903.

Table I. Cases of pyogenic granuloma-like and congenital disseminated angiomatoid lesions

Ref.	Sex	Angiomatous lesions <i>n</i>	Location of angiomatous lesions	GLUT-1 staining	Location of visceral lesions	Clinical history	Course
Patrice, et al. (patient 2) (3)	M	>20	Face, trunk, extremities	Not done	–	–	Excision of skin lesions, some self-healing
Browning, et al. (patient 1) (1)	F	20–30	Head, trunk, extremities	Negative	No	No	Excision or pulsed-dye laser for skin lesions, some self-healing
Browning, et al. (patient 2) (1)	M	0–30	Face, trunk, extremities	Negative	Lung*	Decreased foetal movement several weeks prior to delivery	Prednisone, excision of skin lesions
North, et al. (2)	F	>100	Head, trunk, extremities	Negative	Lung*	–	–
Uyama, et al. (4)	F	Several	Head, trunk, extremities	Not done	Cerebral and multi-visceral	No	Cerebellar lesion resection with no recurrence
Our case	F	3	Trunk	Negative	Cerebral and hepatic	No	Brainstem lesion resection, with no recurrence; skin lesion resection, resolution of remainder

*Lung lesions without pathological examination.