



HAL
open science

A New Lamin A Mutation Associated with Acrogeria Syndrome

Smail Hadj-Rabia, Jacob Mashiah, Patrice Roll, Amandine Boyer, Patrice Bourgeois, Philippe Khau van Kien, Nicolas Lévy, Annachiara de Sandre-Giovannoli, Christine Bodemer, Claire L. Navarro

► **To cite this version:**

Smail Hadj-Rabia, Jacob Mashiah, Patrice Roll, Amandine Boyer, Patrice Bourgeois, et al.. A New Lamin A Mutation Associated with Acrogeria Syndrome. *Journal of Investigative Dermatology*, 2014, 134 (8), pp.2274-2277. 10.1038/jid.2014.158 . hal-01669120

HAL Id: hal-01669120

<https://amu.hal.science/hal-01669120>

Submitted on 6 Feb 2018

HAL is a multi-disciplinary open access archive for the deposit and dissemination of scientific research documents, whether they are published or not. The documents may come from teaching and research institutions in France or abroad, or from public or private research centers.

L'archive ouverte pluridisciplinaire **HAL**, est destinée au dépôt et à la diffusion de documents scientifiques de niveau recherche, publiés ou non, émanant des établissements d'enseignement et de recherche français ou étrangers, des laboratoires publics ou privés.

A New Lamin A Mutation Associated with Acrogeria Syndrome

TO THE EDITOR

Acrogeria (OMIM#201200), first described in 1940 (Gottron, 1940), is a form of skin atrophy combined with mottled hyperpigmentation and subcutaneous tissue atrophy giving an aged appearance. The pathogenesis of acrogeria seems heterogeneous, as abnormal biosynthesis of type III collagen is suspected in some cases, making Gottron-type acrogeria and vascular-type Ehlers–Danlos syndrome (vEDS, OMIM#130050) allelic diseases (Pope *et al.*, 1996; Jansen *et al.*, 2000; Hashimoto *et al.*, 2004).

Several clinical features of acrogeria recall the dermatologic defects observed

in Hutchinson–Gilford progeria syndrome (HGPS OMIM#176670), mandibuloacral dysplasia type A (MADAOMIM#248370), or mandibuloacral dysplasia type B (MADB, OMIM #608612) phenotypes, known to be caused by Lamins A/C defects, due to mutations either in the *LMNA* gene that encodes them or in the *ZMPSTE24* gene, which encodes a protease involved in Lamin A processing (Novelli *et al.*, 2002; De Sandre-Giovannoli *et al.*, 2003; Eriksson *et al.*, 2003; Ahmad *et al.*, 2010). Lamins are nuclear intermediate filaments that are involved in nuclear architecture and functions including chromatin organization or DNA replication, transcription,

and repair, reviewed in Prokocimer *et al.*, 2009.

The patient affected with acrogeria was born in 1969 from a healthy mother and a probably affected father, who was reported by the patient to have the same skin aspect and had a mitral and aortic valve replacement. The patient has a brother and a son who are not affected. At the age of 36 years, he was referred to our department for “prematurely aged” appearance. He presented with a thin nose and translucent skin on the face (Figure 1a, A). The distal portion of the lower limbs seemed lipodystrophic and the patient presented short clavicles (Figure 1a, B). Translucent skin of the arms and abdomen had pigmentation abnormalities (Figure 1a, B, C). The hands and the feet showed atrophic dermis and loss of subcutaneous fat (Figure 1a, B, D). The hands had a very

aged appearance with prominent veins and osteolyses of the distal phalanges (Figure 1a, D). All these clinical signs are strikingly evocative of HGPS or MAD phenotypes. Cardiovascular, pulmonary, ophthalmological, and central nervous system examinations revealed no abnormalities (data not shown). Liver and renal functions were normal, and the patient was not diabetic. The patient consented to his image being used.

A skin biopsy of the right arm showed slight epidermal hyperplasia (Figure 1a, E), irregular and fragmented elastic fibers (orcein staining, Figure 1a, F), and disorganization of collagen bundles with degenerative aspect of collagen network (Figure 1a, G). EDTA blood was obtained from the patient and

family members following written consent, in adherence to the Declaration of Helsinki principles. We screened *LMNA* gene at the genomic level and observed the c.1771T>A heterozygous transition in exon 11 (Figure 1b). The mutation was observed only in the proband and was absent in the rest of the unaffected family. Unfortunately, the DNA of the affected father was not available because he died several years earlier (Figure 1c). At the protein level, the identified mutation was predicted to replace a Cysteine with a Serine at amino acid position 591 (p.Cys591Ser), in the C-terminal part specific to lamin A (from 567–664), being absent from lamin C (stop at 566). This mutation was absent in more than 100 healthy internal controls, as well as in 1500

other patients tested in our molecular diagnostic laboratory in other clinical contexts evocative of a laminopathy; it is not reported in the UMD-*LMNA* database (<http://www.umd.be/LMNA/>) nor in the 1000 genome resources (<http://browser.1000genomes.org/index.html>) or the UCSC genome browser (<http://genome.ucsc.edu/>) as a SNP.

On the basis of deleted Lamin A isoforms associated with *LMNA* exon 11 mutations, we performed cDNA explorations with overlapping and “full-length” primers but did not observe any shorter transcripts (data not shown). In concordance with the reverse transcription–PCR (RT-PCR) analyses, Western blots on primary dermal fibroblasts did not reveal any truncated form at the protein level and showed normal Lamins A/C amounts (Figure 2a, lane 1) in comparison with healthy control (lane 2). No band was evidenced with a progerin-specific antibody, opposite to a HGPS patient, used as a progerin positive “control” (lane 3; Figure 2a).

In parallel, as the vEDS and acrogeria are often misdiagnosed, and because a mutation in the *COL3A1* gene has already been reported in a patient with Gottron-type Acrogeria (Jansen *et al.*, 2000), we excluded *COL3A1* mutations or transcript alterations by RT-PCR and direct sequencing from the *COL3A1* cDNA issued from the patient’s fibroblast cell line (data not shown).

Several laminopathies are characterized by nuclear abnormalities, reflecting a nuclear fragility caused by nuclear lamina instability (Schreiber and Kennedy, 2013). To support the pathogenicity of the identified mutation, we performed indirect immunofluorescence experiments using anti-lamins A/C on patient and control fibroblasts and evidenced that 35.2% of patient’s nuclei presented a misshaped nuclear structure characterized by blebs (Figure 2b, asterisk), but also abundant micronuclei representing 8% of total nuclei (Figure 2b, arrowhead), compared with 11 and 1.3%, respectively, in control fibroblasts (Supplementary Figure S1 online). Antibodies directed against Emerin and Lamin B2, both Lamin A partners, confirmed these anomalies. Staining with NuMA antibody showed a heterogeneous nuclear staining in

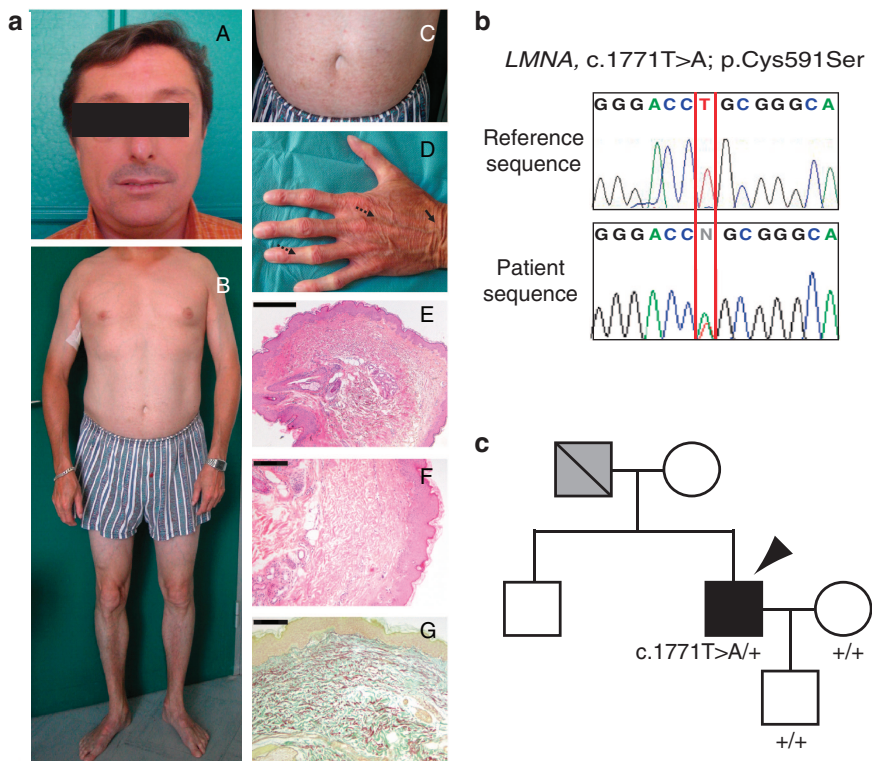


Figure 1. Clinical features and molecular characterization. (a) Clinical feature (36 years old). (A) Patient’s face, (B) body, (C) abdomen with pigmented macules, and (D) aged appearance of the hands. Prominent veins (dotted arrow) and wrinkles (black arrow) are indicated. (E) Hematoxylin and eosin staining, scale bar = 2 mm. Thinned dermis with sweat glands ascents (asterisk). (F) Hematoxylin and eosin staining, scale bar = 4 mm. Disorganization of collagen bundles with degenerative aspect is shown by asterisk. (G) Orcein staining, scale bar = 4 mm. Fragmentation of the elastic fibers is indicated by asterisk. (b) Genetic analysis of the *LMNA* gene in the proband (bottom) compared with control (top). Heterozygous mutation, T to A transition, underlined by red lines, is positioned at the coding nucleotide 1771 in exon 11 (c.1771T>A; p.Cys591Ser). (c) Pedigree of the family. The affected individual is shown by arrowhead, unfilled symbols correspond to unaffected subjects, and individual for whom the disease is suspected is shown as a gray symbol. Diagonal slash indicates the deceased subject. Images used with the patient’s consent.

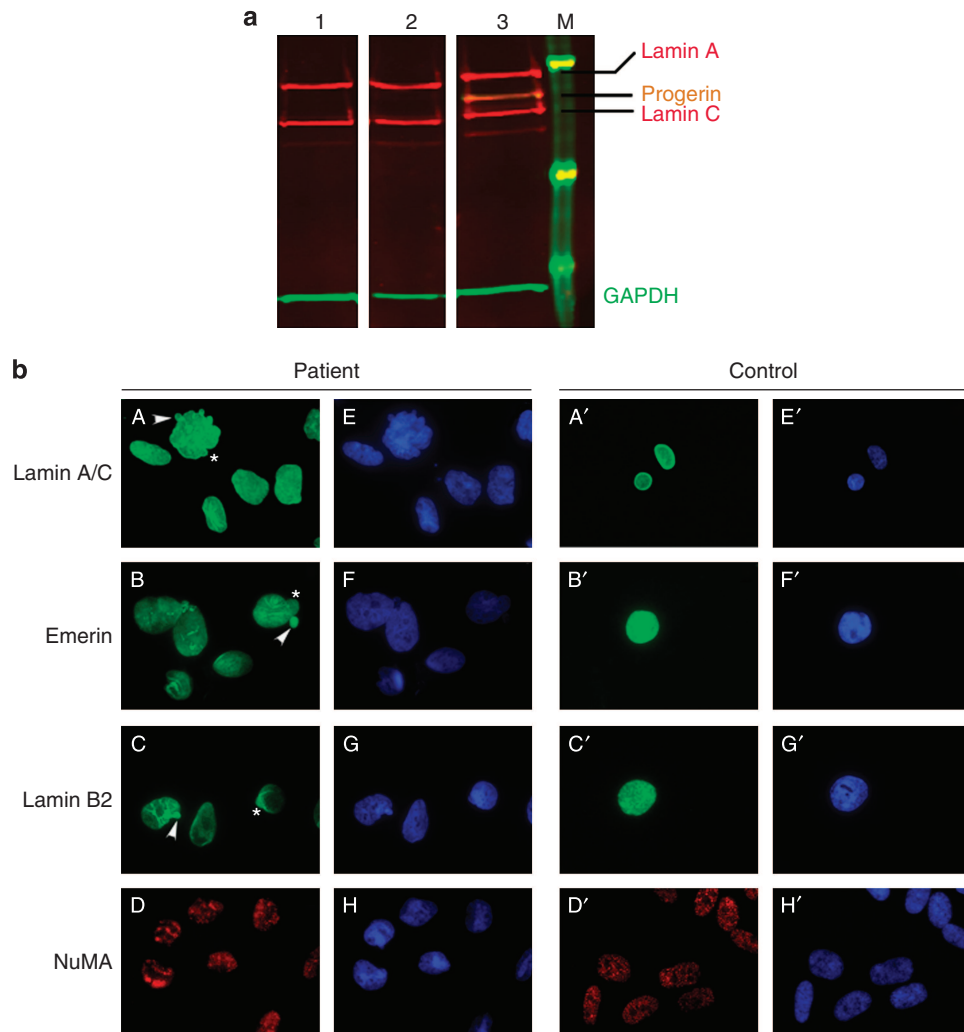


Figure 2. Functional analyses. (a) Western blot. Merged pictures of western blots using anti-lamins A/C (red), anti-progerin (green), and anti-glyceraldehyde-3-phosphate dehydrogenase (GAPDH; green), as a loading control. Patient’s proteins are loaded in lane 1, the healthy control’s proteins in lane 2, and the Hutchinson–Gilford progeria syndrome patient’s proteins in lane 3. Progerin band is present only for the Hutchinson–Gilford progeria syndrome patient (middle band, lane 3). (b) Indirect immunofluorescence. Analyses on skin fibroblast cultures of patient (A–H) compared with control (A’–H’). Lamins A/C (A, A’), emerin (B, B’), and lamin B2 (C, C’) antibodies are in green. All these antibodies evidenced blebs indicated by asterisks and micronuclei by arrowheads. NuMA antibody (D, D’) is in red and shows a heterogeneous and mottled distribution pattern in patient (D) compared with control (D’). All images were counterstained with DAPI, in order to evidence DNA (E–H, E’–H’). Scale bars = 20 μm.

“clumps” in our patient (Figure 2b, D) compared with the homogeneous punctuate staining observed in the control (Figure 2b, D’). Despite the fact that only one patient is described in this study, which is a frequent situation in extremely rare disorders as are some laminopathies, the segregation of the disease in the family, the absence of the mutation in large control populations and databases, the presence of nuclear abnormalities, and the fact that the same Cysteine residue is mutated, with a different substitution (p.Cys591Phe) in a patient affected with partial lipodystrophy, insulin resistance, aortic stenosis, and

hypertrophic cardiomyopathy (Araújo-Vilar *et al.*, 2008), all are very strong arguments in favor of its pathogenicity. It is well established indeed that in the context of Lamins A/C mutations, different changes of the same amino acid can give rise to different clinical phenotypes (Bonne *et al.*, 1999).

The case we report points to the involvement of the *LMNA* gene in “acrogeria”, including this disease in the clinical spectrum of progeroid laminopathies. On the basis of the cardiac disease and dermatological manifestations observed in the father, another possible interpretation is that both cases,

the father and the son, are affected with a form of atypical progeria syndrome with major dermatologic features found in this patient (Doubaj *et al.*, 2012; Kane *et al.*, 2013). In both cases, the patient we report, sharing p.Cys591Ser in Lamin A protein and characterized by nuclear abnormalities in fibroblast culture, extends the clinical spectrum of progeroid laminopathies and suggests that the *LMNA* gene should be screened in patients presenting with segmental progeroid traits, as well as in acrogeria patients presenting wild-type *COL3A1* sequences. However, further functional studies will be needed to determine the

mutant function more precisely, and additional patient recruitment would be very helpful.

CONFLICT OF INTEREST

The authors state no conflict of interest.

ACKNOWLEDGMENTS

We are grateful to the patient who consented to his image being used.

**Smail Hadj-Rabia^{1,2,8},
Jacob Mashiah^{1,2,8}, Patrice Roll^{3,4},
Amandine Boyer⁵, Patrice Bourgeois⁵,
Philippe Khau Van Kien^{6,7},
Nicolas Lévy^{3,5},
Annachiara De Sandre-Giovannoli^{3,5},
Christine Bodemer^{1,2} and
Claire Navarro³**

¹Department of Dermatology, Reference Center for Genodermatoses and Rare Skin Diseases (MAGEC), INSERM U781, Université Paris Descartes—Sorbonne Paris Cité, Paris, France; ²Institut Imagine, Hôpital Universitaire Necker-Enfants Malades, Assistance Publique-Hôpitaux de Paris, Paris, France; ³Aix Marseille Université, GMGF, INSERM, UMR_S 910, Marseille, France; ⁴Laboratoire de Biologie Cellulaire, Assistance Publique-Hôpitaux de Marseille, Hôpital d'Enfants La Timone, Marseille, France; ⁵Laboratoire de Génétique Moléculaire, Assistance Publique-Hôpitaux de Marseille, Hôpital d'Enfants La Timone, Marseille, France; ⁶Laboratoire de Génétique

Moléculaire, Centre de Compétences Maladies Vasculaires Rares, CHU de Montpellier, Montpellier, France and ⁷Laboratoire de Cytologie Clinique et Cytogénétique, UF Génétique Médicale, CHU de Nîmes, Nîmes, France

E-mail: claire.navarro@univ-amu.fr or smail.hadj@inserm.fr

⁸These authors contributed equally to this work.

SUPPLEMENTARY MATERIAL

Supplementary material is linked to the online version of the paper at <http://www.nature.com/jid>

REFERENCES

- Ahmad Z, Zackai E, Medne L *et al.* (2010) Early onset mandibuloacral dysplasia due to compound heterozygous mutations in ZMPSTE24. *Am J Med Genet A* 152A:2703–10
- Araújo-Vilar D, Lado-Abeal J, Palos-Paz F *et al.* (2008) A novel phenotypic expression associated with a new mutation in LMNA gene, characterized by partial lipodystrophy, insulin resistance, aortic stenosis and hypertrophic cardiomyopathy. *Clin Endocrinol (Oxf)* 69:61–8
- Bonne G, Di Barletta MR, Varnous S *et al.* (1999) Mutations in the gene encoding lamin A/C cause autosomal dominant Emery-Dreifuss muscular dystrophy. *Nat Genet* 21:285–8
- De Sandre-Giovannoli A, Bernard R, Cau P *et al.* (2003) Lamin a truncation in Hutchinson-Gilford progeria. *Science* 300:2055
- Doubaj Y, De Sandre-Giovannoli A, Vera EV *et al.* (2012) An inherited LMNA gene mutation in

atypical progeria syndrome. *Am J Med Genet A* 158A:2881s–7s

- Eriksson M, Brown WT, Gordon LB *et al.* (2003) Recurrent de novo point mutations in lamin A cause Hutchinson-Gilford progeria syndrome. *Nature* 423:293–8
- Gottron H (1940) Familiäre Akrogerie. *Arch Dermatol Syph* 181:571
- Hashimoto C, Abe M, Onozawa N *et al.* (2004) Acrogeria (Gottron type): a vascular disorder? *Br J Dermatol* 151:497–501
- Jansen T, de Paep A, Luytincx N *et al.* (2000) COL3A1 mutation leading to acrogeria (Gottron Type). *Br J Dermatol* 142:178–80
- Kane MS, Lindsay ME, Judge DP *et al.* (2013) LMNA-associated cardiocutaneous progeria: an inherited autosomal dominant premature aging syndrome with late onset. *Am J Med Genet A* 161A:1599–611
- Novelli G, Muchir A, Sangiuolo F *et al.* (2002) Mandibuloacral dysplasia is caused by a mutation in LMNA-encoding lamin A/C. *Am J Hum Genet* 71:426–31
- Pope FM, Narcisi P, Nicholls AC *et al.* (1996) COL3A1 mutations cause variable clinical phenotypes including acrogeria and vascular rupture. *Br J Dermatol* 135:163–81
- Prokocimer M, Davidovich M, Nissim-Rafinia M *et al.* (2009) Nuclear lamins: key regulators of nuclear structure and activities. *J Cell Mol Med* 13:1059–85
- Schreiber KH, Kennedy BK (2013) When lamins go bad: nuclear structure and disease. *Cell* 152:1365–75