



HAL
open science

Gamma Knife radiosurgery for hypothalamic hamartoma preserves endocrine functions

Frederic Castinetti, Thierry Brue, Isabelle Morange, Romain Carron, Jean Régis

► **To cite this version:**

Frederic Castinetti, Thierry Brue, Isabelle Morange, Romain Carron, Jean Régis. Gamma Knife radiosurgery for hypothalamic hamartoma preserves endocrine functions. *Epilepsia*, 2017, 58, pp.72 - 76. 10.1111/epi.13760 . hal-01724160

HAL Id: hal-01724160

<https://amu.hal.science/hal-01724160>

Submitted on 10 Apr 2018

HAL is a multi-disciplinary open access archive for the deposit and dissemination of scientific research documents, whether they are published or not. The documents may come from teaching and research institutions in France or abroad, or from public or private research centers.

L'archive ouverte pluridisciplinaire **HAL**, est destinée au dépôt et à la diffusion de documents scientifiques de niveau recherche, publiés ou non, émanant des établissements d'enseignement et de recherche français ou étrangers, des laboratoires publics ou privés.

Gamma Knife radiosurgery for hypothalamic hamartoma preserves endocrine functions

*Frederic Castinetti, *Thierry Brue, *Isabelle Morange, †Romain Carron, and †Jean Régis

SUMMARY

Gamma Knife radiosurgery (GK) is an effective treatment for hypothalamic hamartoma. No precise data are available on the risk of endocrine side effects of this treatment. In this study, 34 patients with hypothalamic hamartoma (HH) were followed prospectively at the Department of Endocrinology, La Timone Hospital, Marseille, France, for a mean follow-up of >2 years (mean \pm standard deviation [SD] 3.6 ± 2 years). Initial pre- and post-GK radiosurgery evaluations were performed, including weight, body mass index (BMI), and a complete endocrinological workup. At diagnosis, eight patients presented with central precocious puberty at a mean age of 5.4 ± 2.4 years. At the time of GK (mean age 18.2 ± 11.1 years), two patients previously treated with surgery presented with luteinizing hormone/follicle-stimulating hormone (LH/FSH) deficiency. After GK, only one patient presented with a new thyrotropin-stimulating hormone (TSH) deficiency, 2 years after the procedure. The other pituitary axes remained normal in all but two patients (who had LH/FSH deficiency prior to GK). There was no significant difference between pre- and post-GK mean BMI (26.9 vs. 25.1 kg/m², $p = 0.59$). To conclude, in this group of 34 patients, GK did not induce major endocrinologic side effects reported with all the other surgical techniques in the literature. It is, thus, a safe and effective procedure in the treatment of hypothalamic hamartoma.

KEY WORDS: Pituitary deficiency, Epilepsy, Radiotherapy, Neurosurgery, Weight gain.

Hypothalamic hamartoma is a rare, slowly growing benign lesion arising from the floor of the third ventricle, tuber cinereum, or mammillary bodies. It can be asymptomatic, or revealed by neurologic disturbances (mainly gelastic seizures).¹ Hypothalamic hamartoma is usually sporadic, even if mutations in the zinc finger transcription factor gene of the GLI family (*GLI3*) have been reported. In a large series of 76 patients with *GLI3* mutations, 4 of 13 patients tested were reported to have growth-hormone (GH)

deficiency, and one presented initially with panhypopituitarism.²

Hypothalamic hamartoma can be associated with central precocious puberty in 30% to 80% of cases.³ This symptom is usually seen in patients carrying pedunculated hypothalamic hamartomas. The precise mechanisms by which hypothalamic hamartomas could induce precocious puberty remain unclear; activation of gonadotropin-releasing hormone (GnRH) via astroglial-derived factors, induction of hypothalamic pubertal neuroendocrine function by secretion of transforming growth factor, or ectopic GnRH neurosecreting cells (ectopic GnRH pulse generator) located in the hamartoma have all been proposed as hypotheses. Patients with hypothalamic hamartoma in the near vicinity to the GnRH system (median eminence, para-hypothalamic position) might be at higher risk of developing precocious puberty. Central precocious puberty in hypothalamic hamartoma correlates with anatomic features, particularly the position in contact with the tuber cinereum or

*Department of Endocrinology, Assistance Publique Hôpitaux de Marseille, La Timone Hospital, Aix-Marseille University, Marseille, France; and †Department of Functional Neurosurgery, Assistance Publique Hôpitaux de Marseille, La Timone Hospital, Aix-Marseille University, Marseille, France

Address correspondence to Frederic Castinetti, La Timone Hospital, Department of Endocrinology, Rue Saint-Pierre, 13005 Marseille, France. E-mail: frederic.castinetti@ap-hm.fr

KEY POINTS

- Gamma Knife radiosurgery is a safe endocrinologic procedure in the treatment of hypothalamic hamartoma
- New onset of delayed pituitary deficiency is a rare event after Gamma Knife radiosurgery
- No hypothalamic syndrome is to be expected after the procedure
- The risk of endocrine side effects should be considered when treatment options are discussed

infundibulum, but not to expression of GnRH, transforming growth factor α (TGF α), or Kiss-1-metastasis-suppressor (KISS1).⁴ Age at diagnosis is frequently before 2 years,⁵ leading to a final shorter stature than expected if left untreated by GnRH agonists.⁶

In contrast to central precocious puberty, pituitary deficiencies are rarely present at diagnosis. In a series of 21 patients with hypothalamic hamartoma, Taylor and colleagues reported the lack of pituitary deficiencies in their patients compared with patients with other pediatric hypothalamic-pituitary lesions, such as craniopharyngioma (pituitary deficiencies in more than two thirds of the patients), suprasellar arachnoid cyst (50%), germ cell tumor (50%), and optic pathway glioma (20%).⁷ Freeman et al. reported the results of presurgical endocrine evaluation of 29 patients aged 4–23 years presenting with hypothalamic hamartoma: four patients were found to have thyroid stimulating hormone (TSH) deficiency, whereas five had complete GH deficiency. Of note is that low cortisol levels were also reported in six patients. However, some of these patients had been treated previously with surgery, and it is thus difficult to ascertain whether the observed pituitary deficiencies were ascribable to the hamartoma itself and not related to previous surgical procedures.⁸ Few case reports of GH or TSH deficiencies have been published, whereas no adrenocorticotropin hormone (ACTH) deficiency has been described.^{9–11}

The treatment of hypothalamic hamartoma can be based on surgery, including transcallosal interforniceal, endoscopic disconnection, radiofrequency thermocoagulation, or brachytherapy. Major endocrinologic complications have been reported after each of these techniques.^{7,11,12} In the present study, we decided to focus specifically on the potential endocrine effects of Gamma Knife radiosurgery (GK) in patients treated for hypothalamic hamartoma, based on 34 patients prospectively followed at the Department of Endocrinology of La Timone Hospital, Marseille, France.

METHODS

Between 2000 and 2011, 54 patients with hypothalamic hamartoma were prospectively followed after being treated

at the Department of Functional Neurosurgery, La Timone Hospital, Marseille, France. Of these 54 patients, 34 patients who had a minimal endocrinologic follow-up of >2 years after treatment have been included. These patients were evaluated in the Department of Endocrinology, La Timone Hospital, Marseille, France, 3 months after and again at least 2 years after GK.

Data were retrieved on the occurrence of central precocious puberty at initial diagnosis. Data on the radiosurgical procedure (maximum, mean dose, reference isodose) and the hamartoma (volume and anatomic classification) were noted. All patients had weight measurement and evaluation of body mass index (BMI) before GK and at last follow-up. The minimal pre- and post-GK endocrinologic evaluation included 8-h ACTH and cortisol, insulin growth factor 1 (IGF1), TSH, free T3, free T4, prolactin, luteinizing hormone (LH), follicle stimulating hormone (FSH), and testosterone (in males) or estradiol (in females). Dynamic testing of growth hormone (GHRH test) was planned for patients with low age and sex IGF1. Complete somatotroph deficiency was defined by low IGF1 and stimulated GH level <10 mUI/L; partial GH deficiency was defined by low IGF1 and stimulated GH level <19 mUI/L. Corticotroph deficiency was defined by low or normal ACTH associated with low basal or stimulated (<550 nmol/L) cortisol level. Dynamic testing of corticotroph axis was planned when the 8-h cortisol level was <300 nmol/L and >140 nmol/L. Thyrotroph deficiency was defined by low or normal TSH (normal value 0.4–5 mUI/L), associated with low free T4 level (normal value 12–22 pmol/L). Gonadotroph deficiency was defined by amenorrhea and low LH/FSH and estradiol levels after the age of 18 years in female patients, and low LH/FSH and testosterone levels in male patients.

Data are presented as mean \pm standard deviation (SD). Statistical analysis with chi-square test was performed with XLStats version 13.0.1 (Paris, France) to compare pre- and post-GK body body-mass index (BMI). $p < 0.05$ was considered statistically significant.

RESULTS

Individual data are presented in Table 1. At initial evaluation, eight patients (23.5%) had been diagnosed with central precocious puberty (mean age 5.4 ± 2.4 years). GK was delivered at a mean age of 18.2 ± 11.1 years. The mean reference isodose was 49.3 ± 3.9 Gy, and the mean dose was 17.1 ± 2.3 Gy. Mean volume of the target was 670.7 ± 896.3 mm³. Anatomic classification defined 8 class I; 12 class II; 8 class III; 1 class IV, V, and VI; and 3 mixed hamartomas.¹³ Two patients had been previously treated by surgery, whereas 32 received GK as a first-line treatment. Mean initial BMI was 25.1 ± 2.8 kg/m². The two patients previously treated by surgery presented with LH/FSH deficiency. No GH, thyrotroph, or corticotroph

Table 1. Individual data of the 34 patients included in the study

Patient number	Age at diagnosis	Age at GK	Sex	Precocious puberty	Age at last f/up	Induced – pituitary deficiency	Final BMI	BMI Z score or status
1	0.75	3	F	Y	7	N	17.7	+3 SD
2	0.5	3	M	Y	6	N	18.3	+3 SD
3	3	4	M	N	8	N	27.9	Obesity
4	7	7	M	N	10	N	18.1	+2 SD
5	7	7	F	N	9	N	20.1	Overweight
6	3	8	M	N	11	N	25.3	Obesity
7	7	8	M	N	11	N	17.8	+1 SD
8	2	9	F	Y	11	N	23.1	Overweight
9	7	9	F	N	11	N	19.7	Overweight
10	4	11	M	Y	14	N	19.8	+1 SD
11	2	12	F	Y	17	N	29.4	Overweight
12	6	12	M	Y	14	N	17.6	–1 SD
13	6	12	F	Y	15	N	24.9	+3 SD
14	6	12	F	N	15	N	20.2	+1 SD
15	5	13	M	N	18	N	23.2	+2 SD
16	5	15	M	N	17	N	25.7	+3 SD
17	14	15	M	N	18	N	24.8	+3 SD
18	6	16	F	N	22	N	23.3	Normal
19	8	16	F	N	19	N	18.3	Normal
20	13	19	M	N	22	N	22.3	Normal
21	6	20	F	N	27	N	22.6	Normal
22	8	20	M	N	26	N	27.7	Overweight
23	6	23	F	Y	25	N	38.6	Obesity
24	8	24	M	N	26	N	27.4	Overweight
25	3	25	M	N	32	N	26.9	Overweight
26	4	25	M	N	31	N	23.5	Normal
27	8	29	M	N	31	N	25.8	Overweight
28	16	29	M	N	33	N	39.0	Obesity
29	0.5	29	F	N	31	N	29.4	Overweight
30	20	30	F	N	32	N	18.3	Normal
31	25	31	F	N	42	N	30.4	Obesity
32	2	31	M	N	34	TSH	28.1	Overweight
33	10	41	F	N	43	N	30.5	Obesity
34	7	50	M	N	53	N	33.7	Obesity

Age at diagnosis, age at GK, age at last follow-up (years). Sex, F, female; M, male. Precocious puberty, Y, yes; N, no. Pituitary deficiency, N, No; TSH, TSH deficiency. BMI Z score is given for individuals <18 years of age at final evaluation. Overweight was defined by a BMI ≥ 25 kg/m²; obesity by a BMI >30 kg/m².

deficiency was observed. Prolactin level was in the normal range in all patients. No sodium or diuresis abnormality was reported.

After GK, mean time to follow-up was 3.6 ± 2 years. There was no statistical difference ($p = 0.59$) between pre- and post-GK BMI; final mean BMI after the procedure was 26.9 ± 3.4 kg/m² (Fig. 1). Of note, one patient presented a transient weight gain (+10 kg) in the 3 months following GK, but he rapidly recovered, and final evaluation weight was comparable to pre-GK weight (without any concomitant change on antiepileptic drugs). Only one patient was found to have a new pituitary deficiency; TSH deficiency (TSH 2 mUI/L; T4 8.7 pmol/L) was diagnosed 2 years after the procedure and remained at last follow-up (5 years after GK). No GH and ACTH deficiency was observed. Prolactin remained in the normal range in all patients. No new gonadotroph deficiency was observed (apart from the two

patients with initial LH/FSH deficiency, and for whom evaluation remained unchanged). No sodium or diuresis abnormality was reported.

DISCUSSION

The treatment of hypothalamic hamartoma is challenging. Apart from remission or at least decrease in the frequency of epileptic episodes, the endocrinologic outcome is also paramount, as profound side effects such as hyponatremia, diabetes insipidus, massive weight gain with compulsive hyperphagia, hyperthermia, and poikilothermia have been reported after surgery by the transcallosal approach.⁸ Drees and coworkers also reported the occurrence of hormonal disturbances in roughly 25% of the 26 patients treated by endoscopic resection, and in >50% of the 10 patients treated by a combined endoscopic-transcallosal

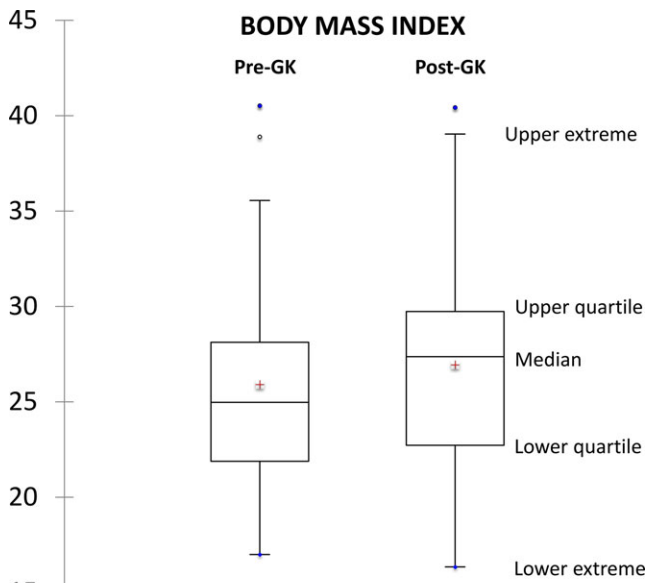


Figure 1. Comparison of BMI pre-Gamma Knife (pre-GK), and at final follow-up after radiosurgery (post-GK). Mean follow-up was 3.6 years, and no patient had a follow-up at <2 years. The red cross represents the mean. Open circle represents outlier/single data point. Closed circle represents maximal value. There was no significant difference when comparing pre- and post-GK mean BMI ($p = 0.59$).
Epilepsia © ILAE

approach. Of interest, major weight gain was reported in 59% and 71% of the patients treated by these two procedures, respectively.¹² Interstitial radiosurgery is another possible approach; Schulze-Bonaghe reported the occurrence of weight gain in 3 of 15 patients (5, 6, and 20 kg), and the lack of pituitary deficiency, poikilothermia, or dysnatremia, after a follow-up of 12 months^{11,14} (Table 2). It is notable that our individual BMI data (Table 1) suggest that while there is no major weight gain after GK, most of the patients are overweight, obese, or at least present a BMI that is greater than normal values (+2 or +3 SD). As most patients had not been treated before by surgery, it suggests

that the disease rather than the treatment is responsible for the weight gain. Because hypothalamic hamartoma and epilepsy treatments usually have a strong impact on daily life, avoiding potential iatrogenic factors, such as weight gain, should be a reasonable aim of any hypothalamic hamartoma treatment.

GK is an effective treatment of hypothalamic hamartoma.^{15–18} Up to now, however, few data were available on the potential endocrine side effects of such treatment. To our knowledge, only one study reported the endocrine outcome of patients treated by GK for hypothalamic hamartoma: Abla et al.¹⁹ reported no pituitary deficiency in 15 patients followed for 18–81 months, but did note the occurrence of transient poikilothermia in one, weight gain in 2, and anxiety and depression in 2 patients. Precise data on the methods of endocrine evaluation were not mentioned in the study. To our knowledge, our study is, thus, the first to prospectively focus on potential endocrine side effects of GK in hypothalamic hamartomas, with a strict endocrine follow-up. Our previous reports based on the use of GK in secreting adenomas could have suggested a risk of delayed endocrine deficiencies after GK in hypothalamic hamartomas: the dose to the stalk was indeed a major risk factor for the development of new pituitary deficiencies, occurring 2–5 years after GK.²⁰ In the present study, however, we observed only one new pituitary deficiency (TSH) after GK in the 34 patients evaluated. The delayed onset of this new deficiency, which occurred 2 years after the procedure, makes it likely that this side effect resulted from GK, even if no study evaluated the spontaneous outcome of pituitary function (without any treatment) in patients with hypothalamic hamartoma. In this patient, treatment with substitutive thyroid hormones allowed rapid euthyroidism, and we consider that the overall impact to daily life was low. We decided to focus only on patients followed for at least 2 years, to avoid the risk of missing late pituitary deficiencies. The fact that pituitary deficiencies can be delayed by >5 years when GK is used as a treatment of pituitary adenomas justifies the need to maintain long-term follow-up of these patients. More interestingly, no permanent weight gain was observed in our patients: only one experienced a

Table 2. Summary of the main endocrinologic effects of the different techniques used for treating hypothalamic hamartoma

Author, year	Technique	Patients	Pituitary deficiency	Weight gain	Hypothalamic syndrome/dysnatremia
Freeman, 2003 ⁸	Transcallosal intraforaminal surgery	29	11/29 (38%)	10/22 (45%)	12/29 (41%)
Drees, 2012 ¹²	Endoscopic surgery	26	5/21 (24%)	13/22 (59%)	6/36 (17%) (Type of treatment was not mentioned)
Drees, 2012 ¹²	Combined surgical approaches	10	4/7 (57%)	5/7 (71%)	6/36 (17%) (Type of treatment was not mentioned)
Schulze-Bonaghe, 2008 ¹¹	Brachytherapy	15	No	3/15 (20%)	No
Abla, 2010 ¹⁹	Gamma Knife radiosurgery	10	No	2/10 (20%)	Poikilothermia in 1/10 (10%)
Current study	Gamma Knife radiosurgery	34	1/34 (3%)	1/34 (3%)	No

transient 10-kg weight gain in the months following the procedure, but complete recovery was obtained rapidly thereafter. By comparison, Freeman and coworkers reported that 13 of 26 operated patients had appetite stimulation with a tendency to hyperphagia, and a clinically significant weight gain $>2.5 \text{ kg/m}^2$ in 45% of cases.⁸

As GK was delivered at a mean age of 18 years, and precocious central puberty was diagnosed at a mean age of 5 years, most of the patients in the present study had already been treated effectively with GnRH agonists; this treatment is transient, and none of our patients experienced gonadotrophic issues at the withdrawal of the drug. In contrast, it is not possible to say whether GK could have improved this symptom secondary to hypothalamic hamartoma, as it has been shown in some patients after surgery.²¹ Given the high efficacy of GnRH agonists,²² we are not sure, however, that improvement of central precocious puberty should be the major factor to consider at the time of the treatment decision.

To conclude, our study emphasizes the lack of major endocrine side effects of GK as a treatment for hypothalamic hamartoma. Indications for surgery and radiosurgery might be different; however, the risk of side effects induced by surgery should be kept in mind when discussing treatment options. Future prospective studies are needed to completely rule out the risk of more delayed endocrine side effects.

TAKE HOME MESSAGES

- Endocrinologic side effects are rare after Gamma Knife radiosurgery used for hypothalamic hamartoma
- An endocrinologic workup should be undertaken 1 and 2 years after radiosurgery; no further endocrinologic follow-up is needed in the absence of pituitary deficiency/weight gain

DISCLOSURE

The authors have nothing to disclose. We confirm that we have read the Journal's position on issues involved in ethical publication and affirm that this report is consistent with those guidelines.

REFERENCES

- Mittal S, Mittal M, Montes JL, et al. Hypothalamic hamartomas. Part 1. Clinical, neuroimaging, and neurophysiological characteristics. *Neurosurg Focus* 2013;34:E6.
- Demurger F, Ichkou A, Mougou-Zerelli S, et al. New insights into genotype-phenotype correlation for GLI3 mutations. *Eur J Hum Genet* 2015;23:92–102.
- Jung H, Neumaier Probst E, Hauffa BP, et al. Association of morphological characteristics with precocious puberty and/or gelastic seizures in hypothalamic hamartoma. *J Clin Endocrinol Metab* 2003;88:4590–4595.
- Chan YM, Fenoglio-Simeone KA, Paraschos S, et al. Central precocious puberty due to hypothalamic hamartomas correlates with anatomic features but not with expression of GnRH, TGF α , or KISS1. *Horm Res Paediatr* 2010;73:312–319.
- Hochman HI, Judge DM, Reichlin S. Precocious puberty and hypothalamic hamartoma. *Pediatrics* 1981;67:236–244.
- Paul D, Conte FA, Grumbach MM, et al. Long-term effect of gonadotropin-releasing hormone agonist therapy on final and near-final height in 26 children with true precocious puberty treated at a median age of less than 5 years. *J Clin Endocrinol Metab* 1995;80:546–551.
- Taylor M, Couto-Silva AC, Adan L, et al. Hypothalamic-pituitary lesions in pediatric patients: endocrine symptoms often precede neuroophthalmic presenting symptoms. *J Pediatr* 2012;161:855–863.
- Freeman JL, Zacharin M, Rosenfeld JV, et al. The endocrinology of hypothalamic hamartoma surgery for intractable epilepsy. *Epileptic Disord* 2003;5:239–247.
- Feuillan P, Peters KF, Cutler GB Jr, et al. Evidence for decreased growth hormone in patients with hypothalamic hamartoma due to Pallister-Hall syndrome. *J Pediatr Endocrinol Metab* 2001;14:141–149.
- Rousseau-Nepton I, Kaduri S, Garfield N, et al. Hypothalamic hamartoma associated with central precocious puberty and growth hormone deficiency. *J Pediatr Endocrinol Metab* 2014;27:117–121.
- Schulze-Bonhage A, Trippel M, Wagner K, et al. Outcome and predictors of interstitial radiosurgery in the treatment of gelastic epilepsy. *Neurology* 2008;71:277–282.
- Drees C, Chapman K, Prenger E, et al. Seizure outcome and complications following hypothalamic hamartoma treatment in adults: endoscopic, open, and Gamma Knife procedures. *J Neurosurg* 2012;117:255–261.
- Regis J, Hayashi M, Eupierre LP, et al. Gamma knife surgery for epilepsy related to hypothalamic hamartomas. *Acta Neurochir Suppl* 2004;91:33–50.
- Schulze-Bonhage A, Quiske A, Homberg V, et al. Effect of interstitial stereotactic radiosurgery on behavior and subjective handicap of epilepsy in patients with gelastic epilepsy. *Epilepsy Behav* 2004;5:94–101.
- Quigg M, Harden C. Minimally invasive techniques for epilepsy surgery: stereotactic radiosurgery and other technologies. *J Neurosurg* 2014;121(Suppl):232–240.
- McGonigal A, Bartolomei F, Gavaret M, et al. Gamma knife radiosurgery of paracentral epilepsy. *Stereotact Funct Neurosurg* 2014;92:346–353.
- Regis J, Scavarda D, Tamura M, et al. Epilepsy related to hypothalamic hamartomas: surgical management with special reference to gamma knife surgery. *Childs Nerv Syst* 2006;22:881–895.
- Regis J, Bartolomei F, de Toffol B, et al. Gamma knife surgery for epilepsy related to hypothalamic hamartomas. *Neurosurgery* 2000;47:1343–1351; discussion 1351–1342.
- Abla AA, Shetter AG, Chang SW, et al. Gamma Knife surgery for hypothalamic hamartomas and epilepsy: patient selection and outcomes. *J Neurosurg* 2010;113(Suppl):207–214.
- Castinetti F, Regis J, Dufour H, et al. Role of stereotactic radiosurgery in the management of pituitary adenomas. *Nat Rev Endocrinol* 2010;6:214–223.
- Li CD, Luo SQ, Gong J, et al. Surgical treatment of hypothalamic hamartoma causing central precocious puberty: long-term follow-up. *J Neurosurg Pediatr* 2013;12:151–154.
- de Brito VN, Latronico AC, Arnhold IJ, et al. Treatment of gonadotropin dependent precocious puberty due to hypothalamic hamartoma with gonadotropin releasing hormone agonist depot. *Arch Dis Child* 1999;80:231–234.