



MRI follow-up is unnecessary in patients with macroprolactinomas and long-term normal prolactin levels on dopamine agonist treatment

J Eroukhmanoff, I Tejedor, I Potorac, T. Cuny, J. Bonneville, H. Dufour, G. Weryha, A. Beckers, P Touraine, Thierry Brue, et al.

► To cite this version:

J Eroukhmanoff, I Tejedor, I Potorac, T. Cuny, J. Bonneville, et al.. MRI follow-up is unnecessary in patients with macroprolactinomas and long-term normal prolactin levels on dopamine agonist treatment. *European Journal of Endocrinology*, 2017, 176 (3), pp.323 - 328. 10.1530/EJE-16-0897 . hal-01724182

HAL Id: hal-01724182

<https://amu.hal.science/hal-01724182>

Submitted on 10 Apr 2018

HAL is a multi-disciplinary open access archive for the deposit and dissemination of scientific research documents, whether they are published or not. The documents may come from teaching and research institutions in France or abroad, or from public or private research centers.

L'archive ouverte pluridisciplinaire **HAL**, est destinée au dépôt et à la diffusion de documents scientifiques de niveau recherche, publiés ou non, émanant des établissements d'enseignement et de recherche français ou étrangers, des laboratoires publics ou privés.

MRI follow-up is unnecessary in patients with macroprolactinomas and long-term normal prolactin levels on dopamine agonist treatment

J Eroukhmanoff¹, I Tejedor², I Potorac³, T Cuny⁴, J F Bonneville³, H Dufour⁵, G Weryha⁴, A Beckers³, P Touraine², T Brue¹ and F Castinetti¹

¹Aix Marseille University, Assistance Publique Hopitaux de Marseille, La Conception Hospital, Marseille, France, ²Groupe Hospitalier Pitié-Salpêtrière Service d'Endocrinologie & Médecine de la Reproduction, Paris, France, ³Domaine Universitaire du Sart Tilman CHU de Liège Service d'Endocrinologie, Liege, Belgium, ⁴CHU de Nancy – Hôpital de Brabois Clinique Médicale et Endocrinologique, Nancy, France, and ⁵Service de Neurochirurgie, Hôpital de la Timone, Marseille, France

Correspondence should be addressed to F Castinetti

Email
Frederic.castinetti@ap-hm.fr

Abstract

Objective: Both antitumor and antisecretory efficacies of dopamine agonists (DA) make them the first-line treatment of macroprolactinomas. However, there is no guideline for MRI follow-up once prolactin is controlled. The aim of our study was to determine whether a regular MRI follow-up was necessary in patients with long-term normal prolactin levels under DA.

Patients and methods: We conducted a retrospective multicenter study (Marseille, Paris La Pitie Salpetriere and Nancy, France; Liege, Belgium) including patients with macroprolactinomas (largest diameter: >10 mm and baseline prolactin level: >100 ng/mL) treated by dopamine agonists, and regularly followed (pituitary MRI and prolactin levels) during at least 48 months once normal prolactin level was obtained.

Results: In total, 115 patients were included (63 men and 52 women; mean age at diagnosis: 36.3 years). Mean baseline prolactin level was 2224 ± 6839 ng/mL. No significant increase of tumor volume was observed during the follow-up. Of the 21 patients (18%) who presented asymptomatic hemorrhagic changes of the macroprolactinoma on MRI, 2 had a tumor increase (2 and 7 mm in the largest size). Both were treated by cabergoline (1 mg/week) with normal prolactin levels obtained for 6 and 24 months. For both patients, no further growth was observed on MRI during follow-up at the same dose of cabergoline.

Conclusion: No significant increase of tumor size was observed in our patients with controlled prolactin levels on DA. MRI follow-up thus appears unnecessary in patients with biologically controlled macroprolactinomas.

Introduction

Prolactinomas represent the most frequent type of pituitary adenomas with a prevalence of about 60–100 cases per million. In women, prolactinomas are usually diagnosed earlier and have a smaller size at diagnosis (microadenomas) (1). The management of microprolactinomas is consensual, based on dopamine agonists (DAs) as a

first-line treatment. Several studies suggested the possibility of DA withdrawal in patients with microprolactinoma when both prolactin level and pituitary MRI were normal for at least 2 years (2, 3, 4). Macroprolactinomas are diagnosed at a later stage, especially in men (5, 6). Delayed diagnosis exposes the patient to severe comorbidities such

as osteoporosis, infertility and altered sexual function. The differential diagnosis with a non-functioning pituitary adenoma associated with hyperprolactinemia (due to a pituitary stalk compression) is rarely an issue as the level of prolactin is highly discriminant, as shown by Karavitaki *et al.* (7). Medical treatment is still considered the first-line treatment (2, 8, 9), as DA results in both a rapid antisecretory (at least 50% decrease in prolactin) and antitumor efficacy (80% of patients present at least 25% decrease in tumor volume) (2, 10, 11, 12, 13). Transphenoidal surgery can be discussed either as a first- or second-line treatment to cure the patient and/or to decrease prolactin levels to enhance the efficacy of the DA. However, results on the possibility of DA withdrawal, as proposed in the case of microprolactinoma, are still controversial (6, 14). According to the Endocrine Society guidelines on prolactinomas (2, 13) there is still a lack of strong recommendation to propose DA withdrawal in case of macroprolactinoma. The long-term follow-up remains unclear particularly in treated patients who have normal prolactin level: as per Guidelines, 'pituitary MRI should be performed after 3 months', and further imaging follow-up should be discussed in a case-by-case approach. As a consequence, some endocrinologists do not perform anymore pituitary MRI in controlled macroprolactinoma, whereas others prefer to check for the absence of pituitary tumor growth or relapse every 1–3 years.

As prolactin levels have been shown to strongly correlate with adenoma size, in particular when the secretion is controlled by cabergoline (15, 16), we decided to determine whether systematic MRI follow-up was really helpful in patients with long-term normal prolactin levels on DA.

Patients and methods

This retrospective study involved 4 tertiary referral centers, in France (French reference center for rare pituitary diseases, La Conception hospital, Marseille; Department of Endocrinology, La Pitié hospital, Paris; Department of Endocrinology, Nancy) and in Belgium (Department of Endocrinology, Liege). All the data files of the patients followed for a macroadenoma with high prolactin levels (>100 ng/mL) in the 4 centers from 1988 to 2012 were evaluated. Patients were included firstly, if they had a diagnosis of macroprolactinoma between 1988 and 2012, i.e. if they presented an adenoma with a largest diameter greater than 10 mm, with a baseline prolactin level exceeding 100 ng/mL, without concomitant

drug intake that might lead to increased prolactin levels; second, if they had a normal prolactin level on DA and had been constantly treated by DA for at least 48 months with a regular prolactin level follow-up (at least every year during the whole duration of the treatment); and third, if they had a regular pituitary MRI follow-up (at least 2 pituitary MRI during the 48 months of follow-up). Patients who received radiotherapy or radiosurgery at any time of the management of macroprolactinoma, patients who did not have a pure prolactinoma and patients who had a giant prolactinoma (17) were not included.

Data on medical history, DA intake, characteristics of the adenoma at initial diagnosis, prolactin level and pituitary hormone evaluations were retrieved in each patient's data file. Longitudinal MRI follow-up was also noted: pituitary MRI (T1-weighted and T2-weighted coronal, axial and sagittal images before and after gadolinium injection) was performed in every center and compared with the previous ones by specialized neuroradiologists in all of the participating centers. Tumor shrinkage was defined by a decrease of at least 10% of the largest diameter of the tumor as determined on axial, frontal and coronal sections. Tumor increase was considered when any of the diameters of the tumor was found to be greater than that of the same measurement at the previous examination. When increased tumor size was reported by the local neuroradiologist, a new comparison was performed in the principal investigator's center.

For all prolactin determinations, an immunoassay was performed by the technique routinely used in each participating center: by radioimmunoassay, fluoroimmunoassay, or enzyme immunoassay. Prolactin level was considered as normal based on the normal values of each kit used.

Statistical analysis was performed with XLStat, version 2013.1.01 (Addinsoft, France). Quantitative data are presented as mean \pm s.d. Statistical comparison of quantitative data was performed by Student's *t* test or by analysis of variance (ANOVA). Statistical comparison of qualitative data was performed by chi-square test or Fisher's exact test when theoretical number of patients was inferior to 5. All statistical tests were two-tailed, and $P < 0.05$ was considered significant.

Results

A total of 115 patients with an average age at diagnosis of 36.3 ± 14.9 years were included (Table 1). There was a significant difference for the age at diagnosis between

Table 1 Characteristics of the whole cohort.

Sex ratio	63 M/52 F
Mean age at diagnostic (years \pm s.d.)	36.3 \pm 14.9
Mean initial prolactin (ng/mL)	2224 \pm 6839
Mean largest diameter at diagnostic (mm \pm s.d.)	21 \pm 10.6
Mean age at last follow-up (years \pm s.d.)	48.8 \pm 16.1
Mean length of follow up (years \pm s.d.)	9.7 \pm 5.8
Hemorrhagic changes during dopamine agonists treatment	21 (18.2%)
Empty sella turcica at final evaluation	29 (25.2%)

Sex ratio: M, male; F, female. Empty sella turcica denotes partial or complete empty sella at MRI with arachnoid herniation into the sella.

females and males (31.1 ± 12.3 vs 41.2 ± 15.3 years respectively; $P < 0.0001$).

Of the 115 patients, 11 had previously been treated by transsphenoidal surgery; 73 patients (63.5%) were receiving cabergoline, 21 (18.3%) quinagolide, and 21 (18.3%) bromocriptine at study inclusion. Initial visual field data were reported in 81% of cases: visual field was normal in 58% of them, and abnormal in the remaining 42%. Mean duration of treatment was 9.7 ± 5.8 years. During this period of treatment, 102 patients (88.7%) presented tumor shrinkage, whereas 11 (9.5%) did not present any change in the tumor size. The duration in terms of imaging was as follows: the median time from achievement of normal prolactin was 8 years (min, 4; max, 22 years); the median time from diagnosis of prolactinoma was 11 years (min 4; max, 27 years). At the last follow-up, 29 patients (25.2%) had empty sella turcica. At the end of the study, visual field remained abnormal in 12% cases, including 1 patient without improvement despite reaching normal prolactin level on medical treatment. None of our patients had a macroadenoma in contact with the optic chiasm.

Of note, 21 patients (18.3%) presented non-symptomatic hemorrhagic changes of the macroprolactinoma on MRI while on treatment: in this subgroup of patients, a statistically significant difference in sex ratio was observed (12/52 (23%) females vs 9/63 (14%) males, $P < 0.0001$). Two patients among them presented with an increase in tumor size on pituitary MRI.

The first patient was a 55-year-old man with a 30-fold increase of prolactin level above upper limit of normal (ULN), reaching 665 ng/mL, and a largest tumor size of 28 mm with suprasellar and bilateral cavernous sinus extensions. Initial visual field shows a superior temporal scotoma of the right eye. Hyperprolactinemia was rapidly normalized on cabergoline, which also induced a 10% tumor volume shrinkage. Tumor growth (+7 mm in his largest diameter) and hemorrhagic changes were observed

after 6 months of treatment (cabergoline 1 mg/week) on a systematic MRI and was confirmed by a 2nd reading. The patient was not symptomatic, prolactin remained normal (17 ng/mL) and cabergoline dose was maintained: at 3 months, MRI showed a modest decrease (−4 mm), and subsequent MRI examinations did not show any further regrowth. Visual field was normal at the end of the study.

The other patient (patient 2) was a 16-year-old woman diagnosed with a macroadenoma (largest size, 17 mm) and a 10-fold increase of prolactin above ULN (initial prolactin, 275 ng/mL) in 2012. Initial visual field was normal. Again, prolactin became rapidly normal under treatment, and cabergoline (1 mg/week) allowed an effective antitumor effect (8 mm largest size in 2013). Hemorrhagic changes and 2 mm growth of the largest diameter were reported on a systematic MRI (and was confirmed by a 2nd reading) after 24 months of treatment, whereas the patient was still controlled by the drug (prolactin level, 20 ng/mL) (Fig. 1). The patient was not symptomatic; the investigator decided to maintain the dose of cabergoline and no further regrowth was observed. Visual field was normal at the end of the study.

All of the remaining nineteen patients had stable pituitary tumor size and were asymptomatic when hemorrhagic changes were reported on MRI.

Discussion

Our results show for the first time that repeat MRI follow-up does not prove to be necessary when prolactin concentrations reach the normal range on DA (i.e. sometimes after up to 3 years after their onset as shown in our patients) in patients with macroprolactinomas. Although it was well admitted that dopamine agonists, and particularly cabergoline, were highly effective in decreasing prolactinoma volume, it was not yet known whether any close MRI follow-up was necessary in patients for whom prolactin level was normal on DA, i.e. if there was a risk of further increase in patients controlled by DA. The most recent Endocrine Society Guidelines (2011) (2) emphasized the need for a 3-month MRI after the initiation of the treatment, and the possibility of DA withdrawal in patients with at least 2 years of normal prolactin level and negative MRI. Although these criteria are applicable for most of the microprolactinoma cases, they are not systematically fulfilled for patients treated for macroprolactinoma. In our study, only 29 (25%) patients finally presented an empty sella turcica in the whole group of 101 patients who had tumor shrinkage. This means

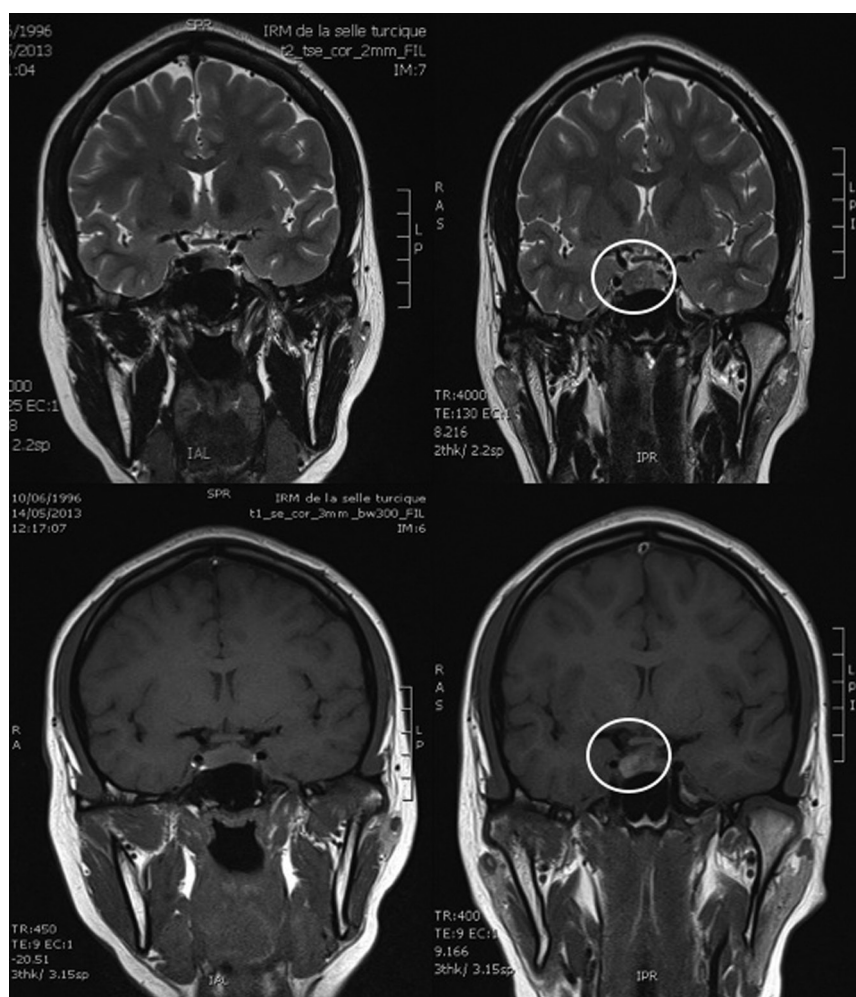


Figure 1
Pituitary MRI, coronal section, T2 weighted (Upper left: 2013; Upper right: 2014) and T1 weighted (Lower left: 2013; Lower right: 2014) of the patient #2.

that 86 patients still had a visualized prolactinoma at the end of the study, while they had normal prolactin levels. Interestingly, due to the retrospective multicentric nature of our study, investigators determined what they considered to be the optimal MRI follow-up. The management was actually quite similar, as most of the patients had MRI follow-up every 1–3 years. Our results, with no symptomatic increase in tumor size, clearly show that this MRI follow-up was useless.

Interestingly, a large proportion of our patients (18.3%) presented asymptomatic hemorrhagic changes on MRI while on dopamine agonists. Two of them had a modest increase in tumor size in this context: the patients were not symptomatic, and the changes were observed because MRI was systematically performed. Hemorrhagic changes with no clinical symptomatology cannot be considered as a pituitary apoplexy, which, by definition, requires clinical symptoms. This explains why our rate of hemorrhagic changes on MRI was actually superior to the rate of clinical apoplexy reported in the

literature (18, 19, 20). In our study, these hemorrhagic changes were likely due to the mechanism of action of DA, even if spontaneous hemorrhagic changes have also been reported in untreated macroprolactinomas. More interestingly, these hemorrhagic changes were reported because a systematic MRI follow-up was performed. As the patients were not symptomatic, and further growth was not observed despite unchanged dose of cabergoline, we conclude that the risk of asymptomatic hemorrhagic changes should not be considered as an evidence for a regular MRI follow-up.

Our results cannot be extrapolated to other types of secreting pituitary tumors. In the recent Endocrine Society Guidelines for Acromegaly (21), there is no specific mention of MRI follow-up in patients controlled by somatostatin analogs. The antitumor efficacy of these drugs is less important (33% according to a review by Mazziotti *et al.* (22); 37–51%, according to a meta-analysis by Giustina *et al.* (23)) than that for dopamine agonists in macroprolactinomas (88% in our study): moreover,

as the first-line treatment of acromegaly is surgery, tumor size is rarely an issue after surgery, in contrast with macroprolactinoma (as the first-line treatment is based on drugs, and an antitumor effect is expected to avoid surgery). Finally, Mazziotti *et al.* showed that some patients with acromegaly presented dissociated antisecretory and antitumor efficacy (22). Cushing's disease can be treated by pituitary-targeted drugs (Pasireotide or Cabergoline): in this context, however, adenoma size is usually not an issue, and recurrence after surgery is frequently associated with a negative MRI. MRI follow-up is thus not mandatory except to look for a delayed appearance of a residue as reported during the long-term use of ketoconazole or mitotane (24, 25). These drugs are however adrenal targeted, and an increased size is considered to be due to the loss of negative feedback by cortisol or to the natural history of the adenoma.

Our study has inherent limitations due to its retrospective nature. To decrease the risk of bias due to an insufficient follow-up, we only recruited patients who had at least 4-year follow-up on DA, and none of them was lost to follow-up during this period. The fact that pituitary MRI was not all read by the same radiologist could also be questioned; however, all the MR images were read by a specialized radiologist in each center, and a second reading was performed when an increased size was reported. In the latter situation, the second reading was consistent with the local neuroradiologist's interpretation. Due to the lack of surgery in most patients, we had no pathological confirmation that the hyperprolactinemia was due to a prolactinoma rather than a stalk compression; we used the criteria previously described by Karavitaki *et al.* (7). In this study based on histologically confirmed cases of prolactinoma, a prolactin level <2000 U/L (94 ng/mL) was found in 99.5% of patients with non-functioning pituitary adenoma. Our 2 patients with increased tumor size on treatment and hemorrhagic changes had prolactin levels largely above this threshold, which suggests that they were carrying a macroprolactinoma. We decided to exclude giant prolactinomas as we considered that it was a somehow different entity than classical macroprolactinomas, and this specific type of adenomas should lead to another specific study. Finally, we included patients treated by 3 different dopamine agonists. Even if our results suggest that an increase in the size of the prolactinoma is highly unlikely in patients for whom prolactin is controlled by DA, whatever the drug, a larger study on bromocriptine and quinagolide could be useful to ascertain this point.

To conclude, our study is the first to show that MRI follow-up does not seem necessary in patients with macroprolactinomas as long as prolactin levels remain normal on DA. This is of major importance as it might change the practice of endocrinologists dealing with macroprolactinomas. Asymptomatic hemorrhagic changes of the macroprolactinoma can happen during treatment, and this event can be observed when a regular MRI follow-up is performed. As these changes are usually asymptomatic and have only a modest effect on tumor size, they should not lead to a more aggressive follow-up. MRI should thus be reserved to patients presenting with clinical signs in favor of a symptomatic apoplexy or for whom prolactin levels increase despite a stable dose of previously effective dopamine agonist (6). Further studies should help determine whether repeat MRI follow-up would be necessary in patients responding to medical treatment with stable prolactin levels, though not reaching normal values.

Declaration of interest

The authors declare that there is no conflict of interest that could be perceived as prejudicing the impartiality of the research reported.

Funding

This research did not receive any specific grant from any funding agency in the public, commercial or not-for-profit sector.

References

- 1 Ciccarelli A, Daly AF & Beckers A. The epidemiology of prolactinomas. *Pituitary* 2005 **8** 3–6. (doi:10.1007/s11102-005-5079-0)
- 2 Melmed S, Casanueva FF, Hoffman AR, Kleinberg DL, Montori VM, Schlechte JA & Wass JA. Diagnosis and treatment of hyperprolactinemia: an endocrine society clinical practice guideline. *Journal of Clinical Endocrinology and Metabolism* 2011 **96** 273–288. (doi:10.1210/jc.2010-1692)
- 3 Dekkers OM, Lagro J, Burman P, Jørgensen JO, Romijn JA & Pereira AM. Recurrence of hyperprolactinemia after withdrawal of dopamine agonists: systematic review and meta-analysis. *Journal of Clinical Endocrinology and Metabolism* 2010 **95** 43–51. (doi:10.1210/jc.2009-1238)
- 4 Biswas M, Smith J, Jadon D, McEwan P, Rees DA, Evans LM, Scanlon MF & Davies JS. Long-term remission following withdrawal of dopamine agonist therapy in subjects with microprolactinomas. *Clinical Endocrinology* 2005 **63** 26–31. (doi:10.1111/j.1365-2265.2005.02293.x)
- 5 Iglesias P & Diez JJ. Macroprolactinoma: a diagnostic and therapeutic update. *QJM* 2013 **106** 495–504. (doi:10.1093/qjmed/hcs240)
- 6 Vroonen L, Jaffrain-Rea M-L, Petrossians P, Tamagno G, Chanson P, Vilar L, Borson-Chazot F, Naves LA, Brue T, Gatta B *et al.* Prolactinomas resistant to standard doses of cabergoline: a multicenter study of 92 patients. *European Journal of Endocrinology* 2012 **167** 651–662. (doi:10.1530/EJE-12-0236)
- 7 Karavitaki N, Thanabalasingham G, Shore HCA, Trifanescu R, Ansong O, Meston N, Turner HE & Wass JA. Do the limits of serum

- prolactin in disconnection hyperprolactinaemia need re-definition? A study of 226 patients with histologically verified non-functioning pituitary macroadenoma. *Clinical Endocrinology* 2006 **65** 524–529. (doi:10.1111/j.1365-2265.2006.02627.x)
- 8 Colao A & Savastano S. Medical treatment of prolactinomas. *Nature Reviews Endocrinology* 2011 **7** 267–278. (doi:10.1038/nrendo.2011.37)
 - 9 Molitch ME. Medical management of prolactin-secreting pituitary adenomas. *Pituitary* 2002 **5** 55–65. (doi:10.1023/A:1022375429083)
 - 10 Pontikides N, Krassas GE, Nikopoulou E & Kaltsas T. Cabergoline as a first-line treatment in newly diagnosed macroprolactinomas. *Pituitary* 2000 **2** 277–281. (doi:10.1023/A:1009913200542)
 - 11 Colao A, Vitale G, Cappabianca P, Briganti F, Ciccarelli A, De Rosa M, Zarrilli S & Lombardi G. Outcome of cabergoline treatment in men with prolactinoma: effects of a 24-month treatment on prolactin levels, tumor mass, recovery of pituitary function, and semen analysis. *Journal of Clinical Endocrinology and Metabolism* 2004 **89** 1704–1711. (doi:10.1210/jc.2003-030979)
 - 12 Ono M, Miki N, Kawamata T, Makino R, Amano K, Seki T, Kubo O, Hori T & Takano K. Prospective study of high-dose cabergoline treatment of prolactinomas in 150 patients. *Journal of Clinical Endocrinology and Metabolism* 2008 **93** 4721–4727. (doi:10.1210/jc.2007-2758)
 - 13 Casanueva FF, Molitch ME, Schlechte JA, Abs R, Bonert V, Bronstein MD, Brue T, Cappabianca P, Colao A & Fahlbusch R. Guidelines of the Pituitary Society for the diagnosis and management of prolactinomas. *Clinical Endocrinology* 2006 **65** 265–273. (doi:10.1111/j.1365-2265.2006.02562.x)
 - 14 Sala E, Bellaviti Buttoni P, Malchiodi E, Verrua E, Carosi G, Profka E, Rodari G, Filopanti M, Ferrante E, Spada A *et al.* Recurrence of hyperprolactinemia following dopamine agonist withdrawal and possible predictive factors of recurrence in prolactinomas. *Journal of Endocrinological Investigation* 2016 **39** 1377–1382. (doi:10.1007/s40618-016-0483-z)
 - 15 Colao A, Di Sarno A, Landi ML, Scavuzzo F, Cappabianca P, Pivonello R, Volpe R, Di Salle F, Cirillo S, Annunziato L *et al.* Macroprolactinoma shrinkage during cabergoline treatment is greater in naive patients than in patients pretreated with other dopamine agonists: a prospective study in 110 patients. *Journal of Clinical Endocrinology and Metabolism* 2000 **85** 2247–2252. (doi:10.1210/jc.85.6.2247)
 - 16 Lombardi M, Lupi I, Cosottini M, Rossi G, Manetti L, Raffaelli V, Sardella C, Martino E & Bogazzi F. Lower prolactin levels during cabergoline treatment are associated to tumor shrinkage in prolactin secreting pituitary adenoma. *Hormone and Metabolic Research* 2014 **46** 939–942. (doi:10.1055/s-0034-1389925)
 - 17 Maiter D & Delgrange E. Therapy of endocrine disease: the challenges in managing giant prolactinomas. *European Journal of Endocrinology* 2014 **170** R213–R227. (doi:10.1530/EJE-14-0013)
 - 18 Carija R & Vucina D. Frequency of pituitary tumor apoplexy during treatment of prolactinomas with dopamine agonists: a systematic review. *CNS and Neurological Disorders Drug Targets* 2012 **11** 1012–1014. (doi:10.2174/1871527311211080011)
 - 19 Möller-Goede DL, Brändle M, Landau K, Bernays RL & Schmid C. Pituitary apoplexy: re-evaluation of risk factors for bleeding into pituitary adenomas and impact on outcome. *European Journal of Endocrinology* 2011 **164** 37–43. (doi:10.1530/EJE-10-0651)
 - 20 Zhu X, Wang Y, Zhao X, Jiang C, Zhang Q, Jiang W, Wang Y, Chen H, Shou X, Zhao Y *et al.* Incidence of pituitary apoplexy and its risk factors in Chinese people: a database study of patients with pituitary adenoma. *PLoS ONE* 2015 **10** e0139088. (Disponibile sur: <http://www.ncbi.nlm.nih.gov/pmc/articles/PMC4583273/>).
 - 21 Katznelson L, Laws ER, Melmed S, Molitch ME, Murad MH, Utz A & Wass JA. Acromegaly: an endocrine society clinical practice guideline. *Journal of Clinical Endocrinology and Metabolism* 2014 **99** 3933–3951. (doi:10.1210/jc.2014-2700)
 - 22 Mazziotti G & Giustina A. Effects of lanreotide SR and Autogel on tumor mass in patients with acromegaly: a systematic review. *Pituitary* 2010 **13** 60–67. (doi:10.1007/s11102-009-0169-z)
 - 23 Giustina A, Mazziotti G, Torri V, Spinello M, Floriani I & Melmed S. Meta-analysis on the effects of octreotide on tumor mass in acromegaly. *PLoS ONE* 2012 **7** e36411. (doi:10.1371/journal.pone.0036411)
 - 24 Castinetti F, Guignat L, Giraud P, Muller M, Kamenicky P, Drui D, Caron P, Luca F, Donadille B & Vantyghem MC. Ketoconazole in Cushing's disease: is it worth a try? *Journal of Clinical Endocrinology and Metabolism* 2014 **99** 1623–1630. (doi:10.1210/jc.2013-3628)
 - 25 Bou Khalil R, Baudry C, Guignat L, Carrasco C, Guibourdenche J, Gaillard S, Bertagna X & Bertherat J. Sequential hormonal changes in 21 patients with recurrent Cushing's disease after successful pituitary surgery. *European Journal of Endocrinology* 2011 **165** 729–737. (doi:10.1530/EJE-11-0424)