



Highly efficacious, long-term, triglyceride lowering with rituximab therapy in a patient with autoimmune hypertriglyceridemia

Sophie Béliard, Mathilde Di Filippo, Gilles Kaplanski, Rene Valero

► To cite this version:

Sophie Béliard, Mathilde Di Filippo, Gilles Kaplanski, Rene Valero. Highly efficacious, long-term, triglyceride lowering with rituximab therapy in a patient with autoimmune hypertriglyceridemia. Journal of clinical lipidology, 2018, 12 (4), pp.883-887. 10.1016/j.jacl.2018.04.011 . hal-01996207

HAL Id: hal-01996207

<https://amu.hal.science/hal-01996207>

Submitted on 28 Jan 2019

HAL is a multi-disciplinary open access archive for the deposit and dissemination of scientific research documents, whether they are published or not. The documents may come from teaching and research institutions in France or abroad, or from public or private research centers.

L'archive ouverte pluridisciplinaire **HAL**, est destinée au dépôt et à la diffusion de documents scientifiques de niveau recherche, publiés ou non, émanant des établissements d'enseignement et de recherche français ou étrangers, des laboratoires publics ou privés.

Highly efficacious, long-term, triglyceride lowering with Rituximab therapy in a patient with autoimmune hypertriglyceridemia

INTRODUCTION

Hyperchylomicronemia is a subset of severe hypertriglyceridemia (>10 mmol/L) that is characterized by the abnormal persistence of chylomicrons in fasting plasma ¹. The relatively rare familial chylomicronemia syndrome (FCS) is an autosomal recessive condition that can be diagnosed either in childhood or adulthood. FCS is due to genetic deficiency of genes implicated in chylomicron and very-low-density lipoproteins (VLDL) lipolysis and clearance from the circulation: lipoprotein lipase (LPL) or related proteins such as apoC-II, apoA-V, lipase maturation factor 1 (LMF1) or glycosylphosphatidylinositol-anchored high-density lipoprotein binding protein 1 (GPIHBP1)^{1,2}. More commonly, hypertriglyceridemia is caused by a high burden of multiple risk alleles, each making a small contribution to the hypertriglyceridemic condition (ie polygenic basis of hypertriglyceridemia), interacting with acquired or environmental factors, usually presenting later in life and frequently characterized by an accumulation of both intestinally-derived chylomicrons and hepatically-derived VLDL^{3,4}. Complex interactions between environmental factors such as poor diet, obesity, alcohol intake, certain medications, pregnancy, uncontrolled diabetes on a genetically predisposed background may lead to hypertiglyceridemia⁵.

Rare cases of autoimmune severe hypertriglyceridemia due to autoantibodies against LPL^{6,7}, apoC-II⁸ and GPIHBP1⁹ have been described leading to severe hypertriglyceridemia. Immunosuppressive therapies have been used to treat this autoimmune disorder in order to restore LPL activity and decrease triglyceride levels^{6,10,11}. Here, we report the first case of a patient with autoimmune hypertriglyceridemia due to anti-LPL antibodies who was

successfully treated with rituximab, an anti-CD20-targeted biotherapy commonly used in various autoimmune diseases¹²

CASE REPORT

A 45 year-old man was referred to our nutrition department with severe hypertriglyceridemia (fasting plasma triglycerides 76 mmol/L, upper limit of normal approximately 1.5 mmol/l). He had no symptoms or prior history of acute pancreatitis and was not noted to have eruptive xanthomas, which may be seen in cases of marked hypertriglyceridemia. He was overweight, with a BMI of 29 kg/m². His past medical history was significant for genetically determined and treated, heterozygous familial hypercholesterolemia (heterozygous mutation in the exon 6 (c.829 G>A) of the low-density lipoprotein receptor (LDLR) gene), ischemic stroke at 44 years old, Grave's disease treated by neomercazole and in remission since 6 years, known positive anti-nuclear antibodies (nucleolar: 1/160). We ruled out secondary causes of hypertriglyceridemia: alcohol consumption, hypothyroidism, uncontrolled diabetes, renal disease or drugs. His severe hypertriglyceridemia was discovered during one of his LDL apheresis treatment sessions (see below) when his plasma was noted, for the first time, to be lactescent. Indeed the patient had been treated for 7 years by LDL apheresis every 3 weeks associated with rosuvastatin 20 mg/day and ezetimibe 10 mg/day for severe, heterozygous familial hypercholesterolemia with uncontrolled LDL-c >2 g/L in secondary prevention. His plasma triglyceride concentration had been regularly monitored since the beginning of the LDL apheresis treatment, revealing moderated hypertriglyceridemia between 4.5 and 9.1 mmol/L (until this occasion never > 10 mmol/l).

For this severe hypertriglyceridemia, the patient was first treated with 48 hours fasting followed by a hypocaloric, low fat, sugar-free diet. This nutritional therapy was associated with 5 plasma exchanges every 5 days leading to a substantial decrease of plasma triglyceride concentration immediately following the plasma exchanges, with nadir triglyceride concentration of 3.88 mmol/L. However, triglyceride concentration increased prior to each plasma exchange therapy (reaching 33 mmol/l immediately prior to the sixth plasma exchange). Next we tried insulin/glucose IV infusion but triglyceride levels remained elevated at 19.4 mmol/l. Then monthly plasma exchanges were performed for six months leading to triglyceride levels between 14.8 mmol/l and 52.4 mmol/l.

In order to further investigate the etiology of his severe hypertriglyceridemia, we performed a series of laboratory investigations. The fasting lipogram showed a high quantity of chylomicrons and excess of VLDL. The genetic analysis showed his *APOE* genotype as *E3/E4* and no genetic mutations (neither any polymorphisms) were found in genes coding for proteins known to be involved in triglyceride metabolism: *LPL*, *APOC2*, *APOA5*, *GPIHBP1*, *LMF1*. Considering the autoimmune background of the patient, we looked for the presence of LPL antibodies and found anti-LPL IgG antibodies by immunoblot using human LPL as ligand (figure 1).

When the potential autoimmune basis of his marked hypertriglyceridemia was confirmed and due to the lack of efficacy of conventional therapies, we elected, after obtaining informed consent from the patient, to treat him with a chimeric monoclonal antibody binding to CD20 and depleting B cells, commonly used in several autoimmune diseases: Rituximab (375 mg/m²/wk for 3 weeks). We ensured that the patient received pre-treatment vaccinations against B hepatitis and pneumococcus. Plasma triglyceride concentration

declined dramatically from 27 mmol/L pretreatment to 1.9 mmol/L after three infusions, in parallel with a decrease of CD19⁺ B lymphocytes (108 to 2/mm³) (figure 2). Anti-LPL antibodies also decreased after the first infusion of Rituximab and were barely detectable after the third infusion (figure 1). Six months after the first cycle of Rituximab infusions, triglyceride levels gradually increased again up to 44.8 mmol/L. At the same time, anti-LPL antibodies were again strongly detectable and CD19⁺ B lymphocytes increased up to 22/mm³ (figures 1 and 2). A single new infusion of Rituximab was successfully performed, inducing a marked reduction of plasma triglyceride concentration to 2 mmol/L. The patient is currently treated with Rituximab maintenance infusions when triglyceride levels exceed 10 mmol/L. Rituximab infusions are performed an average of once a year. The patient has received a total of 7 Rituximab infusions during the past 5 years.

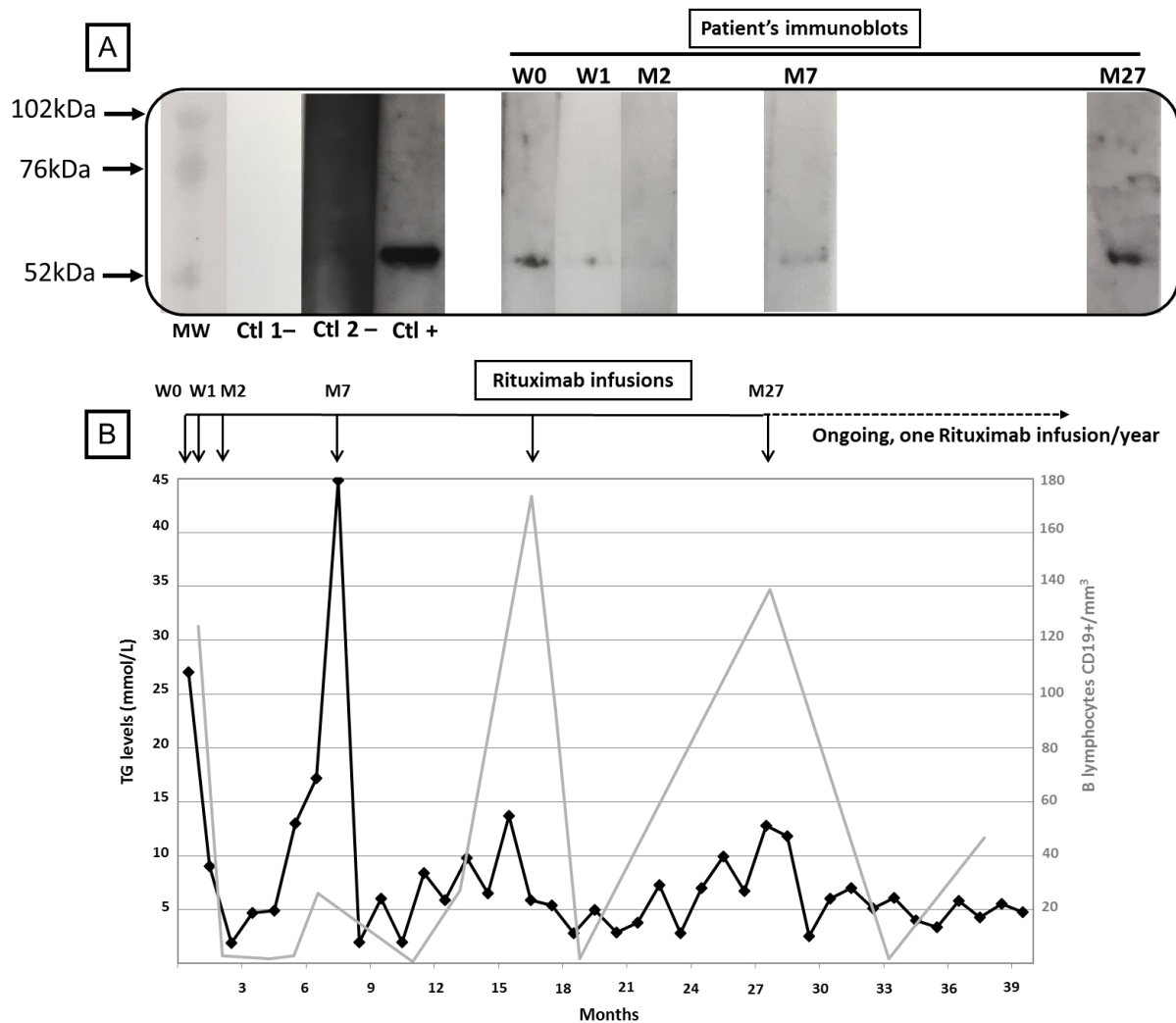


Figure 1:

Figure 1A: Anti-lipoprotein lipase (LPL) antibodies. MW: molecular weight standards, Ctl 1 - : negative control with anti-IgG, Ctl 2 - : negative control with control serum, Ctl +: positive control. Lanes W0 to M27: patient's immunoblots using bovine LPL as ligand. W0: before Rituximab first infusion, W1: one week after the first infusion, M2: two months after the first infusion, M7: seven months after the first infusion, M27: before the 6th infusion.

Figure 1B: Course of triglyceride levels (mmol/l) (black line) and B lymphocytes CD19⁺ number/mm³ (grey line) over time in response to Rituximab therapy.

PATIENT AND LABORATORY METHODS

The patient was evaluated at the Conception hospital in Marseille, France. A written informed consent was obtained for genetic testing. After the genomic DNA extraction, the coding regions and the adjacent splice sites of *LPL*, *GPIHBP1*, *APOA5*, *APOC2*, and *LMF1* were PCR-amplified using gene-specific primers. The purified PCR products were sequenced to determine the nucleotide alternations. Serum triglycerides and lipoproteins were measured enzymatically in commercial laboratories. Detection of circulating autoantibodies directed against LPL was performed after adaptation of a method previously described¹³. Briefly, bovine LPL was submitted to 4% -12% PAGE in the presence of SDS, then transferred onto a nitrocellulose membrane. After saturation of the nonspecific binding capacity, the blots were incubated for 1h15 with total plasma from a previous patient with autoimmune LPL antibodies serving as a positive control, a negative control, or from our patient at a 1:500 dilution. A mouse peroxidase-conjugated goat antihuman IgG was used as the secondary antibody at a 1:10 000 dilution. Detection was performed by a chemiluminescent method.

DISCUSSION

This is the first reported case demonstrating long term efficacy of intermittent Rituximab therapy for the management of severe, resistant, acquired, autoimmune hypertriglyceridemia due to anti-LPL antibodies. We observed rapid triglyceride-lowering efficacy of Rituximab for the management of this patient in which other triglyceride lowering therapies had failed. Efficacy of Rituximab was demonstrated by the combined decrease of plasma triglycerides concentration, anti-LPL antibody concentration and CD19+ B lymphocyte count, a few weeks after starting the biotherapy. The concomitant increase of

plasma triglycerides and anti-LPL IgG concentrations associated with blood CD19+ B lymphocytes reappearance, 7 months after the first Rituximab infusion and subsequent rapid decline in all three of these parameters following retreatment is further evidence of the efficacy of this specific, B cell-targeted therapy. Indeed, the effects of Rituximab are usually time-limited in other auto-immune diseases, between 6 and 12 months after infusion cycle completion, associated with reappearance of circulating CD19+B cells^{14 15}. Re-treatment is usually efficient and maintenance treatment is a widely used strategy in rheumatoid arthritis^{14 15}.

The first step in this disease was to diagnose the autoimmune mechanism. When a secondary cause and a genetic cause have been ruled out in a patient presenting with uncontrolled hyperchylomicronemia associated with an autoimmune background, the diagnosis of autoimmune hypertriglyceridemia must be suspected. Our patient had a history of Grave's disease and anti-nuclear antibodies were presents in his plasma confirming the autoimmune background. The first case of autoimmune hyperchylomicronemia induced by anti-LPL autoantibodies and described by Kihira in 1989 also presented with an autoimmune background with a history of Grave's disease and idiopathic thrombocytopenic purpura¹⁶. Several other cases of autoimmune hypertriglyceridemia due to anti-LPL-antibodies have been reported, and other autoimmune diseases such as Sjögren's syndrome¹¹ or idiopathic thrombocytopenic purpura⁶ are frequently (but not always) associated.

The majority of cases of autoimmune hyperlipidemia reported are due to antibodies directed against LPL. A recent case of severe hyperchylomicronemia due to anti-ApoCII antibodies was recently also described⁸. More recently, Beigneux et al. confirmed the presence of anti-GPIHBP1 antibodies in the serum of six patients who had presented with

severe hypertriglyceridemia⁹. Four of them also suffered from Lupus or Sjögren's syndrome. No cases of hypertriglyceridemia due to antibodies directed against LMF1 and APO-AV, also well known for playing an important role in the LPL activity, have been reported at this time.

Different immunosuppressive therapies for treating autoimmune hypertriglyceridemia have been described in the literature. Some authors reported therapeutic efficacy with resolution of hypertriglyceridemia with prednisone, mycophenolate mofetil and hydroxychloroquine in a young girl¹¹, or azathioprine and/or prednisolone in adults^{6,10}. However, conventional immunosuppressive treatments such as azathioprine or mycophenolate mofetil need to be used for prolonged duration and prescribed with steroids in order to be efficient. In our patient, the context of the combination of severe and uncontrolled hypertriglyceridemia and familial hypercholesterolemia lead us to avoid long duration steroid treatment. Similarly, azathioprine which is known to induce pancreatitis¹⁷ should be avoided in the setting of hypertriglyceridemia. We therefore proposed to use Rituximab, a chimeric anti-CD20 IgG1 that is now commonly used in the treatment of auto-immune diseases such as rheumatoid arthritis, idiopathic thrombopenic purpura, pemphigus or ANCA-associated vasculitis^{14,18}. Furthermore in this patient, auto-immune hypertriglyceridemia was due to specific anti-LPL antibodies. Rituximab has been reported to be very effective in auto-immune diseases that are characterized by antibodies directed against enzymes, such as cholinesterase in myasthenia gravis or ADAMTS13 in thrombotic thrombocytopenic purpura^{19,15}. Short-term tolerability of the treatment is usually excellent, with limited cases of infusion related febrile reactions or infections²⁰. Our patient however, consistently reported nausea and vomiting after each infusion during few days (which led us to limit the first cycle to 3 infusions instead of 4), without pancreatitis. At this time, the patient continues to be treated with Rituximab maintenance infusions approximately once a year, effectively controlling his hypertriglyceridemic condition by maintaining his plasma triglyceride concentration <10 mmol/L. He did not present hypogammaglobulinemia which is the most common complication in patients receiving long term Rituximab treatment. The only adverse event was, 3 years after starting Rituximab, an infectious episode on a central venous catheter which was probably favored by the immunosuppressive therapy.

To our knowledge, this is the first time that Rituximab has been used to treat autoimmune acquired hypertriglyceridemia due to anti-LPL antibodies. Twelve years ago, Blomet al. described the case of a patient with hypertriglyceridemia associated with lupus in whom the hypertriglyceridemia significantly decreased after the infusion of Rituximab prescribed for the lupus treatment²¹. The autoimmune origin of the hyperlipidemia was suspected at the time of the publication in 2005 but no anti-LPL antibodies were found at this time. Anti-GPIHBP1 antibodies were found in the serum of this patient in 2017 by the Dr Beigneux's group⁹. This same group also tested the serum of our patient and they confirmed the absence of anti-GPIHBP1 antibodies in its serum.

CONCLUSION:

We present, to our knowledge, the first case report of successful rituximab long-term treatment of autoimmune severe hypertriglyceridemia.

ACKNOWLEDGMENTS:

We thank Dr Beigneux and his group for testing the serum of our patient for the screening of anti-GPIHBP1 antibodies. We also thank Dr Marçais for the genetic testing and Dr Poullin who is in charge of the patient for LDL-apheresis.

AUTHORS CONTRIBUTIONS:

RV, PP and GK were in charge of the treatment of the patient. SB and RV contributed to the analysis and interpretation of the data and drafted the manuscript. MD contributed to the experiments (immunoblot). All authors contributed to the critical revision of the manuscript. SB and RV are the guarantors of this work and take responsibility for the integrity of the data.

DISCLOSURES: All authors have no financial conflicts of interest in relation to this submission.

BIBLIOGRAPHY:

1. Brahm AJ, Hegele RA. Chylomicronaemia--current diagnosis and future therapies. *Nat Rev Endocrinol* 2015;11:352-62.
2. Johansen CT, Hegele RA. Genetic bases of hypertriglyceridemic phenotypes. *Curr Opin Lipidol* 2011;22:247-53.
3. de Graaf J, Couture P, Sniderman A. A diagnostic algorithm for the atherogenic apolipoprotein B dyslipoproteinemias. *Nat Clin Pract Endocrinol Metab* 2008;4:608-18.
4. Hassing HC, Surendran RP, Mooij HL, Stroes ES, Nieuwdorp M, Dallinga-Thie GM. Pathophysiology of hypertriglyceridemia. *Biochim Biophys Acta* 2012;1821:826-32.
5. Miller M, Stone NJ, Ballantyne C, et al. Triglycerides and cardiovascular disease: a scientific statement from the American Heart Association. *Circulation* 2011;123:2292-333.
6. Pruneta V, Moulin P, Labrousse F, Bondon PJ, Ponsin G, Berthezene F. Characterization of a new case of autoimmune type I hyperlipidemia: long-term remission under immunosuppressive therapy. *J Clin Endocrinol Metab* 1997;82:791-6.
7. Moret M, Pruneta-Deloché V, Sassolas A, Marcais C, Moulin P. Prevalence and function of anti-lipoprotein lipase auto-antibodies in type V hyperchylomicronemia. *Atherosclerosis* 2010;208:324-7.
8. Yamamoto H, Tanaka M, Yoshiga S, Funahashi T, Shimomura I, Kihara S. Autoimmune severe hypertriglyceridemia induced by anti-apolipoprotein C-II antibody. *J Clin Endocrinol Metab* 2014;99:1525-30.
9. Beigneux AP, Miyashita K, Ploug M, et al. Autoantibodies against GPIHBP1 as a Cause of Hypertriglyceridemia. *N Engl J Med* 2017;376:1647-58.
10. Pruneta-Deloché V, Marcais C, Perrot L, et al. Combination of circulating antilipoprotein lipase (Anti-LPL) antibody and heterozygous S172 fsX179 mutation of LPL gene leading to chronic hyperchylomicronemia. *J Clin Endocrinol Metab* 2005;90:3995-8.
11. Ashraf AP, Beukelman T, Pruneta-Deloché V, Kelly DR, Garg A. Type 1 hyperlipoproteinemia and recurrent acute pancreatitis due to lipoprotein lipase antibody in a young girl with Sjogren's syndrome. *J Clin Endocrinol Metab* 2011;96:3302-7.
12. Randall KL. Rituximab in autoimmune diseases. *Aust Prescr* 2016;39:131-4.
13. Di Filippo M, Marcais C, Charriere S, et al. Post-heparin LPL activity measurement using VLDL as a substrate: a new robust method for routine assessment of plasma triglyceride lipolysis defects. *PLoS One* 2014;9:e99721.
14. Buch MH, Smolen JS, Betteridge N, et al. Updated consensus statement on the use of rituximab in patients with rheumatoid arthritis. *Ann Rheum Dis* 2011;70:909-20.
15. Froissart A, Veyradier A, Hie M, Benhamou Y, Coppo P. Rituximab in autoimmune thrombotic thrombocytopenic purpura: A success story. *Eur J Intern Med* 2015;26:659-65.
16. Kihara S, Matsuzawa Y, Kubo M, et al. Autoimmune hyperchylomicronemia. *N Engl J Med* 1989;320:1255-9.
17. Ledder O, Lemberg DA, Day AS. Thiopurine-induced pancreatitis in inflammatory bowel diseases. *Expert Rev Gastroenterol Hepatol* 2015;9:399-403.
18. Guillevin L. Rituximab for ANCA-associated vasculitides. *Clin Exp Rheumatol* 2014;32:S118-21.
19. Iorio R, Damato V, Alboini PE, Evoli A. Efficacy and safety of rituximab for myasthenia gravis: a systematic review and meta-analysis. *J Neurol* 2015;262:1115-9.
20. Kasi PM, Tawbi HA, Oddis CV, Kulkarni HS. Clinical review: Serious adverse events associated with the use of rituximab - a critical care perspective. *Crit Care* 2012;16:231.

21. Blom DJ, Marais AD. Severe hypertriglyceridemia in a patient with lupus. *Am J Med* 2005;118:443-4.