



## Long-term management of leukocyte adhesion deficiency type III without hematopoietic stem cell transplantation

Paul Saultier, Sarah Szeppetowski, Matthias Canault, Celine Falaise, Marjorie Poggi, Pierre Suchon, Vincent Barlogis, Gerard Michel, Stephane Loyau, Martine Jandrot-Perrus, et al.

### ► To cite this version:

Paul Saultier, Sarah Szeppetowski, Matthias Canault, Celine Falaise, Marjorie Poggi, et al.. Long-term management of leukocyte adhesion deficiency type III without hematopoietic stem cell transplantation. *Haematologica*, 2018, 103 (6), pp.E264-E267. 10.3324/haematol.2017.186304 . hal-02091256

**HAL Id: hal-02091256**

**<https://amu.hal.science/hal-02091256>**

Submitted on 26 May 2020

**HAL** is a multi-disciplinary open access archive for the deposit and dissemination of scientific research documents, whether they are published or not. The documents may come from teaching and research institutions in France or abroad, or from public or private research centers.

L'archive ouverte pluridisciplinaire **HAL**, est destinée au dépôt et à la diffusion de documents scientifiques de niveau recherche, publiés ou non, émanant des établissements d'enseignement et de recherche français ou étrangers, des laboratoires publics ou privés.



Distributed under a Creative Commons Attribution 4.0 International License



## Long-term management of leukocyte adhesion deficiency type III without hematopoietic stem cell transplantation

by Paul Saultier, Sarah Szepetowski, Matthias Canault, Céline Falaise, Marjorie Poggi, Pierre Suchon, Vincent Barlogis, Gérard Michel, Stéphane Loyau, Martine Jandrot-Perrus, Jean-Claude Bordet, Marie-Christine Alessi, and Hervé Chambost

Haematologica 2018 [Epub ahead of print]

*Citation: Paul Saultier, Sarah Szepetowski, Matthias Canault, Céline Falaise, Marjorie Poggi, Pierre Suchon, Vincent Barlogis, Gérard Michel, Stéphane Loyau, Martine Jandrot-Perrus, Jean-Claude Bordet, Marie-Christine Alessi, and Hervé Chambost. Long-term management of leukocyte adhesion deficiency type III without hematopoietic stem cell transplantation.*

*Haematologica. 2018; 103:xxx*

*doi:10.3324/haematol.2017.186304*

### *Publisher's Disclaimer.*

*E-publishing ahead of print is increasingly important for the rapid dissemination of science. Haematologica is, therefore, E-publishing PDF files of an early version of manuscripts that have completed a regular peer review and have been accepted for publication. E-publishing of this PDF file has been approved by the authors. After having E-published Ahead of Print, manuscripts will then undergo technical and English editing, typesetting, proof correction and be presented for the authors' final approval; the final version of the manuscript will then appear in print on a regular issue of the journal. All legal disclaimers that apply to the journal also pertain to this production process.*

# Long-term management of leukocyte adhesion deficiency type III without hematopoietic stem cell transplantation

Paul Saultier,<sup>1,2</sup> Sarah Szepetowski,<sup>1</sup> Matthias Canault,<sup>2</sup> Céline Falaise,<sup>1,3,4</sup> Marjorie Poggi,<sup>2</sup> Pierre Suchon,<sup>2,3</sup> Vincent Barlogis,<sup>1,5</sup> Gérard Michel,<sup>1,5</sup> Stéphane Loyau,<sup>6</sup> Martine Jandrot-Perrus,<sup>6</sup> Jean-Claude Bordet,<sup>7,8</sup> Marie-Christine Alessi<sup>2,3,4</sup> and Hervé Chambost<sup>1,2</sup>

<sup>1</sup>APHM, La Timone Children's Hospital, Department of pediatric hematology and oncology, Marseille, France

<sup>2</sup>Aix Marseille Univ, INSERM, INRA, C2VN, Marseille, France

<sup>3</sup>APHM, CHU Timone, Laboratory of Hematology, Marseille, France

<sup>4</sup>APHM, CHU Timone, French national reference center for inherited platelet disorders (CRPP), Marseille, France

<sup>5</sup>APHM, La Timone Children's Hospital, French national reference center for primary immune deficiencies (CEREDIH), Marseille, France

<sup>6</sup>Laboratory of Vascular Translational Science, U1148 Institut National de la Santé et de la Recherche Médicale (INSERM), Univ Paris Diderot, Sorbonne Paris Cité, France

<sup>7</sup>HCL, Hôpital Cardiologique Louis Pradel, Unité d'Hémostase Biologique, Bron, France

<sup>8</sup>EAM 4609 Hémostase et cancer, Université Claude Bernard Lyon 1, Lyon, France

**Running head:** Leukocyte adhesion deficiency type III management

**Corresponding Author:** Paul Saultier, Department of Pediatric Hematology and Oncology, La Timone Children's Hospital, APHM and Aix Marseille Univ, 264 rue St Pierre, 13385 Marseille, France; E-mail: paul.saultier@gmail.com; phone: +33491386778; fax: +33491384989.

**Word count (main text):** 1418 words

**Table number:** 0; **Figure number:** 2; **Supplemental material:** Table, References

**Conflict of interest statement:** PSa has received support for attending scientific meetings and educational events from Baxalta-Shire, Novo Nordisk, and Pfizer. HC has received support for attending scientific meetings and honoraria (speaker fees/consultant on advisory boards) from Baxalta-Shire, Bayer Healthcare, CSL Behring, LFB, Novo Nordisk, Octapharma, Pfizer and Sobi; has been an investigator in studies sponsored by Baxter, Bayer, Biogen, CSL Behring, LFB and Octapharma; and has received research support from CSL Behring, LFB, Novo Nordisk and Octapharma (none of these relate to the present study). CF has received support for attending scientific meetings and honoraria (speaker fees/consultant on advisory boards) from Baxalta-Shire, CSL Behring, LFB, Pfizer and Sobi; has been an investigator in studies sponsored by Baxter, Bayer, Biogen, CSL Behring, LFB and Octapharma; and has received research support from CSL Behring, LFB, Novo Nordisk and Octapharma (none of these relate to the present study). The other authors have no conflict of interest to disclose. These companies had no role in the study design, the

collection or interpretation of the data, the preparation of the manuscript and the decision to submit it for publication.

**Acknowledgements:** The study was funded by the “Fondation pour la Recherche Médicale” (grant to PSA: FDM20150633607). The authors thank Laurence Panicot-Dubois and Christophe Dubois (Aix-Marseille Univ, INSERM, VRCM, Marseille, France) for the kind gift of Gly-Pro-Arg-Pro, David Gabriele for technical assistance, Sandra Moore for the revision of the paper, and the patient and his family for the participation in this study.

**Systematic review registration:** PROSPERO identifier CRD42017064092;  
PROSPERO International prospective register of systematic reviews  
<https://www.crd.york.ac.uk/PROSPERO>

## MAIN TEXT

To the Editor,

Leukocyte adhesion deficiency type III (LAD-III) is a recessive autosomal condition characterized by bleeding events and life-threatening infections. This condition is due to variations in the *FERMT3* gene (encoding the kindlin-3 protein) that impair integrin function. Less than 40 LAD-III cases have been reported.<sup>1</sup> The primary treatment for this condition is early hematopoietic stem cell transplantation (HSCT), which is however associated with severe complications and high rates of treatment-related mortality.

In 2011, our team described a patient of gypsy ethnicity carrying a novel bi-allelic *FERMT3* variant.<sup>2</sup> Herein, we discuss the long-term data regarding innovative therapeutic management of the disorder involving hemostatic and antimicrobial treatment, without HSCT. We performed a systematic literature review, which provides exhaustive data concerning complications, therapeutic strategies and prognosis of LAD-III. Furthermore, we investigated *in vitro* the effect of recombinant factor VIIa (rFVIIa) on kindlin-3-deficient platelet aggregation.

The patient was included in the study after informed written consent was obtained from his parents, in accordance with the Declaration of Helsinki. The systematic review was included in the PROSPERO international prospective register (registration number CRD42017064092). The electronic databases MEDLINE, Cochrane Library and Web of Science were included in the literature search according to the strategy described on the PROSPERO website (<http://www.crd.york.ac.uk/prospero>). The flow diagram of the systematic review is presented in Figure 1A. Thirty-four LAD-III patients were included in the review. Data from the systematic review are compiled in Figure 1B-E and Supplemental Table.

The patient presented with bleeding symptoms starting at birth, as is common in most LAD-III patients. He constantly suffered from mild to moderate mucocutaneous bleeding (petechiae, buccal hemorrhaging and epistaxis). A total of 71% of reported LAD-III cases presented with mucocutaneous bleeding, which constitutes a hallmark of the disease (Figure 1B, top). The patient's medical history involved severe bleeding episodes (traumatic penile hematoma, hematuria and traumatic bleeding of the tongue). The patient's ISTH-BAT bleeding score was 13. The LAD-III bleeding phenotype may be more severe than that of Glanzmann thrombasthenia.<sup>3</sup> Indeed, intracranial hemorrhage, gastrointestinal bleeding and pulmonary bleeding occurred in 15%, 15% and 6% of reported patients, respectively (Figure

1B, top). The management of these complications remains very challenging, as illustrated by the reports of three deaths due to bleeding complications.

Erythrocyte and platelet transfusions were performed in >90% of LAD-III cases, constituting a pivotal treatment for bleeding events (Figure 1B, bottom). Some patients received >20 erythrocyte transfusions and >50 platelet transfusions per year.<sup>4</sup> Our patient received only one platelet transfusion, which may be due to the use of rFVIIa as a first-line treatment for severe bleeding as well as a preventive treatment in high-risk situations (off-label use). Ten doses of 90-120 µg/kg rFVIIa were successfully administered to treat penile hematoma (one dose), tongue bleeding (five doses) and three preventive circumstances (one to two doses; dental surgeries). The first dose of rFVIIa was administered at 17 months of age. This treatment has not been previously reported in LAD-III cases. Tranexamic acid was used in 8% of reported cases. Our patient received this antifibrinolytic drug as a long-term prophylaxis, which has never been reported in LAD-III cases. This treatment has been used from the age of three at a dose of 25 mg/kg/day divided in three oral doses.

The clinical efficacy of rFVIIa to control bleeding in Glanzmann thrombasthenia patients has been clearly demonstrated,<sup>3</sup> although the mechanism of action of rFVIIa in this disease is not fully understood. Direct activation of Factor X on the platelet surface by rFVIIa may improve local thrombin generation.<sup>5</sup> Furthermore, rFVIIa treatment restores aggregation of Glanzmann thrombasthenia platelets *in vitro*.<sup>6</sup> We observed rFVIIa-mediated platelet aggregation for αIIbβ3-inhibited platelets and kindlin-3-deficient platelets (Figures 2AB), thereby possibly explaining the clinical efficacy of rFVIIa in LAD-III patients. Platelet aggregates were analyzed using transmission electron microscopy (Figure 2C). The interplatelet distance within rFVIIa-mediated aggregates of kindlin-3-deficient platelets was increased and less regular compared with that of control platelet aggregates (mean ± standard deviation 359 ± 373 nm, n=31 *versus* 59 ± 18 nm, n=59, respectively; n referring to the number of interplatelet distances measured). However, interplatelet close interactions (<100 nm) were also observed.

Platelet glycoprotein VI (GPVI) has recently been shown to bind to immobilized fibrin.<sup>7</sup> We hypothesized that GPVI-fibrin interactions may mediate the aggregation of kindlin-3-deficient platelets in our model. In the presence of a fibrin generating system (prothrombin complex concentrate, fibrinogen, rFVIIa), washed kindlin-3-deficient platelets fully aggregated in response to collagen or TRAP-6 (Figure 2B). This aggregation was impeded if fibrin polymerization was inhibited by the Gly-Pro-Arg-Pro peptide (Figure 2B). Blocking GPVI using the anti-GPVI Fab fragment 9O12<sup>8</sup> inhibited collagen-induced aggregation of the kindlin-3-deficient platelets, which correlates with the fact that GPVI represents the receptor

for platelet activation by collagen. However, the anti-GPVI Fab fragment 9O12, which was shown to inhibit GPVI-fibrin interactions,<sup>7</sup> did not prevent rFVIIa-mediated aggregation upon TRAP-6 stimulation. This suggests that GPVI-fibrin interactions were not involved in this response (Figure 2B). Dependence on rFVIIa-mediated fibrin generation may explain the increased aggregation lag-time compared with that observed upon activation of normal platelets (Figure 2AB). The use of collagen in this model probably results in collagen/thrombin double stimulation, which is known to strongly promote the formation of procoagulant platelets.<sup>9</sup> This may explain the difference in aggregation lag-time following collagen or TRAP-6 stimulation (Figure 2B).

Regarding infections, the patient was treated with trimethoprim/sulfamethoxazole at five months of age for probable *Pneumocystis jirovecii* pneumonia, as reported for other LAD-III patients. Thereafter, preventive antibiotics (trimethoprim/sulfamethoxazole and itraconazole) were initiated. The patient did not suffer from additional severe infections, even after itraconazole was discontinued at 3.5 years of age. Severe bacterial infections have been reported in LAD-III patients, including bacteremias (47%), pulmonary infections (47%), omphalitis (12%) and other soft tissue infections (32%) (Figure 1C, top). Furthermore, fungal infections, such as *Aspergillus* pneumonia and *Fusarium* sepsis have been reported. Few authors have reported the use of bacterial or fungal prophylaxis in LAD-III patients (22%) (Figure 1C, bottom). Although these data emphasize individual variability, systematic antifungal and antibacterial prophylaxis should be considered for LAD-III patients.

With sustained hypogammaglobulinemia, our patient required long-term gamma globulin replacement at 10 months of age. This treatment has rarely been reported in the literature (17%; Figure 1C, bottom). Gamma globulin levels were only evaluated in six cases. Two of these patients suffered from hypogammaglobulinemia.<sup>10,11</sup> These patients presented no severe infection while undergoing gamma globulin replacement, and one patient developed severe sepsis a few weeks after discontinuing replacement therapy.<sup>11</sup> In some patients, a defect in the adaptive immune response is thus an aspect of LAD-III, which suggests that kindlin-3 plays a role in B-cell biology.<sup>11</sup> Gamma globulin levels must be systematically evaluated, as long-term gamma globulin replacement may effectively prevent severe infections in LAD-III patients with hypogammaglobulinemia.

HSCT has been reported as the only curative therapy for LAD-III.<sup>1</sup> Indeed, several groups have reported long-term, disease-free LAD-III survivors after HSCT. This therapy option has been applied in 68% of cases (Figure 1D). Furthermore, the reported survival of non-transplanted patients is relatively low (55%) (Figure 1E). Lethality is probably underestimated due to cases who died prior to diagnosis. Indeed, several siblings of LAD-III

patients have died during the first months of life due to bleeding or infection. However, the mortality rate was 22% among transplanted patients (Figures 1D-E), and all deaths were directly due to HSCT complications. Severe complications were reported in 48% of cases, e.g., graft failure, sinusoidal obstruction syndrome or graft-versus-host disease (Figure 1D). Notably, 32% of patients had osteopetrosis, which likely compromises engraftment. Therefore, balancing of the risk of rejection and toxicity is challenging in this disease. This may explain that the appropriate type of conditioning regimen remains controversial (Figure 1D). Furthermore, LAD-III survivors treated without HSCT have been reported.<sup>12</sup> Regarding our patient, optimized treatment to manage bleeding and infection without HSCT appears to be an efficient therapeutic approach, with no significant adverse events. Indeed, this strategy led to a favorable outcome after a 10-year follow-up. Our patient exhibits normal growth and development and has integrated into a standard school system. This approach may also apply to other LAD-III patients.

This study provides new insights regarding the complications, management and prognosis of LAD-III. Notably, we report the first effective use of rFVIIa to treat and prevent bleeding in a LAD-III patient, which was supported by *in vitro* platelet ultrastructural and aggregation data. Our results suggest that rFVIIa activity is platelet activation-dependent, fibrin-dependent and independent of GPVI-fibrin interaction. International registry and cohort studies should be implemented to identify prognostic factors that could guide therapeutic strategies for LAD-III.



## REFERENCES

1. Etzioni A. Leukocyte adhesion deficiency III - when integrins activation fails. *J Clin Immunol.* 2014;34(8):900–903.
2. Robert P, Canault M, Farnarier C, et al. A novel leukocyte adhesion deficiency III variant: kindlin-3 deficiency results in integrin- and nonintegrin-related defects in different steps of leukocyte adhesion. *J Immunol.* 2011;186(9):5273–5283.
3. Poon M-C, Di Minno G, d'Oiron R, Zotz R. New Insights Into the Treatment of Glanzmann Thrombasthenia. *Transfus Med Rev.* 2016;30(2):92–99.
4. Kuijpers TW, van Bruggen R, Kamerbeek N, et al. Natural history and early diagnosis of LAD-1/variant syndrome. *Blood.* 2007;109(8):3529–3537.
5. Di Minno G. Eptacog alfa activated: a recombinant product to treat rare congenital bleeding disorders. *Blood Rev.* 2015;29 Suppl 1:S26-33.
6. Lisman T, Adelmeijer J, Heijnen HFG, de Groot PG. Recombinant factor VIIa restores aggregation of  $\alpha$ IIb $\beta$ 3-deficient platelets via tissue factor-independent fibrin generation. *Blood.* 2004;103(5):1720–1727.
7. Mammadova-Bach E, Ollivier V, Loyau S, et al. Platelet glycoprotein VI binds to polymerized fibrin and promotes thrombin generation. *Blood.* 2015;126(5):683–691.
8. Lecut C, Feeney LA, Kingsbury G, et al. Human platelet glycoprotein VI function is antagonized by monoclonal antibody-derived Fab fragments. *J Thromb Haemost.* 2003;1(12):2653–2662.
9. Agbani EO, Poole AW. Procoagulant platelets: generation, function, and therapeutic targeting in thrombosis. *Blood.* 2017;130(20):2171–2179.
10. Kuijpers TW, Van Lier RA, Hamann D, et al. Leukocyte adhesion deficiency type 1 (LAD-1)/variant. A novel immunodeficiency syndrome characterized by dysfunctional  $\beta$ 2 integrins. *J Clin Invest.* 1997;100(7):1725–1733.
11. Suratannon N, Yeetong P, Srichomthong C, et al. Adaptive immune defects in a patient with leukocyte adhesion deficiency type III with a novel mutation in FERMT3. *Pediatr Allergy Immunol.* 2016;27(2):214–217.
12. Kuijpers TW, van de Vijver E, Weterman MAJ, et al. LAD-1/variant syndrome is caused by mutations in FERMT3. *Blood.* 2009;113(19):4740–4746.
13. Chiesa R, Veys P. Reduced-intensity conditioning for allogeneic stem cell transplant

in primary immune deficiencies. *Expert Rev Clin Immunol*. 2012;8(3):255–266; quiz 267.

14. Saultier P, Vidal L, Canault M, et al. Macrothrombocytopenia and dense granule deficiency associated with FLI1 variants: ultrastructural and pathogenic features. *Haematologica*. 2017;102(6):1006–1016.

## FIGURE LEGENDS

### **Figure 1: Systematic review of leukocyte adhesion deficiency type III complications, treatments and outcome**

(A) Flow diagram of the systematic review. The number of records included or excluded is indicated at each step. Twenty-seven records reporting data from 34 patients were ultimately included in the analysis. The previous report from our group<sup>2</sup> was excluded.

(B) Prevalence of bleeding events with regards to topography (top; n=27) and associated treatments (bottom; n=24) among LAD-III patients reported in the literature. Frequency of vaginal bleeding was calculated for female patients. CNS: central nervous system; TF: transfusion.

(C) Prevalence of infections with regards to topography / type (top; n=27) and associated treatments (bottom; n=18) among LAD-III patients reported in the literature. ATB: antibiotics; Ig: immunoglobulin.

(D): Description of LAD-III patients treated with hematopoietic stem cell transplantation (HSCT). The percentage of patients treated with HSCT was calculated for all reported LAD-III patients (n=34). The frequency of conditioning regimens and HSCT-related complications was calculated for transplanted patients (n=23). Some patients underwent two HSCTs with different types of conditioning regimen, thus the sum of the conditioning regimen frequencies exceeds 100%. Conditioning regimen intensity was defined as previously reported.<sup>13</sup>

(E) Survival rate of reported LAD-III patients. HSCT: hematopoietic stem cell transplantation.

### **Figure 2: rFVIIa-mediated aggregation of $\alpha$ IIb $\beta$ 3-inhibited and kindlin-3-deficient platelets**

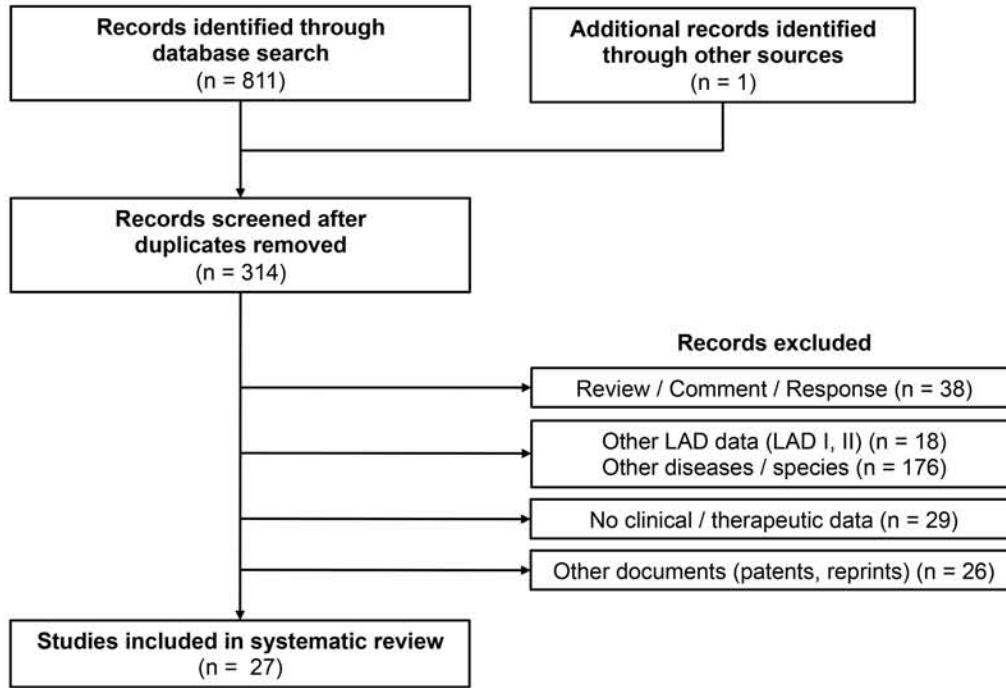
(A-B) Light transmission aggregometry. Washed platelets were prepared from citrated blood samples obtained by venipuncture and resuspended in Hepes-Tyrode buffer at pH 7.4 (final platelet concentration =  $200 \times 10^9$ /l). The platelet suspension was recalcified with 3 mM  $\text{CaCl}_2$ . Aggregation of (A) control platelets pretreated for 10 minutes with the  $\alpha$ IIb $\beta$ 3 inhibitor tirofiban (50  $\mu$ g/ml; Sigma-Aldrich) and (B) kindlin-3-deficient platelets was monitored using a PAP-8E aggregometer (Bio/Data Corporation) at 37°C, with a stir speed of 900 rpm. The platelets were activated with 4  $\mu$ g/mL collagen (Hyphen) or 20  $\mu$ M TRAP-6 (SFLLRN; PolyPeptide Group). The effect of (1) a fibrin-generating system consisting of fibrinogen (fg; 50  $\mu$ g/ml), factor II (0.13 UI/ml), factor VII (0.07 UI/ml), factor IX (0.16 UI/ml), factor X (0.18 UI/ml), and recombinant factor VIIa (rFVIIa; 1.2  $\mu$ g/ml; Novoseven®, NovoNordisk), (2) the

fibrin polymerization inhibitor Gly-Pro-Arg-Pro (GPRP; 5 mM; AnaSpec/Eurogentec), and (3) the anti-GPVI blocking Fab 9O12<sup>8</sup> (30 µg/ml) was evaluated. Factors II, VII, IX, and X – *i.e.*, prothrombin complex concentrate (PCC) – were prepared using a Confidex® solution (CSL Behring GmbH). The data are representative of two independent experiments for the patient's platelets and four independent experiments for the tirofiban-treated control platelets.

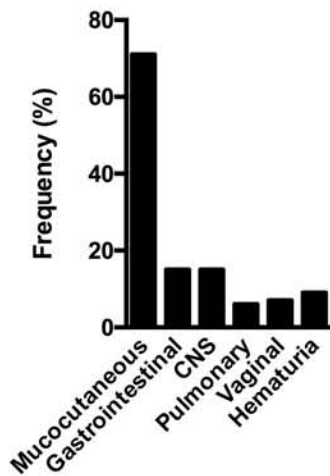
(C) Representative transmission electron microscopy images of platelet aggregate ultrathin sections. The aggregates of control platelets (left) and kindlin-3-deficient platelets in the presence of the fibrin-generating system described above (right) were fixed and prepared as previously described<sup>14</sup> after a 10 min stimulation with 4 µg/ml collagen. Images of the same field acquired at higher magnification are shown at the bottom. Scale bar, 1 µm (top) and 200 nm (bottom).

# FIGURE 1

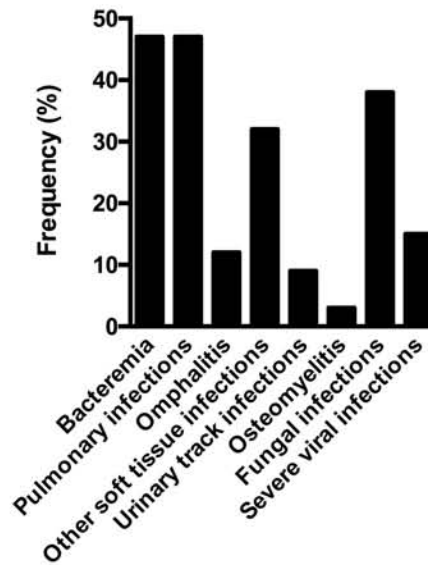
A



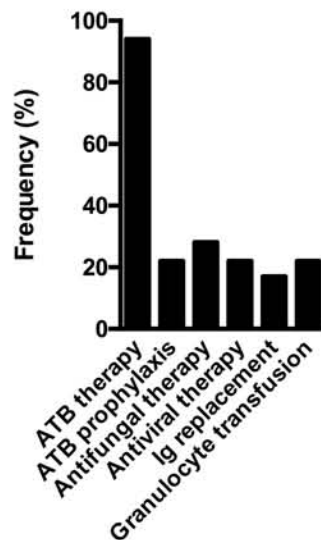
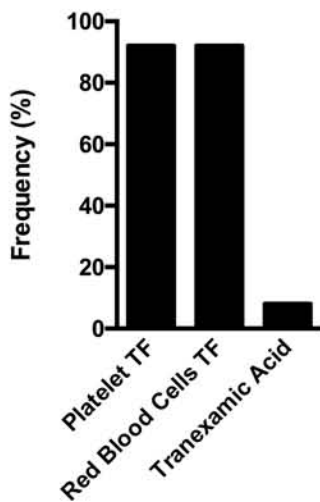
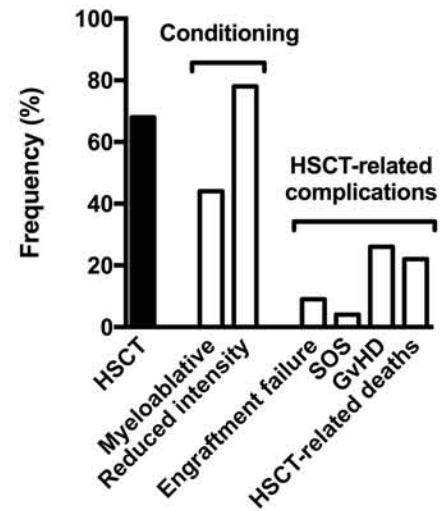
B



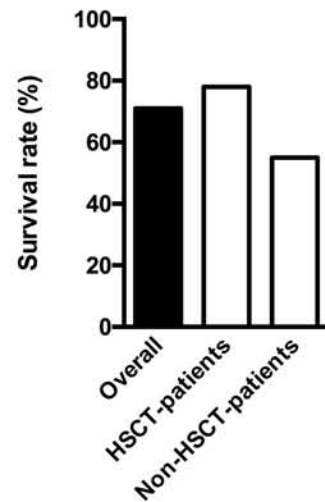
C



D



E



## **SUPPLEMENTAL MATERIAL**

**Long-term management of leukocyte adhesion deficiency  
type III without hematopoietic stem cell transplantation**

Supplemental Table: Complications, therapeutic management and outcome of previously reported LAD-III patients

FERMT3 alteration	Gender (M / F)	HSCT  Age at conditioning, donor, conditioning regimen, complications, outcome	Bleeding complications		Infections		Survival (Y / N)	Supplemental references
			Description	Management	Description	Management		
c.48G>A p.W16X	M	Yes	Mucosal bleedings, CNS bleeding	RBC TF	Lymphadenitis, Recurrent infections	NA	Y	1
c.48G>A p.W16X	F	Yes	Mucocutaneous bleedings, CNS bleeding	Platelet TF	Recurrent infections	NA	Y	1
c.687G>A p.W229X	NA	Yes, †	Moderate bleeding tendency	NA	NA	NA	N	2,3
c.687G>A p.W229X	M	6 years, MMRD, RIC (alemtuzumab/Bu/Flu/Mel), †	Mucocutaneous bleedings Life-threatening bleedings	Platelet and RBC TF, Tranexamic acid	Omphalitis, Recurrent soft tissue infections, Bacteremia (Staphylococcus), Osteomyelitis, CMV viremia, Disseminated fungal infection (†)	ATB therapy, granulocyte TF, surgical debridement, ATB prophylaxis, ganciclovir, antifungal treatment	N	4,5
c.687G>A p.W229X	F	21 and 51 months, MMUUCBD 5/6 and MMUD 8/10, MAC (Bu/Cy/ATG) and RIC (Flu/Treo/TT/ATG), GvHD (Grade IV), good outcome	Mucocutaneous bleedings, Gastrointestinal bleedings	Platelet and RBC TF	Pneumocystis pulmonary infection, Recurrent CMV viremia	ATB therapy, ganciclovir	Y	5
c.687G>A p.W229X	M	12 months, MRD, RIC (Flu/Treo/TT/Alemtuzumab), no GvHD, good outcome	Cutaneous bleeding	Platelet and RBC TF	Recurrent pulmonary infections, Cellulitis, Gangrene, Deep-seated abscesses, Intestinal infection, Bacteremia (Pseudomonas, Klebsiella)	ATB therapy, amputation	Y	5
c.[922G>A;1287delT] p.[G308R;E430Rfs*3]	F	8 months, MMUUCBD 5/6, RIC (Flu/Bu/Cy/rabbit ATG), skin and gut GvHD (Grade III), good outcome	Gastrointestinal bleedings, Traumatic hematomas	Platelet and RBC TF	Necrotizing enterocolitis, RSV pulmonary infection, Urinary tract infection (E. coli, P. aeruginosa), Bacteremia (S. aureus)	ATB therapy, Partial bowel resection	Y	6,7

c.1324-1G>A splice variant	F	No HSCT	Joint bleedings (knee, elbow), Mucocutaneous bleedings	NA	Pulmonary infection, Otitis media, Arthritis, Recurrent CMV viremia	ATB therapy, ganciclovir	Y	8
c.1438C>T p.Q480X	M	8 months, MRD, Good outcome	Mucosal bleedings	NA	Omphalitis, Urachal duct cyst infection, Soft tissue infection, Bacteremia (Staphylococcus), Pneumocystis pulmonary infection, Oral candidiasis; Urinary tract infection	ATB therapy	Y	9–11
c.1438C>T p.Q480X	M	15 weeks, Good outcome	Cutaneous bleedings	NA	Oral candidiasis, Omphalitis, Bacteremia (Staphylococcus)	ATB therapy	Y	9
c.1537C>T p.R513X	F	MUD, GvHD (†)	Gastrointestinal bleedings, Hematuria, Mucosal bleedings	Platelet and RBC TF	Recurrent pulmonary infections, Bacteremia (†)	NA	N	12
c.1537C>T p.R513X	M	Good outcome	Gastrointestinal bleedings, Hematuria, Mucosal bleedings	Platelet and RBC TF	Recurrent pulmonary infections	NA	Y	12
c.1537C>T p.R513X	M	No HSCT	Severe mucocutaneous bleedings	Platelet and RBC TF	Bacteremia and fungemia	NA	N	13
c.1537C>T p.R513X	M	No HSCT	Cutaneous bleedings, Pulmonary hemorrhage (†)	NA	Recurrent pulmonary infections, Intestinal infection, Bacteremia (P. aeruginosa), Oral candidiasis	NA	N	13,14
c.1537C>T p.R513X	F	3.5 years, MMRD x 2, RIC (Flu/Mel/TT/rabbit ATG) and MAC (Bu/Cy/TLNI), no engraftment	Severe bleeding tendency	Platelet and RBC TF	Recurrent pulmonary infections, buccal infection (P. aeruginosa)	ATB therapy	Y	13–15
c.1537C>T p.R513X	F	No HSCT	Mucocutaneous bleedings, Pulmonary hemorrhage (†)	Platelet and RBC TF	Pulmonary infections, Otitis media, Bacteremia (†)	ATB therapy	N	13,14
c.1537C>T p.R513X	M	13 years, MUD, †	Mucosal bleedings, Postoperative thoracic bleeding	Platelet and RBC TF	Perianal abscesses, Pulmonary infection, Bacteremia (P. aeruginosa), Mediastinal mass	ATB therapy, ATB prophylaxis, Ig replacement therapy, granulocyte TF, voriconazole	N	2,3,16,17



c.1537C>T p.R513X	M	4 years, Good outcome	Severe bleeding tendency, Cutaneous bleedings	Platelet and RBC TF	Perianal abscesses, Candidiasis	NA	Y	2,3,16
c.1537C>T p.R513X	M	1 year, Sinusoidal obstruction syndrome (†)	Severe bleeding tendency, CNS bleeding	Platelet and RBC TF	Pulmonary aspergillosis	Amphotericin B	N	2,3,16
c.1537C>T p.R513X	M	No HSCT	Severe bleeding tendency	Platelet and RBC TF	Omphalitis, Fungemia (F. oxysporum), Soft tissue infection, Bacteremia (P. aeruginosa (†)	ATB therapy, Amphotericin B, flucytosine, granulocytes TF	N	2,3,16
c.1537C>T p.R513X	M	No HSCT	Severe traumatic epistaxis (†)	Platelet and RBC TF	Bacterial infections	NA	N	2,3,16
c.1537C>T p.R513X	M	Yes	Severe bleeding tendency, CNS bleeding	Platelet and RBC TF	Omphalitis, Perianal abscesses, CMV infections	ATB therapy	Y	2,3,16
c.1537C>T p.R513X	F	No HSCT	Moderate bleeding tendency	Platelet and RBC TF	NA	NA	Y	2,3,16
c.1537C>T p.R513X	F	No HSCT	Moderate bleeding tendency	Platelet and RBC TF	NA	NA	Y	2,3,16
c.1537C>T p.R513X	M	No HSCT	Moderate bleeding tendency Mucocutaneous bleedings	Platelet and RBC TF	Sepsis, CMV infection	NA	Y	2,3,16
c.1537C>T p.R513X	F	No HSCT	Hematuria, Gastrointestinal bleedings, Cutaneous bleedings	RBC TF	Cutaneous ulcers, Cellulitis, Bacteremia	NA	Y	18
c.1597C>T p.Q533X	F	5 months, MUD, RIC (Bu/Flu/TT), no GvHD, Good outcome	Gastrointestinal bleedings, Vaginal bleedings	Platelet and RBC TF	Presumed amnion infection	ATB therapy	Y	19

c.1683-2A>G splice variant	F	Yes, Good outcome	Antenatal CNS bleeding, Cutaneous bleeding	Platelet TF, Tranexamic acid	Recurrent infections, Cutaneous ulcers	ATB therapy, ATB prophylaxis	Y	7,18,20
c.1729C>T p.R577X	M	7 years, MUD, MAC (Bu/Flu/Cy/Rabbit ATG), GvHD (grade II), Good outcome	Buccal bleedings, Epistaxis	Platelet and RBC TF	Recurrent infections, Pulmonary infections, bacteremia ( <i>S. pneumoniae</i> )	ATB therapy	Y	21
c.1729C>T p.R577X	M	3.5 years, MUD, MAC (Bu/Flu/Cy), Chronic lung GvHD (grade I)	Mucosal bleedings	NA	Recurrent infection, Pulmonary infections	ATB therapy	Y	21
c.1729C>T p.R577X	NA	No HSCT	Moderate bleeding tendency	NA	NA	NA	Y	2,3
c.1796A>C p.Q599P	F	No HSCT	Mild bleeding tendency	NA	Recurrent pulmonary infections ( <i>A. baumannii</i> , <i>S. mitis</i> , <i>E. coli</i> ), Bacteremia ( <i>P. aeruginosa</i> ), Mucocutaneous candidiasis, Intestinal infection ( <i>Salmonella</i> ), Urinary tract infection	ATB therapy, Ig replacement therapy	Y	22–24
c.1802delA p.N601Mfs*?	F	2 months, MUUCBD, RIC (Flu/Treo/TT/rabbit ATG), Liver and skin GvHD (grade III)	Cutaneous bleedings	NA	Pulmonary candidiasis, CMV viremia	NA	Y	25
c.1857delG p.A620Pfs*?	NA	14 months, MUUCBD, good outcome	Cutaneous bleeding, Epistaxis	NA	Pneumocystis pulmonary infection	NA	Y	26,27

*FERMT3* variants were numbered according to the reference sequence NM\_178443. The conditioning regimen intensity was defined as previously described.<sup>28</sup> The affected families are separated using dotted lines. Abbreviations: †: death; ATB: antibiotic; ATG: anti-thymocyte globulin; Bu: busulfan; CMV: cytomegalovirus; CNS: central nervous system; Cy: cyclophosphamide; F: female; Flu: fludarabine; GvHD: graft versus host disease; HSCT: hematopoietic stem cell transplantation; Ig: immunoglobulin; M: male; MAC: myeloablative conditioning; Mel: melphalan; MMRD: mismatched related donor; MMUUCBD mismatched unrelated umbilical cord blood donor; MRD: matched related donor; MUD: matched unrelated donor; MUUCBD: matched unrelated umbilical cord blood donor; N: no; NA: not available; RBC: red blood cells; RIC: reduced intensity conditioning; RSV: respiratory syncytial virus; TF: infusion; TLNI: total lymph node irradiation; Treo: treosulfan; TT thiotepa; Y: yes.

## SUPPLEMENTAL REFERENCES

1. Malinin NL, Zhang L, Choi J, et al. A point mutation in KINDLIN3 ablates activation of three integrin subfamilies in humans. *Nat Med*. 2009;15(3):313–318.
2. Kuijpers TW, van de Vijver E, Weterman MAJ, et al. LAD-1/variant syndrome is caused by mutations in FERMT3. *Blood*. 2009;113(19):4740–4746.
3. van de Vijver E, Weterman MA, de Boer M, et al. Leukocyte Adhesion Deficiency-1/variant syndrome is caused by mutations in FERMT3. *Eur J Clin Invest*. 2009;39:32–32.
4. Alon R, Aker M, Feigelson S, et al. A novel genetic leukocyte adhesion deficiency in subsecond triggering of integrin avidity by endothelial chemokines results in impaired leukocyte arrest on vascular endothelium under shear flow. *Blood*. 2003;101(11):4437–4445.
5. Stepensky PY, Wolach B, Gavrieli R, et al. Leukocyte adhesion deficiency type III: clinical features and treatment with stem cell transplantation. *J Pediatr Hematol Oncol*. 2015;37(4):264–268.
6. Sabnis H, Kirpalani A, Horan J, et al. Leukocyte adhesion deficiency-III in an African-American patient. *Pediatr Blood Cancer*. 2010;55(1):180–182.
7. McDowall A, Svensson L, Stanley P, et al. Two mutations in the KINDLIN3 gene of a new leukocyte adhesion deficiency III patient reveal distinct effects on leukocyte function in vitro. *Blood*. 2010;115(23):4834–4842.
8. Meller J, Malinin NL, Panigrahi S, et al. Novel aspects of Kindlin-3 function in humans based on a new case of leukocyte adhesion deficiency III. *J Thromb Haemost JTH*. 2012;10(7):1397–1408.
9. Harris ES, Smith TL, Springett GM, Weyrich AS, Zimmerman GA. Leukocyte adhesion deficiency-I variant syndrome (LAD-Iv, LAD-III): molecular characterization of the defect in an index family. *Am J Hematol*. 2012;87(3):311–313.
10. Harris ES, Shigeoka AO, Li W, et al. A novel syndrome of variant leukocyte adhesion deficiency involving defects in adhesion mediated by beta1 and beta2 integrins. *Blood*. 2001;97(3):767–776.
11. Harris ES, Li W, Shigeoka AO, Zimmerman GA, Lorant DE. A new leukocyte-adhesion deficiency (LAD) variant characterized by defective signaling of beta 1 and beta 2 integrins in an Epstein-Barr (EB) virus-transformed cell line. *Am J Respir Crit Care Med*. 1999;159(3):A264–A264.

12. Aygun D, Nepesov S, Gershoni R, Camcioglu Y. Leukocyte Adhesion Deficiency III: Report of Two Siblings. *Pediatr Neonatol*. 2017;58(1):99–100.
13. Kilic SS, Etzioni A. The clinical spectrum of leukocyte adhesion deficiency (LAD) III due to defective CalDAG-GEF1. *J Clin Immunol*. 2009;29(1):117–122.
14. Pasvolsky R, Feigelson SW, Kilic SS, et al. A LAD-III syndrome is associated with defective expression of the Rap-1 activator CalDAG-GEF1 in lymphocytes, neutrophils, and platelets. *J Exp Med*. 2007;204(7):1571–1582.
15. Elhasid R, Kilic SS, Ben-Arush M, Etzioni A, Rowe JM. Prompt recovery of recipient hematopoiesis after two consecutive haploidentical peripheral blood SCTs in a child with leukocyte adhesion defect III syndrome. *Bone Marrow Transplant*. 2010;45(2):413–414.
16. Kuijpers TW, Van Lier RA, Hamann D, et al. Leukocyte adhesion deficiency type 1 (LAD-1)/variant. A novel immunodeficiency syndrome characterized by dysfunctional beta2 integrins. *J Clin Invest*. 1997;100(7):1725–1733.
17. Kuijpers TW, van Bruggen R, Kamerbeek N, et al. Natural history and early diagnosis of LAD-1/variant syndrome. *Blood*. 2007;109(8):3529–3537.
18. Svensson L, Howarth K, McDowall A, et al. Leukocyte adhesion deficiency-III is caused by mutations in KINDLIN3 affecting integrin activation. *Nat Med*. 2009;15(3):306–312.
19. Crazzolara R, Maurer K, Schulze H, Zieger B, Zustin J, Schulz AS. A new mutation in the KINDLIN-3 gene ablates integrin-dependent leukocyte, platelet, and osteoclast function in a patient with leukocyte adhesion deficiency-III. *Pediatr Blood Cancer*. 2015;62(9):1677–1679.
20. McDowall A, Inwald D, Leitinger B, et al. A novel form of integrin dysfunction involving beta1, beta2, and beta3 integrins. *J Clin Invest*. 2003;111(1):51–60.
21. Jurk K, Schulz AS, Kehrel BE, et al. Novel integrin-dependent platelet malfunction in siblings with leukocyte adhesion deficiency-III (LAD-III) caused by a point mutation in FERMT3. *Thromb Haemost*. 2010;103(5):1053–1064.
22. Suratannon N, Yeetong P, Srichomthong C, et al. Adaptive immune defects in a patient with leukocyte adhesion deficiency type III with a novel mutation in FERMT3. *Pediatr Allergy Immunol Off Publ Eur Soc Pediatr Allergy Immunol*. 2016;27(2):214–217.
23. Suratannon N, Yeetong P, Srichomthong C, et al. Improvement of Recurrent Infections after IVIG Supplementation in a Patient with Leukocyte Adhesion Deficiency III with a Novel

Missense Mutation in FERMT3. *J Allergy Clin Immunol*. 2015;135(2):AB183-AB183.

24. Suratannon N, Chatchatee P, Yeetong P, et al. Adaptive Immune defect in a rare phagocytic disorder: leukocyte adhesion deficiency III with a novel missense mutation in FERMT3. *Allergy*. 2014;69:500–500.

25. Palagano E, Slatter MA, Uva P, et al. Hematopoietic stem cell transplantation corrects osteopetrosis in a child carrying a novel homozygous mutation in the FERMT3 gene. *Bone*. 2017;97:126–129.

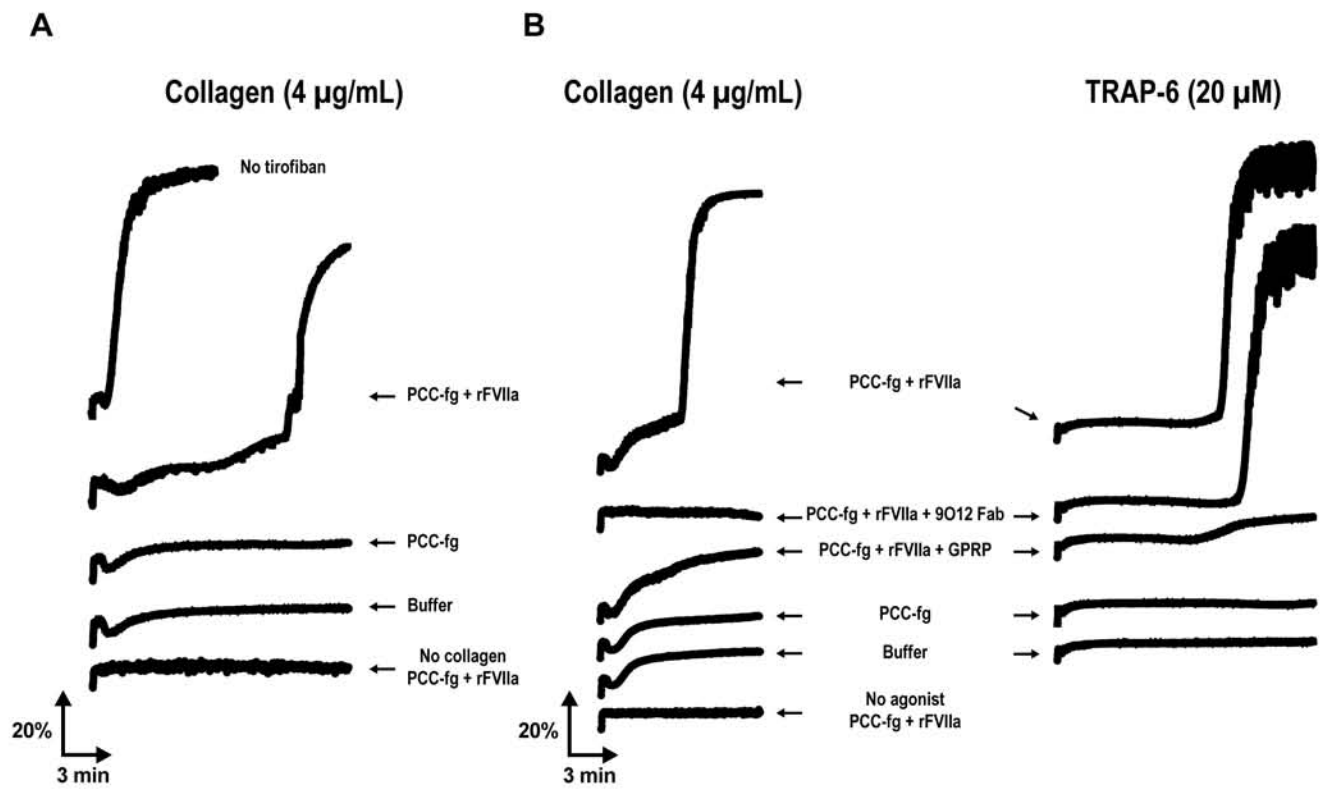
26. Taaning E, Shah B, Schejbel L, et al. Leukocyte adhesion deficiency type III due to a novel mutation in the FERMT3 gene. *Vox Sang*. 2012;103:270–270.

27. Shah B, Taaning E, Schejbel L, et al. Leukocyte adhesion deficiency type III due to a novel mutation in the FERMT3 Gene. *J Clin Immunol*. 2012;32:215–216.

28. Chiesa R, Veys P. Reduced-intensity conditioning for allogeneic stem cell transplant in primary immune deficiencies. *Expert Rev Clin Immunol*. 2012;8(3):255–266; quiz 267.

29. Robert P, Canault M, Farnarier C, et al. A novel leukocyte adhesion deficiency III variant: kindlin-3 deficiency results in integrin- and nonintegrin-related defects in different steps of leukocyte adhesion. *J Immunol Baltim Md 1950*. 2011;186(9):5273–5283.

# FIGURE 2



**C**

