



HAL
open science

3D Dynamic MRI for Pelvis Observation - a First Step

Augustin C. Ogier, Stanislas Rapacchi, Arnaud Le Troter, Marc-Emmanuel Bellemare

► **To cite this version:**

Augustin C. Ogier, Stanislas Rapacchi, Arnaud Le Troter, Marc-Emmanuel Bellemare. 3D Dynamic MRI for Pelvis Observation - a First Step. IEEE 16th International Symposium on Biomedical Imaging (ISBI), Apr 2019, Venise (IT), Italy. pp.1801-1804, 10.1109/ISBI.2019.8759589 . hal-02195177

HAL Id: hal-02195177

<https://amu.hal.science/hal-02195177v1>

Submitted on 15 Apr 2024

HAL is a multi-disciplinary open access archive for the deposit and dissemination of scientific research documents, whether they are published or not. The documents may come from teaching and research institutions in France or abroad, or from public or private research centers.

L'archive ouverte pluridisciplinaire **HAL**, est destinée au dépôt et à la diffusion de documents scientifiques de niveau recherche, publiés ou non, émanant des établissements d'enseignement et de recherche français ou étrangers, des laboratoires publics ou privés.

3D DYNAMIC MRI FOR PELVIS OBSERVATION - A FIRST STEP.

Augustin C. Ogier¹, Stanislas Rapacchi², Marc-Emmanuel Bellemare¹

¹ Aix Marseille Univ, Université de Toulon, CNRS, LIS, Marseille, France

² Aix Marseille Univ, CNRS, CRMBM, UMR 7339, Marseille, France

ABSTRACT

In the context of pelvic floor diseases understanding we advocate a process to observe the bladder over time in 3D. Thanks to multiplanar MRI acquisitions and adequate volume constructions, several volumes per seconds can show a bladder undergoing deformations under strain conditions. To our knowledge it is the first time such observation is performed. In addition we propose some deformation estimation clues that may be useful to pathology characterization and clinical diagnosis.

Index Terms— Dynamic MRI, Pelvic floor, Deformation quantification

1. INTRODUCTION

Pelvic floor disorders affect approximately 50% of women older than 50 years [1]. They are mainly due to weakening of the muscles and ligaments of the pelvic floor leading to mechanical dysfunction of the pelvic organs support structures. Symptoms range from abnormal descent of pelvic organs, urinary and bowel incontinence, sexual dysfunction to pelvic organ prolapse [1]. MRI has emerged as one of the most attractive methods for pelvic imaging thanks to its non-invasive nature, its high-spatial resolution, good contrast between soft tissues and lack of ionizing radiation [2].

Dynamic MRI examinations are considered essential [3] for the investigation of the pelvic area and guidelines emphasize their importance to identify pathological organs deformations. Current clinical practice involves 2D dynamic MRI acquiring a single sagittal plane during an exercise. Beyond visual inspection by a radiologist, one quantitative measure is to evaluate the inclination between the pubis and the sacrum [4]. Nevertheless, these approaches remain limited to assess the volume deformations. Due to speed in MRI acquisition, 3D imaging have been exclusive to static MRI so far, to observe anatomy at rest during instructed apnea. However, only the understanding of three-dimensional deformations can provide full assessment of the pelvic organs mechanical defects.

Recent advances in MRI hardware and MRI reconstruction techniques now allow faster acquisition, potentially enabling dynamic 3D MRI. The advent of high-density coil arrays, which multiply the signal receivers, and the advanced

image reconstruction from under-sampled data such as parallel imaging [5] and more recently Compressed Sensing [6] allow for fast and robust dynamic MRI with minimal compromises. The implementation of such novel acquisitions in the pelvic application field is of great importance. These new acquisitions should help better classify pathologies and automate clinical analysis by studying pelvic organs in their entirety and their 3D complexity with high contrast and good resolution.

Making use of state-of-the art acceleration of the MRI, we demonstrate the first quantitative assessment of 3D deformations of a pelvic organ under exercise load. The process was divided into four steps: dynamic acquisition, temporal reconstruction, organs segmentation, quantification and visualization of deformations. To our knowledge, this study is the first to propose a dynamic 3D observation of the pelvic region as well as a dynamic 3D representation of the organs. In addition, we propose an estimation of the deformation magnitudes undergone by the organs. The computation of the Jacobian determinants of a non linear transformation model gives clues for the interpretation of the different loading phases of the pelvic organs. The mapping of these values on the organ surfaces allows a high level representation of the deformation locations.

2. METHOD

2.1. Data Acquisition

Three-dimensional MRI can be acquired either using slab excitations or multi-planar slice excitations. Due to imperfection of slab excitations, oversampling of the targeted volume is required and hampers acquisition speed. Thus, rapid acquisition of multi-planar 2D slices was preferred to follow the motion of the pelvis organs. In this study, we sought to harness the potential of high-density coil arrays to accelerate MRI using parallel imaging techniques. Non-linear reconstruction techniques, such as Compressed Sensing [6], were not considered in this preliminary work to maintain reliability of the imaging information. The sliding-window temporal-GRAPPA (TGRAPPA) technique [7] allowed for a significant acceleration. In TGRAPPA, consecutive images share low-frequency information to provide basis for image reconstruction. Assuming the pelvic deformations do not modify the

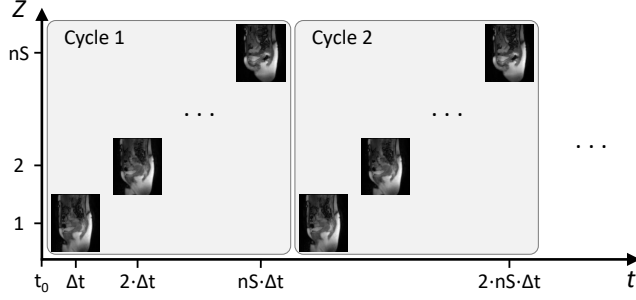


Fig. 1. Configuration of the acquisition planes of the dynamic sequence.

low-frequency image information within the range of a second (i.e. low-resolution images do not vary within a second), the full coverage of the pelvic region was guaranteed using up to 12 slices within a second. Another interesting feature of this multi-planar setup is the T1-recovery of the signal between images, which boosts signal-to-noise ratio and offers a reinforced contrast between tissues and liquids.

The number, location and orientation of the planes determine the spatial and temporal resolution of the data. To allow for clinical-grade signal-to-noise ratio and spatial resolution, the duration of a single image plane acquisition approximated 100ms. This leads to a tradeoff between spatial and temporal coverage. A high number of spatial slices means an increase in spatial coverage, but with a significant time lag between the first and the last spatial slice of a 3D cycle. On the contrary, with fewer slices, difference in time between the farthest slices is shortened at the expense of the spatial coverage.

In this study, the configuration of the 3D dynamic cycles corresponded to multiple parallel sagittal 2D slices covering the body from the right lateral side to the left lateral side (Fig.1). The number and thickness of slices was defined according to the corpulence of each subject to cover the pelvic area as much as possible. Let nS be the number of slices needed for the spatial coverage. Each successive spatial slice was temporally separated by the acquisition time of one slice Δt (i.e. the sequence-specific repetition time [TR]). The time-frame of a 3D cycle was equal to TR times nS .

Let $(S_{acq})^t$ be the set of the acquired slices and N its cardinal. Each dynamic 2D MRI slice S_i^t was acquired at a time $t = t_0 + k \cdot \Delta t$ with a plane index i such as $i = k \bmod nS$. Let nC be the number of cycle. Hence, the number of acquired slices, N , is such as $N = nS \cdot nC$.

These dynamic 3D MRI were acquired with combined T₁/T₂ weighted balanced steady-state free precession sequences (T₁/T₂W bSSFP). In comparison to the T₂W sequence, usually used for pelvic area MRI, the T₁/T₂W bSSFP sequence allows an optimal acquisition speed combined with a strong contrast between body fluids and the different pelvic organs tissues: uterus in dark gray, bladder in white (hyper-signal) and rectum and viscera (dark gray tissue and light gray content).

2.2. Temporal Reconstruction

Due to the acquisition protocol, spatial coverage evolves with each time step Δt . Thus some slices are missing to get the full volume information. To recover more realistic volume datasets, the missing slices were interpolated at each time step to create an isotropic sampled set. Each of the slices $(S_{int})_i^t$ has been linearly interpolated between the previous acquired slice and the subsequent acquired slices within the (S_{acq}) set (1). We advocate such an interpolating scheme since the movement of pelvic organs is assumed to be rather slow as regards the slice acquisition time.

$$(S_{int})_i^t = \frac{t'' - t}{nS} \cdot (S_{acq})^{t'} + \frac{t - t'}{nS} \cdot (S_{acq})^{t''}$$

with

$$t' = \left(t \operatorname{div} nS \right) \cdot nS + i$$

$$t'' = \left((t \operatorname{div} nS) + 1 \right) \cdot nS + i$$
(1)

Obtaining dynamic slices S was thereby generalized as the union of the slices actually acquired with the linearly interpolated slices (2).

$$S = \{S_{acq}\} \cup \{S_{int}\}$$
(2)

2.3. Data Segmentation

Automatic segmentation of major pelvic organs is a challenging task. Only the bladder is natively contrasted. The contours of the rectum, uterus and vagina may be difficult to define because of MRI properties similar to those of surrounding soft tissues. To enhance the contrast, extraneous liquid can be inserted in the pelvic cavities. As a result, the segmentation process of pelvic organs has mainly been performed manually in studies that have focused on pelvic dynamics [8]. Automatic segmentation methods have already been proposed for the segmentation of the pelvic organs from 2D dynamic T₂W MRI images [9].

Overall, the segmentation of 3D dynamic MRI datasets stands as a novel challenge due to the combined non-rigid deformations and the natively depleted contrasts. In this study, a semi-automatic method was therefore proposed for the segmentation of pelvic organs to balance between segmentation accuracy and user's dedication. The manual segmentation of only a few slices at regular intervals initiated the segmentation. The contours were then automatically propagated over all the remaining times according to a previously described method [10]. The manually segmented sections are denoted $S_i^{k \cdot p}$, with $k \in \mathbb{N}$, and p the time step of the mandatory manual segmentation. The manual segmentation of the slices $S_i^{k \cdot p}$ and $S_i^{(k+1) \cdot p}$ allowed the automatic segmentation of the $p - 1$ slices of the interval. Time window of a cycle being short, pelvic organs deformations are limited during the

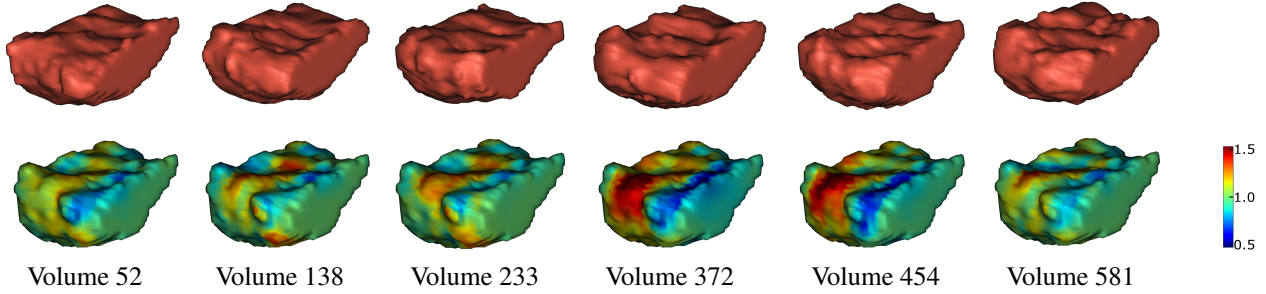


Fig. 2. Anterior view of a bladder at distinct loading phases during a forced breathing exercise (up). Representation of Jacobian determinant at each point estimated through the deformations undergone by these volumes in relation to a reference volume (down). Volumes 52, 372 and 454 represent dilatation phases while volumes 138, 233 and 581 illustrate compression phases.

refreshing of a given spatial slice. The segmentation propagation process combining different approaches of non-linear registration allowed therefore a accurate follow-up of these subtle three-dimensional deformations.

From these segmentations, the volume V^t of a pelvic organ has been reconstructed as the union of the organ segmentation on the nS different sagittal slices (3). The volume construction process started when all the slices S_i^t were available, i.e. $t \geq nS \cdot \Delta t$.

$$V^t = \bigcup_{i=1}^{nS} S_i^t \quad \forall t(nS \cdot \Delta t \leq t \leq (nC - 1) \cdot nS \cdot \Delta t) \quad (3)$$

2.4. Data Analysis

Although the visualization of the 3D volumes generated through times at a high speed rate could be of utmost importance for clinicians, quantitative information would facilitate the interpretation. For this purpose, the local deformations at each point of the volumes V^t were analysed.

Non-linear diffeomorphic registrations were performed between each volume V^t and the first volume acquired, fixed as reference. From the resulting transformation fields, Jacobian determinants were computed at every voxel. Jacobian determinant, which is a unitless measure defined by the ratio of volumes, allowed to estimate the quantity of deformations undergone by the organs on the all surface tissue area. All Jacobian maps were displayed on the reference volume.

Since pelvic organs are incompressible, it is assumed that any transformation on a volume induces a reverse transformation. As a result, the analysis of Jacobian determinants focused on their distribution via their standard deviation and the value of extreme percentiles. The deformations of each volume V^t , estimated in relation to the reference volume, were therefore summarized with quantitative values. These values could be correlated with the different phases of organ during loading exercises.

Furthermore, Jacobian determinants were also meaningful to analyze the dynamic at every voxel of the organ. For this

purpose, a 3D Jacobian map was created for which each voxel represented the standard deviation over times of the Jacobian determinants estimated across all the reconstructed volumes at that point. This map was then plot on the reference volume and provided a high-level representation of the location of the most deformed tissue areas during an loading exercise.

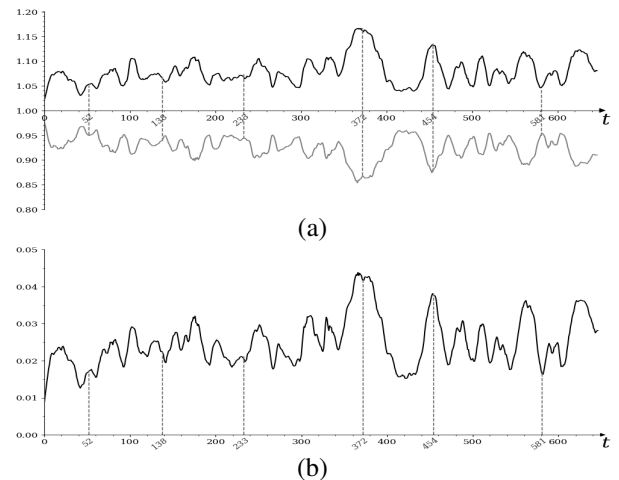


Fig. 3. Values of the 1st (gray), the 99th (black) percentile (b) and the standard deviation (c) of Jacobian determinants computed for each volume of an example subject. Specific values refer to volumes previously recognized as load phases of compression or dilatation.

3. EXPERIMENTS

3.1. Datasets

Pelvis areas of four healthy participants (two women) were imaging with a 1.5T MRI scanner (MAGNETOM Avanto, Siemens AG, Healthcare Sector, Erlangen, Germany) using a spine/phased array coil combination. T₁/T₂W bSSFP images (TR: 109 ms, echo time: 1.25 ms, flip angle: 52°, field of view: 299 x 350 mm², pixel size: 1.8 x 1.8 mm², slice thickness: 4 mm, 10 - 12 slices depending on subject corpulence) were recording during a 1:20-minute forced breathing

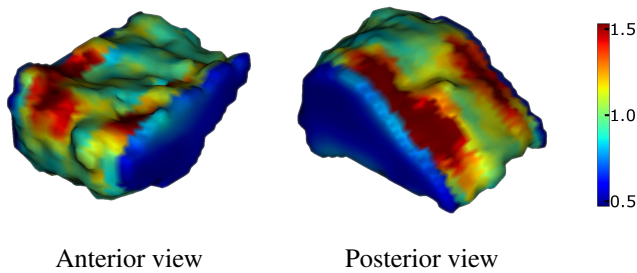


Fig. 4. Standard deviation over times of the Jacobian determinants computed at every points across all the reconstructed volumes and plotted on a reference volume.

exercise. During this exercise, the subject alternately inspired and expired at maximum capacity. Subjects were also asked to increase the pelvic pressure to the maximum inspiration and contrary to contract the pelvic floor during the expiration. These actions increased the intra-abdominal pressure, causing deformities of the pelvic organs.

The study was approved by the local human research committee and was conducted in conformity with the Declaration of Helsinki (version October 2013).

Since no extraneous liquids was injected into pelvic cavities in this study, only the segmentation of the bladder was performed and the analysis focused exclusively on this organ. For each subject 650 volumes of bladder were generated at a rate of about 9 volumes per second.

3.2. Results

Meshes representation of different phases of compression and dilation of a bladder are shown in Fig.2. Although the movements during the forced breathing exercise were intense, it is challenging to visually identify these phases with non ill subjects. In light of these meshes, the corresponding Jacobian determinants calculated at each point and plotted on the reference volume allow a better quantification and localization of the deformations undergone by the organ. Therefore, the temporal analysis of the standard deviation of the Jacobian determinants on each volume allows to quickly identify the phases of organ loads as well as their amplitudes (Fig.3).

The analysis of the percentiles of the Jacobian determinants distribution authenticates that all the transformations undergone by an organ have been captured. This is of utmost importance given that a perfect coverage of pelvic organs with 3D dynamic MRI could be challenging. A symmetry between extreme percentiles ensure the incompressibility of the bladder and further investigations could lead to associate the opposite deformations.

Finally, the Jacobian map depicting the standard deviation at each point over times provided a high level representation of quantitative information, with the location of tissue areas with the highest elongation rates (Fig.4).

4. CONCLUSION

We proposed a complete process to visualize, for the first time in its 3D complexity, a pelvic organ during deformation due to strain conditions. This first successful result was presented with a bladder for the sake of simplicity. In addition to simple visualization, we have shown that quantitative information can be extracted on current deformations. The deformations were locally estimated and plotted on a reference surface to locate tissues that are likely to deform significantly. This process might lead to a systemic characterization of the deformation of pelvic organs which would be of utmost importance to feed a computer aided diagnosis system and further a surgical planning system. This work in progress is going toward the observation of the other main organs.

5. REFERENCES

- [1] Yan Mee Law and Julia R Fielding, "Mri of pelvic floor dysfunction," *American Journal of Roentgenology*, vol. 191, no. 6.supplement, pp. S45–S53, 2008.
- [2] Courtney A Woodfield, Saravanan Krishnamoorthy, Brittany S Hampton, and Jeffrey M Brody, "Imaging pelvic floor disorders: trend toward comprehensive mri," *American Journal of Roentgenology*, vol. 194, no. 6, pp. 1640–1649, 2010.
- [3] Rania Farouk El Sayed, Celine D Alt, Francesca Maccioni, Matthias Meissnitzer, Gabriele Masselli, Lucia Manganaro, Valeria Vinci, Dominik Weishaupt, ESUR, ESGAR Pelvic Floor Working Group, et al., "Magnetic resonance imaging of pelvic floor dysfunction-joint recommendations of the esur and esgar pelvic floor working group," *European radiology*, vol. 27, no. 5, pp. 2067–2085, 2017.
- [4] Maria Chiara Colaiacomo, Gabriele Masselli, Elisabetta Poletti, Silvia Lanciotti, Emanuele Casciani, Luca Bertini, and Gianfranco Gualdi, "Dynamic mr imaging of the pelvic floor: a pictorial review," *Radiographics*, vol. 29, no. 3, pp. e35, 2009.
- [5] Mark A Griswold, Peter M Jakob, Robin M Heidemann, Mathias Nittka, Vladimir Jellus, Jianmin Wang, Berthold Kiefer, and Axel Haase, "Generalized autocalibrating partially parallel acquisitions (grappa)," *Magnetic Resonance in Medicine: An Official Journal of the International Society for Magnetic Resonance in Medicine*, vol. 47, no. 6, pp. 1202–1210, 2002.
- [6] Michael Lustig, David Donoho, and John M Pauly, "Sparse mri: The application of compressed sensing for rapid mr imaging," *Magnetic Resonance in Medicine: An Official Journal of the International Society for Magnetic Resonance in Medicine*, vol. 58, no. 6, pp. 1182–1195, 2007.
- [7] Felix A Breuer, Peter Kellman, Mark A Griswold, and Peter M Jakob, "Dynamic autocalibrated parallel imaging using temporal grappa (tgrappa)," *Magnetic Resonance in Medicine: An Official Journal of the International Society for Magnetic Resonance in Medicine*, vol. 53, no. 4, pp. 981–985, 2005.
- [8] Mehdi Rahim, Marc-Emmanuel Bellemare, Rémy Bulot, and Nicolas Pirró, "A diffeomorphic mapping based characterization of temporal sequences: application to the pelvic organ dynamics assessment," *Journal of mathematical imaging and vision*, vol. 47, no. 1-2, pp. 151–164, 2013.
- [9] Rafael Namias, M-E Bellemare, Mehdi Rahim, and Nicolas Pirró, "Uterus segmentation in dynamic mri using lbp texture descriptors," in *Medical Imaging 2014: Image Processing*. International Society for Optics and Photonics, 2014, vol. 9034, p. 90343W.
- [10] Augustin Ogier, Michael Sdika, Alexandre Foure, Arnaud Le Troter, and David Bendahan, "Individual muscle segmentation in mr images: A 3d propagation through 2d non-linear registration approaches," in *Engineering in Medicine and Biology Society (EMBC), 2017 39th Annual International Conference of the IEEE*. IEEE, 2017, pp. 317–320.