



HAL
open science

Maxillary fungus balls due to *Fusarium proliferatum*

T. Radulesco, A. Varoquaux, S. Ranque, P. Dessi, J. Michel, C. Cassagne

► **To cite this version:**

T. Radulesco, A. Varoquaux, S. Ranque, P. Dessi, J. Michel, et al.. Maxillary fungus balls due to *Fusarium proliferatum*. *Journal of Medical Mycology = Journal de Mycologie Médicale*, 2019, 29 (1), pp.59-61. 10.1016/j.mycmed.2019.01.008 . hal-02263665

HAL Id: hal-02263665

<https://amu.hal.science/hal-02263665v1>

Submitted on 3 Apr 2020

HAL is a multi-disciplinary open access archive for the deposit and dissemination of scientific research documents, whether they are published or not. The documents may come from teaching and research institutions in France or abroad, or from public or private research centers.

L'archive ouverte pluridisciplinaire **HAL**, est destinée au dépôt et à la diffusion de documents scientifiques de niveau recherche, publiés ou non, émanant des établissements d'enseignement et de recherche français ou étrangers, des laboratoires publics ou privés.

Case report

Maxillary fungus balls due to *Fusarium proliferatum*

T. Radulesco^{a,b,*}, A. Varoquaux^c, S. Ranque^d, P. Dessi^a, J. Michel^{a,b}, C. Cassagne^d

^a Department of Oto-Rhino-Laryngology and Head and Neck Surgery, La Conception University Hospital, Assistance publique-hôpitaux de Marseille, 13385 Marseille cedex, France

^b CNRS, IUSTI, Aix-Marseille Université, 13453 Marseille, France

^c Department of Radiology, La Conception University Hospital, Assistance publique-hôpitaux de Marseille, 13385 Marseille cedex, France

^d SSA, IRD, IHU – Méditerranée Infection, VITROME, Aix-Marseille Université, AP-HM, 13005 Marseille, France

Keywords:

Fungi
Surgery
Mycoses
Chronic sinusitis
Paranasal sinus
Maxillary disease

ABSTRACT

Fungus ball is the most common form of non-invasive fungal rhinosinusitis. *Aspergillus fumigatus* (between 44.8% and 75%) and *Aspergillus flavus* (14%) are the two most common species recovered. However, recent advances in mycological laboratory methods have enhanced the detection and identification of fungi within fungus balls. *Fusarium* species, sometimes recovered from other forms of fungal rhinosinusitis such as allergic fungal rhinosinusitis or acute invasive fungal rhinosinusitis, are poorly associated with sinonasal fungus ball. Here, we describe two further cases of a fungus ball due to *Fusarium proliferatum* and provide the first description of this fungal pathogen with a fungus ball of odontogenic origin. These case reports demonstrate that uncommon fungal species such as *Fusarium* spp. might be underestimated as agents of sinus cavity fungus ball. Enhanced mycological detection and diagnostic techniques might give rise, in the near future, to the emergence of new or rare fungal species associated with this clinical entity.

1. Introduction

Fungus ball paranasal sinusitis, defined as a compact mass of fungal hyphae and cellular debris in a sinus cavity, is the most common form of non-invasive fungal rhinosinusitis. Fungus balls are mostly unilateral and affect preferentially the maxillary sinus, followed by the sphenoid sinus and, in very rare cases, the ethmoid and frontal sinuses [1]. Immunocompetent middle-aged or elderly women are most commonly affected by fungus balls, that seem to develop mostly in the smallest sinus [2].

Another important risk factor of developing maxillary sinusitis is the presence of endodontic material, particularly containing zinc oxide, accidentally pushed into the sinus during endodontic treatment [3]. The most common species of fungus recovered from fungus balls are *A. fumigatus* and, rarely, other species of *Aspergillus*, *Penicillium*, *Chrysosporium* and *Scedosporium* [4]. *Fusarium* species, sometimes recovered from other forms of fungal rhinosinusitis such as allergic fungal rhinosinusitis or acute invasive fungal rhinosinusitis, are poorly associated with sinonasal

fungus ball. To our knowledge, only one case study reported a fungus ball type pan-sinusitis due to *F. proliferatum* [5]. Here, we describe two further cases of a fungus ball due to *F. proliferatum* and provide the first description of this fungal pathogen with a fungus ball of odontogenic origin.

2. Case report 1 (medical history)

A 52-year-old woman was referred to our Department of Oto-Rhino-Laryngology and Head and Neck Surgery for left maxillary sinusitis fortuitously discovered on CT-scan performed for dysphagia. Her medical history was insignificant except for esophagitis and a 30-pack-year smoking history. She had no functional impairment: no pain, no rhinorrhea, no nasal bleeding and no anosmia. Laboratory values were all normal. No mucosal or sub-mucosal abnormal enhancement was depicted on CT-scanner. Incidentally, CT-scanner demonstrated a dental filling migrated from the mesial root of 27 to the left maxillary sinus cavity (Fig. 1). Soft tissue thickening within the maxillary sinus floor was observed. MRI, performed for soft thickening characterization, showed a 14 mm maxillary sinus floor lesion with intermediate signal on T1wi and signal void on T2wi consistent with a fungus ball. Endoscopic surgery was performed on the left maxilla to remove all involved mucosa and maxillary sinus content.

* Corresponding author. Department of Oto-Rhino-Laryngology and Head and Neck Surgery, La Conception University Hospital, Assistance publique-hôpitaux de Marseille, 147, boulevard Baille, 13005 Marseille, France.

E-mail address: thomas.radulesco@ap-hm.fr (T. Radulesco).

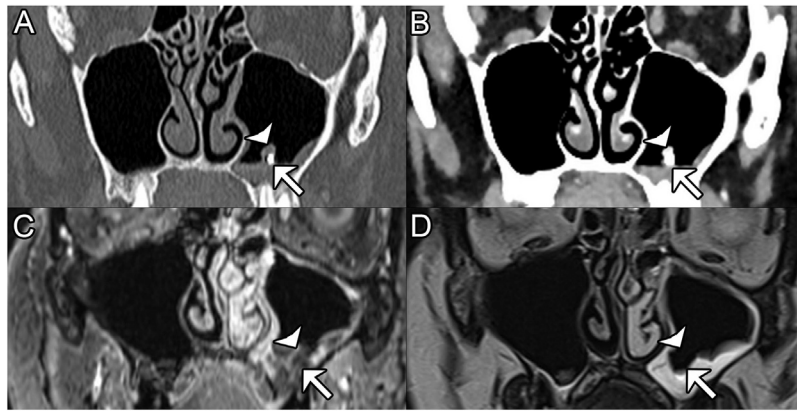


Fig. 1. Just visible maxillary fungus ball: coregistered CT-scanner (A, B) and T1 with gadolinium (C, axial 3DVibe gradient recall after 2D reslicing in the coronal plane coregistered with T2), T2wi (D). Metal dental filling (arrow) migrated into the maxillary sinus cavity is shown on CT using bone windowing in bone algorithm. Very small-sized fungus ball (arrow head) is seen as a dense lesion above the dental amalgam on CT with soft tissue algorithm and windowing (B), containing secretions in signal void T2 (D) compared to T1 (C). Note the absence of micro-concretion seen on CT with bone algorithm (A).

Multiple biopsied fragments were collected during surgery for histopathological examination and microbiological analysis.

3. Case report 2 (medical history)

A 58-year-old woman was referred to our Department for left maxillary sinusitis discovered on CT-scanner performed for chronic rhinosinusitis with crusts. She has no significant medical history except a coronary artery disease (2 stents), dyslipidemia and obesity. She had no other functional impairment than nasal obstruction. Standard laboratory values were all normal. CT-scanner found a sinus filling and MRI a signal void on T2wi.

In both cases, all the involved mucosa and the fungal masses were removed surgically (Functional Endoscopic Sinus Surgery). The fungal disease was thus considered as eradicated and no antifungal treatment was initiated. Prophylactic treatment by amoxicillin plus clavulanic acid was administered for 7 days to reduce the risk of infection following surgery. One year later, no recurrence was detected.

4. Microbiological work-up

In both cases, histological examination of the sinusal mucosa following Periodic Acid Schiff and Hematoxylin and Eosin stain showed an inflammatory sinusal mucosa infiltrated by numerous polynuclear neutrophils. Microscopic direct examination following a lactophenol blue stain (Lactophenol blue solution, Sigma-Aldrich, France) showed hyaline and septate hyphae with acute angles (Fig. 2). Other pieces of the biopsied tissue were inoculated onto Sabouraud dextrose agar plates supplemented with gentamicin and chloramphenicol (SGC) (Oxoid, Dardilly, France) and incubated at 30 °C up to 10 days. The culture media were examined daily for microbial growth.

For Case 1, six days after inoculation, a white cottony colony was observed on the SGC medium. Microscopic examination of the colony showed hyaline, septate hyphae and sickled-shape conidia suggesting a *Fusarium* species. The colony was further identified both by MALDI-TOF mass spectrometry and DNA sequence-based identification as described respectively by Cassagne et al. [6] and Gautier et al. [7]. The colony was identified as *F. proliferatum* both by MALDI-TOF mass spectrometry identification (with the interpretation criteria described in [5] and DNA sequence-based identification [>98% identity]). The obtained ITS sequence was blasted against GenBank nucleotide sequences and matched with

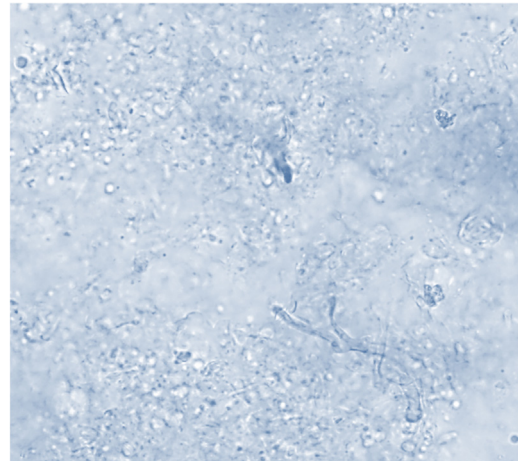


Fig. 2. Lactophenol blue-stained smear of sinus discharge showing dichotomous branched and septate hyphae.

100% identity with the *F. proliferatum* sequence KY425734.1. For Case 2, a biopsied sinusal fragment incubated at 30 °C grew a white cottony colony at day four after incubation. The colony was identified by MALDI-TOF mass spectrometry as *F. proliferatum* [6]. In parallel, direct DNA sequencing identification targeting the rRNA ITS2 region (primer sequences, [GCA TCG ATG AAG AAC GCA GC] and [TCC TCC GCT TAT TGA TAT GC]) and the partial beta-tubulin gene (primer sequences [GGT AAC CAA ATC GGT GCT GCT TTC] and [ACC CTC AGT GTA GTG ACC CTT GGC]) was performed in parallel on another specimen of the sinusal content. The obtained sequences matched 99% and 100% with the *F. proliferatum* Genbank accession numbers KJ767073.1 and KX421566, respectively.

5. Discussion

Fungal species causing paranasal sinusitis fungus balls remain largely unknown for two main reasons. First, few fungus balls are sent for histopathological and/or mycological analysis after surgery. Second, fungus ball cultures are often negative, maybe on account of the poor viability of the fungal component within a fungus ball. Only about 23% to 50% of the fungus balls grew on

mycological culture media [8]. Although hyphae are often observed in surgical samples, direct microscopic examination cannot identify the *fungus* species. *A. fumigatus* (between 44.8% and 75%) and *A. flavus* (14%) are the two most common species recovered [8–10]. However, recent advances in mycological laboratory methods have enhanced the detection and identification of fungi within fungus balls. Direct sequencing from samples and identification by MALDI-TOF mass spectrometry have greatly improved the mycological diagnosis over the last few decades [11]. Besides *Aspergillus* spp., a growing number of unusual species have been identified from sinuses fungus balls. For example, nucleotide sequencing is a helpful tool for diagnosing *Schizophyllum commune*, an uncommon basidiomycete, in fungal sinusitis [11,12]. Other rare fungal genera involved in fungus ball are *Alternaria*, *Bipolaris*, *Cochliobolus*, *Paecilomyces*, *Mucor*, *Scedosporium* and *Penicillium* [10,13]. While *Fusarium* species are frequently isolated from the environment, according to Katkar et al., they are rarely involved in fungus ball. [14]. Few cases of fungus ball due to *Fusarium solani* are reported in the literature, and only one case of fungus ball due to *F. proliferatum*. In this paper, we described several very rare cases of *F. proliferatum* fungus ball maxillary sinusitis. Our cases differed from the first one published by its endodontic origin [5]. Presence of endodontic material in maxillary sinus has been proved to be a risk factor for fungus ball, even if the mechanism still remains unclear. Here, functional endoscopic sinus surgery was sufficient to cure the patients by removing the fungal material and involved mucosa. There was no difference in clinical presentation compared to maxillary sinusitis due to *Aspergillus* species. Antifungal treatment is not required for non-invasive fungal rhinosinusitis. These case reports demonstrate that uncommon *fungus* species such as *Fusarium* spp. might be underestimated as agents of sinusal cavity fungus ball. Enhanced mycological detection and diagnostic techniques might give rise, in the near future, to the emergence of new or rare *fungus* species associated with this clinical entity.

Ethics

All procedures performed in studies involving human participants were in accordance with the ethical standards of the institutional and/or national research committee and with the 1964 Helsinki declaration and its later amendments or comparable ethical standards. Informed consent was obtained from all individual participants included in the study.

Informed consent: yes.

Ethical responsibilities of authors

The manuscript has not been submitted to more than one journal for simultaneous consideration.

The manuscript has not been published previously (partly or in full).

No data have been fabricated or manipulated (including images) to support our conclusions.

No data, text, or theories by others are presented as if they were the author's own ("plagiarism"). Proper acknowledgements to other works must be given (this includes material that is closely copied (near verbatim), summarized and/or paraphrased), quotation

marks are used for verbatim copying of material, and permissions are secured for material that is copyrighted.

Consent to submit has been received explicitly from all co-authors, as well as from the responsible authorities – tacitly or explicitly – at the institute/organization where the work has been carried out, before the work is submitted.

Authors whose names appear on the submission have contributed sufficiently to the scientific work and therefore share collective responsibility and accountability for the results.

Funding

None.

Sources of support in the form of grants: none.

Disclosure of interest

The authors declare that they have no competing interest.

Acknowledgement

None.

References

- [1] Nicolai P, Lombardi D, Tomenzoli D, Villaret AB, Piccioni M, Mensi M, et al. Fungus ball of the paranasal sinuses: experience in 160 patients treated with endoscopic surgery. *Laryngoscope* 2009;119:2275–9.
- [2] Michel J, Radulesco T, Mancini J, Paganelli A, Varoquaux A, Adalian P, et al. Maxillary sinus volume: new physiopathological data in fungus ball genesis? A retrospective study. *Clin Otolaryngol* 2017;42:831–6.
- [3] Mensi M, Piccioni M, Marsili F, Nicolai P, Sapelli PL, Latronicon. Risk of maxillary fungus ball in patients with endodontic treatment on maxillary teeth: a case-control study. *Oral Surg Oral Med Oral Pathol Oral Radiol Endod* 2007;103:433–6.
- [4] Ferreiro J, Carlson B, Cody D. Paranasal sinus fungus balls. *Head Neck* 1997;19:481–6.
- [5] Hashemi S, Ardehali M, Rezaei S, Zibafar E, Shoar M, Rezaei-Matehkolaei A, et al. A case of fungus ball-type pansinusitis due to *Fusarium proliferatum*. *Mycopathologia* 2015;180:251–5.
- [6] Cassagne C, Ranque S, Normand AC, Fourquet P, Thiebault S, Planard C, et al. Mould routine identification in the clinical laboratory by matrix-assisted laser desorption ionization time-of-flight mass spectrometry. *PLoS One* 2011;6 [e28425].
- [7] Gautier M, Ranque S, Normand AC, Becker P, Packeu A, Cassagne C, et al. Matrix-assisted laser desorption ionization time-of-flight mass spectrometry: revolutionizing clinical laboratory diagnosis of mould infections. *Clin Microbiol Infect* 2014;20:1366–71.
- [8] Ferguson BJ. Fungus balls of the paranasal sinuses. *Otolaryngol Clin North Am* 2000;33:389–98.
- [9] Klossek J, Serrano E, Peloquin L, Percodani J, Fontanel J, Pessey J. Functional endoscopic sinus surgery and 109 mycetomas of paranasal sinuses. *Laryngoscope* 1997;107:112–7.
- [10] Montone K, Livolsi V, Feldman M, Palmer J, Chiu A, Lanza D, et al. Fungal rhinosinusitis: a retrospective microbiologic and pathologic review of 400 patients at a single university medical center. *Int J Otolaryngol* 2012;2012 [684835].
- [11] Baron O, Cassaing S, Percodani J, Berry A, Linas MD, Fabre R, et al. Nucleotide sequencing for diagnosis of sinusal infection by *Schizophyllum commune*, an uncommon pathogenic fungus. *J Clin Microbiol* 2006;44:3042–3.
- [12] Michel J, Maubon D, Varoquaux DA, Boulze C, Normand AC, Righini CA, et al. *Schizophyllum commune*: an emergent or misdiagnosed fungal pathogen in rhinology? *Med Mycol* 2016;54:301–9.
- [13] Gautier M, Michel J, Normand AC, Cassagne C, Piarroux R, Ranque S. *Cochliobolus hawaiiensis* sinusitis, a tropical disease? A case report and review of the literature. *Mycopathologia* 2015;180:117–21.
- [14] Katkar VJ, Tankhiwale SS, Kurhade A. *Fusarium solani* mycetoma. *Indian J Dermatol* 2011;56:315–7.