



**HAL**  
open science

## Isolated renal echinococcosis presenting as a complex renal cyst with initial suspicion of malignancy

Carole Eldin, Jeanne Thomassin-Piana, Pierre Berger, Thomas Maubon,  
Philippe Parola

► **To cite this version:**

Carole Eldin, Jeanne Thomassin-Piana, Pierre Berger, Thomas Maubon, Philippe Parola. Isolated renal echinococcosis presenting as a complex renal cyst with initial suspicion of malignancy. IDCASES, 2019, 18, pp.e00653. 10.1016/j.idcr.2019.e00653 . hal-02439835

**HAL Id: hal-02439835**

**<https://amu.hal.science/hal-02439835v1>**

Submitted on 6 Nov 2024

**HAL** is a multi-disciplinary open access archive for the deposit and dissemination of scientific research documents, whether they are published or not. The documents may come from teaching and research institutions in France or abroad, or from public or private research centers.

L'archive ouverte pluridisciplinaire **HAL**, est destinée au dépôt et à la diffusion de documents scientifiques de niveau recherche, publiés ou non, émanant des établissements d'enseignement et de recherche français ou étrangers, des laboratoires publics ou privés.



Distributed under a Creative Commons Attribution - NonCommercial - NoDerivatives 4.0 International License

## Case report

## Isolated renal echinococcosis presenting as a complex renal cyst with initial suspicion of malignancy



Carole Eldin<sup>a,b,\*</sup>, Jeanne Thomassin-Piana<sup>c</sup>, Pierre Berger<sup>c</sup>, Thomas Maubon<sup>c</sup>,  
Philippe Parola<sup>a,b</sup>

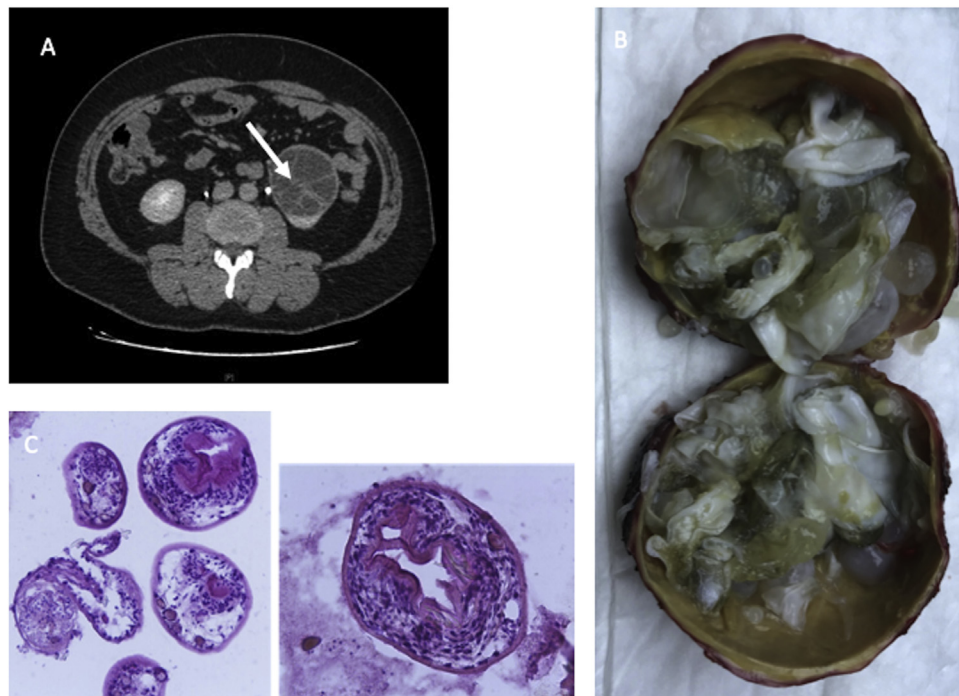
<sup>a</sup> Aix Marseille Univ, IRD, AP-HM, SSA, VITROME, Marseille, France

<sup>b</sup> IHU-Méditerranée Infection, Marseille, France

<sup>c</sup> Centre de Lutte contre le Cancer, Institut Paoli-Calmettes, Fédération Unicancer, Marseille, France

In March 2018, a 43-year-old man presented at the emergency unit of our centre with lumbar pain immediately following a car accident. A lumbar CT-scan was performed, which incidentally revealed an 85 mm atypical cystic and partitioned mass in the left kidney, with hyperdense walls (Fig. 1). He lived in Algeria until the age of 25. The complete WBC count, haemoglobin, C-reactive

protein and standard blood biochemistry values were within normal limits. Due to suspected renal malignancy, the patient was transferred to the oncological centre, where he was operated upon in May 2018. A partial nephrectomy was performed but the surgical procedure proved difficult due to very adherent cystic lesions.



**Fig. 1.** (A) CT urogram showing a left partitioned cystic renal mass. (B) Resected specimen showing a hydatid cyst and multiple daughter cysts within it. (C) Histological sections of hydatid cysts.

\* Corresponding author at: Aix Marseille Univ, IRD, AP-HM, SSA, VITROME, Marseille, France.  
E-mail address: [carole.eldin@gmail.com](mailto:carole.eldin@gmail.com) (C. Eldin).

Pathological examination revealed a hydatid cyst with multiple daughter cysts within it (Fig. 1). The patient was subsequently referred to the infectious diseases unit. Serological tests for *Echinococcus granulosus* (ELISA and indirect haemagglutination) were performed following surgery and were positive. No hepatic cyst or other localisation was found using a thoracic and abdominal CT-scan. Treatment with albendazole was started on June 2018 for three months in order to prevent potential dissemination, and because the patient had not been treated before surgery. A CT-scan was performed at three months, confirming the absence of residual

lesions. Treatment was stopped after five months. Follow-up at eight months after surgery showed no signs of dissemination.

Hydatidosis is one of the 17 neglected tropical diseases recognised by the World Health Organization. Renal hydatid cysts represent between 1 and 5% of all hydatid diseases in humans. This case should remind clinicians that hydatidosis should be considered in the differential diagnosis of renal cystic masses in patients who live or have lived in endemic areas, in order to treat them before surgical procedures, and to avoid the spillage of cyst contents during surgery.