



HAL
open science

Mediastinitis in the intensive care unit patient: a narrative review

B. Pastene, N. Cassir, J. Tankel, S. Einav, P.-E. Fournier, P. Thomas, M. Leone

► To cite this version:

B. Pastene, N. Cassir, J. Tankel, S. Einav, P.-E. Fournier, et al.. Mediastinitis in the intensive care unit patient: a narrative review. *Clinical Microbiology and Infection*, 2020, 26 (1), pp.26-34. 10.1016/j.cmi.2019.07.005 . hal-02446211

HAL Id: hal-02446211

<https://amu.hal.science/hal-02446211>

Submitted on 7 Mar 2022

HAL is a multi-disciplinary open access archive for the deposit and dissemination of scientific research documents, whether they are published or not. The documents may come from teaching and research institutions in France or abroad, or from public or private research centers.

L'archive ouverte pluridisciplinaire **HAL**, est destinée au dépôt et à la diffusion de documents scientifiques de niveau recherche, publiés ou non, émanant des établissements d'enseignement et de recherche français ou étrangers, des laboratoires publics ou privés.



Distributed under a Creative Commons Attribution - NonCommercial 4.0 International License

1 **Mediastinitis in the ICU patient: a narrative review.**

2 Bruno Pastene,¹ Nadim Cassir,² James Tankel,^{3, 4} Sharon Einav,⁵ Pierre-Edouard Fournier,⁶ Pascal
3 Thomas,⁷ Marc Leone^{1,2}

4

5 1. Aix Marseille Université, Assistance Publique Hôpitaux de Marseille, Hôpital Nord, Department of
6 Anesthesiology and Intensive Care Medicine, Marseille, France

7 2. MEPHI, IHU Méditerranée Infection, Aix Marseille Université, Marseille, France

8 3. Department of General Surgery, Shaare Zedek Medical Centre, Jerusalem, Israel

9 4. Department of Surgery and Cancer, Imperial College Healthcare Trust, St Mary's Hospital, London

10 5. Surgical Intensive Care Unit, Shaare Zedek Medical Centre, Jerusalem, Israel

11 6. VITROME, IHU Méditerranée Infection, Aix Marseille Université, Marseille, France

12 7. Aix Marseille Université, Assistance Publique Hôpitaux de Marseille, Hôpital Nord, Department of
13 Thoracic Surgery and Esophageal Diseases, Marseille, France

14

15 Corresponding author

16 Marc Leone, Department of Anesthesiology and Intensive Care Medicine, Hôpital Nord, Chemin des
17 Bourrely, 13015 Marseille, France. *E-mail address:* marc.leone@ap-hm.fr

18

19

20 **Statement:**

21 The abstract is 239 words long

22 The article is 3666 words long.

23 **Abstract**

24 Background

25 Mediastinitis is a rare but severe infection, defined as an inflammation of the connective tissues and
26 structures within the mediastinum. Due to its proximity with vital structures, mediastinitis represents
27 a highly morbid pathological process associated with a high risk of mortality. In most cases
28 mediastinitis requires treatment in the intensive care unit.

29 Objectives

30 The goal of this narrative review is to highlight to the reader the clinical features of mediastinitis, to
31 attempt to define each clinical scenario, to describe the responsible pathogens and finally to depict
32 both the medical and surgical treatment.

33 Sources

34 We performed a literature search of the PubMed and Cochrane libraries, limited for articles
35 published between January 2003 and December 2018, reporting on acute mediastinitis.

36 Content

37 The term covers different entities of different etiologies including deep sternal wound infection
38 related to sternotomy; esophageal perforation or anastomosis leakage; and finally descending
39 necrotizing mediastinitis often secondary to oropharyngeal abscess. The responsible pathogens and
40 therefore subsequent management depends on the underlying etiology. Empirical antimicrobial
41 therapy should cover the suspected microorganisms while surgery and supportive measures should
42 aim to reduce the inoculum of pathogens by providing adequate drainage and debridement.

43 Implications

44 Literature concerning mediastinitis in the ICU is relatively scarce. Here we collated the evidence and
45 reviewed the different causes and treatment options of acute mediastinitis with a particular focus on
46 microbiological epidemiology. Future research in larger cohorts is needed to better understand the
47 treatment of this difficult disease.

48

49 **Introduction**

50 An otherwise healthy lumberjack was diagnosed with a tooth abscess. Despite being treated with a
51 course of oral antibiotics and steroids the infection progressed and after two days he developed
52 septic shock caused by descending necrotizing mediastinitis (DNM). This required extraction of the
53 affected tooth, cervico-mediastinal debridement, a prolonged course of intravenous antibiotics and
54 hospitalization in the Intensive Care Unit (ICU) for several weeks. It took almost three months before
55 the patient fully recovered and was able to return to work. Although mediastinitis is rare, this
56 vignette is typical and highlights the high level of morbidity and mortality that this severe infection
57 can cause.

58 The term “mediastinitis” refers to an infection of the mediastinum which can be caused by a range of
59 different etiologies including deep sternal wound infection (DSWI) following sternotomy, esophageal
60 perforation and DNM which is often secondary to an oropharyngeal abscess. The goal of this
61 narrative review is to define each of these causes of mediastinitis, to describe the associated clinical
62 features and responsible pathogens as well as discuss the medical and surgical treatment options.

63

64 **Method**

65 For the purpose of this review, an online literature search of the PubMed and Cochrane libraries was
66 performed using the terms listed in the supplementary file 1. The search was limited to articles that
67 were published in English, between January 2003 and December 2018 and included only human
68 adult subjects. Initially the search was also limited to include only randomized controlled trials, meta-
69 analyses and observational studies. However, as this yielded an insufficient amount of high-quality
70 data the search was subsequently expanded to include expert opinion papers, guidelines,
71 recommendations and case series. Those articles that were not specifically written in the context of
72 the ICU were also included if it was thought to be relevant to this review. Finally, the references of all
73 of these articles identified in this expanded search were screened in order to identify any additional

74 relevant sources, regardless of publication date. Figure 1 shows the flow chart of the research
75 process. All of the contributing authors had access to electronic versions of all of the articles
76 identified.

77

78 **Definitions, epidemiology and risk factors**

79 The mediastinum is the area posterior to the sternum and anterior to the thoracic spinal column. It
80 contains the heart and large vessels, trachea, esophagus, thymus and lymph nodes (Figure 2).
81 Mediastinitis describes a process of either inflammation and/or infection of the connective tissues
82 and structures contained within the mediastinum. Due to the vital nature of those structures
83 contained within the mediastinum, mediastinitis is associated with a high degree of morbidity and
84 mortality with most cases requiring admission and treatment in the ICU [1]. The three most common
85 etiologies of mediastinitis are described below and include DSWI, esophageal perforation and DNM.

86

87 **Deep sternal wound infection**

88 DSWI describes a process by which the mediastinum becomes infected secondary to a deep wound
89 infection following sternotomy. The Center for Disease Control defines DSWI as the presence of
90 fever, chest pain or sternal instability with any one of the following: Purulent discharge from the
91 operative wound; mediastinal widening on imaging studies; identification of micro-organisms
92 cultured from mediastinal fluid or tissues; or histopathological evidence of mediastinitis on tissue
93 samples from the mediastinum[2, 3]. The most recent classification of DSWI is based on the depth
94 and extent of the infectious process and correlates with the severity of the infection. A Type I
95 infection involves the skin and subcutaneous tissues only, Type II either the sternum or ribs, Type III
96 includes bone loss of either the sternum or ribs and finally Type IV, when the mediastinum itself is
97 affected[4].

98 Recent multi-center cohort studies and meta-analyses have reported that DSWI affects between
99 0.5% and 2.2% of patients undergoing cardiac surgery [5–7] and is associated with a mortality rate of
100 14% [5]. Mortality rates of elective cardiac surgery patients are five times higher if postoperative
101 mediastinitis occurs [6]. Risk factors for DSWI can be either patient or procedure-related. The
102 patient-related factors that increase the risk of developing DSWI are old age [2, 7], obesity, elevated
103 preoperative creatinine, peripheral vascular disease [2, 6, 8], diabetes mellitus [2, 5], hyperglycemia
104 in non-diabetic patients [6], pre-operative colonization with *Staphylococcus aureus* [9], chronic
105 obstructive pulmonary disease, smoking, heart failure and female gender [2]. Procedure-related risk
106 factors include the use of a ventricular assist device, transplant surgery [5, 6], the use of bilateral
107 internal mammary artery grafts, prolonged length of surgery, the use of aortic cross clamping, redo
108 surgery and finally on-pump perfusion [2, 8]. Tracheostomy is also considered as a risk factor for
109 DSWI, with early percutaneous tracheostomy being at higher risk. [10, 11]

110

111 Esophageal perforation

112 As the esophagus is colonized by both commensal and hospital-acquired microorganisms, any loss in
113 the integrity of the esophageal wall may result in mediastinitis. The data relating to esophageal
114 perforation comes from large and recent multi-center cohort studies and systematic reviews.
115 Iatrogenic perforation during endoscopy is responsible for 60% of all esophageal perforations [12,
116 13] with the risk depending on the type of procedure performed. Pneumatic dilatations are
117 associated with a 2-6% risk of esophageal perforation, stricture dilatation with a 0.09-2% risk and
118 diagnostic procedures with 0.03-0.11% risk [12]. Furthermore, abnormal esophageal tissue is found
119 in half of all of the cases of endoscopic perforation [13]. In the healthy esophagus, perforation
120 usually occurs in areas of natural anatomical weakness such as Killian’s triangle, the cricopharyngeal
121 region and the esophagogastric juncture [12]. Spontaneous perforation (including Boerhaave’s
122 syndrome) represents between 8 to 33% of all esophageal perforations [12, 14] whilst traumatic and

123 malignant perforations represent 17% of cases [13, 14]. With an annual incidence of 3.1/million,
124 esophageal perforation is rare with a reported mortality of up to 20% [13]. Whilst late diagnosis is a
125 major factor associated with patient death [12], so elusive is the diagnosis that almost 20% of cases
126 are only diagnosed at autopsy [13].

127 Perforation can also occur due to failure of a surgical anastomosis. This life-threatening post-
128 operative complication occurs in up to 30% of esophageal anastomoses with a mortality rate of 2-
129 12% [15]. The risk of such a failure is associated with a cervical anastomosis, female gender and pre-
130 operative smoking [15]. Anastomotic leak can be graded as follows: Grade I (radiologically evident,
131 no clinical sequelae); Grade II (minor clinical sequelae); Grade III (major clinical sequelae); and Grade
132 IV (necrosis of the conduit) [15]. Whilst there is a paucity of data concerning the success of various
133 treatment options for each grade of leak, it is clear that an anastomotic leak often requires
134 protracted treatment in the ICU, a long hospital stay and multiple interventions. Furthermore, it has
135 a lasting impact on the patients' quality of life, consumes a large amount of hospital resources and is
136 associated with high overall costs [16–19].

137

138 Descending necrotizing mediastinitis (DNM)

139 DNM describes a serious infective process that originates from the ears, nose or throat and spreads
140 inferiorly into the mediastinum via connective tissues planes. It can be defined by the presence of a
141 severe oropharyngeal infection with concurrent radiological features that suggest mediastinitis [20,
142 21]. As with other forms of mediastinitis, DNM can be classified into Type I (localized), Type IIa
143 (diffuse, extending into the lower anterior mediastinum) and Type IIb (diffuse, extending into both
144 the anterior and posterior lower mediastinum) [22] (Figure 3).

145 DNM is caused by odontogenic (36-47%), pharyngeal (33-45%) or cervical (15%) infections. In 6% of
146 cases, the source of infection is unknown [1, 21]. As listed in Table 1, the main risk factors for DNM
147 include impaired immune function, diabetes, the use of oral glucocorticoids and reduced tissue

148 oxygenation caused by heart failure, respiratory insufficiency and peripheral artery occlusive disease.
149 As a result, only 13% of DNM patients have no underlying comorbid illness [23]. The regular use of
150 non-steroidal anti-inflammatory drugs is not thought to be a contributing factor [24]. The mortality
151 of DNM is high and reported to be between 15 and 30% [1, 21, 23] with a higher risk of death
152 associated with a delay in diagnosis, inadequate surgical drainage of the mediastinum [23], advanced
153 age, increasing ICU severity scores and higher a grade of DNM [1]. Epidemiology of DNM is also based
154 on recent multi-center cohort studies and systematic review.

155

156 Acute hematogenous mediastinitis, rare mediastinitis etiologies

157 A rare cause of acute mediastinitis is primary mediastinitis caused by hematogenous spread from a
158 remote infection. Although typically found in ICU patients, there are only a few case reports that
159 describe this process [25, 26]. As a result, the etiology is poorly understood and treatment modalities
160 not elaborated. Also, any cause of esophageal or broncho-tracheal perforations can be a potential,
161 yet uncommon, cause of mediastinitis.

162

163 **Diagnosis and management**

164 Diagnosis

165 *Clinical presentation*

166 Signs of mediastinitis are non-specific and largely depend on the underlying etiology. They consist of
167 an infective process causing fever, chills and tachycardia. Although pain is often masked in the ICU
168 patient, if it is present it can often help identify the site and thus underlying cause of the infection.
169 When an ear, nose or throat infection is present, a trismus, or *lockjaw*, can also sometimes be found.
170 A systemic inflammatory response syndrome often develops abruptly although the speed of onset
171 depends on both the underlying etiology and patient characteristics. Early diagnosis of mediastinitis

172 is critical as it allows for prompt antibiotic therapy to be started and surgical intervention to be
173 performed [21].

174

175 *Laboratory findings*

176 Although laboratory findings are non-specific, an elevated leukocyte count, C-reactive protein and
177 procalcitonin level are often found. Additionally, a progressive thrombocytopenia may reflect
178 worsening sepsis. Evidence of disseminated intravascular coagulation may also be present.

179

180 *Imaging*

181 When mediastinitis is suspected, contrast enhanced computed tomography (CT) of the neck and
182 chest is the imaging modality of choice in order to confirm the diagnosis. Not only is a CT scan highly
183 sensitive for identifying the underlying cause of the mediastinitis, but the extent of the infectious
184 process can also be gauged. This is vital in planning potential surgical interventions [27] (Figure 4).

185 Despite the high sensitivity of cross-sectional imaging, it should be noted that in the setting of DSWI
186 diagnosing mediastinitis can be challenging due to the inflammatory changes that occur following
187 surgery. In this situation, a repeat CT scan and/or scintigraphy may be useful in assessing for
188 evidence of disease progression [28].

189 *Microbiological sampling*

190 In addition to cross-sectional imaging, the microbiological diagnosis of mediastinitis is critical in order
191 to adapt the antimicrobial therapy accordingly. Blood cultures should ideally be taken and either
192 tissue or fluid samples obtained prior to the initiation of antibiotic therapy. This may require
193 aspiration from deep abscess cavities or debridement of infected sternal or mediastinal tissues [29,
194 30]. In more severe cases, pleural fluid or broncho-alveolar secretions may also be required [31].
195 When taken alone, superficial wound cultures should be interpreted with caution as they may
196 represent wound colonization rather than infection and lead to inappropriate antibiotic therapy [30].

197

198 Microbiological epidemiology.

199 *Mediastinitis after cardiac surgery -*

200 The majority of patients with postoperative mediastinitis develop monomicrobial infections. In a
201 French study that included 309 patients admitted to the ICU for post-cardiac surgery mediastinitis,
202 262 (84.7%) were monomicrobial [32]. The most common bacteria isolated were methicillin
203 susceptible *Staphylococcus aureus* (MSSA) (31.9%), *Enterobacteriaceae* (25.8%), coagulase negative
204 *Staphylococcus* (CoNS) (18.7%), *Streptococcus* spp. (8.5%), methicillin resistant *S.aureus* (MRSA)
205 (6.9%) and non-fermenting Gram negative bacteria (1.9%). In a Chinese study on a similar cohort of
206 patients, the organisms isolated were Gram negative bacteria (55.4%), MSSA (20.4%), CoNS (14%),
207 MRSA (5.7%) and fungi (3.8%) [33]. Amongst the Gram negative bacteria, *Acinetobacter baumannii*,
208 *Pseudomonas aeruginosa*, and *Enterobacter cloacae* exhibited 100%, 15%, and 0% resistance to
209 ceftazidime respectively, 100%, 22.5% and 40% resistance to piperacillin-tazobactam, and 80%,
210 17.5%, and 0% resistance to carbapenem [33]. In a Brazilian series including 92 patients with post-
211 cardiac surgery mediastinitis [34], 33 patients (35.8%) were infected with carbapenem-resistant
212 *Enterobacteriaceae*, amongst which 15 (45%) were also resistant to colistin. The discrepancy
213 between the different cultures and sensitivities of the microbiological flora identified may be
214 explained by local ecologies and institutional antibiotic policies.

215 Sporadic outbreaks of unexpected organisms, such as *Candida* spp. [35] and *Legionella* spp. [36],
216 have also been found to cause DSWI following cardiac surgery, as have *Nocardia* spp. [37],
217 *Mycoplasma hominis* and *Mycobacterium tuberculosis* [38, 39]. *Mycobacterium chimaera* as a
218 causative agent, thought to originate from a contaminated heater-cooler device used in bypass
219 surgery, has also been described [40].

220 *Mediastinitis secondary to esophageal perforation*

221 The microorganisms responsible for mediastinitis secondary to esophageal perforation depend on
222 several factors including the site of perforation, the clinical status of patient, the use of enteral
223 nutrition and of gastric acid suppression, the degree of immunosuppression and a history of recent
224 antibiotic exposure. In non-intubated, healthy adults who has not recently received antibiotics,
225 organisms in the upper esophagus are essentially identical to those in the oropharynx and include
226 streptococci (including *S.salivarius*, *S.mutans*, *S.mitis*, *S.sanguinis* and *S.anginosus*), *Neisseria* spp.,
227 *Haemophilus* spp. and anaerobes such as *Prevotella* spp. or *Fusobacterium* spp. [41]. In those who
228 are critically ill and have been exposed to recent antibiotic therapy, the normal oral flora is rapidly
229 replaced by aerobic Gram negative bacteria, *S. aureus*, and *Candida* spp. [42].

230 *Descending necrotizing mediastinitis*

231 Unlike the monobacterial infections of DSWI, mediastinitis caused by DNM is typically polymicrobial
232 and consists of the normal resident flora found on the mucosal surfaces of the oral cavity, upper
233 respiratory tract, ears and eyes. However, in those who are critically ill with odontogenic infections,
234 less than 25% of blood and tissue cultures are positive [43]. This may reflect the finding that the
235 patients referred from the community to the hospital with odontogenic infections are likely to have
236 received a course of antibiotics prior to their admission [44].

237 The pathogens found in odontologic infections commonly include *Streptococcus* spp., *S.aureus*,
238 *P.aeruginosa* and *Escherichia coli* [43]. Most dental abscesses also harbor oral anaerobes including
239 *Peptostreptococcus* spp., *Fusobacterium nucleatum*, *Prevotella* spp. and *Actinomyces* spp. [45].

240 Infections arising from the pharynx frequently contain oral anaerobes, such as *Fusobacterium*
241 *necrophorum* and facultative streptococci including *S.pyogenes* [46]. *H.influenzae* may also be found
242 in parapharyngeal or retropharyngeal abscesses [47].

243 Otogenic infections frequently involve streptococci, obligate anaerobes, *S.aureus* and *P.aeruginosa*
244 [48]. Infections arising from chronic suppurative sinusitis tend to involve *S.pneumoniae*, *H.influenzae*,

245 *Moraxella catarrhalis*, *S.aureus* and obligate anaerobes [47]. The distribution of these bacterial flora
246 is described in Table 2.

247

248 General principles of management

249 Although the management of mediastinitis depends on the underlying etiology, several elements of
250 care are generic to all patients. Mediastinitis is a severe infection that often evolves into septic shock.
251 In patients with DNM, there is a correlation between both the time to ICU admission and the ICU
252 severity scores on admission to the unit with the overall mortality [1]. Moreover, septic shock is an
253 independent predictor of mortality [21].

254 Airway compromise should be anticipated early especially in cases involving the neck and upper
255 mediastinum. Due to trismus and local swelling, both laryngoscopic visualization and anterior access
256 to the airway may be compromised. Guidelines dictate that the airway should be managed by an
257 expert anesthesiologist with an alternative plan for airway control clarified beforehand. Involvement
258 of an expert otolaryngologist and/or maxillo-facial surgeon in planning intubation is encouraged and
259 they should also be present at the time of intubation should efforts at endotracheal intubation fail
260 [49–51].

261

262 Antimicrobial therapy

263 The antimicrobial treatment of mediastinitis should follow the good practice principles of empirical
264 antimicrobial therapy in ICU patients [52, 53]. Microbiological samples should ideally be collected
265 prior to the administration of antibiotics although treatment should not be unduly delayed [53]. In
266 mediastinitis, specific data regarding the efficacy of antimicrobial therapy are scarce and hence the
267 following recommendations, summarized in Table 3, are based on expert opinions.

268 In mediastinitis secondary to DSWI, empirical antimicrobial therapy should cover MSSA, skin
269 commensals and gastrointestinal Gram negative bacteria [6, 54]. We recommend a broad-spectrum
270 beta-lactam penicillin, such as piperacillin/tazobactam, with the addition of a glycopeptid or
271 oxazolidinone if MRSA or methicillin resistant CoNS stains are suspected.

272 In patients with mediastinitis after esophageal perforation, intravenous broad-spectrum antibiotics
273 should cover the aerobes and anaerobes that are commonly found in the upper digestive tract and
274 may include piperacillin/tazobactam or a third-generation cephalosporin with metronidazole [2, 12].
275 We suggest that this treatment should be continued for at least seven days after the drainage of fluid
276 collections and repair/healing of the perforation. In more severe infections or complex patients,
277 although not supported by data from randomized studies, we suggest considering the use of an
278 empirical anti-fungal. Specifically, we recommend initiating echinocandin if three out of the four
279 following criteria are present: Septic shock; female gender; previous upper gastrointestinal surgery;
280 and previous recent antimicrobial therapy lasting more than 48 hours [55].

281 In mediastinitis secondary to DNM, empirical antimicrobial therapy should cover those aerobic and
282 anaerobic bacteria commonly associated with ear, nose and throat infections. Although there are no
283 standardized regimens described in the academic literature, a third-generation cephalosporin with
284 metronidazole [21] or a combination of piperacillin/tazobactam and clindamycin is suggested [56].

285 Once microbiological samples have been obtained, broad-spectrum antimicrobial therapy can be
286 initiated until such time that it can be tailored according to the subsequent microbiological findings
287 [57]. The ideal duration of antimicrobial therapy in mediastinitis is not well defined. Nevertheless,
288 the literature consistently suggests that a long course of treatment lasting between 14 to 21 days is
289 required [2, 12, 21]. A course of six weeks is recommended when foreign bodies, such as sternotomy
290 wires, are present [58]. Whilst the use of serial CT imaging and biochemical markers of infection can
291 be helpful in monitoring the success of antibiotic therapy, the level of evidence supporting this

292 approach is limited [59]. Therefore, patients require close observation with the dosing, duration and
293 regimen of antimicrobial therapy changed as required.

294

295 Surgery

296 Control of the infectious source and debridement of affected tissue are the cornerstones of the
297 surgical treatment of mediastinitis. The surgical strategy is determined according to the cause and
298 extent of the underlying disease. This can be best appreciated on cross-sectional imaging. A delay
299 between diagnosis and surgical intervention is known to be associated with poor outcome and as
300 such should not exceed 24 hours [2].

301 DSWI requires early operative intervention for the debridement of necrotic tissues and the removal
302 of sternal wires. If sternal instability is present and healthy bone stock lacking, surgical closure can be
303 ultimately achieved using muscle or omental flaps [2]. In both DNM and esophageal perforation,
304 priority is given to treating the causative lesion with concurrent generous cervical and mediastinal
305 drainage. Figure 5 shows the classical drainage required for DNM.

306 Endoscopic management of esophageal perforations or anastomotic leakage with stents has been
307 described in the literature and is an acceptable option if expertise is available [12, 60, 61]. In certain
308 situations, endoscopically placed negative pressure wound therapy has shown promising results [62].
309 However, due to the small cohorts studied and the clinical heterogeneity of the patients included, no
310 evidence based treatment strategy can be composed based on the existing literature.

311 For localized infections of the neck and upper mediastinum, fascial planes can often be satisfactorily
312 opened by means of a cervicotomy. Should the anterior mediastinum need to be debrided, a median
313 sternotomy may be required. However, in order to prevent subsequent sternal osteomyelitis, a
314 generous bilateral anterolateral thoracotomy may be more appropriate. If local expertise is
315 available, video assisted thoracic surgery has also been used effectively [63]. Should the patient need

316 more drastic debridement, a clamshell thoracotomy offers excellent exposure to the entire
317 mediastinum as well as both pleural cavities. If the posterior mediastinum needs to be accessed, a
318 posterolateral thoracotomy may be more appropriate. Any sign of clinical or biochemical
319 deterioration should be identified early as it may indicate the need for subsequent surgical re-
320 intervention.

321

322 Supportive measures

323 Several of the supportive measures associated with the treatment of mediastinitis are of particular
324 importance and are described in Table 4. Regarding DSWI, routine pre-operative decolonization of
325 nasal *S. aureus* is beneficial [64] and is included in international guidelines as part of the pre-
326 operative prophylactic care bundle for patients undergoing thoracic surgery [65]. Should
327 debridement result in a wound that is not amenable to surgical repair, negative pressure wound
328 therapy is now well recognized and widely used for the closure of complicated sternal wounds that
329 may still be infected. This strategy is safe and effective for both Type I and Type II DSWI and may also
330 have a role preventing disease progression that could result in gross mediastinitis [2]. Whilst the use
331 of open dressings with granulated sugar [66] and treatment with hyperbaric oxygen therapy [67]
332 have also been described, the quality of the evidence supporting these approaches is either low or
333 very low.

334 Adequate calorie intake is critical for preventing a catabolic state and is closely related to successful
335 wound healing. However, as those patients with either esophageal perforation or anastomotic leak
336 are often nil by mouth for long periods of time, either an endoscopically or radiologically placed
337 naso-jejunal feeding tube or formal surgical jejunostomy should be used for enteral feeding in stable
338 patients [2, 68]. If enteral nutrition will be contraindicated for a prolonged period of time, total
339 parenteral nutrition should be used. We also recommend intravenous proton pump inhibitor therapy
340 for between two to three weeks [2, 12].

341 The main supportive measure of DNM is airway management. Due to the difficult nature of the
342 airway in this subset of patients, national and local guidelines regarding difficult airway management
343 must be thoroughly followed. Early tracheotomy should be considered and is both useful for securing
344 the airway as well as opening the fascial planes of the neck [2]. Early airway support is also
345 advantageous as on average patients will need more than three surgical procedures during the
346 course of their illness [21].

347

348 **Conclusion and perspectives**

349 Mediastinitis is a life-threatening infection with significant associated morbidity and mortality. The
350 diagnosis relies on both thorough clinical examination and early cross-sectional imaging. Subsequent
351 management depends on the underlying etiology and can be divided into DSWI, esophageal
352 perforation and DNM. Identification of the causative bacteria is critical in order to appropriately
353 direct antimicrobial therapy although the responsible pathogens vary according to anatomical
354 location making empirical treatment challenging. Surgery and supportive measures should aim to
355 reduce the inoculum of pathogens by providing adequate drainage and debridement.

356 As mediastinitis is a relatively rare entity, the literature supporting treatment options is scarce and
357 often focuses on a single etiology or treatment modality. In this article we have collated this evidence
358 and reviewed the different etiologies as well as treatment options of acute mediastinitis with a
359 particular focus on the microbiological epidemiology. Future research in larger cohorts of patients is
360 needed to better understand the treatment of acute mediastinitis in order to reduce both the
361 morbidity and mortality of this difficult disease.

362 **Transparency declaration**

363 Dr. Pastene has nothing to disclose.

364 Dr. Cassir has nothing to disclose.

365 Dr. Tankel has nothing to disclose.

366 Pr. Einav reports personal fees from Zoll, Medtronic, Diasorin, Merck, Artisanpharma, Eisai, Astra

367 Zenca, outside the submitted work.

368 Pr. FOURNIER has nothing to disclose.

369 Pr. THOMAS has nothing to disclose.

370 Pr. LEONE reports personal fees from MSD, Pfizer, Octopharma, Aspen, Orion, Amomed, Aguetant

371 outside the submitted work.

372

373 No external funding was received for the study.

374

375 No results from this review were previously presented.

376 References

- 377 1. Palma DM, Giuliano S, Cracchiolo AN, Falcone M, Ceccarelli G, Tetamo R, Venditti M (2016)
378 Clinical features and outcome of patients with descending necrotizing mediastinitis:
379 prospective analysis of 34 cases. *Infection* 44:77–84
- 380 2. Abu-Omar Y, Kocher GJ, Bosco P, et al (2017) European Association for Cardio-Thoracic Surgery
381 expert consensus statement on the prevention and management of mediastinitis. *Eur J Cardio-*
382 *Thorac Surg Off J Eur Assoc Cardio-Thorac Surg* 51:10–29
- 383 3. Goh SSC (2017) Post-sternotomy mediastinitis in the modern era. *J Card Surg* 32:556–566
- 384 4. Anger J, Dantas DC, Arnoni RT, Farsky PS (2015) A new classification of post-sternotomy
385 dehiscence. *Rev Bras Cir Cardiovasc Orgao Of Soc Bras Cir Cardiovasc* 30:114–118
- 386 5. Filsoufi F, Castillo JG, Rahmanian PB, Broumand SR, Silvay G, Carpentier A, Adams DH (2009)
387 Epidemiology of deep sternal wound infection in cardiac surgery. *J Cardiothorac Vasc Anesth*
388 23:488–494
- 389 6. Perrault LP, Kirkwood KA, Chang HL, et al (2018) A Prospective Multi-Institutional Cohort Study
390 of Mediastinal Infections After Cardiac Operations. *Ann Thorac Surg* 105:461–468
- 391 7. Abdelnoor M, Vengen ØA, Johansen O, Sandven I, Abdelnoor AM (2016) Latitude of the study
392 place and age of the patient are associated with incidence of mediastinitis and microbiology in
393 open-heart surgery: a systematic review and meta-analysis. *Clin Epidemiol* 8:151–163
- 394 8. Cotogni P, Barbero C, Rinaldi M (2015) Deep sternal wound infection after cardiac surgery:
395 Evidences and controversies. *World J Crit Care Med* 4:265–273
- 396 9. Allen KB, Fowler VGJ, Gammie JS, Hartzel JS, Onorato MT, DiNubile MJ, Sobanjo-Ter Meulen A
397 (2014) Staphylococcus aureus Infections After Elective Cardiothoracic Surgery: Observations
398 From an International Randomized Placebo-Controlled Trial of an Investigational S aureus
399 Vaccine. *Open Forum Infect Dis* 1:ofu071
- 400 10. Tsai Y-C, Phan K, Stroebel A, Williams L, Nicotra L, Drake L, Ryan E, McGree J, Tesar P, Shekar K
401 (2016) Association between post-sternotomy tracheostomy and deep sternal wound infection:
402 a retrospective analysis. *J Thorac Dis* 8:3294–3300
- 403 11. Pilarczyk K, Marggraf G, Dudasova M, Demircioglu E, Scheer V, Jakob H, Dusse F (2015)
404 Tracheostomy After Cardiac Surgery With Median Sternotomy and Risk of Deep Sternal Wound
405 Infections: Is It a Matter of Timing? *J Cardiothorac Vasc Anesth* 29:1573–1581
- 406 12. Chirica M, Champault A, Dray X, Sulpice L, Munoz-Bongrand N, Sarfati E, Cattan P (2010)
407 Esophageal perforations. *J Visc Surg* 147:e117-128
- 408 13. Vidarsdottir H, Blondal S, Alfredsson H, Geirsson A, Gudbjartsson T (2010) Oesophageal
409 perforations in Iceland: a whole population study on incidence, aetiology and surgical outcome.
410 *Thorac Cardiovasc Surg* 58:476–480
- 411 14. Bhatia P, Fortin D, Inculet RI, Malthaner RA (2011) Current concepts in the management of
412 esophageal perforations: a twenty-seven year Canadian experience. *Ann Thorac Surg* 92:209–
413 215

- 414 15. Price TN, Nichols FC, Harmsen WS, Allen MS, Cassivi SD, Wigle DA, Shen KR, Deschamps C
415 (2013) A comprehensive review of anastomotic technique in 432 esophagectomies. *Ann Thorac*
416 *Surg* 95:1154–1160; discussion 1160-1161
- 417 16. Biere SS a. Y, Maas KW, Cuesta MA, van der Peet DL (2011) Cervical or thoracic anastomosis
418 after esophagectomy for cancer: a systematic review and meta-analysis. *Dig Surg* 28:29–35
- 419 17. Alanezi K, Urschel JD (2004) Mortality secondary to esophageal anastomotic leak. *Ann Thorac*
420 *Cardiovasc Surg Off J Assoc Thorac Cardiovasc Surg Asia* 10:71–75
- 421 18. Luketich JD, Pennathur A, Awais O, et al (2012) Outcomes after minimally invasive
422 esophagectomy: review of over 1000 patients. *Ann Surg* 256:95–103
- 423 19. Blackmon SH, Correa AM, Wynn B, et al (2007) Propensity-matched analysis of three
424 techniques for intrathoracic esophagogastric anastomosis. *Ann Thorac Surg* 83:1805–1813;
425 discussion 1813
- 426 20. Estrera AS, Landay MJ, Grisham JM, Sinn DP, Platt MR (1983) Descending necrotizing
427 mediastinitis. *Surg Gynecol Obstet* 157:545–552
- 428 21. Prado-Calleros HM, Jiménez-Fuentes E, Jiménez-Escobar I (2016) Descending necrotizing
429 mediastinitis: Systematic review on its treatment in the last 6 years, 75 years after its
430 description. *Head Neck* 38 Suppl 1:E2275-2283
- 431 22. Endo S, Murayama F, Hasegawa T, Yamamoto S, Yamaguchi T, Sohara Y, Fuse K, Miyata M,
432 Nishino H (1999) Guideline of surgical management based on diffusion of descending
433 necrotizing mediastinitis. *Jpn J Thorac Cardiovasc Surg Off Publ Jpn Assoc Thorac Surg Nihon*
434 *Kyobu Geka Gakkai Zasshi* 47:14–19
- 435 23. Ridder GJ, Maier W, Kinzer S, Teszler CB, Boedeker CC, Pfeiffer J (2010) Descending necrotizing
436 mediastinitis: contemporary trends in etiology, diagnosis, management, and outcome. *Ann Surg*
437 251:528–534
- 438 24. Petitpas F, Blancal J-P, Mateo J, et al (2012) Factors associated with the mediastinal spread of
439 cervical necrotizing fasciitis. *Ann Thorac Surg* 93:234–238
- 440 25. Er F, Nia AM, Caglayan E, Gassanov N (2010) Mediastinitis as a complication of central venous
441 catheterization. *Infection* 38:509
- 442 26. Chang CH, Huang JY, Lai PC, Yang CW (2009) Posterior mediastinal abscess in a hemodialysis
443 patient - a rare but life-threatening complication of Staphylococcus bacteremia. *Clin Nephrol*
444 71:92–95
- 445 27. Exarhos DN, Malagari K, Tsatalou EG, Benakis SV, Peppas C, Kotanidou A, Chondros D, Roussos
446 C (2005) Acute mediastinitis: spectrum of computed tomography findings. *Eur Radiol* 15:1569–
447 1574
- 448 28. Rouzet F, de Labriolle-Vaylet C, Trouillet J-L, Hitzel A, Benali K, Lebtahi R, Le Guludec D (2015)
449 Diagnostic value of (9)(9)mTc-HMPAO-labeled leukocytes scintigraphy in suspicion of post-
450 sternotomy mediastinitis relapse. *J Nucl Cardiol Off Publ Am Soc Nucl Cardiol* 22:123–129
- 451 29. Gottlieb GS, Fowler VG, Kong LK, McClelland RS, Gopal AK, Marr KA, Li J, Sexton DJ, Glower D,
452 Corey GR (2000) Staphylococcus aureus bacteremia in the surgical patient: a prospective

- 453 analysis of 73 postoperative patients who developed *Staphylococcus aureus* bacteremia at a
454 tertiary care facility. *J Am Coll Surg* 190:50–57
- 455 30. Benlolo S, Matéo J, Raskine L, Tibourtine O, Bel A, Payen D, Mebazaa A (2003) Sternal puncture
456 allows an early diagnosis of poststernotomy mediastinitis. *J Thorac Cardiovasc Surg* 125:611–
457 617
- 458 31. Hoffmann M, Kujath P, Vogt F-M, Laubert T, Limmer S, Mulrooney T, Bruch H-P, Jungbluth T,
459 Schloerick E (2013) Outcome and management of invasive candidiasis following oesophageal
460 perforation. *Mycoses* 56:173–178
- 461 32. Charbonneau H, Maillet JM, Faron M, et al (2014) Mediastinitis due to Gram-negative bacteria
462 is associated with increased mortality. *Clin Microbiol Infect Off Publ Eur Soc Clin Microbiol*
463 *Infect Dis* 20:O197-202
- 464 33. Ma J-G, An J-X (2018) Deep sternal wound infection after cardiac surgery: a comparison of three
465 different wound infection types and an analysis of antibiotic resistance. *J Thorac Dis* 10:377–
466 387
- 467 34. Abboud CS, Monteiro J, Stryjewski ME, et al (2016) Post-surgical mediastinitis due to
468 carbapenem-resistant Enterobacteriaceae: Clinical, epidemiological and survival characteristics.
469 *Int J Antimicrob Agents* 47:386–390
- 470 35. Arıkan AA, Omay O, Kanko M, Horuz E, Yağlı G, Kağan EY, Ağır H (2018) Treatment of *Candida*
471 sternal infection following cardiac surgery - a review of literature. *Infect Dis Lond Engl* 1–11
- 472 36. Lowry PW, Blankenship RJ, Gridley W, Troup NJ, Tompkins LS (1991) A cluster of legionella
473 sternal-wound infections due to postoperative topical exposure to contaminated tap water. *N*
474 *Engl J Med* 324:109–113
- 475 37. Wenger PN, Brown JM, McNeil MM, Jarvis WR (1998) *Nocardia farcinica* sternotomy site
476 infections in patients following open heart surgery. *J Infect Dis* 178:1539–1543
- 477 38. Sielaff TD, Everett JE, Shumway SJ, Wahoff DC, Bolman RM, Dunn DL (1996) *Mycoplasma*
478 *hominis* infections occurring in cardiovascular surgical patients. *Ann Thorac Surg* 61:99–103
- 479 39. Wang LZ, Wei CN, Xiao F, Chang XY, Zhang YF (2018) Incidence and risk factors for chronic pain
480 after elective caesarean delivery under spinal anaesthesia in a Chinese cohort: a prospective
481 study. *Int J Obstet Anesth* 34:21–27
- 482 40. Lyman MM, Grigg C, Kinsey CB, et al (2017) Invasive Nontuberculous Mycobacterial Infections
483 among Cardiothoracic Surgical Patients Exposed to Heater-Cooler Devices¹. *Emerg Infect Dis*
484 23:796–805
- 485 41. Norder Grusell E, Dahlén G, Ruth M, Ny L, Quiding-Järbrink M, Bergquist H, Bove M (2013)
486 Bacterial flora of the human oral cavity, and the upper and lower esophagus. *Dis Esophagus Off*
487 *J Int Soc Dis Esophagus* 26:84–90
- 488 42. Safdar N, Crnich CJ, Maki DG (2005) The pathogenesis of ventilator-associated pneumonia: its
489 relevance to developing effective strategies for prevention. *Respir Care* 50:725–739; discussion
490 739-741

- 491 43. Qu L, Liang X, Jiang B, Qian W, Zhang W, Cai X (2018) Risk Factors Affecting the Prognosis of
492 Descending Necrotizing Mediastinitis From Odontogenic Infection. *J Oral Maxillofac Surg Off J*
493 *Am Assoc Oral Maxillofac Surg* 76:1207–1215
- 494 44. Sandner A, Börgermann J, Kösling S, Silber R-E, Bloching MB (2007) Descending necrotizing
495 mediastinitis: early detection and radical surgery are crucial. *J Oral Maxillofac Surg Off J Am*
496 *Assoc Oral Maxillofac Surg* 65:794–800
- 497 45. Brook I (2009) Current management of upper respiratory tract and head and neck infections.
498 *Eur Arch Oto-Rhino-Laryngol Off J Eur Fed Oto-Rhino-Laryngol Soc EUFOS Affil Ger Soc Oto-*
499 *Rhino-Laryngol - Head Neck Surg* 266:315–323
- 500 46. Ehlers Klug T, Rusan M, Fuursted K, Ovesen T (2009) *Fusobacterium necrophorum*: most
501 prevalent pathogen in peritonsillar abscess in Denmark. *Clin Infect Dis Off Publ Infect Dis Soc*
502 *Am* 49:1467–1472
- 503 47. Brook I (2004) Microbiology and management of peritonsillar, retropharyngeal, and
504 parapharyngeal abscesses. *J Oral Maxillofac Surg Off J Am Assoc Oral Maxillofac Surg* 62:1545–
505 1550
- 506 48. Laulajainen Hongisto A, Aarnisalo AA, Lempinen L, Saat R, Markkola A, Leskinen K, Blomstedt G,
507 Jero J (2017) Otogenic Intracranial Abscesses, Our Experience Over the Last Four Decades. *J Int*
508 *Adv Otol* 13:40–46
- 509 49. Apfelbaum JL, Hagberg CA, Caplan RA, et al (2013) Practice guidelines for management of the
510 difficult airway: an updated report by the American Society of Anesthesiologists Task Force on
511 Management of the Difficult Airway. *Anesthesiology* 118:251–270
- 512 50. Frerk C, Mitchell VS, McNarry AF, Mendonca C, Bhagrath R, Patel A, O’Sullivan EP, Woodall NM,
513 Ahmad I, Difficult Airway Society intubation guidelines working group (2015) Difficult Airway
514 Society 2015 guidelines for management of unanticipated difficult intubation in adults. *Br J*
515 *Anaesth* 115:827–848
- 516 51. Langeron O, Bourgain J-L, Francon D, et al (2018) Difficult intubation and extubation in adult
517 anaesthesia. *Anaesth Crit Care Pain Med*. doi: 10.1016/j.accpm.2018.03.013
- 518 52. Champion M, Scully G (2018) Antibiotic Use in the Intensive Care Unit: Optimization and De-
519 Escalation. *J Intensive Care Med* 885066618762747
- 520 53. Pastene B, Duclos G, Martin C, Leone M (2016) Antimicrobial therapy in patients with septic
521 shock. *Presse Med* 45:e111-117
- 522 54. Lemaigen A, Birgand G, Ghodhbane W, et al (2015) Sternal wound infection after cardiac
523 surgery: incidence and risk factors according to clinical presentation. *Clin Microbiol Infect Off*
524 *Publ Eur Soc Clin Microbiol Infect Dis* 21:674.e11–18
- 525 55. Montravers P, Dupont H, Leone M, et al (2015) Guidelines for management of intra-abdominal
526 infections. *Anaesth Crit Care Pain Med* 34:117–130
- 527 56. Gunaratne DA, Tseros EA, Hasan Z, Kudpaje AS, Suruliraj A, Smith MC, Riffat F, Palme CE (2018)
528 Cervical necrotizing fasciitis: Systematic review and analysis of 1235 reported cases from the
529 literature. *Head Neck* 40:2094–2102

- 530 57. McDanel JS, Perencevich EN, Diekema DJ, Herwaldt LA, Smith TC, Chrischilles EA, Dawson JD,
531 Jiang L, Goto M, Schweizer ML (2015) Comparative effectiveness of beta-lactams versus
532 vancomycin for treatment of methicillin-susceptible *Staphylococcus aureus* bloodstream
533 infections among 122 hospitals. *Clin Infect Dis Off Publ Infect Dis Soc Am* 61:361–367
- 534 58. Yusuf E, Chan M, Renz N, Trampuz A (2018) Current perspectives on diagnosis and management
535 of sternal wound infections. *Infect Drug Resist* 11:961–968
- 536 59. Zhang T, Wang Y, Yang Q, Dong Y (2017) Procalcitonin-guided antibiotic therapy in critically ill
537 adults: a meta-analysis. *BMC Infect Dis* 17:514
- 538 60. Vogel SB, Rout WR, Martin TD, Abbitt PL (2005) Esophageal perforation in adults: aggressive,
539 conservative treatment lowers morbidity and mortality. *Ann Surg* 241:1016-1021 ;discussion
540 1021-1023
- 541 61. Brinster CJ, Singhal S, Lee L, Marshall MB, Kaiser LR, Kucharczuk JC (2004) Evolving options in
542 the management of esophageal perforation. *Ann Thorac Surg* 77:1475–1483
- 543 62. Bludau M, Hölscher AH, Herbold T, Leers JM, Gutschow C, Fuchs H, Schröder W (2014)
544 Management of upper intestinal leaks using an endoscopic vacuum-assisted closure system (E-
545 VAC). *Surg Endosc* 28:896–901
- 546 63. Son HS, Cho JH, Park SM, Sun K, Kim KT, Lee SH (2006) Management of descending necrotizing
547 mediastinitis using minimally invasive video-assisted thoracoscopic surgery. *Surg Laparosc*
548 *Endosc Percutan Tech* 16:379–382
- 549 64. Bode LGM, Kluytmans JAJW, Wertheim HFL, et al (2010) Preventing surgical-site infections in
550 nasal carriers of *Staphylococcus aureus*. *N Engl J Med* 362:9–17
- 551 65. Engelman R, Shahian D, Shemin R, Guy TS, Bratzler D, Edwards F, Jacobs M, Fernando H, Bridges
552 C, Workforce on Evidence-Based Medicine, Society of Thoracic Surgeons (2007) The Society of
553 Thoracic Surgeons practice guideline series: Antibiotic prophylaxis in cardiac surgery, part II:
554 Antibiotic choice. *Ann Thorac Surg* 83:1569–1576
- 555 66. De Feo M, Gregorio R, Renzulli A, Ismeno G, Romano GP, Cotrufo M (2000) Treatment of
556 recurrent postoperative mediastinitis with granulated sugar. *J Cardiovasc Surg (Torino)* 41:715–
557 719
- 558 67. Mills C, Bryson P (2006) The role of hyperbaric oxygen therapy in the treatment of sternal
559 wound infection. *Eur J Cardio-Thorac Surg Off J Eur Assoc Cardio-Thorac Surg* 30:153–159
- 560 68. Doddoli C, Trousse D, Avaro J-P, Djournon X-B, Giudicelli R, Fuentes P, Thomas P (2010) [Acute
561 mediastinitis except in a context of cardiac surgery]. *Rev Pneumol Clin* 66:71–80

562

563

564

INITIAL PubMed and Cochrane search :
RCT, meta-analyses and observational studies

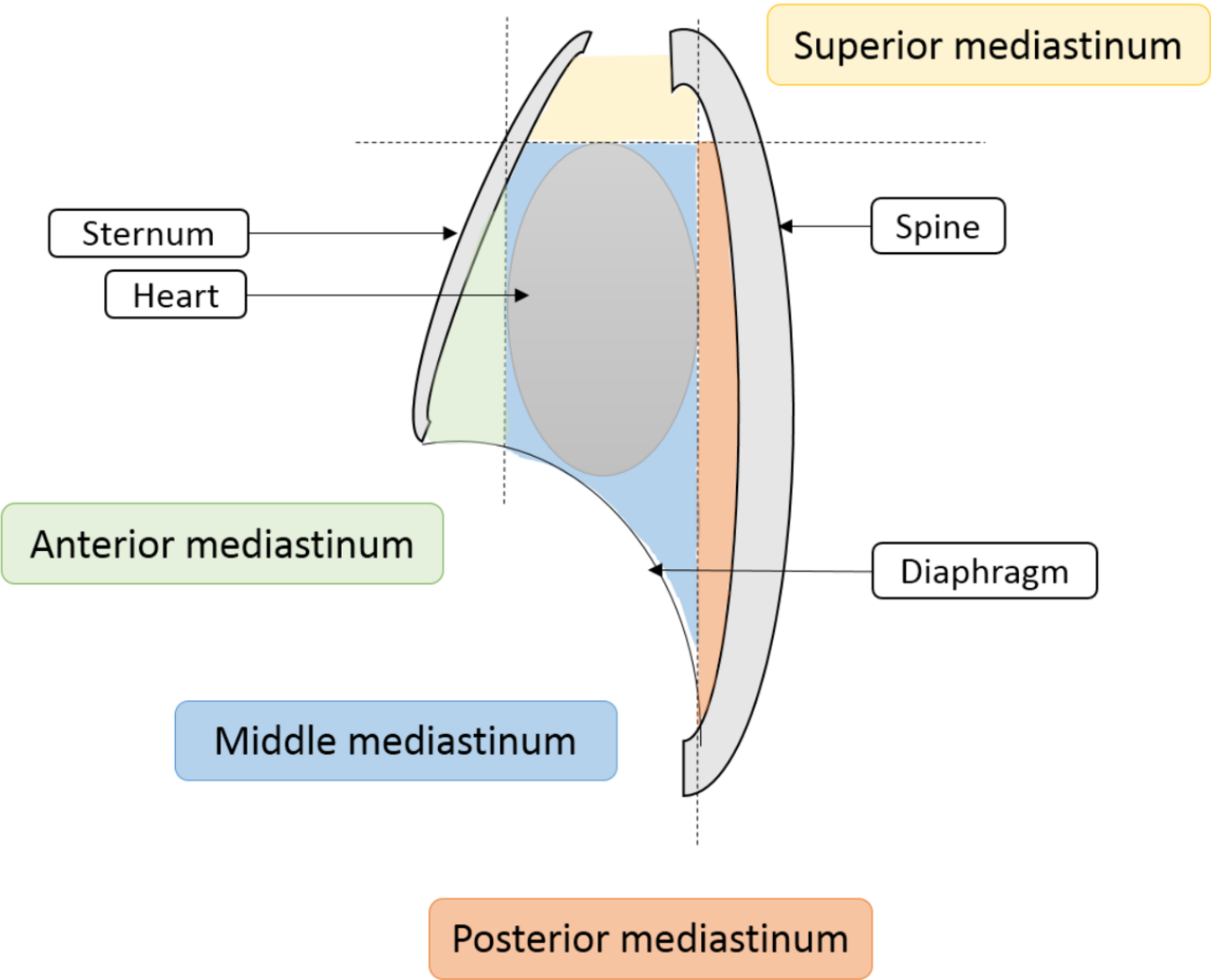
Insufficient amount of data

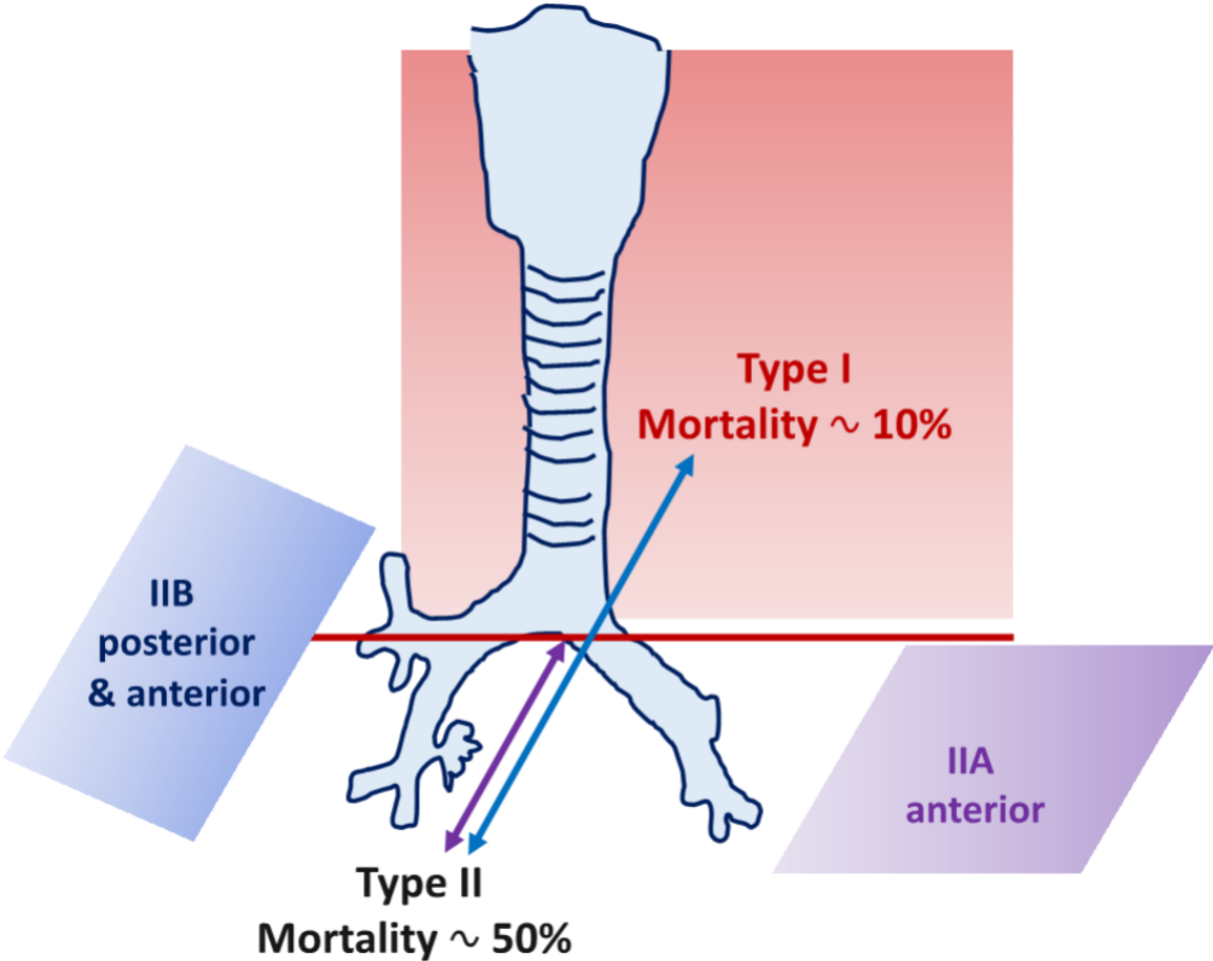
EXTENDED PubMed and Cochrane search :
expert opinion papers, guidelines, recommendations
and case series

n = 66

Inclusion of non ICU-specific papers

Inclusion of relevant references





SC 250mm

R

L

C1 66
W1 193

30509-52
-145.7mm

120kV, 199mAs
ST 21.1s
SW 5.5mm

Widening of the mediastinum

Mediastinal collection

Pneumomediastinum

37.3mm

73.3mm

5
cm

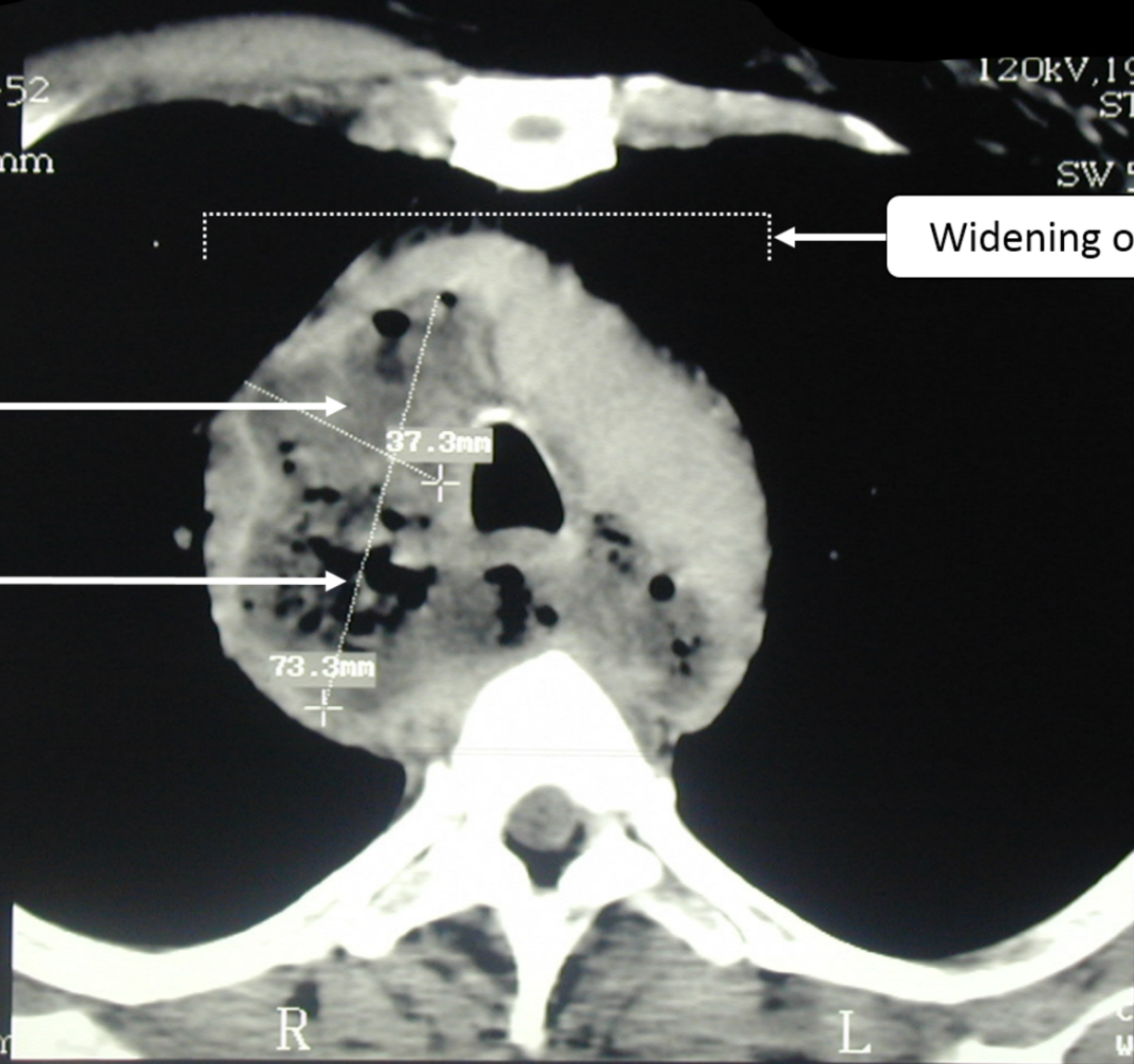
Z 2.24

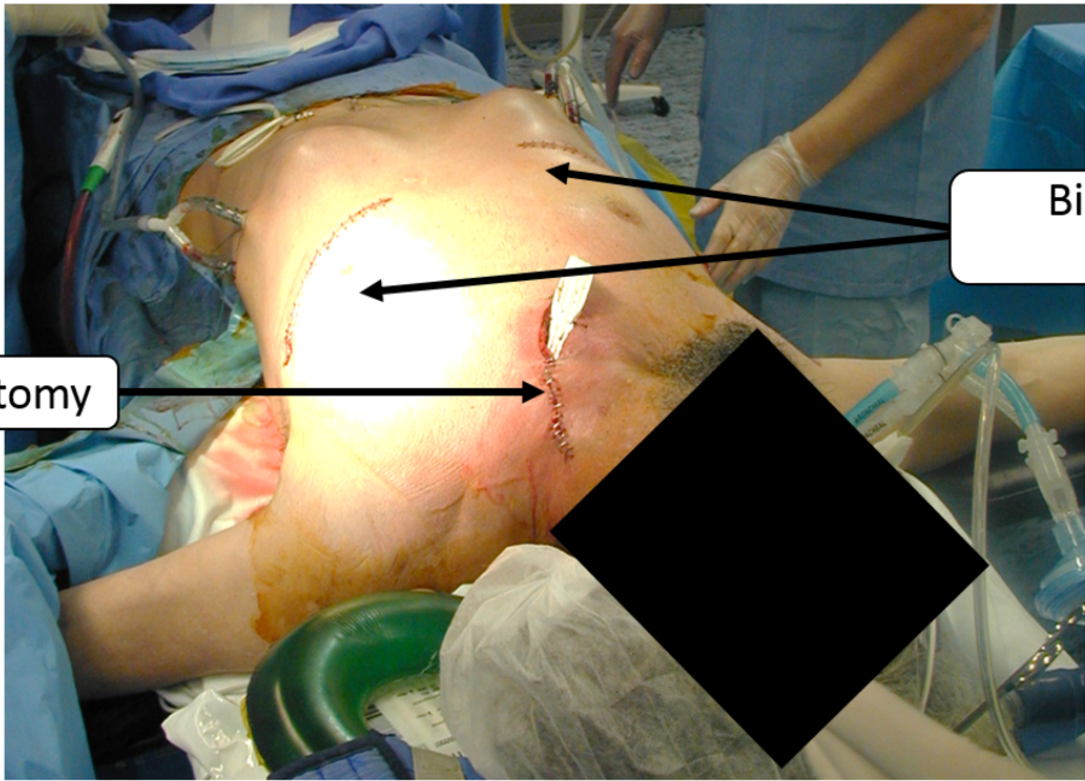
SC 430m

R

L

C1 84
W1 238





Cervicotomy

Bilateral anterolateral thoracotomy

Table 1.**Risk factors for mediastinitis**

| Etiology | Patient related risk factors | Procedure related risk factors |
|-------------------------------|---------------------------------------|---|
| DSWI | Old age | Use of ventricular assist device |
| | Obesity | Transplantation surgery |
| | Elevated creatinine | Redo surgery |
| | Peripheral vascular disease | Bilateral internal mammary artery graft |
| | S.aureus colonization | Length of surgery |
| | Diabetes mellitus | Aortic cross clamping |
| | Hyperglycemic episodes | Length of on-pump perfusion |
| | Chronic obstructive pulmonary disease | |
| | Smoking | |
| | Heart failure | |
| | Female gender | |
| Esophageal perforation | Abnormal esophageal tissues | Pneumatic dilatation |
| Anastomotic leakage | Female gender | Cervical anastomosis |
| DNM | Smoking | Circumference and surface of defect |
| | Sepsis | Extent of the defect |
| | Time from diagnosis | |
| | Impaired immune function | |
| | Reduced tissue oxygenation | |
| | Oral intake of glucocorticoids | |

Table 2.

Microbiological flora of mediastinitis according to disease etiology

| Type of infection | Deep sternal wound infection | Descending necrotizing mediastinitis | Esophageal perforation |
|----------------------|---|--|---|
| Gram positive | Methicillin-susceptible <i>S. aureus</i> | <i>Streptococcus</i> sp. <i>S. aureus</i> | <i>Viridans streptococci</i> including <i>S. salivarius</i> , <i>S. mutans</i> , <i>S. mitis</i> , <i>S. sanguinis</i> , <i>S. anginosus</i> |
| | Coagulase-negative <i>Staphylococcus</i> | <i>Streptococcus pyogenes</i> <i>Streptococcus pneumoniae</i> | |
| | <i>Streptococcus</i> sp. | <i>Peptostreptococcus</i> | |
| | Methicillin-resistant <i>S. aureus</i> | | |
| | | | |
| Gram negative | Enterobacteriaceae | <i>Hemophilus influenzae</i> | <i>Neisseria</i> sp. |
| | Non-fermenting bacteria including <i>Pseudomonas aeruginosa</i> and <i>Acinetobacter baumannii</i> | <i>Pseudomonas aeruginosa</i> <i>Escherichia coli</i> <i>Moraxella catarrhalis</i> <i>Fusobacterium</i> sp. | <i>Hemophilus</i> sp. <i>Prevotella</i> sp. <i>Fusobacterium</i> sp. |
| | | <i>Fusobacterium</i> sp. | |
| | | <i>Prevotella</i> sp. | |
| | | | |
| Others | <i>Candida</i> sp. | <i>Actinomyces</i> | |

Table 3.**Suggested antimicrobial therapy for mediastinitis according to disease etiology**

| Type of infection | Deep sternal wound infection | Descending necrotizing mediastinitis | Esophageal perforation |
|-------------------|--|--|---|
| First line | “Piperacillin/Tazobactam” or “Third-generation cephalosporin” + “Glycopeptid or Linezolid” | “Third-generation Cephalosporin + Metronidazole” | “Piperacillin/Tazobactam” or “Third-generation Cephalosporin + Metronidazole” |
| Optional | . | | Antifungals |

Table 4.**Main Supportive measures for the treatment of mediastinitis**

| Etiology | Action | Management |
|---|-------------------|---------------------------------------|
| Deep Sternal Wound Infection | Prevention | Pre-operative antibiotic prophylaxis |
| | | Routine S.aureus eradication |
| | | Perioperative glycemic control |
| | Wound Management | Negative pressure wound therapy |
| Esophageal perforation | Nutrition | Early enteral nutrition when feasible |
| | | Total parenteral nutrition if needed |
| | Pharmacological | Proton pump inhibitors |
| | Interventional | Endoscopic management |
| | | Negative pressure wound therapy |
| Descending necrotizing mediastinitis | Airway Management | Early tracheotomy |