



HAL
open science

Functioning gonadotroph adenoma with severe ovarian hyperstimulation syndrome: A new emergency in pituitary adenoma surgery? Surgical considerations and literature review

Thomas Graillon, Frederic Castinetti, Veronique Chabert-Orsini, Isabelle Morange, Thomas Cuny, Frédérique Albarel, Thierry Brue, Henry Dufour

► To cite this version:

Thomas Graillon, Frederic Castinetti, Veronique Chabert-Orsini, Isabelle Morange, Thomas Cuny, et al.. Functioning gonadotroph adenoma with severe ovarian hyperstimulation syndrome: A new emergency in pituitary adenoma surgery? Surgical considerations and literature review. *Annales d'Endocrinologie*, 2019, 80 (2), pp.122-127. 10.1016/j.ando.2018.11.007 . hal-02461458

HAL Id: hal-02461458

<https://amu.hal.science/hal-02461458>

Submitted on 22 Oct 2021

HAL is a multi-disciplinary open access archive for the deposit and dissemination of scientific research documents, whether they are published or not. The documents may come from teaching and research institutions in France or abroad, or from public or private research centers.

L'archive ouverte pluridisciplinaire **HAL**, est destinée au dépôt et à la diffusion de documents scientifiques de niveau recherche, publiés ou non, émanant des établissements d'enseignement et de recherche français ou étrangers, des laboratoires publics ou privés.



Distributed under a Creative Commons Attribution - NonCommercial 4.0 International License

Functioning gonadotroph adenoma with severe ovarian hyperstimulation syndrome: A new emergency in pituitary adenoma surgery? Surgical considerations and literature review

Adénome hypophysaire gonadotrope sécrétant avec syndrome d'hyperstimulation ovarienne sévère : une nouvelle urgence en chirurgie hypophysaire ? Considérations chirurgicales et revue de la littérature

Thomas Graillon^{1,3} MD, PhD, Frédéric Castinetti^{2,3} MD, PhD, Véronique Chabert-Orsini⁴ MD, Isabelle Morange² MD, Thomas Cuny^{2,3} MD, PhD, Frédérique Albarel² MD, Thierry Brue^{2,3} MD, PhD, Henry Dufour^{1,3} MD

¹ Assistance Publique - Hôpitaux de Marseille (AP-HM), Department of Neurosurgery, Hôpital La Timone, Marseille, France

² Assistance Publique - Hôpitaux de Marseille (AP-HM), Department of Endocrinology, Hôpital de la Conception, Centre de Référence des Maladies Rares Hypophysaires HYPO, 13005 Marseille, France

³ Aix Marseille Université, Institut National de la Santé et de la Recherche Médicale (INSERM), U1251, Marseille Medical Genetics (MMG), Marseille, France

⁴ Institute of Reproductive Medicine, 6 rue Rocca, 13008, Marseille, France

	substantial contributions to conception and design	acquisition of data	analysis and interpretation of data	"drafting the article	revising it critically for important intellectual content	final approval of the version to be published
Thomas Graillon	+	+	+	+		
Frédéric Castinetti			+	+	+	
Véronique Chabert-Orsini		+	+			
Isabelle Morange		+	+			
Thomas Cuny		+	+			
Frédérique Albarel		+	+			
Thierry Brue			+	+	+	
Henry Dufour			+	+	+	

Corresponding Author: Thomas Graillon
Neurosurgery department Timone Hospital Adults, 264 rue St Pierre, 13005 Marseille, France
tom.graillon@free.fr
tel: +33646656599
fax +33491384235

Short title: Functioning Gonadotroph Adenoma with Ovarian Hyperstimulation Syndrome

Titre court: Adénome hypophysaire gondotrope sécrétant avec Syndrome d'hyperstimulation ovarienne

Abstract word count= 284

Text word count=2242

Caractères espaces compris: 14933

Number of references=39

Number of tables and/or figures (total)= 6 fig/table(total)

Number of videos=0

Abstract

The authors reported 2 cases of functioning gonadotroph pituitary adenoma (FGPA) revealed by an ovarian hyperstimulation syndrome (OHSS) in young women. In the first case, OHSS was observed after GnRH analog injection. Pelvic echography revealed multiple voluminous ovarian cysts. Dopamine agonist posology failed in estradiol hypersecretion control, which necessitated endoscopic endonasal transsphenoidal surgery. The patient experienced improvement in pelvic pain as estradiol hypersecretion decreased during the first few postoperative days. Outcome was favorable, and her menstrual cycle was normal after two months. The second case was a young girl with spontaneous pelvic pain and elevated plasma FSH and estradiol levels. FGPA was confirmed on cerebral MRI. Dopamine agonists were introduced, and surgical removal of the tumor was scheduled for 7 days later. In the meantime, the patient was admitted and underwent surgery for bilateral adnexal torsion related to OHSS. The tumor was removed one week later. Outcome was favorable, and estradiol and FSH plasma levels were normal after 3 months. The ovarian cysts were no longer visible on echography after 3 months.

Given the lack of efficacy of the current standard medical therapy, surgical removal of pituitary adenomas is the reference treatment for FGPA. The authors suggest that severe OHSS related to FGPA should be considered as a relative surgical emergency and that surgery should not be unduly delayed, given the unpredictable risk of adnexal torsion, particularly in case of voluminous ovarian cysts. The authors performed a literature review on this topic.

Keywords: adnexal torsion; gonadotroph; ovarian hyperstimulation syndrome; pituitary adenoma; secreting

Résumé

Les auteurs rapportent 2 cas d'adénome hypophysaire gonadotrope sécrétant (AHGS), révélés par un syndrome d'hyperstimulation ovarienne (SHSO). Dans le premier cas, le SHSO a été observé après injection d'analogie de GnRH. L'échographie pelvienne a révélé des kystes ovariens multiples et volumineux. Le traitement par agoniste dopaminergique n'a pas permis le contrôle de l'hypersécrétion d'œstradiol, conduisant à la réalisation d'une chirurgie endoscopique endonasale et trans-sphénoïdale. L'amélioration des douleurs pelviennes s'est accompagnée d'une diminution de l'hypersécrétion d'œstradiol au cours des premiers jours postopératoires. L'évolution a été favorable et son cycle menstruel s'est normalisé après deux mois. Le deuxième cas est une jeune fille avec une douleur pelvienne spontanée et une élévation des taux plasmatiques de FSH et d'œstradiol. La présence d'un AHGS a été confirmée sur l'IRM cérébrale. Des agonistes dopaminergiques ont été introduits et l'exérèse chirurgicale de la tumeur a été planifiée 7 jours plus tard. Dans l'intervalle, la patiente a été admise en urgence et opérée pour une torsion bilatérale des annexes. La tumeur hypophysaire a été opérée une semaine plus tard. L'évolution a été favorable. Les taux plasmatiques d'œstradiol et de FSH se sont normalisés dans les 3 mois. Les kystes ovariens n'étaient plus visibles à l'échographie à 3 mois.

Compte tenu du manque d'efficacité du traitement médical standard actuel, l'exérèse chirurgicale est le traitement de référence des AHGS. Les auteurs suggèrent qu'un syndrome d'hyperstimulation ovarienne sévère en lien avec un AHGS doit être considéré comme une urgence chirurgicale relative et que la chirurgie ne devrait pas

être abusivement retardée compte tenu du risque imprévisible de torsion d'annexe, en particulier en cas de kystes ovariens volumineux. Les auteurs ont effectué une revue de la littérature sur ce sujet.

Mots-clés: adénome hypophysaire ; gonadotrope ; sécrétant ; syndrome d'hyperstimulation ovarienne ; torsion d'annexe

Introduction

Functioning gonadotroph pituitary adenomas (FGPAs) are defined according to the expression and secretion of biologically active gonadotrophins. FGPAs are rare. The first case of FGPA was reported in 1995 (1). The prevalence of FGPA is estimated to be 2.9–8.1% of all non-functioning pituitary and gonadotroph adenomas (2). FGPAs are principally symptomatic in premenopausal women and young girls. Ovarian hyperstimulation syndrome (OHSS) leads to an increase in abdominal waist circumference due to an increase in ovarian cyst volume as well as abdominal and pelvic pain, which can be either chronic or acute. In contrast, in menopausal women, ovarian insensitivity to FSH leads to FSH hypersecretion with few symptoms. In this short manuscript, we report two cases of OHSS induced by FGPA.

Methods

These two cases were selected from our database of pituitary adenomas that were surgically removed in the last 3 years. Pre- and postoperative clinical and biological data were collected.

Patients and cases description

The first case is a 36-year-old woman who underwent medically assisted procreation, conjoint infertility analysis, and ultimately, *in vitro* fertilization. Menses were regular without galactorrhea. Moderate increased prolactin (36 ng/ml, normal value < 20 ng/ml) led to a cerebral MRI, which revealed a 5-mm microadenoma. Cabergoline was rapidly initiated (half a tablet/week), which resulted in a normal prolactin level. An injection of a GnRH analog was performed for assisted procreation procedures (decapeptyl 3 mg IM). Two weeks after the

GnRH analog injection without gonadotrophin, the patient presented with an obvious clinical and radiological OHSS. Interestingly, the FSH levels were clearly increased. The estradiol level was 22,357 pg/ml, the progesterone level was 14.86 ng/ml, and beta HCG was negative at day 15 (table 1). The following day, the estradiol level was 25,000 pg/ml, the progesterone level was 18.46 ng/ml, and the prolactin level was 6.8 ng/ml. A pelvic ultrasound revealed a large ovarian diameter of 11 cm with follicles > 30 mm. At day 24 after the GnRH analog injection, estradiol increased to 31,293 pg/ml and progesterone increased to 22.58 ng/ml. The pelvic ultrasound again showed a large ovarian diameter, which had increased to more than 15 cm. Preventive anticoagulation was introduced and cabergoline was increased to 1 tablet/week. Cerebral MRI showed a 13-mm grade II A Knosp 1 pituitary macroadenoma (Fig.1). The volume was increased compared with that on the initial MRI. Visual examination was normal. Endoscopic transsphenoidal surgery was performed, which resulted in complete tumor removal. A neuropathologist observed anti-FSH immunostaining in 15% of the adenomatous cells, whereas chromogranin A was diffusely positive. The proliferation index was 2%, and P53 expression was absent. Postoperative levels of FSH, estradiol, and prolactin were normal (table 1). No new pituitary deficiency was observed. Mild hyponatremia was observed at day 3 and was managed with water deprivation and salt supply. Estradiol and progesterone levels were normal at 1 month. Pelvic pain was significantly decreased from the first postoperative day. Abdominal echography at postoperative day 3 showed a decrease in volume of different ovarian cysts (9 x 3 cm for the right ovary and 10 x 5 cm for the left ovary). Menses returned after 2 months. After three months, an MRI of the pituitary did not reveal any residual pituitary adenoma. After four months, abdominal ultrasound showed normal ovaries without cysts. The long-term outcome was favorable, and the *in vitro* fertilization procedure was performed 5 months after surgery.

The second case is a 29-year-old woman who presented with multiple ovarian cysts that were diagnosed based on abdominal and pelvic pain. A hypophysiogram revealed an increase in FSH and estradiol, a suppressed LH level, and a 2-fold increase in prolactin (table 2). An MRI of the pituitary showed a 23-mm pituitary macroadenoma (fig.2). Treatment with cabergoline (1/2 tablet every week) was initiated while the patient awaited surgery, which was planned for 7 days after treatment initiation. However, 3 days after the diagnosis, she was admitted for acute pelvic pain: a pelvic MRI revealed the presence of large ovarian cysts and a suspected right adnexal torsion (fig.3). Bilateral adnexal detorsion was performed via coeloscopy, and resulted in a favorable outcome. One week later, the patient was transferred to the neurosurgery unit where she underwent endoscopic transsphenoidal surgery with complete tumor removal. The pituitary adenoma was soft, and the sella turcica was filled with abdominal fat related to peroperative CSF leak. The outcome was favorable in this case. A neuropathologist observed FSH immunostaining in 40% of adenoma cells, whereas chromogranin A was diffusely expressed. The proliferation index was 2%, and P53 expression was absent. At 3 months, no pituitary deficiency was observed, and the ovarian cysts had resolved. No residual tumor was observed on a MRI at 3 months (fig.2). Five months later, the patient became pregnant spontaneously. The pregnancy was uneventful, and the long-term outcome was favorable.

Discussion and literature review

Clinical symptoms at diagnosis

Most FGPA's are diagnosed in premenopausal women. The most frequent clinical symptoms are menstrual irregularity (including secondary amenorrhea, oligomenorrhea, spontaneous vaginal spotting, or severe menorrhagia), infertility, galactorrhea, and OHSS, the symptoms

of which include abdominal and pelvic pain, bloating, and multiple ovarian cysts. Pelvic ultrasound or MRI might be helpful for showing large multi septated cysts (> 5 cm) on both ovaries, which may have a “soap-bubble” or “wheel-spoke” appearance. OHSS is a classical complication of assisted reproductive procedures. In the first case, the OHSS was revealed and diagnosed after the injection of GnRH, which led to an exacerbation of the OHSS. OHSS induced by a GnRH agonist and the subsequent diagnosis of FGPA was previously reported (3, 4). In 2 cases, OHSS was also diagnosed during pregnancy (5, 6).

FGPA has been rarely reported in post-menopausal women. After approximately 45 years of age, high FSH levels usually do not modify ovarian function and estrogen secretion. As in a non-functioning PA, mass effect and visual disturbance are the most frequent revealing symptoms.

Only rare cases have been reported in children (precocious puberty) and males (testicular enlargement or tumoral syndrome).

Biology at diagnosis

A high estrogen level and a high or paradoxical non-decreased FSH level are classically observed. The FSH level is usually increased whereas the LH level is low; this is related to negative feedback and antehypophyseal deficiency even in cases of LH-positive immunoreactivity (1, 5, 7-10). The variable increase in prolactin is due to pituitary stalk disconnection, hyperandrogenism and an increase in estradiol. In the literature review by Hallupzock et al., FSH was normal in 17/31 cases and was increased in 14/31 cases; LH was decreased in 27/32 patients, estradiol was elevated in 29/32 cases, and prolactin was increased in 24/27 patients (11). Rare cases of OHSS with normal FSH and estradiol levels with probable low-secreting gonadotroph pituitary adenomas were also reported (4, 9, 12). This biological profile is the distinguishing feature of polycystic ovary syndrome (PCOS), in which

LH is usually increased relative to FSH and testosterone is increased. Finally, the size of the ovarian cysts usually remains smaller than 10 mm in PCOS vs greater than 15 mm in OHSS (11). Hyperandrogenism is predominant in PCOS, and hyperestrogenism is predominant in OHSS. An LH-secreting gonadotroph pituitary adenoma was also reported (13). In males, FSH elevation is associated with normal, low, or elevated LH and testosterone levels. Decreased testosterone is related primarily to hyperprolactinemia and hypogonadism (14).

Risk of OHSS

Severe forms of OHSS could be life-threatening and may be associated with hypovolemic shock, renal failure, adult respiratory distress syndrome, and thromboembolism (6, 15, 16). Fluid shift to a third sector and ascites are also described. Adnexal torsion occurred in a case of multiple and voluminous cysts. As reported, acute abdomen related to adnexal torsion could lead to an extremely emergent situation that requires acute surgical management with coelioscopic detorsion or salpingo-oophorectomy (14). This severe complication is unpredictable. However, multiple and voluminous cysts lead to a high short-term risk, which strongly suggests that the pituitary adenoma be removed with very little delay (16). The data from the literature showed that adnexal torsion mainly occurs in ovarian cysts greater than 5 cm: 5 to 22 cm (9 cases) in the study by Gorkemli et al. (17), 9–10 cm (1 case) in the study by Gil Navarro et al. (18), and 5.7–17.5 cm (5 cases) in the study by Spitzer et al. (19). The cyst diameter threshold remains difficult to establish given that the cyst diameter in OHSS induced by a gonadotroph pituitary adenoma is usually greater than 5 cm (11). Of note, in our 2 cases, the short-term outcome of OHSS after pituitary surgery was favorable. A decrease in cyst volume was observed during the first several postoperative days, which in turn decreased the risk of adnexal torsion. The resolution of ovarian cysts and OHSS occurred mostly in the first postoperative month.

Differential diagnosis

One case of ectopic FSH secretion in a carcinoid tumor was reported (20), but the main differential diagnosis of OHSS is PCOS, as described above. However, pregnancy should always be considered.

Neuropathology

Macroadenomas are described most often, but some cases of microadenomas have also been reported. The pathological features of FGPA are similar to those of non-functioning pituitary adenomas. Usually, there is a majority of FSH-immunopositive cells, and even some cases that lack LH and FSH immunostaining have been reported. The difference in the mechanism of FSH secretion between functioning and non-functioning pituitary adenoma remains uncertain. Although our 2 FGPA cases did not show aggressive or invasive features, several cases of invasive and recurrent GPA were reported in the literature (8, 21-23).

Surgical considerations

Transsphenoidal surgery is the first-line treatment for FGPA. The outcome is particularly favorable in cases of total removal. The estradiol level usually returns to normal within the first week. Clinical symptoms of OHSS improve during the first several postoperative days. Moreover, the cyst volume begins to decrease during the first several postoperative days. In our 2 patients, cysts were no longer visible on ultrasound 3–4 months after surgery. In these 2 cases, OHSS induced by FGPA was cured by surgery. One patient became pregnant only a few months after surgery; the pregnancy was uneventful. Cases of early spontaneous

pregnancy after transsphenoidal surgery have been reported, which suggests a favorable endocrinological outcome (3, 5, 7, 10, 24, 25). No postoperative pituitary deficiency was observed in our 2 cases, and only transient and minor hyponatremia was seen. The operative features seem similar to those of non-functioning gonadotroph adenomas. In cases of cavernous sinus invasion, incomplete tumor removal might require complementary treatment. Radiotherapy and radiosurgery are efficient and are therefore recommended (1, 8, 21, 22, 26-28). As previously mentioned, our 2 cases did not exhibit any aggressive or invasive features. Nevertheless, cases of aggressive and recurrent FGPA, which require iterative surgery and radiotherapy/radiosurgery, are reported in the literature (8, 21-23).

Timing of surgery

As reported previously, OHSS could lead to life-threatening situations. The lack of effective medical therapy suggests pituitary surgery as a first-line therapy. In cases of severe OHSS or voluminous ovarian cysts greater than 5 cm, the authors suggest not delayed pituitary surgery to avoid complications such as adnexal torsion. In the postoperative period, the decrease in the plasma estradiol concentration considerably decreases the risk of adnexal torsion within the first several postoperative days. Therefore, in cases of severe OHSS, short-term pituitary surgery should be preferred to transient dopamine agonist therapy and delayed pituitary surgery.

Medical management

No medical therapy is currently proven efficient for FGPA. D2DR expression was demonstrated in FSH-secreting FGPA, but the expression pattern of dopamine receptors remains uncertain (29). Dopamine agonists seem to be the most pertinent drugs for this

indication. Treatment with DAs led to decreased FSH and estradiol levels, and in some cases, allowed pregnancy (29-32). However, the effect is mostly transient and moderate and is clearly not a substitute for surgical treatment (33, 34). In our second case, DAs failed to control OHSS and the prevention of adnexal torsion.

GnRH agonists were demonstrated to provide a short-term increase in FSH/LH secretion and therefore an increase in estradiol secretion, and in one case, an increase in tumor volume (31). Moreover, GnRH agonists pose a risk of apoplexy (35).

Although SST2-3 and SST2-3-5 expression was demonstrated in an FSH-secreting FGPA and an LH/PRL-secreting pituitary adenoma, respectively, the expression pattern of somatostatin receptors remains uncertain (36, 37). Octreotide injection was demonstrated efficient in one case (22). In another case, treatment with octreotide combined with a DA over 7 months decreased the tumor volume (36). An interest in somatostatin agonists remains.

Patient outcome

In our 2 cases, total surgical removal without hormonal deficiency led to an excellent outcome: one patient was pregnant 5 months later, while the other patient was able to undergo an *in vitro* fertilization procedure 5 months after surgery. The data from the literature demonstrated a favorable endocrine and tumoral outcome. Some cases of aggressive and recurrent FGPA might lead to complex therapeutic situations, but those cases are rare (1, 21-23). Therefore, long-term follow-up with biological and imaging surveillance is required.

Conclusion

The authors reported two cases of OHSS related to FSH-secreting FGPA. OHSS was spontaneous in one case and was revealed by GnRH injection in the other case. OHSS was complicated in one case by a bilateral adnexal torsion. Dopamine agonists were non-efficient in the two cases. Surgical removal of pituitary adenoma remains the preferred treatment and should not be delayed in cases of severe OHSS in order to prevent the occurrence of OHSS-related complications.

Disclosure

The authors report no conflict of interest concerning the materials or methods used in this study or the findings specified in this paper

References

1. Djerassi A, Coutifaris C, West VA, Asa SL, Kapoor SC, Pavlou SN, et al. Gonadotroph adenoma in a premenopausal woman secreting follicle-stimulating hormone and causing ovarian hyperstimulation. *J Clin Endocrinol Metab.* 1995 Feb;80(2):591-4.
2. Caretto A, Lanzi R, Piani C, Molgora M, Mortini P, Losa M. Ovarian hyperstimulation syndrome due to follicle-stimulating hormone-secreting pituitary adenomas. *Pituitary.* 2017 Oct;20(5):553-60.
3. Castelbaum AJ, Bigdeli H, Post KD, Freedman MF, Snyder PJ. Exacerbation of ovarian hyperstimulation by leuprolide reveals a gonadotroph adenoma. *Fertil Steril.* 2002 Dec;78(6):1311-3.
4. Kihara M, Sugita T, Nagai Y, Saeki N, Tatsuno I, Seki K. Ovarian hyperstimulation caused by gonadotroph cell adenoma: a case report and review of the literature. *Gynecol Endocrinol.* 2006 Feb;22(2):110-3.
5. Ghayuri M, Liu JH. Ovarian hyperstimulation syndrome caused by pituitary gonadotroph adenoma secreting follicle-stimulating hormone. *Obstet Gynecol.* 2007 Feb;109(2 Pt2):547-9.
6. Baba T, Endo T, Kitajima Y, Kamiya H, Moriwaka O, Saito T. Spontaneous ovarian hyperstimulation syndrome and pituitary adenoma: incidental pregnancy triggers a catastrophic event. *Fertil Steril.* 2009 Jul;92(1):390 e1-3.
7. Sicilia V, Earle J, Mezitis SG. Multiple ovarian cysts and oligomenorrhea as the initial manifestations of a gonadotropin-secreting pituitary macroadenoma. *Endocr Pract.* 2006 Jul-Aug;12(4):417-21.
8. Roberts JE, Spandorfer S, Fasouliotis SJ, Lin K, Rosenwaks Z. Spontaneous ovarian hyperstimulation caused by a follicle-stimulating hormone-secreting pituitary adenoma. *Fertil Steril.* 2005 Jan;83(1):208-10.
9. Shimon I, Rubinek T, Bar-Hava I, Nass D, Hadani M, Amsterdam A, et al. Ovarian hyperstimulation without elevated serum estradiol associated with pure follicle-stimulating hormone-secreting pituitary adenoma. *J Clin Endocrinol Metab.* 2001 Aug;86(8):3635-40.
10. Murakami T, Higashitsuji H, Yoshinaga K, Terada Y, Ito K, Ikeda H. Management of ovarian hyperstimulation due to follicle-stimulating hormone-secreting gonadotroph adenoma. *BJOG.* 2004 Nov;111(11):1297-300.

11. Halupczok J, Kluba-Szyszka A, Bidzinska-Speichert B, Knychalski B. Ovarian Hyperstimulation Caused by Gonadotroph Pituitary Adenoma--Review. *Adv Clin Exp Med*. 2015 Jul-Aug;24(4):695-703.
12. Kanaya M, Baba T, Kitajima Y, Ikeda K, Shimizu A, Morishita M, et al. Continuous follicle-stimulating hormone exposure from pituitary adenoma causes periodic follicle recruitment and atresia, which mimics ovarian hyperstimulation syndrome. *Int J Womens Health*. 2012;4:427-31.
13. Castelo-Branco C, del Pino M, Valladares E. Ovarian hyperstimulation, hyperprolactinaemia and LH gonadotroph adenoma. *Reprod Biomed Online*. 2009 Aug;19(2):153-5.
14. Cote DJ, Smith TR, Sandler CN, Gupta T, Bale TA, Bi WL, et al. Functional Gonadotroph Adenomas: Case Series and Report of Literature. *Neurosurgery*. 2016 Dec;79(6):823-31.
15. Grossman LC, Michalakis KG, Browne H, Payson MD, Segars JH. The pathophysiology of ovarian hyperstimulation syndrome: an unrecognized compartment syndrome. *Fertil Steril*. 2010 Sep;94(4):1392-8.
16. Delvigne A, Rozenberg S. Review of clinical course and treatment of ovarian hyperstimulation syndrome (OHSS). *Hum Reprod Update*. 2003 Jan-Feb;9(1):77-96.
17. Gorkemli H, Camus M, Clasen K. Adnexal torsion after gonadotrophin ovulation induction for IVF or ICSI and its conservative treatment. *Arch Gynecol Obstet*. 2002 Nov;267(1):4-6.
18. Gil Navarro N, Garcia Grau E, Pina Perez S, Ribot Luna L. Ovarian torsion and spontaneous ovarian hyperstimulation syndrome in a twin pregnancy: A case report. *Int J Surg Case Rep*. 2017;34:66-8.
19. Spitzer D, Wirleitner B, Steiner H, Zech NH. Adnexal Torsion in Pregnancy after Assisted Reproduction - Case Study and Review of the Literature. *Geburtshilfe Frauenheilkd*. 2012 Aug;72(8):716-20.
20. Burgos J, Cobos P, Vidaurrazaga N, Prieto B, Ocerin I, Matorras R. Ovarian hyperstimulation secondary to ectopic secretion of follicle-stimulating hormone. Literature review prompted by a case. *Fertil Steril*. 2009 Sep;92(3):1168 e5-8.
21. Benito M, Asa SL, Livolsi VA, West VA, Snyder PJ. Gonadotroph tumor associated with multiple endocrine neoplasia type 1. *J Clin Endocrinol Metab*. 2005 Jan;90(1):570-4.
22. Karapanou O, Tzanela M, Tamouridis N, Tsagarakis S. Gonadotroph pituitary macroadenoma inducing ovarian hyperstimulation syndrome: successful response to octreotide therapy. *Hormones (Athens)*. 2012 Apr-Jun;11(2):199-202.
23. Pentz-Vidovic I, Skoric T, Grubisic G, Korsic M, Ivcevic-Bakulic T, Besenski N, et al. Evolution of clinical symptoms in a young woman with a recurrent gonadotroph adenoma causing ovarian hyperstimulation. *Eur J Endocrinol*. 2000 Nov;143(5):607-14.
24. Mor E, Rodi IA, Bayrak A, Paulson RJ, Sokol RZ. Diagnosis of pituitary gonadotroph adenomas in reproductive-aged women. *Fertil Steril*. 2005 Sep;84(3):757.
25. Sugita T, Seki K, Nagai Y, Saeki N, Yamaura A, Ohigashi S, et al. Successful pregnancy and delivery after removal of gonadotrope adenoma secreting follicle-stimulating hormone in a 29-year-old amenorrheic woman. *Gynecol Obstet Invest*. 2005;59(3):138-43.
26. Christin-Maitre S, Rongieres-Bertrand C, Kottler ML, Lahlou N, Frydman R, Touraine P, et al. A spontaneous and severe hyperstimulation of the ovaries revealing a gonadotroph adenoma. *J Clin Endocrinol Metab*. 1998 Oct;83(10):3450-3.
27. Tashiro H, Katabuchi H, Ohtake H, Kaku T, Ushio Y, Okamura H. A follicle-stimulating hormone-secreting gonadotroph adenoma with ovarian enlargement in a 10-year-old girl. *Fertil Steril*. 1999 Jul;72(1):158-60.
28. Chaidarun SS, Klibanski A. Gonadotropinomas. *Semin Reprod Med*. 2002 Nov;20(4):339-48.
29. Murata Y, Ando H, Nagasaka T, Takahashi I, Saito K, Fukugaki H, et al. Successful pregnancy after bromocriptine therapy in an anovulatory woman complicated with ovarian hyperstimulation caused by follicle-stimulating hormone-producing plurihormonal pituitary microadenoma. *J Clin Endocrinol Metab*. 2003 May;88(5):1988-93.
30. Paoletti AM, Depau GF, Mais V, Guerriero S, Ajossa S, Melis GB. Effectiveness of cabergoline in reducing follicle-stimulating hormone and prolactin hypersecretion from pituitary macroadenoma in an infertile woman. *Fertil Steril*. 1994 Oct;62(4):882-5.

31. Knoepfelmacher M, Danilovic DL, Rosa Nasser RH, Mendonca BB. Effectiveness of treating ovarian hyperstimulation syndrome with cabergoline in two patients with gonadotropin-producing pituitary adenomas. *Fertil Steril*. 2006 Sep;86(3):719 e15-8.
32. Gryngarten MG, Braslavsky D, Ballerini MG, Ledesma J, Ropelato MG, Escobar ME. Spontaneous ovarian hyperstimulation syndrome caused by a follicle-stimulating hormone-secreting pituitary macroadenoma in an early pubertal girl. *Horm Res Paediatr*. 2010;73(4):293-8.
33. Ambrosi B, Bassetti M, Ferrario R, Medri G, Giannattasio G, Faglia G. Precocious puberty in a boy with a PRL-, LH- and FSH-secreting pituitary tumour: hormonal and immunocytochemical studies. *Acta Endocrinol (Copenh)*. 1990 May;122(5):569-76.
34. Clemente M, Caracseghi F, Gussinyer M, Yeste D, Albisu M, Vazquez E, et al. Macroorchidism and panhypopituitarism: two different forms of presentation of FSH-secreting pituitary adenomas in adolescence. *Horm Res Paediatr*. 2011;75(3):225-30.
35. Chanson P, Schaison G. Pituitary apoplexy caused by GnRH-agonist treatment revealing gonadotroph adenoma. *J Clin Endocrinol Metab*. 1995 Jul;80(7):2267-8.
36. Ceccato F, Occhi G, Regazzo D, Randi ML, Cecchin D, Gardiman MP, et al. Gonadotropin secreting pituitary adenoma associated with erythrocytosis: case report and literature review. *Hormones (Athens)*. 2014 Jan-Mar;13(1):131-9.
37. Saveanu A, Morange-Ramos I, Gunz G, Dufour H, Enjalbert A, Jaquet P. A luteinizing hormone-, alpha-subunit- and prolactin-secreting pituitary adenoma responsive to somatostatin analogs: in vivo and in vitro studies. *Eur J Endocrinol*. 2001 Jul;145(1):35-41.

Figure Legends

Figure 1: First case: Preoperative cerebral MRI with coronal T2, T1 gadolinium, and sagittal T1 gadolinium sequences displayed a pituitary macroadenoma.

Premier cas: IRM cérébrale préopératoire avec séquence T2 et T1 avec injection de gadolinium coronale et T1 sagittale mettant en évidence un macroadénome hypophysaire.

Figure 2: Second case: Pre and postoperative cerebral MRI

Coronal and sagittal T2 MRI (A, B) revealed a pituitary macroadenoma. Three-month postoperative MRI with sagittal T2 (C), coronal T1 gadolinium (D) and T1 Fat-Sat (E) sequences showed pituitary adenoma removal and intrasellar filling with abdominal fat.

Second cas: IRM cérébrale pré et post-opératoire

IRM T2 coronale et sagittale (A, B) mettant en évidence un macroadénome hypophysaire. IRM hypophysaire à 3 mois avec séquences T2 sagittale (C), T1 gadolinium coronale (D) et T1 fat-sat (E) mettant en évidence l'exérèse de l'adénome hypophysaire ainsi que la présence de graisse intrasellaire.

Figure 3: Second case: Preoperative pelvic MRI (coronal (A-B) and axial (C) T2 sequences).

Adnexal volume was increased (6.5 x 4.2 x 6.6 cm on the left side and 15 x 10 x 6 cm on the right side) with multiple cysts. The right adnexal pedicle presented a turn of spire, and the right adnexal parenchyma was edematous and was not enhanced by gadolinium, which strongly suggests right adnexal torsion. Peritoneal effusion was also observed. Peroperative observation concluded to bilateral adnexal torsion.

Second cas: IRM pelvienne préopératoire (séquences coronale (A-B) et axiale T2 (C)).

Les ovaires sont volumineux (6.5 x 4.2 x 6.6 cm du côté gauche et 15 x 10 x 6 cm du côté droit) et présentent de multiples kystes. Le pédicule ovarien droit présente un tour de spire avec un parenchyme ovarien œdémateux et non rehaussé par le gadolinium, suggérant fortement une torsion de l'annexe droite. Une suffusion péritonéale est également observée. En peropératoire, il a été constaté une torsion d'ovaires bilatérale.

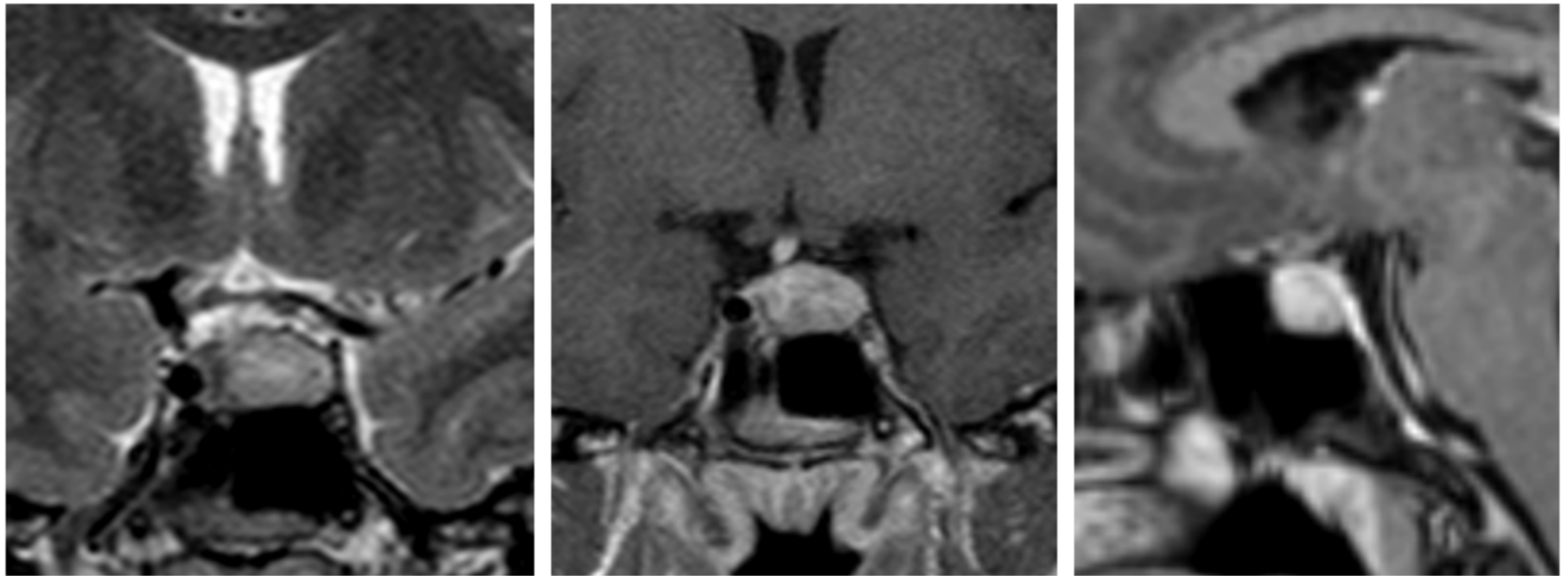
Table Legends

Table 1: Pre and postoperative results of endocrine tests for patient presented in the first case.

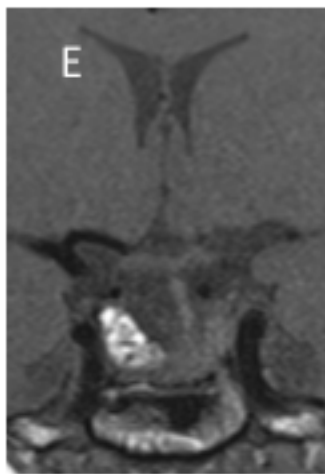
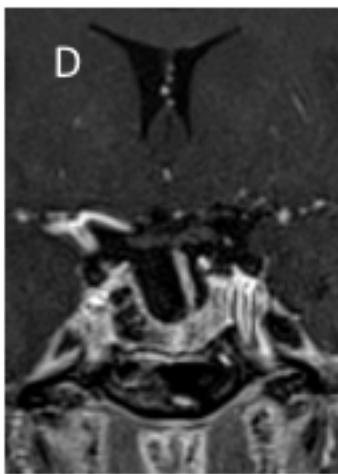
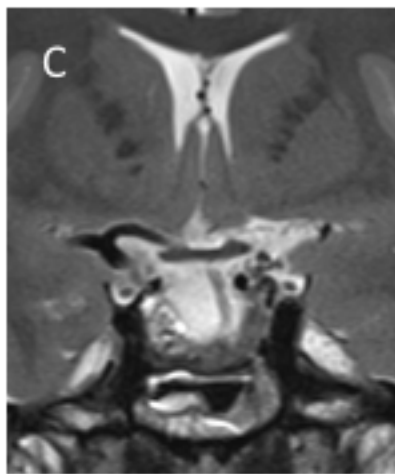
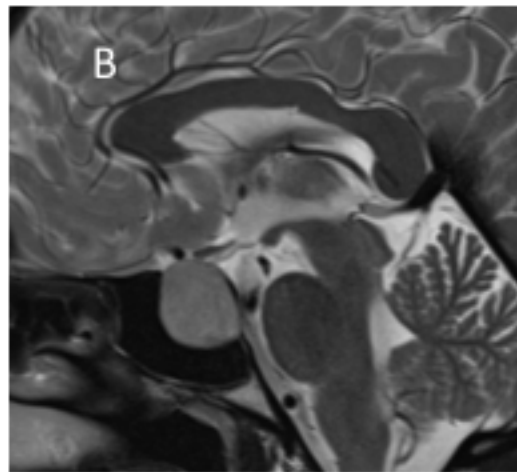
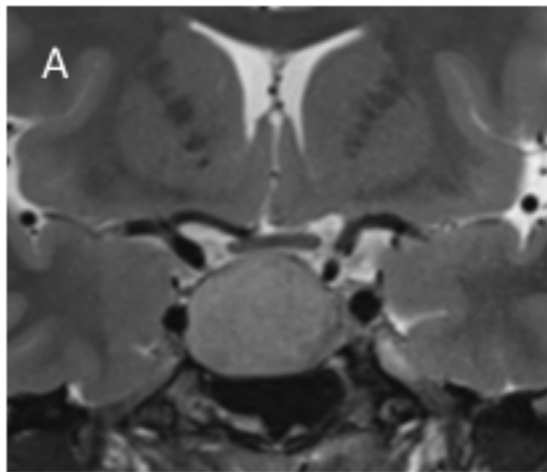
Bilan endocrinien pré et post-opératoire du premier patient présenté.

Table 2: Pre and postoperative results of endocrine tests for patient presented in the second case.

Bilan endocrinien pré et post-opératoire du second patient présenté.



Case 1: Preoperative cerebral MRI with coronal T2, T1 gadolinium and sagittal T1 gadolinium sequences displayed a pituitary macroadenoma.



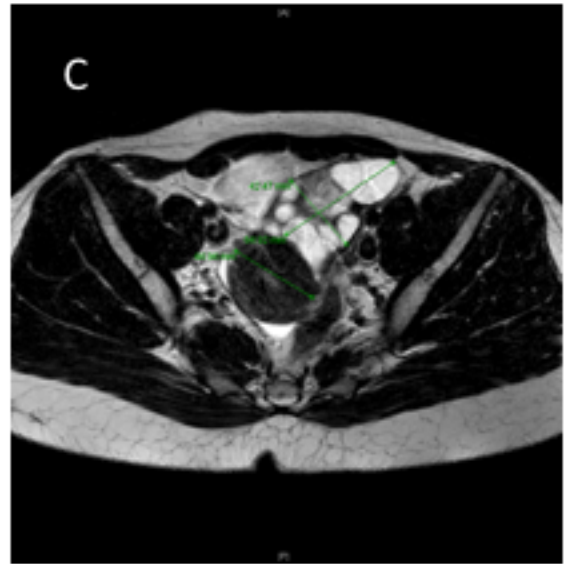
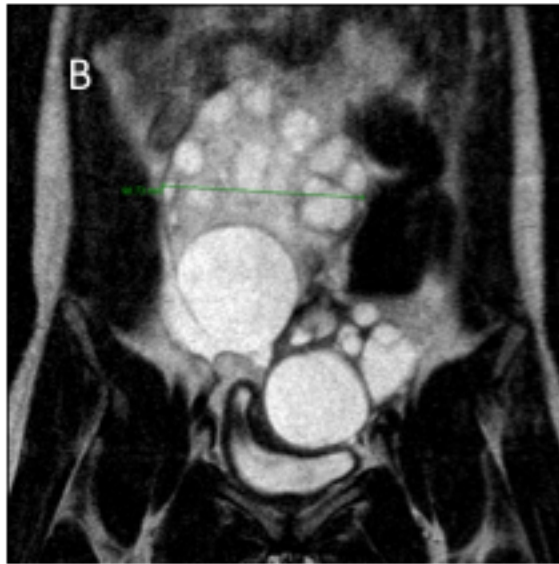
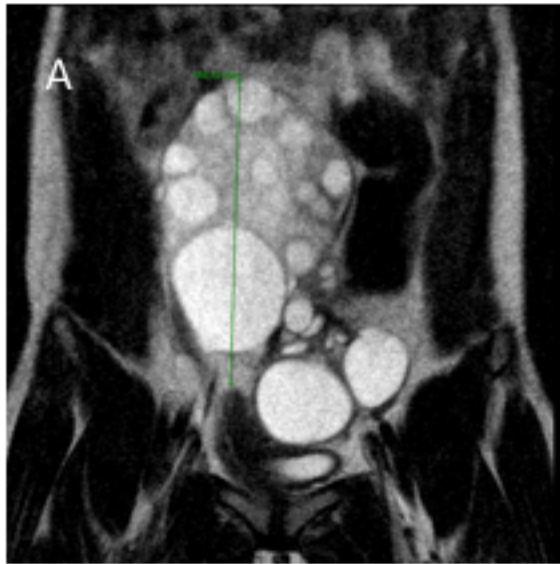

Table 1: Pre and postoperative results of endocrine tests for patient presented in the first case

	Before GnRH agonists inj	Day 15	Day 16	Day 24	Day 2 postop	Day 4 postop	Day 7 postop	1 month postop	3 months postop	Normal values
FSH (UI/L)	5,7	-	-	-	0.9	0.5	0.5	2.35	4.8	[1.7-21.5]
LH (UI/L)	5,4	-	-	-	<0.1	<0.1	<0.1	<0.1	4.8	[2.4-95.6]
Estradiol (pg/mL)	54	22357	25000	31293	1736.5	137.9	46.95	<11	81.1	[22.4-398]
Progesteron (ng/mL)	0,05	14,86	18, 46	22.58	-	-	-	>0,2	-	[0.06-23.9]
Prolactin (ng/mL)	4,4	-	6,8	-	5.9	7.4	6.8	-	24.6	[4.8-23.4]

Table 2 : Pre and postoperative results of endocrine tests for patient presented in the second case

	Preop	Day 3 postop	3 months postop	Normal values
FSH (UI/L)	11.6	1.4	11.7	[1.7-21.5]
LH (UI/L)	<0.1	0.6	17.5	[2.4-95.6]
Estradiol (pg/mL)	3248	98	162	[22.4-398]
Prolactin (ng/mL)	79.4	5.6	7.4	[4.8-23.4]