



HAL
open science

Prognostic significance of NAB2-STAT6 fusion variants and TERT promotor mutations in solitary fibrous tumors/hemangiopericytomas of the CNS: not (yet) clear

Rob Vogels, Nicolas Macagno, Klaus Griewank, Patricia Groenen, Marian Verdijk, Judy Fonville, Benno Kusters, Dominique Figarella-Branger, Pieter Wesseling, Corinne Bouvier, et al.

► To cite this version:

Rob Vogels, Nicolas Macagno, Klaus Griewank, Patricia Groenen, Marian Verdijk, et al.. Prognostic significance of NAB2-STAT6 fusion variants and TERT promotor mutations in solitary fibrous tumors/hemangiopericytomas of the CNS: not (yet) clear. *ACTA NEUROPATHOLOGICA*, 2019, 137 (4), pp.679-682. 10.1007/s00401-019-01968-3 . hal-02461460

HAL Id: hal-02461460

<https://amu.hal.science/hal-02461460v1>

Submitted on 20 Feb 2020

HAL is a multi-disciplinary open access archive for the deposit and dissemination of scientific research documents, whether they are published or not. The documents may come from teaching and research institutions in France or abroad, or from public or private research centers.

L'archive ouverte pluridisciplinaire **HAL**, est destinée au dépôt et à la diffusion de documents scientifiques de niveau recherche, publiés ou non, émanant des établissements d'enseignement et de recherche français ou étrangers, des laboratoires publics ou privés.

Prognostic significance of *NAB2-STAT6* fusion variants and *TERT* promotor mutations in solitary fibrous tumors/hemangiopericytomas of the CNS: Not (yet) clear.

Rob Vogels^{1,2*}, Nicolas Macagno^{3,4*}, Klaus Griewank⁵, Patricia Groenen¹, Marian Verdijk¹, Judy Fonville², Benno Kusters^{1,6}, French and Dutch CNS SFT/HPC Consortium⁷, Dominique Figarella-Branger^{3,8}, Pieter Wesseling^{9,10,11}, Corinne Bouvier^{3,4}, Uta Flucke^{1,10}

1. Department of Pathology, Radboud University Medical Center, Nijmegen, The Netherlands
2. Department of Pathology, Stichting PAMM, Eindhoven, The Netherlands
3. Department of Pathology and Neuropathology, Timone Hospital, APHM, Marseille, France
4. Aix-Marseille University, INSERM, MMG, Marseille, France
5. Department of Dermatology, University Hospital Essen, Essen, Germany
6. Department of Pathology, Maastricht University Medical Center, Maastricht, The Netherlands
7. Author information French and Dutch CNS SFT/HPC Consortium in Supplementary material
8. Aix-Marseille University, CNRS, INP, Inst Neurophysiopathol, Marseille, France
9. Department of Pathology, Amsterdam Universities Medical Center/VU University Medical Center, Amsterdam, The Netherlands
10. Princess Máxima Center for Pediatric Oncology, Utrecht, The Netherlands
11. Department of Pathology, University Medical Center Utrecht, Utrecht, The Netherlands

*Authors contributed equally to this work

Correspondence:

Rob Vogels

Department of Pathology, Radboud University Medical Center, Nijmegen, The Netherlands

Rob.Vogels@radboudumc.nl

Grading of meningeal solitary fibrous tumors/hemangiopericytomas (SFTs/HPCs) of the central nervous system (CNS) is nowadays based on histologic criteria as described in the revised fourth edition of the WHO Classification of CNS tumors [10] or the more recently published, updated version of the Marseille Grading System (MGS) [11]. Histology based grading of CNS SFTs/HPCs allows for discriminating subgroups with significant differences in prognosis. However, the often-piecemeal resection of these tumors may hamper adequate evaluation of mitotic activity and necrosis, and thereby assessment of malignancy grade. *NAB2-STAT6* fusion is the molecular hallmark of both soft tissue SFTs and CNS SFTs/HPCs, and the resulting fusion protein accumulates in the nucleus and acts as a transcriptional activator of early growth response mediated pathways with STAT6 immunohistochemistry being a very sensitive and specific tool for their diagnosis [5, 8, 12, 14]. For soft tissue SFTs, particular *NAB2-STAT6* fusion variants as well as telomerase reverse transcriptase (*TERT*) promoter mutations leading to telomerase activity and tumor cell immortalization have been reported to have prognostic value. Some studies have included CNS SFTs/HPCs in their cohort, but because of small numbers and lack of (long term) follow-up data the prognostic value of these markers for CNS SFTs/HPCs is still unclear [1–4, 6, 7, 9, 13, 15, 16].

To evaluate the prognostic value of *NAB2-STAT6* fusion variants and *TERT* promoter mutations for CNS SFTs/HPCs, we retrospectively analyzed these markers in a cohort of 136 patients with STAT6 nucleopositive CNS tumors. All tumors were graded according to the most recent WHO classification [10] and the updated MGS [11] and were analyzed for type of *NAB2-STAT6* fusion and the presence of *TERT* promoter mutation. For *NAB2-STAT6* fusion analysis, we performed reverse transcriptase polymerase chain reaction (RT-PCR) after RNA extraction and cDNA synthesis using multiple primer sets finding the most common fusion variants which were subsequently grouped based on their hypothesized functional effects [3, 15].

After DNA isolation, amplicons of 163 base pairs spanning *TERT* promoter hot-spot mutations at positions 1,295,228 and 1,295,250 on chromosome 5 were amplified by PCR using the primers hTERT-F CAG CGC TGC CTGAAA CTC and hTERT-R GTC CTG CCC CTT CAC CTT and subsequent sequencing of the products was performed. More detailed information on Materials and Methods is given in the Supplementary Information. For survival analyses, patients who died due to complications of initial therapy (e.g., surgery or radiotherapy) were excluded. Results of

Table 1 Results of *NAB2-STAT6* fusion analysis and *TERT* promoter mutation analysis: correlation with histological grading and extradural metastatic disease

	NAB2-STAT6						TERTp			
	All	Ex4-Ex2	Ex6-Ex16/17	Neg	NA	P value	WT	Mutation	NA	P value
MGS										
1	71	24	24	7	16		43	21	7	
2	54	4	29	10	11		34	15	5	
3	11	0	6	2	3		5	3	3	
Total	136					0.006				0.519
WHO										
I	24	13	1	1	9		15	8	1	
II	47	11	23	6	7		28	13	6	
III	65	4	35	12	14		39	18	8	
Total	136					< 0.0001				0.854
Extradural metastasis										
Yes	17	0	11	3	3		15	2	0	
No	57	13	33	4	7		33	16	8	
Total	74					0.121				0.09

Significant if *p* equal or below 0.05

NA not assessable, WT *TERT*p-wildtype, MGS updated Marseille Grading System

histological grading, analysis of *NAB2-STAT6* fusion and *TERT* promoter mutations and survival analysis are listed in Tables 1 and 2.

Table 2 Association of *NAB2-STAT6* fusion analysis and *TERT* promoter mutation analysis with survival

	No. of patients	PFS (months)			OS (months)		
		Mean	95% CI	Log-rank	Mean	95% CI	Log-rank
NAB2-STAT6							
All	128 ^a	124	93–155		346	255–436	
Ex4-Ex2	26	140	94–187		306	265–348	
Ex6-Ex16/17	55	131	83–178		307	186–428	
Neg	17	88	55–122		133	96–171	
NA	30	79	50–107		189	164–215	
				0.280			0.172
TERT_p							
All	128 ^a	124	93–155		346	255–436	
WT	77	126	85–166		266	151–382	
Mutation	36	111	71–151		237	198–275	
NA	15	90	93–155		272	190–356	
				0.635			0.107

PFS progression-free survival, OS overall survival, NA not assessable, WT *TERT_p*-wildtype

^a8 patients died due to complications of initial therapy (e.g., surgery or radiotherapy) and were excluded for survival analysis

Eighty-seven percent of the tumors could be analyzed for *NAB2-STAT6* fusion variants using RT-PCR ($n = 106$), in the remaining 30 cases RNA quality was insufficient. Of the 106 tumors, 26% had an exon4–exon2 fusion ($n = 28$) and 56% ($n = 59$) an exon6–exon16/17 fusion. In 18% of the tumors ($n = 19$), no fusion was detected, which may partly be due to our RT-PCR approach which did not cover all possible, rarely detected *NAB2-STAT6* fusion variants.

In our cohort, the *NAB2-STAT6* fusion variants are correlated to both WHO and MGS malignancy grade: The exon6–exon16/17 fusion is significantly more frequent in WHO grade II and III and MGS grade 2 and 3 tumors ($p < 0.0001$ and $p = 0.006$, respectively).

Information regarding extradural metastatic disease was available for 74 cases, and 17 of these patients had metastases during their follow-up. In this group of 17 patients, 11(64%) had a tumor with exon6–exon16/17 gene fusion and none an exon4–exon2 fusion. In three cases, no fusion could be detected with our RT-PCR approach and in three cases, RNA quality was insufficient. The results were not statistically significant ($p = 0.121$), possibly due to the limited number of patients with extradural metastatic disease ($n = 17$).

In addition, a non-significant trend ($p = 0.172$) towards shorter overall survival was noted for the exon6–exon16/17 subgroup: of the 19 patients who died from the disease, 12 had a tumor with exon6–exon16/17 fusion and only 2 with exon4–exon2 fusion. In the remaining five cases, our fusion analysis approach did not allow for identification of the exact type of *NAB2-STAT6* fusion ($n = 3$) or could not be assessed due to poor RNA quality ($n = 2$). *NAB2-STAT6* gene fusion was not correlated to progression-free survival ($p = 0.280$). *TERT* promoter mutation status could successfully be analyzed in 89% of the tumors ($n = 121$). Tumors with hot-spot mutations in this promoter region were grouped as ‘*TERT_p*-mutant’ and those without such mutations as ‘*TERT_p*-wildtype’. In 68% of the cases, the tumor was found to be *TERT_p*-wildtype ($n = 82$), and in 32% *TERT_p*-mutant ($n = 39$). *TERT* promoter mutation was not significantly correlated with *NAB2-*

STAT6 fusion type ($p = 0.164$), WHO grade ($p = 0.854$) or MGS grade ($p = 0.519$). In addition, *TERT* promoter mutation was not significantly correlated with metastatic disease ($p = 0.090$), progression-free survival ($p = 0.635$) or overall survival ($p = 0.107$), albeit a trend was noted for less aggressive clinical course in *TERT*_p-mutant tumors, which is contradictory to published results in soft tissue SFT [2, 7]. Survival curves for *NAB2-STAT6* fusion groups and the presence of *TERT* promoter mutation are provided in the Supplementary Information.

In summary, although in our relatively large cohort of CNS SFTs/HPCs the type of *NAB2-STAT6* fusion lacks significant prognostic value, tumors with an exon6–exon16/17 fusion do show a tendency towards more malignant behavior compared to tumors with exon4–exon2 fusion. This difference in aggressiveness may be explained by the presence of different functional domains within the chimeric *NAB2-STAT6* protein in different fusion groups, with, e.g., the CID domain of *NAB2* only integrated in the exon4–exon2 variant resulting in EGR1 activation and fibrosis as seen in the low-grade groups as hypothesized by Barthelmeß et al. [3]. Furthermore, in contrast to studies on mainly extradural SFTs in which *TERT* promoter mutation was shown to indicate poor disease-free survival, in our cohort clear prognostic value of *TERT* promoter mutation status was lacking. Based on our study we conclude that so far, histology-based grading incorporating mitotic activity and necrosis remains the best indicator of prognosis in SFTs/HPCs of the CNS. However, given the trend towards more malignant behavior in the exon6–exon16/17 fusion group future and larger studies are needed to sort out if esp. *NAB2-STAT6* fusion analysis may be of additional value in histology-based prognostic models after all.

Acknowledgements This study was performed with a supporting research grant from the Stichting STOP Hersentumoren, the Netherlands. French CNS SFT/HPC Consortium: Corinne Bouvier^{1,2}, Philippe Cornu⁴, Henry Dufour⁵, Dominique Figarella-Branger^{1,3}, Jacques Guyotat⁶, Anne Jouvett⁷, Nicolas Macagno^{1,2}, Philippe Métellus^{2,3,4}, Karima Mokhtari⁸, Alexandre Vasiljevic⁶, Pascale Varlet⁹. ¹Department of Pathology and Neuropathology, Timone Hospital, APHM, Marseille, France; ²Aix-Marseille university, INSERM, MMG, Marseille, France; ³Aix-Marseille University, CNRS, INP, Inst Neurophysiopathol, Marseille, France; ⁴Department of Neurosurgery, Pitié-Salpêtrière Hospital, Paris, France; ⁵Department of Neurosurgery, Timone Hospital, Marseille, France; ⁶Department of Neurosurgery, CHU Lyon, Lyon, France; ⁷Department of Neuropathology, CHU Lyon, Lyon, France; ⁸Department of Neuropathology, Pitié-Salpêtrière Hospital, Paris, France; ⁹Department of Neuropathology, Sainte-Anne Hospital, Paris, France. Dutch CNS SFT/HPC Consortium: R. Vogels^{1,2}, U. Flucke^{1,3}, B. Küsters^{1,4}, P. Groenen¹, P. Wesseling^{3,5}, E. Bekers⁶, M. Verdijk¹, M. Djafarihamedani¹, E. Kurt^{7,8}, H. Küsters-Vandeveld⁹, R. Fleischeuer¹⁰, S. Leenstra^{11,12}, P. Robe¹³, W. Spliet¹⁴, D. Troost¹⁵, W. van Furth¹⁶, ¹Department of Pathology, Radboud University Medical Center, Nijmegen, The Netherlands; ²Department of Pathology, Stichting PAMM, Eindhoven, The Netherlands; ³Princess Máxima Center for Pediatric Oncology, Utrecht, and University Medical Center Utrecht, Utrecht, The Netherlands; ⁴Department of Pathology, Maastricht University Medical Center+, Maastricht, The Netherlands; ⁵Department of Pathology, Amsterdam Universities Medical Center/VU University Medical Center, Amsterdam, The Netherlands; ⁶Pathologie- DNA, Location Jeroen Bosch Hospital, Den Bosch, The Netherlands; ⁷Department of Neurosurgery, Radboud University Medical Center, Nijmegen, The Netherlands; ⁸Department of Neurosurgery, Canisius Wilhelmina Hospital, Nijmegen, The Netherlands; ⁹Department of Pathology, Canisius Wilhelmina Hospital, Nijmegen, The Netherlands; ¹⁰Department of Pathology, St. Elisabeth Hospital, Tilburg, The Netherlands; ¹¹Department of Neurosurgery, St. Elisabeth Hospital, Tilburg, The Netherlands; ¹²Department of Neurosurgery, Erasmus Medical Center, Rotterdam, The Netherlands; ¹³Department of Neurosurgery, University Medical Center Utrecht, The Netherlands; ¹⁴Department of Pathology, University Medical Center Utrecht, The Netherlands; ¹⁵Department of Pathology, Amsterdam Medical Center, Amsterdam, The Netherlands; ¹⁶Department of Neurosurgery, Amsterdam Medical Center, Amsterdam, The Netherlands.

References

1. Akaike K, Kurisaki-Arakawa A, Hara K, Suehara Y, Takagi T, Mitani K et al (2015) Distinct clinicopathological features of NAB2–STAT6 fusion gene variants in solitary fibrous tumor with emphasis on the acquisition of highly malignant potential. *Hum Pathol* 46:347–356. <https://doi.org/10.1016/j.humpath.2014.11.018>
2. Bahrami A, Lee S, Schaefer IM, Boland JM, Patton KT, Pounds S et al (2016) TERT promoter mutations and prognosis in solitary fibrous tumor. *Mod Pathol* 29:1511–1522. <https://doi.org/10.1038/modpathol.2016.126>
3. Barthelmeß S, Geddert H, Boltze C, Moskalev EA, Bieg M, Sirbu H et al (2014) Solitary fibrous tumors/hemangiopericytomas with different variants of the NAB2–STAT6 gene fusion are characterized by specific histomorphology and distinct clinicopathological features. *Am J Pathol* 184:1209–1218. <https://doi.org/10.1016/j.ajpat.2013.12.016>
4. Bertero L, Anfossi V, Osella-Abate S, Disanto MG, Mantovani C, Zenga F et al (2018) Pathological prognostic markers in central nervous system solitary fibrous tumour/hemangiopericytoma: evidence from a small series. *PLoS One* 13:e0203570. <https://doi.org/10.1371/journal.pone.0203570>
5. Chmielecki J, Crago AM, Rosenberg M, O'Connor R, Walker SR, Ambrogio L et al (2013) Whole-exome sequencing identifies a recurrent NAB2–STAT6 fusion in solitary fibrous tumors. *Nat Genet* 45:131–132. <https://doi.org/10.1038/ng.2522>
6. Chuang IC, Liao KC, Huang HY, Kao YC, Li CF, Huang SC et al (2016) NAB2–STAT6 gene fusion and STAT6 immunoexpression in extrathoracic solitary fibrous tumors: the association between fusion variants and locations. *Pathol Int* 66:288–296. <https://doi.org/10.1111/pin.12408>
7. Demicco EG, Wani K, Ingram D, Wagner M, Maki RG, Rizzo A et al (2018) TERT promoter mutations in solitary fibrous tumour. *Histopathology* 73:843–851. <https://doi.org/10.1111/his.13703>
8. Doyle LA, Vivero M, Fletcher CD, Mertens F, Hornick JL (2013) Nuclear expression of STAT6 distinguishes solitary fibrous tumor from histologic mimics. *Mod Pathol*. <https://doi.org/10.1038/modpathol.2013.164>
9. Fritchie KJ, Jin L, Rubin BP, Burger PC, Jenkins SM, Barthelmeß S et al (2016) NAB2–STAT6 gene fusion in meningeal hemangiopericytoma and solitary fibrous tumor. *J Neuropathol Exp Neurol* 5:263–271. <https://doi.org/10.1093/jnen/nlv026>
10. Louis DN, Ohgaki H, Wiestler OD, Cavenee WK, Ellison DW, Figarella-Branger D et al (2016) WHO classification of tumours of the central nervous system, 4th edn. International Agency for Research on Cancer (IARC), Lyon
11. Macagno N, Vogels R, Appay R, Colin C, Mokhtari K, French CNSSFTHPCC et al (2018) Grading of meningeal solitary fibrous tumors/hemangiopericytomas: analysis of the prognostic value of the Marseille Grading System in a cohort of 132 patients. *Brain Pathol*. <https://doi.org/10.1111/bpa.12613>
12. Mohajeri A, Tayebwa J, Collin A, Nilsson J, Magnusson L, von Steyern FV et al (2013) Comprehensive genetic analysis identifies a pathognomonic NAB2/STAT6 fusion gene, nonrandom secondary genomic imbalances, and a characteristic gene expression profile in solitary fibrous tumor. *Genes Chromosomes Cancer* 2:873–886. <https://doi.org/10.1002/gcc.22083>
13. Nakada S, Minato H, Nojima T (2016) Clinicopathological differences between variants of the NAB2–STAT6 fusion gene in solitary fibrous tumors of the meninges and extra-central nervous system. *Brain Tumor Pathol* 33:169–174. <https://doi.org/10.1007/s10014-016-0264-6>

14. Robinson DR, Wu YM, Kalyana-Sundaram S, Cao X, Lonigro RJ, Sung YS et al (2013) Identification of recurrent NAB2–STAT6 gene fusions in solitary fibrous tumor by integrative sequencing. *Nat Genet* 45:180–185. <https://doi.org/10.1038/ng.2509>
15. Tai HC, Chuang IC, Chen TC, Li CF, Huang SC, Kao YC et al (2015) NAB2–STAT6 fusion types account for clinicopathological variations in solitary fibrous tumors. *Mod Pathol* 25:25. <https://doi.org/10.1038/modpathol.2015.90>
16. Yuzawa S, Nishihara H, Wang L, Tsuda M, Kimura T, Tanino M et al (2016) Analysis of NAB2–STAT6 gene fusion in 17 cases of meningeal solitary fibrous tumor/hemangiopericytoma: review of the literature. *Am J Surg Pathol* 40:1031–1040. <https://doi.org/10.1097/PAS.0000000000000625>

Supplementary Information Text

Materials and Methods

Patient cohort and sample selection

Patients with a diagnosis of meningeal SFT or HPC were retrospectively selected from the (referral) files of the authors. For each case, one representative tumor tissue block of the resection specimen was retrieved from the pathology archives of the participating hospitals and included for histomorphological assessment and gene fusion analysis.

Clinical data including age at first histological diagnosis and follow-up data were extracted from the patient files. Extradural metastatic disease was detected by imaging techniques (with no other malignancies known) and/or proven by histological assessment. Progression-free survival is counted in months from date of first histological diagnosis to date of diagnosis of the (first) local recurrence, growth of residual disease for which therapy was required or detection of metastasis. Overall survival is counted in months from date of first histological diagnosis to date of last known follow-up or date of death. Distinction was made between patients who died due to disease-related factors (i.e. disease-specific survival; DSS) and patients who died due to other causes.

This study was approved by the local scientific review board and was performed in accordance with the Code of Conduct of the Federation of Medical Scientific Societies in the Netherlands. The French Samples used in this study were stored and retrieved from the APHM Tumor Bank (authorization number: AC2018-31053; CRB BB-0033-00097), which respects the ethical charter of the French National Cancer Institute to store and deliver samples for scientific research according to the French Public Health Code (articles L. 1243-4 and R. 1243-61). All samples were obtained after informed consent from patients or their parents when the patients were under the age of 18. As this research was not interventional, it did not require an approval by an ethics committee. The French committee for the treatment of biomedical research information approved the data management of this study (C.C.T.I.R.S. - 09.084Ter).

Assessment of histomorphological features

Four μm thick sections were stained with hematoxylin and eosin and all cases were reviewed by three of the authors (UF, BK, RV). Diagnosis and WHO grade were assigned according to the 2016 WHO

Classification of Tumours of the Central Nervous System [WHO]. The updated Marseille Grading System [Macagno 2018] was applied on all cases by two authors (NM, CB).

All cases were confirmed by STAT6 nuclear staining of tumor cells using an already published protocol [1].

***NAB2-STAT6* gene fusion analysis and *TERT* promoter mutation analysis**

NAB2-STAT6 gene fusion analysis and *TERT* promoter mutation analysis was performed on all cases.

Briefly, RNA was extracted from formalin-fixed, paraffin-embedded tissue using RNA-Bee-RNA isolation reagent (Bio-Connect BV, Huissen, the Netherlands). RNA quantity and quality were determined by a NanoDrop measurement (Fisher Scientific, Landsmeer, the Netherlands) and subsequently, cDNA synthesis was performed using Superscript II (Invitrogen Life Technologies Europe, Bleiswijk, the Netherlands) and random hexamers (Promega Nederland, Leiden, the Netherlands). The cDNA was tested by the reverse transcription-polymerase chain reaction (RT-PCR) for the HMBS (hydroxymethylbilase synthase) housekeeping gene using the primers forw150 5'-TGCCAGAGAAGAGTGTGGTG-3' and rev150 5'-ATGATGGCACTGAACTCCTG-3'. Samples without cDNA template were amplified in parallel as negative controls.

For the detection of the most common *NAB2-STAT6* gene fusions, three primers in *NAB2* (NM_005967.3): forw 5'-CAAGTAGCCCGAGAGAGCAC-3' (exon 3), forw 5'-CTCCACTGAAGAAGCTGAAAC-3' (exon 4) and forw 5'-CTGTGTGCCTGCGAAGCC-3' (exon 6) were used in combination with three primers in *STAT6* (NM_001178078.1): rev 5'-GGGAAAGTCGACATAGAGCC-3' (exon 2), rev 5'-GAGCTGAGCAAGATCCCGG-3' (exon 16) and rev 5'-TTCCACGGTCATCTTGATGG-3' (exon 17). The PCR products were analyzed by agarose gel electrophoresis.

PCR was applied to amplify the *TERT* promoter region using the following primers: hTERT-F: CAGCGCTGCCTGAAACTC and hTERT-R GTCCTGCCCTTACCTT, amplifying a 163-bp fragment spanning hot-spot mutations at positions 1,295,228 and 1,295,250 on chromosome 5. Sequencing was done on an Illumina MiSeq next generation sequencer. Adapter ligation and barcoding was done using the NEBNext Ultra DNA Library Prep Mastermix Set and NEBNext Multiplex Oligos from New England Biolabs. CLC Cancer Research Workbench software from QIAGEN® was performed for sequence analysis. Described briefly, the analysis workflow included adapter trimming and read pair merging before mapping to the human reference genome (hg19). Insertions and deletions as well as single nucleotide variants were detected. Additional information regarding potential mutation type, known single nucleotide

polymorphisms and conservation scores was obtained by cross-referencing various databases (COSMIC, ClinVar, dbSNP, 1000 Genomes Project, HAPMAP and PhastCons-Conservation_scores_hg19).

Statistical analysis

Statistical analysis was performed using IBM SPSS Statistics v22.0.

Comparison of different *NAB2-STAT6* fusion variants with various clinical and histomorphological parameters were evaluated by using the χ^2 - or Fisher's exact test as appropriate.

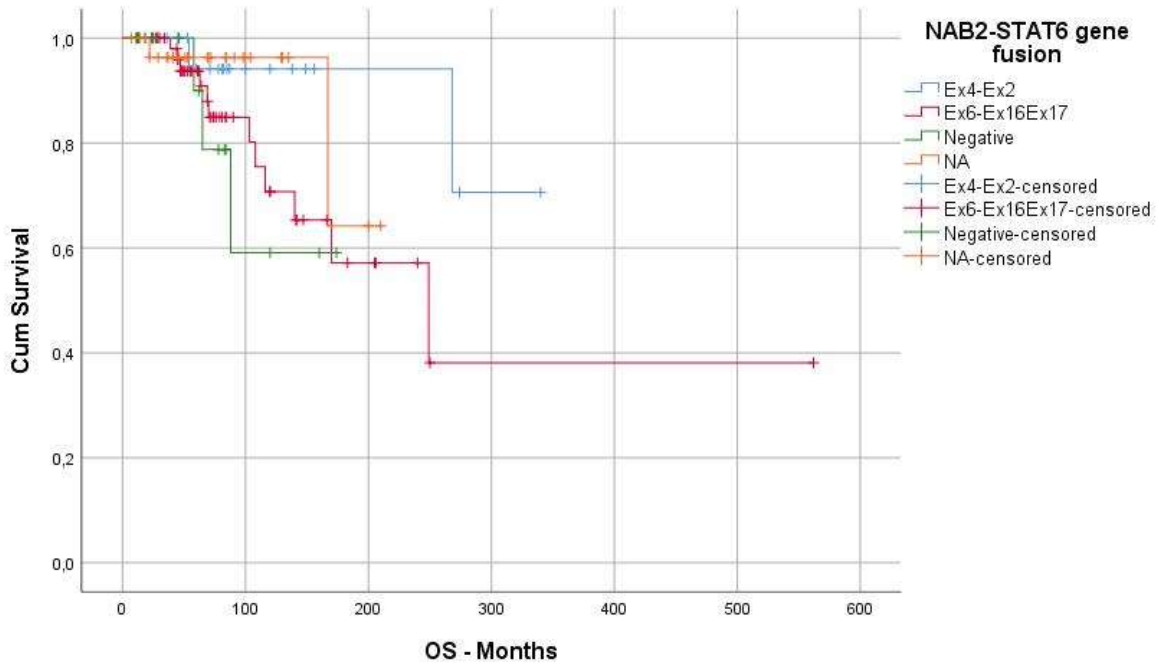
Progression-free- and disease-specific overall survival were used as end points as defined above. Kaplan-Meier curves were plotted for visualizing survival in different *NAB2-STAT6* fusion variant groups and the log-rank test was used for comparing the difference between the groups. For survival analysis, patients who died due to complications of initial therapy (e.g. surgery or radiotherapy) were excluded.

References

1. Vogels RJ, Vlenterie M, Versleijen-Jonkers YM, Ruijter E, Bekers EM, Verdijk MA, Link MM, Bonenkamp JJ, van der Graaf WT, Slootweg PJ, Suurmeijer AJ, Groenen PJ, Flucke U (2014) Solitary fibrous tumor - clinicopathologic, immunohistochemical and molecular analysis of 28 cases. *Diagnostic pathology* 9:224. doi:10.1186/s13000-014-0224-6

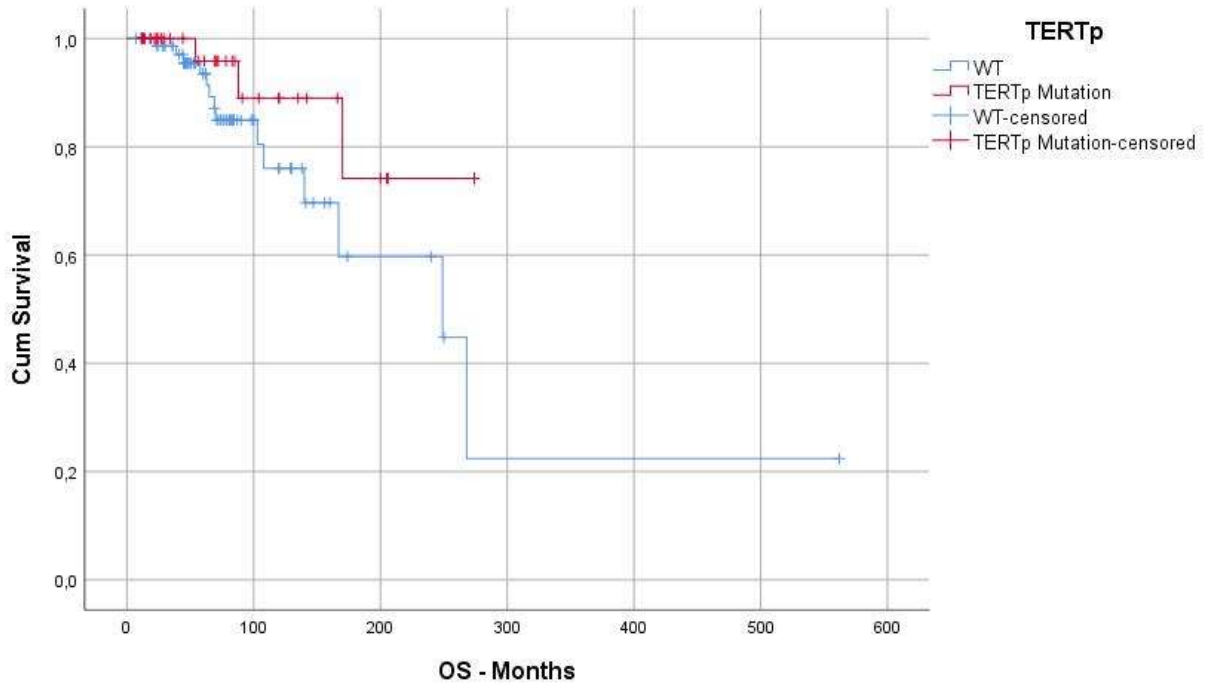
Supplementary Information Figures

Figure 1a: Overall survival in different *NAB2-STAT6* fusion groups of solitary fibrous tumors/hemangiopericytomas of the central nervous system



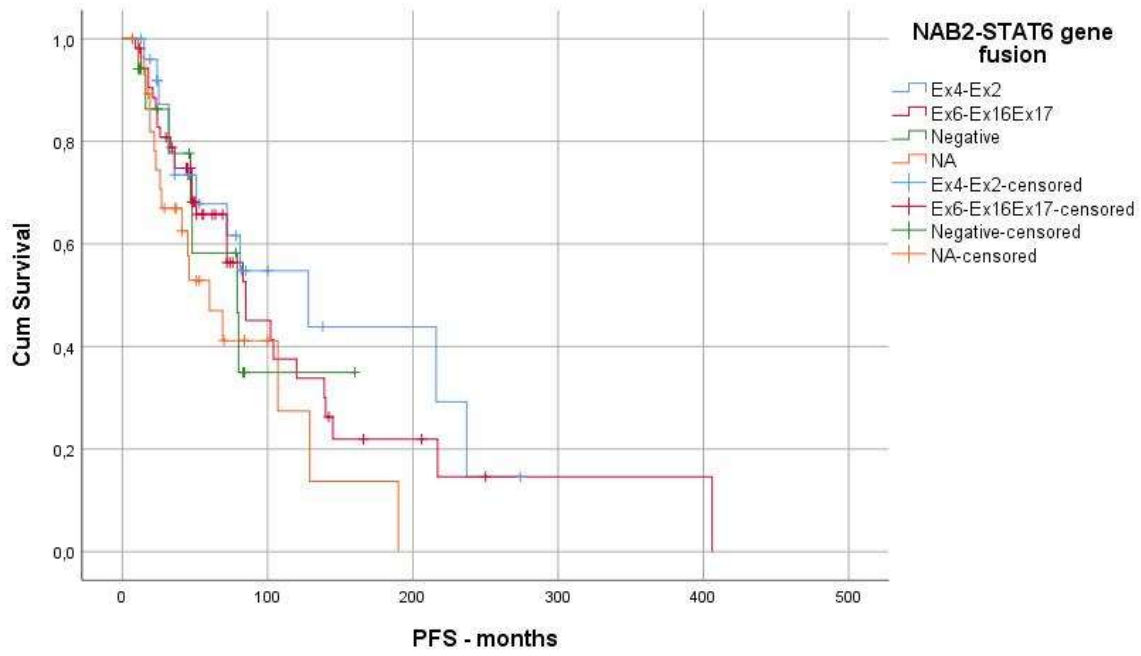
Log-rank $p = 0.172$

Figure 1b: Overall survival in *TERT* promoter-mutant versus *TERT* promoter-wildtype solitary fibrous tumors/hemangiopericytomas of the central nervous system



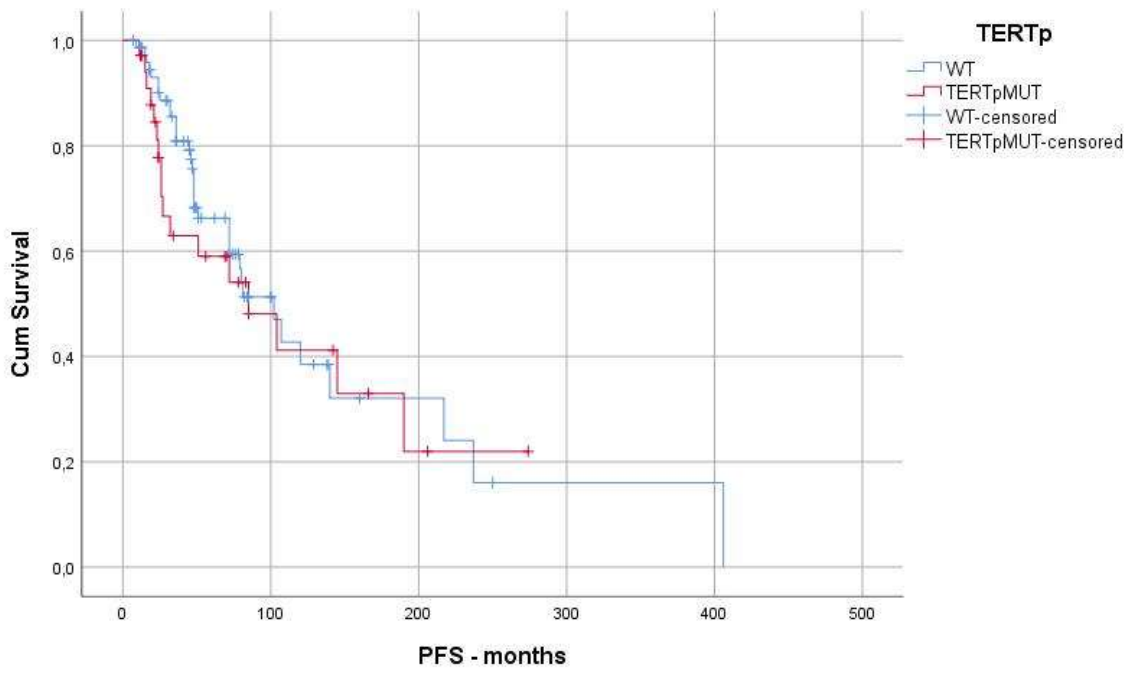
Log-rank $p = 0.107$

Figure 2a: Progression-free survival in different *NAB2-STAT6* fusion groups of solitary fibrous tumors/hemangiopericytomas of the central nervous system



Log-rank $p = 0.280$

Figure 2b: Progression-free survival in *TERT* promoter-mutant versus *TERT* promoter-wildtype solitary fibrous tumors/hemangiopericytomas of the central nervous system



Log-rank $p = 0.635$