



HAL
open science

Actinomycetoma Caused by Actinomadura mexicana , A Neglected Entity in the Caribbean

Simon Bessis, Latifa Noussair, Véronica Rodriguez-Nava, Camille Jousset, Clara Duran, Alina Beresteanu, Morgan Matt, Benjamin Davido, Robert Carlier, Emmanuelle Bergeron, et al.

► To cite this version:

Simon Bessis, Latifa Noussair, Véronica Rodriguez-Nava, Camille Jousset, Clara Duran, et al.. Actinomycetoma Caused by Actinomadura mexicana , A Neglected Entity in the Caribbean. Emerging Infectious Diseases, 2020, 26 (2), pp.379-380. 10.3201/eid2602.191005 . hal-02525278

HAL Id: hal-02525278

<https://amu.hal.science/hal-02525278>

Submitted on 7 Jun 2022

HAL is a multi-disciplinary open access archive for the deposit and dissemination of scientific research documents, whether they are published or not. The documents may come from teaching and research institutions in France or abroad, or from public or private research centers.

L'archive ouverte pluridisciplinaire **HAL**, est destinée au dépôt et à la diffusion de documents scientifiques de niveau recherche, publiés ou non, émanant des établissements d'enseignement et de recherche français ou étrangers, des laboratoires publics ou privés.



Distributed under a Creative Commons Attribution 4.0 International License

PCR and sequencing results confirmed that sequences at the 2 junctional sites were the same as those found by next-generation sequencing.

Pathogens causing respiratory disease in domesticated animals, such as cattle and pigs, are relatively well studied. However, pathogens causing these diseases in wildlife animals, such as deer, are not well characterized. In this study, the new astrovirus we found or the bacterial pathogens could have contributed to the respiratory disease observed. Whether astrovirus plays a major or just synergistic role in respiratory disease in deer should be explored further.

Astrovirus was previously identified in roe deer with gastrointestinal illness in Europe and found to be closely related to bovine astrovirus isolates from Hong Kong, China, of the same genus (*Mamastrovirus* 33) (7,8). WI65268 was also closely related to bovine isolates from Japan but distantly related to roe deer and Hong Kong bovine astrovirus isolates. An additional analysis of genetic distances of related isolates on the basis of ORF2 tentatively classified WI65268 as a novel species (Appendix Table).

Determining the evolution of WI65268 any further is difficult without further epidemiologic data. Bovine or bovid astroviruses might be able to cross species barriers and replicate in deer, as suggested in a previous study (9), in which a bovine astrovirus isolate clustered with a porcine astrovirus type 5 instead of other bovine astroviruses. Further surveillance of white-tailed deer for astrovirus is needed for field monitoring.

About the Author

Dr. Wang is a clinical assistant professor in the College of Veterinary Medicine at the University of Illinois, Urbana, Illinois, USA. His research interests focus on diagnosis of viral infectious diseases and novel pathogen discovery.

References

1. Bosch A, Pintó RM, Guix S. Human astroviruses. *Clin Microbiol Rev.* 2014;27:1048-74. <https://doi.org/10.1128/CMR.00013-14>
2. Donato C, Vijaykrishna D. The broad host range and genetic diversity of mammalian and avian astroviruses. *Viruses.* 2017;9:102. <https://doi.org/10.3390/v9050102>
3. Ng TF, Kondov NO, Deng X, Van Eenennaam A, Neiberghs HL, Delwart E. A metagenomics and case-control study to identify viruses associated with bovine respiratory disease. *J Virol.* 2015;89:5340-9. <https://doi.org/10.1128/JVI.00064-15>
4. Padmanabhan A, Hause BM. Detection and characterization of a novel genotype of porcine astrovirus 4 from nasal swabs from pigs with acute respiratory disease. *Arch Virol.* 2016;161:2575-9. <https://doi.org/10.1007/s00705-016-2937-1>
5. Cordey S, Brito F, Vu DL, Turin L, Kilowoko M, Kyungu E, et al. Astrovirus VA1 identified by next-generation sequencing in a nasopharyngeal specimen of a febrile Tanzanian child with acute respiratory disease of unknown etiology. *Emerg Microbes Infect.* 2016;5:e99. <https://doi.org/10.1038/emi.2016.98>
6. Smits SL, van Leeuwen M, Kuiken T, Hammer AS, Simon JH, Osterhaus AD. Identification and characterization of deer astroviruses. *J Gen Virol.* 2010;91:2719-22. <https://doi.org/10.1099/vir.0.024067-0>
7. To KKW, Chan WM, Li KSM, Lam CSF, Chen Z, Tse H, et al. High prevalence of four novel astrovirus genotype species identified from rodents in China. *J Gen Virol.* 2017;98:1004-15. <https://doi.org/10.1099/jgv.0.000766>
8. Tse H, Chan WM, Tsoi HW, Fan RY, Lau CC, Lau SK, et al. Rediscovery and genomic characterization of bovine astroviruses. *J Gen Virol.* 2011;92:1888-98. <https://doi.org/10.1099/vir.0.030817-0>
9. Nagai M, Omatsu T, Aoki H, Otomaru K, Uto T, Koizumi M, et al. Full genome analysis of bovine astrovirus from fecal samples of cattle in Japan: identification of possible interspecies transmission of bovine astrovirus. *Arch Virol.* 2015;160:2491-501. <https://doi.org/10.1007/s00705-015-2543-7>

Address for correspondence: Ganwu Li, Department of Veterinary Diagnostic and Production Animal Medicine, College of Veterinary Medicine, Iowa State University, Ames, IA 50011, USA; email: liganwu@iastate.edu

Actinomycetoma Caused by *Actinomyces mexicanus*, a Neglected Entity in the Caribbean

Simon Bessis, Latifa Noussair, Veronica Rodriguez-Nava, Camille Jousset, Clara Duran, Alina Beresteanu, Morgan Matt, Benjamin Davido, Robert Carlier, Emmanuelle Bergeron, Pierre-Edouard Fournier, Jean Louis Herrmann, Aurélien Dinh

Author affiliations: Hôpital Universitaire Raymond-Poincaré, Assistance Publique-Hôpitaux de Paris, Garches, France (S. Bessis, L. Noussair, C. Jousset, C. Duran, A. Beresteanu, M. Matt, B. Davido, R. Carlier, J.L. Herrmann, A. Dinh); Claude Bernard University-Lyon I, Lyon, France (V. Rodriguez-Nava, E. Bergeron); Aix-Marseille University, Marseille, France (P.-E. Fournier); Institut Hospitalo-Universitaire Méditerranée Infection, Marseille (P.-E. Fournier); Paris-Saclay University, Versailles, France (J.L. Herrmann)

DOI: <https://doi.org/10.3201/eid2602.191005>

Mycetoma is a chronic infection that is slow to develop and heal. It can be caused by fungi (eumycetoma) or bacteria (actinomycetoma). We describe a case of actinomycetoma caused by *Actinomadura mexicana* in the Caribbean region.

Mycetoma is a neglected tropical disease that poses a major public health problem (1). It is endemic in arid or semiarid regions, such as part of the Indian subcontinent, East and West Africa, and Central and South America (2). Mycetoma when caused by bacteria is called actinomycetoma; when caused by fungi, eumycetoma. The pathogens are found in the environment, often in soil, and usually infect people through minor or undetected trauma, thorn pricks being the most common (3). Bacteria of the *Actinomadura* genus can cause actinomycetoma; the most frequently clinically isolated species are *A. madurae* and *A. pelletieri* (1). We report infection with *A. mexicana* that was acquired in the Caribbean.

A 38-year-old woman from Haiti who had arrived in France with no apparent medical problems was hospitalized a month after her arrival for treatment of multinodular lesions of the left foot and the distal part of the left leg (Figure 1, panel A). She was afebrile but had multiple bulbous nodules of the foot associated with a nodular lesion. The nodules had central pinpoint ulcerations with granular discharge. The woman was experiencing pain and a complete loss of function of her left foot, symptoms that had been evolving for ≈6 months.

Standard radiographs, a computed tomography scan, and magnetic resonance imaging of the affected foot showed symmetrical para-articular marginal erosion in the third and fourth metatarsophalangeal joints, with local inflammation and multiple subcutaneous nodular lesions containing small low-signal foci. A negative result from an HIV serology test and the absence of lymphopenia (2.19 g/L) and

hypogammaglobulinemia indicated that there was no immunosuppression. An inflammatory syndrome, with a C-reactive protein level of 53.93 mg/L and a total leukocyte count of 4.5 g/L (neutrophils 1.7 g/L), was identified.

A sample of the nodules, taken from a punch biopsy, revealed a liquid serum containing white-yellow grains (Figure 1, panel B). Direct examination showed numerous branching gram-positive bacilli, characteristic of actinomycetal bacteria (Figure 1, panel C). Histologic analysis revealed abundant filamentous structures consistent with aerobic actinomycetes. Results from Grocott's methenamine silver staining and Zhiel-Neelssen staining tests were negative at direct examination for mycobacteria and fungus.

We cultured biopsy specimens on Columbia blood agar in an aerobic atmosphere using chocolate Polyvitex agar under 5% CO₂ and Sabouraud and Lowenstein media. After an 8-day incubation, the cultures yielded positive results for bacterial colonies, which were pink to red in color and convex with a wrinkled morphology in shape (Figure 1, panel D). Aerobic and anaerobic blood vials remained negative. A surgical bone biopsy was also performed, and direct examination showed gram-positive branching filaments. Final identification was confirmed by 16S rRNA gene sequencing, as described by Rodriguez-Nava et al. (4), using BLAST (<https://blast.ncbi.nlm.nih.gov/Blast.cgi>) to compare the identified sequence with existing sequences in the GenBank database. The sequence matched ≥95% with *A. mexicana* (GenBank accession no. MN684846).

Antimicrobial susceptibility testing, performed using the agar disk diffusion method (Bio-Rad, <https://www.bio-rad.com>) according to French Microbiology Society guidelines (5), showed susceptibility to amoxicillin, amoxicillin/clavulanate, carbapenems, third-generation cephalosporins, aminosides,

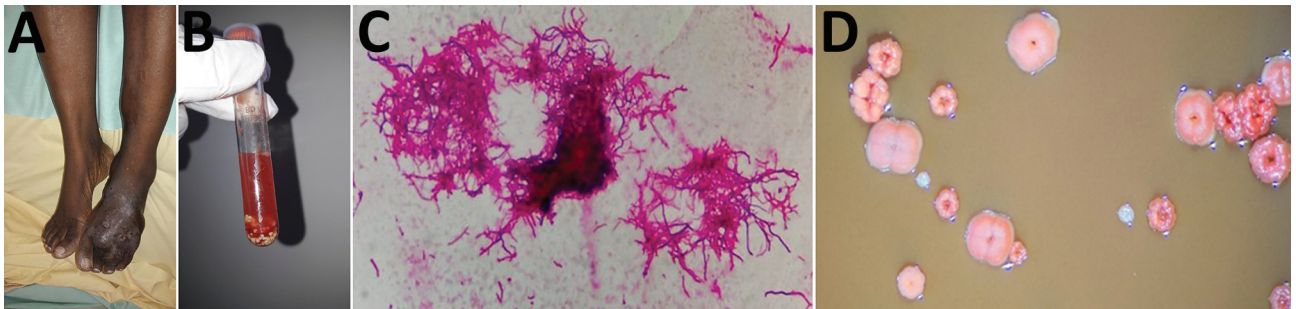


Figure. Actinomycetoma caused by *Actinomadura mexicana* infection in a 38-year-old woman from Haiti, France. A) Multinodular lesions on the dorsal surface of the left foot. B) Liquid from puncture of the nodules, showing white-yellow grains. C) Gram-positive bacilli branching out, characteristic of actinomycetal bacteria (original magnification $\times 1,000$). D) Colonies after an 8-day incubation, showing warty ornamentation, pink to pallid red, convex, with a wrinkled morphology (observed through binocular magnifying glass).

cyclines, erythromycin, linezolid, vancomycin, sulfamethoxazole/trimethoprim, fluoroquinolones, and rifampin. The patient was given amoxicillin/clavulanate (2 g 3×/d) and sulfamethoxazole/trimethoprim (1,600 mg/280 mg 3×/d) for a minimum of 6 months. At her 3-month follow-up, the woman reported reduced pain and doctors found a decrease in the size of the subcutaneous nodules; magnetic resonance imaging confirmed decreased nodule size and indicated no extension of bone damage. No debridement surgery was performed.

The patient used to live in a rural village near the town of Gonaïves in the Artibonite district of Haiti, a semiarid and hot region compatible with actinomycetoma (6), and she mainly walked barefoot or with open shoes, which may explain her exposure to the bacteria. However, no previous case of actinomycetoma caused by *A. mexicana* had been reported in that area. *A. mexicana* was described by Quintana et al. (7) and was isolated with *A. meyerii* from garden soil samples in Mexico in 2003, but a study by Bonifaz et al. published in 2014 found that this species was not identified as a cause of any of the 482 cases of mycetoma recorded in the country during 1980–2013 (8). *A. mexicana* was also not identified as the cause of any mycetoma cases reported during 1991–2014 in Brazil (9). We could find no accounts in the literature of actinomycetoma in the Caribbean region. The only clinical case of mycetoma found, described by Gugnani and Denning in 2016 (10), involved eumycetoma, with etiologic agents such as chromoblastomycoses and *Microsporium canis*. In that article, 2 infections were identified as mycetomas based on case reports in which no laboratory-confirmed microbiological identifications were reported. However, the absence of previous identification might be explained, in part, by lack of access to current molecular biology resources (e.g., matrix-assisted laser desorption/ionization time-of-flight mass spectrometry or PCR).

This case highlights that actinomycetoma may be present but underrecognized in the Caribbean. Because of the severity of mycetoma and the potential for major socioeconomic effects, healthcare providers in this region should remain informed about the potential risk for these infections.

Acknowledgments

We thank the team of the CNR des actinomycétales de Lyon for their help in identifying the strain.

The patient has given free and informed consent for the publication of her data.

About the Author

Dr. Bessis is an assistant clinical fellow, a specialist in infectious and tropical diseases, working in the Infectious Diseases Department of Raymond-Poincaré Hospital, APHP, in Paris.

References

- Zijlstra EE, van de Sande WWJ, Welsh O, Mahgoub ES, Goodfellow M, Fahal AH. Mycetoma: a unique neglected tropical disease. *Lancet Infect Dis*. 2016;16:100–12. [https://doi.org/10.1016/S1473-3099\(15\)00359-X](https://doi.org/10.1016/S1473-3099(15)00359-X)
- van de Sande WWJ. Global burden of human mycetoma: a systematic review and meta-analysis. *PLoS Negl Trop Dis*. 2013;7:e2550. <https://doi.org/10.1371/journal.pntd.0002550>
- Fahal AH, Suliman SH, Hay R. Mycetoma: the spectrum of clinical presentation. *Trop Med Infect Dis*. 2018;3:97–107. <https://doi.org/10.3390/tropicalmed3030097>
- Rodríguez-Nava V, Couble A, Devulder G, Flandrois J-P, Boiron P, Laurent F. Use of PCR-restriction enzyme pattern analysis and sequencing database for hsp65 gene-based identification of *Nocardia* species. *J Clin Microbiol*. 2006;44:536–46. <https://doi.org/10.1128/JCM.44.2.536-546.2006>
- Société Française de Microbiologie (SFM), The European Committee on Antimicrobial Susceptibility Testing (EUCAST). Comité de l'antibiogramme de la Société Française de Microbiologie. Recommendations 2019 v2.0 Mai [in French]. 2019 [cited 2019 May 9]. https://www.sfm-microbiologie.org/wp-content/uploads/2019/05/CASFM2019_V2.0_MAI.pdf
- Mohammadipanah F, Wink J. Actinobacteria from arid and desert habitats: diversity and biological activity. *Front Microbiol*. 2016;6:1541. <https://doi.org/10.3389/fmicb.2015.01541>
- Quintana ET, Trujillo ME, Goodfellow M. *Actinomadura mexicana* sp. nov. and *Actinomadura meyerii* sp. nov., two novel soil sporoactinomycetes. *Syst Appl Microbiol*. 2003;26:511–7. <https://doi.org/10.1078/072320203770865800>
- Bonifaz A, Tirado-Sánchez A, Calderón L, Saúl A, Araiza J, Hernández M, et al. Mycetoma: experience of 482 cases in a single center in Mexico. Reynolds T, editor. *PLoS Negl Trop Dis*. 2014;8:e3102.
- Sampaio FMS, Wanke B, Freitas DFS, Coelho JMCO, Galhardo MCG, Lyra MR, et al. Review of 21 cases of mycetoma from 1991 to 2014 in Rio de Janeiro, Brazil. Vinetz JM, editor. *PLoS Negl Trop Dis*. 2017;11:e0005301.
- Gugnani HC, Denning DW. Burden of serious fungal infections in the Dominican Republic. *J Infect Public Health*. 2016;9:7–12. <https://doi.org/10.1016/j.jiph.2015.04.026>

Address for correspondence: Simon Bessis or Aurélien Dinh, Hôpital Raymond-Poincaré, Service de maladies infectieuses et tropicales, Assistance Publique-Hôpitaux de Paris (AP-HP), 104 Boulevard Raymond Poincaré, Garches 92380, France; email: simon.bessis@aphp.fr or aurelien.dinh@aphp.fr