



**HAL**  
open science

## Open-heart transcatheter aortic valve replacement in complex aortic valve reoperation: about a case series

Laury Leveille, Nicolas Jaussaud, Alexis Theron, Alberto Riberi, Frederic Collart

### ► To cite this version:

Laury Leveille, Nicolas Jaussaud, Alexis Theron, Alberto Riberi, Frederic Collart. Open-heart transcatheter aortic valve replacement in complex aortic valve reoperation: about a case series. *European Heart Journal. Case Reports*, 2018, 2 (2), 10.1093/ehjcr/yty064 . hal-02526700

**HAL Id: hal-02526700**

**<https://amu.hal.science/hal-02526700>**

Submitted on 5 Jul 2023

**HAL** is a multi-disciplinary open access archive for the deposit and dissemination of scientific research documents, whether they are published or not. The documents may come from teaching and research institutions in France or abroad, or from public or private research centers.

L'archive ouverte pluridisciplinaire **HAL**, est destinée au dépôt et à la diffusion de documents scientifiques de niveau recherche, publiés ou non, émanant des établissements d'enseignement et de recherche français ou étrangers, des laboratoires publics ou privés.



Distributed under a Creative Commons Attribution - NonCommercial 4.0 International License

# Open-heart transcatheter aortic valve replacement in complex aortic valve reoperation: about a case series

Laury Leveille, Nicolas Jaussaud\*, Alexis Theron\*, Alberto Riberi, and Frederic Collart

Department of Cardiac Surgery, La Timone Hospital, Marseille, 264 rue Saint Pierre 13385 Marseille, France

Received 7 November 2017; accepted 2 May 2018; online publish-ahead-of-print 24 May 2018

## Introduction

Aortic homograft and stentless aortic root are helpful in acute infective endocarditis of the aortic valve as biological conduit when total root replacement is required. Reoperation for failure of aortic homograft and stentless aortic root remains challenging for the surgeon as the entire root can be heavily calcified.

## Case presentation

Here, are reported, three cases of patients successfully treated with open-heart transcatheter aortic valve replacement (TAVR) whereas no other prosthesis was implantable due to a massively calcified homograft or stentless prosthesis.

## Discussion

Open-heart TAVR avoided the risk of complete root replacement which is higher than redo aortic valve replacement (AVR). This rescue technique facilitated risky surgical procedure by combining the strengths of both TAVR and conventional AVR.

## Keywords

Aortic root • Aortic valve replacement • Heart valve replacement • Transapical • Percutaneous • Case series

## Learning points

- Reoperation for failure of homograft or stentless valve remains a technical challenge for the surgeon as the root calcifications can lead to technical difficulties during surgery.
- Open transcatheter aortic valve replacement is a safe and helpful procedure as it allows to avoid full aortic root reconstruction whereas no other prosthesis is implantable.

## Introduction

Acute infective endocarditis of the aortic valve often requires total root replacement. Aortic homograft and stentless aortic root are helpful in this situation as biological conduit. As with any bioprosthetic valve, tissue calcification or degeneration may lead to a need for reoperation. Regarding homograft failure rate, it is between 10% and 25% within 15 years and nearly 50% by 20 years.<sup>1</sup> After prior freestyle aortic valve replacement (AVR), 10- and 15-year rates for freedom from reoperation are 92% and 81%, respectively.<sup>2</sup> In these cases, reoperation remains a technical challenge as the entire root can be heavily calcified.

We report the successful treatment of three patients with failing aortic root homografts and stentless valve with 'open TAVR'.

\* Corresponding authors. Alexis Theron, Tel: (33) 491385717, Fax: (33) 491384926, Email: alexis.theron@ap-hm.fr; Nicolas Jaussaud, Email: nicolas.jaussaud@ap-hm.fr. This case report was reviewed by Kyriakos Dimitriadis, Savvas Loizos, and Hosam Hasan.

© The Author(s) 2018. Published by Oxford University Press on behalf of the European Society of Cardiology.

This is an Open Access article distributed under the terms of the Creative Commons Attribution Non-Commercial License (<http://creativecommons.org/licenses/by-nc/4.0/>), which permits non-commercial re-use, distribution, and reproduction in any medium, provided the original work is properly cited. For commercial re-use, please contact [journals.permissions@oup.com](mailto:journals.permissions@oup.com)

## Timeline

Patients	One	Two	Three
History	19 years earlier: <ul style="list-style-type: none"> <li>• <i>Staphylococcus aureus</i> native aortic valve endocarditis</li> <li>• 22 mm aortic root homograft</li> </ul>	<ul style="list-style-type: none"> <li>• 40 years earlier: commissurotomy for congenital aortic stenosis</li> <li>• 20 years later: 22 mm aortic root homograft for aortic stenosis</li> </ul>	17 years earlier: <ul style="list-style-type: none"> <li>• <i>Staphylococcus aureus</i> native aortic valve endocarditis</li> <li>• Aortic root replacement with 23 stentless bioprosthesis</li> </ul>
Clinic and para clinic	<ul style="list-style-type: none"> <li>• Ingravescient dyspnoea</li> <li>• Transthoracic echocardiography (TTE)/transoesophageal echocardiography (TOE): severe aortic valve regurgitation</li> <li>• Computed tomography (CT): severe calcified aortic root</li> </ul>	<ul style="list-style-type: none"> <li>• Dyspnoea, malaise</li> <li>• TTE/TOE: severe aortic regurgitation</li> <li>• CT: calcified aortic root homograft, clampable ascending aorta</li> </ul>	<ul style="list-style-type: none"> <li>• Dyspnoea evolving for 6 months</li> <li>• TTE: severe aortic regurgitation</li> <li>• ECG-gated heart CT: sinus and sinotubular calcification</li> </ul>
Surgery	<ul style="list-style-type: none"> <li>• Attempt of conventional AVR</li> <li>• Open transcatheter aortic valve replacement (TAVR) with 23 Sapien XT bioprosthesis</li> <li>• TOE: severe periprosthetic regurgitation (PPR)</li> <li>• Open TAVR with 26 Sapien XT bioprosthesis</li> <li>• 2nd TOE: no PPR</li> </ul>	<ul style="list-style-type: none"> <li>• Attempt of RDVAR</li> <li>• Open TAVR with 26 Sapien XT bioprosthesis</li> <li>• TOE: no PPR</li> </ul>	<ul style="list-style-type: none"> <li>• Attempt of conventional AVR</li> <li>• Open TAVR with 23 Sapien 3 bioprosthesis</li> <li>• TOE: no PPR</li> </ul>
Outcomes	<ul style="list-style-type: none"> <li>• TTE: no PPR, mean aortic transvalvular gradient: 16 mmHg</li> <li>• Discharge: 10th post-operative day</li> </ul>	<ul style="list-style-type: none"> <li>• TTE: no PPR, mean aortic transvalvular gradient: 13 mmHg</li> <li>• Discharge: 10th post-operative day</li> </ul>	<ul style="list-style-type: none"> <li>• TTE: no PPR, mean aortic transvalvular gradient: 20 mmHg</li> <li>• Discharge: 15th post-operative day</li> </ul>

## Case series

### Patient 1

Patient 1 was a 53-year-old man with symptoms of ingravescient dyspnoea.

Nineteen years previously, he had been operated on for native aortic valve endocarditis as a result of *Staphylococcus aureus* infection and received a 22 mm aortic root homograft. This endocarditis was complicated by a stroke and a spondylodiscitis. On examination, the patient was dyspnoeic. Cardiac auscultation revealed aortic diastolic and systolic murmurs Grades 2 and 3/6, respectively. Transthoracic echocardiography (TTE) and transoesophageal echocardiography (TOE) showed severe aortic valve regurgitation and moderate aortic stenosis. Computed tomography (CT) scan revealed a severe calcified aortic root (Figure 1). Native ascending aorta remained uncalcified. Conventional redux AVR was planned in order to implant a bioprosthesis (patient refused a mechanical valve).

After a general anaesthesia, a median sternotomy was performed. The procedure was performed under a normothermic cardiopulmonary bypass through the cannulation of the ascending aorta and the right atrial appendage. The aorta was clamped, and cold crystalloid cardioplegia was administered in a retrograde fashion. Aortotomy was performed above the distal suture line of the homograft. A massively

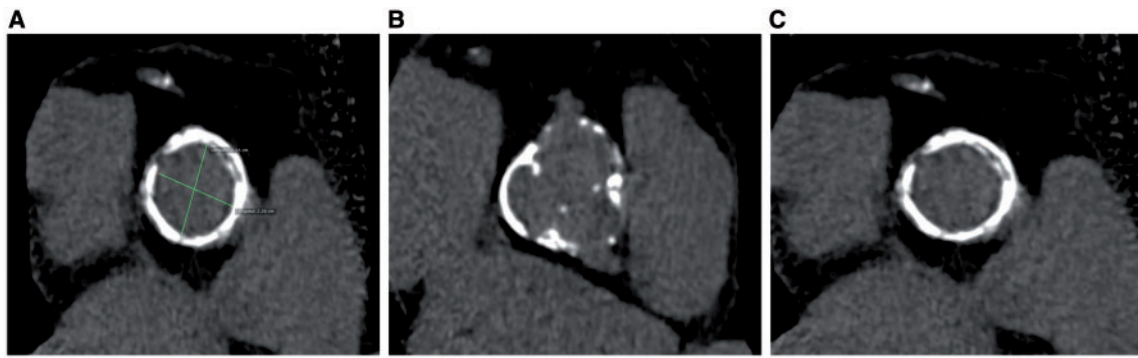
calcified aortic root was documented. Because of the heavy calcification of the aortic annulus, the suture of a conventional aortic bioprosthesis was not possible and the replacement of the entire homograft was considered too risky. After excision of the aortic leaflets and annulus sizing, a TAVR was performed with a 23 Sapien XT bioprosthesis (Edwards Lifesciences, Inc.) using the Ascendra 24 Fr delivery system. After weaning from cardiopulmonary bypass, operative TOE was performed and showed a severe periprosthetic regurgitation (PPR). Therefore, the 23 Sapien XT was replaced by a 26 Sapien XT. The aortic cross clamp time (XCT) and the cardiopulmonary bypass time (CPBT) were 94 and 125 min, respectively. The second TOE showed no PPR.

The post-operative course was uneventful. The patient was discharged on the 10th post-operative day. Mean transvalvular gradient was 16 mmHg, and no PPR was observed in TTE at discharge and 1 year after surgery.

### Patient 2

The second patient was a 67-year-old female with severe aortic regurgitation as a result of aortic homograft degeneration. She was hospitalized in our cardiology department for dyspnoea and malaise. Cardiac auscultation revealed an aortic diastolic murmur Grade 2/6.

Forty years earlier, she underwent aortic commissurotomy for congenital aortic stenosis. Twenty years later, she received a 22 mm



**Figure 1** MDCT anatomy of the aortic root (A) with cross-sectional area of the aortic annulus. Massively calcified coronary ostia (B) and sinotubular junction (C) (for Patient 1). MDCT, multidetector computed tomography.

aortic root homograft for the recidivism of the aortic stenosis. This surgery was complicated by a post-operative conduction disorder that led to the implantation of a permanent pacemaker. Preoperative TTE and TOE showed an important aortic regurgitation and a posterior anastomotic false aneurysm. Euroscore II was 3.42%. The CT scan performed revealed a calcified aortic root homograft and a clampable ascending aorta. A rapid deployment AVR with an Intuity bioprosthesis was decided.

As the sinotubular junction was too narrowed and too calcified (Figure 2) to coast the device used to deploy the Intuity bioprosthesis, a TAVR was performed with a 26 Sapien XT. The perioperative TOE showed no PPR.

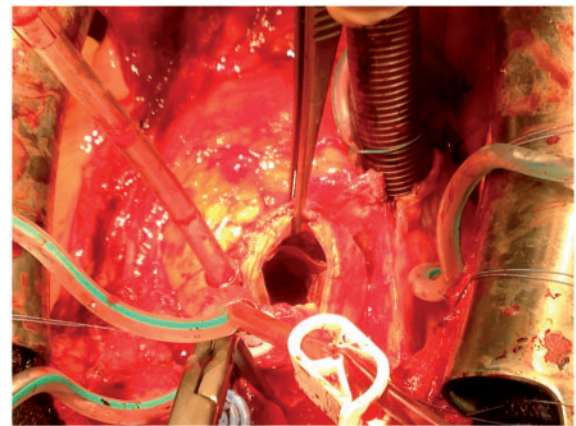
The aortic XCT and the CPBT were 67 and 87 min, respectively. The post-operative course was uneventful. Mean transvalvular gradient was 13 mmHg and no PPR was observed in TTE at discharge and 6 months after surgery.

### Patient 3

The third patient was a 55-year-old female with a dyspnoea evolving for 6 months. Seventeen years earlier, she suffered a native aortic valve endocarditis with left atrial-aorta fistula as a result of a *S. aureus* infection. It was complicated by haemorrhagic cerebrovascular accident and resulted in left haemiplegia. She received a 23 mm Medtronic Freestyle stentless bioprosthesis implanted as a complete aortic root. On examination, cardiac auscultation revealed an aortic diastolic murmur Grade 4/6. Euroscore II was 4.53%.

Preoperative TTE and TOE showed severe aortic regurgitation related to a tear of the non-coronary cusp. The ECG-gated cardiac CT scan revealed heavy calcifications of the sinus and sinotubular of the stentless valve. Aortic annulus area measurement was 320 mm<sup>2</sup> and area at the level of the sinotubular junction was 314 (Figure 3). The conclusion of the heart team, considering patient's age, was to attempt a conventional AVR with a mechanical prosthesis.

The aorta was opened above the stentless valve on the native aorta. The sinotubular junction was too stiff and narrow to be crossed by any mechanical or other conventional valves. A 23 mm Sapien 3 bioprosthesis was implanted using the 18Fr Certitude Delivery System (Edwards Lifescience, Inc.). Intraoperative TOE showed no PPR. The aortic XCT and the CPBT were 35 and 71 min,



**Figure 2** Operative view of the Sapien valve inserted in a heavily calcified aortic root.

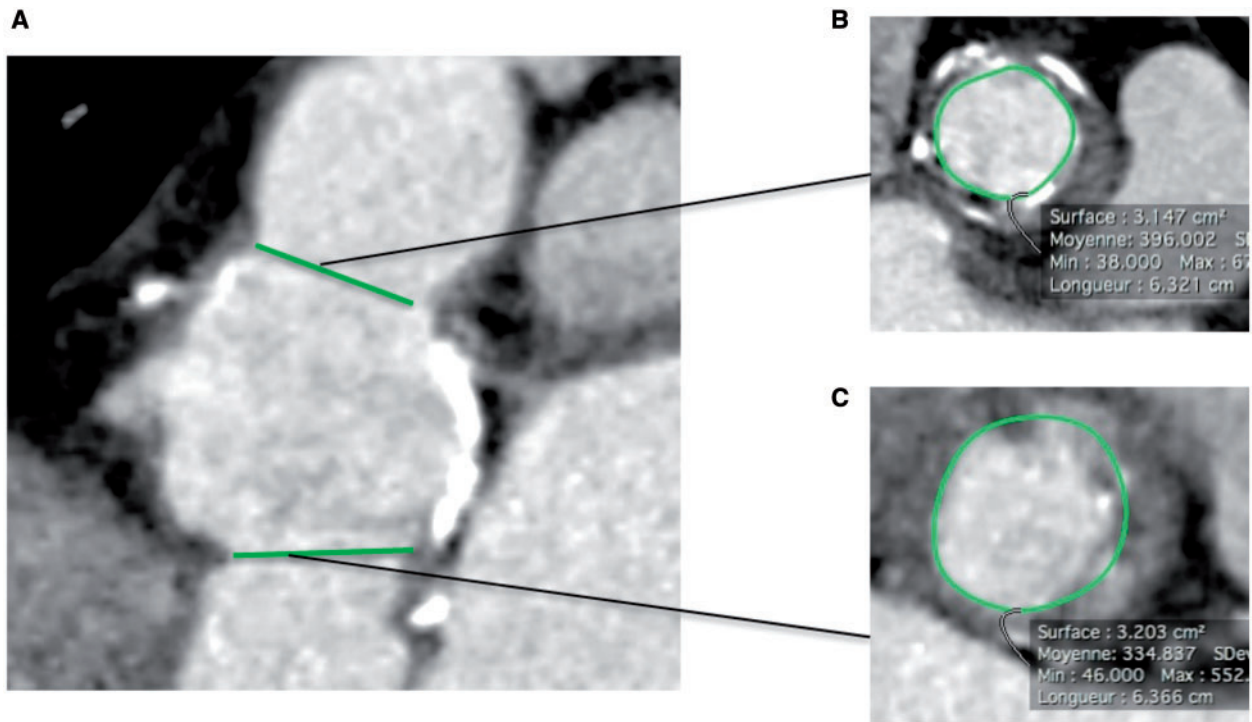
respectively. Post-operative course was uneventful. Mean transvalvular gradient was 20 mmHg, and no PPR was observed in TTE at discharge and 1 month after surgery.

## Discussion

The present study included three cases of high-risk patients who underwent successful open-heart transcatheter aortic valve replacement (TAVR) in complex aortic valve reoperation. Our main results are (i) open TAVR is a bail-out procedure that avoid the risk of complete root replacement in case of massively calcified homograft or stentless prosthesis. (ii) By combining the strengths of both TAVR and conventional AVR, open TAVR facilitates risky surgical procedure.

Reoperation for failure of aortic homograft and stentless aortic root remains challenging for the cardiac surgeon.<sup>1</sup>

In literature, redo AVR presents less risks than redo aortic root replacement.<sup>3,4</sup> Also, if possible, AVR is performed with conservation



**Figure 3** MDCT anatomy of the aortic root (A) with cross-section surface at the annular (B) and sinotubular junction (C) (for Patient 3).

of the calcified aortic root. Nevertheless, this technique is only feasible in half the cases,<sup>1</sup> if the homograft wall remained soft so a conventional aortotomy can be performed. When the aortic root presents major calcifications, the aortotomy has to be performed above the distal suture line of the conduit. Therefore, the procedure is performed afar from the aortic valve and an AVR may become difficult. This option can also be far-fetched, as in our three cases. The first reason is a narrow and calcified sinotubular junction. In fact, conventional or sutureless prosthesis are cumbersome and don't climb down upon the aortic annulus. In this case, the only option is an aortic root replacement. However, the dissection and relocation of the coronary arteries can be troublesome and thereby lead to a significant increase of the CPBT and therefore the risk of post-operative morbidity and mortality.<sup>5</sup>

The second is the impossibility to cross a calcified annulus with the needles so the valve cannot be sutured.

In young patients, transcatheter aortic valve implantation (TAVI) in first intention is rarely proposed because some doubts persist about its durability.<sup>6</sup> Moreover, the dimensions of the homograft or the stentless valve can be too small to allow a TAVR. The reasons are manifold: the surface of the aortic annulus, coronary height, sinus width, or diameter of the sinotubular junction. In the three cases presented here, age of patients (between 53 and 67 years old) made us attempt a conventional AVR with a biologic or mechanical prosthesis. Firstly, for reasons of sustainability, on the other hand for technical reasons when the anatomy of the failing prosthesis was incompatible with TAVI.

In the first case, the 23 sutureless bioprosthesis was too small and therefore responsible for severe PPR. It was replaced by a 26

bioprosthesis with good result. In this case, there was no pre-operative annulus sizing to determine the size of the prosthesis before the procedure. In the last two cases, preoperative sizing was performed allowing the right size of prosthesis on the first attempt.

One of the difficulties in implanting the valve is to deploy it at the level of the aortic ring. The achievement of this procedure in a hybrid room could allow to realize this deployment under scopic control after having marked the nadir of the three sinus of the aortic ring.

On the other hand, the advantage over a conventional TAVI is that the native valve and so the possible asymmetric calcifications are removed. The risk of occurrence of PPR is therefore decreased.<sup>7</sup> Furthermore, open TAVI reduces the risk of rupture of the aortic annulus and allows to slightly oversize the prosthesis when necessary; as in the latter case where a 23 mm Sapiens 3 was implanted whereas the sizing was too small to do it in conventional TAVI. In the same way, there is no risk of coronary occlusion since their permeability can be directly controlled once the prosthesis is in place.

In complex aortic valve reoperation, TAVI changed our attitude. A pre-TAVI scan is realized to measure the aortic annulus and choose the size of the TAVI prosthesis that will be implanted. During the intervention, TAVI's equipment is present in the room and the circulating nurse selected for the procedure is experienced in the techniques of preparation of the valve that will be used (crimping).

The lower profile of TAVR devices vs. conventional valves allow to cross the stiff and calcified root and provide a safe, rapid, and technically easy solution to replace the aortic valve in this hostile surrounding.

In complex aortic valve reoperation, open TAVI represents a very interesting option as a bail-out procedure when conventional valve/root replacement is not safely feasible.

**Consent:** The author/s confirm that written consent for submission and publication of this case report including image(s) and associated text has been obtained from the patient in line with COPE guidance.

**Conflict of interest:** F.C. and A.T. received consulting fees from Edwards Lifesciences.

## References

- Joudinaud TM, Baron F, Raffoul R, Pagis B, Vergnat M, Parisot C, Hvass U, Nataf PR. Redo aortic root surgery for failure of an aortic homograft is a major technical challenge. *Eur J Cardiothorac Surg* 2008;**33**:989–994.
- David S, Bach MD, Neal D, Kon MD. Long-term clinical outcomes 15 years after aortic valve replacement with the freestyle stentless aortic bioprosthesis. *Ann Thorac Surg* 2014;**97**:544–551.
- Daviewala PM, Borger MA, David TE, Rao V, Maganti M, Yau TM. Reoperation is not an independent predictor of mortality during aortic valve surgery. *J Thorac Cardiovasc Surg* 2006;**131**:329–335.
- Akins CW, Buckley MJ, Daggett WM, Hilgenberg AD, Vlahakes GJ, Torchiana DF, Madsen JC. Risk of reoperative valve replacement for failed mitral and aortic bioprostheses. *Ann Thorac Surg* 1998;**65**:1545–1551; discussion: 1551–1552.
- Al-Sarraf N, Thalib L, Hughes A, Houlihan M, Tolan M, Young V, McGovern E. Cross-clamp time is an independent predictor of mortality and morbidity in low- and high-risk cardiac patients. *Int J Surg* 2011;**9**:104–109.
- Sondergaard L. Time to explore transcatheter aortic valve replacement in younger, low-risk patients. *J Am Coll Cardiol Intv* 2016;**9**:2183–2185.
- Vasa-Nicotera M, Sinning J-M, Chin D, Lim TK, Spyt T, Jilaihawi H. Impact of paravalvular leakage on outcome in patients after transcatheter aortic valve implantation. *J Am Coll Cardiol Intv* 2012;**5**:858–865.