



**HAL**  
open science

## Bilateral Breast Ulcers: Granulomatosis with Polyangiitis

Pierre-André Jarrot, Marie-Laure Pelletier, Marion Brun, Martin Penicaud, Karin Mazodier, Audrey Benyamine, Jean Del Grande, Rodolphe Jean, Dominique Casanova, Gilles Kaplanski, et al.

► **To cite this version:**

Pierre-André Jarrot, Marie-Laure Pelletier, Marion Brun, Martin Penicaud, Karin Mazodier, et al.. Bilateral Breast Ulcers: Granulomatosis with Polyangiitis. *The American Journal of Medicine*, 2019, 132 (2), pp.179-181. 10.1016/j.amjmed.2018.09.008 . hal-02591551

**HAL Id: hal-02591551**

**<https://amu.hal.science/hal-02591551>**

Submitted on 15 May 2020

**HAL** is a multi-disciplinary open access archive for the deposit and dissemination of scientific research documents, whether they are published or not. The documents may come from teaching and research institutions in France or abroad, or from public or private research centers.

L'archive ouverte pluridisciplinaire **HAL**, est destinée au dépôt et à la diffusion de documents scientifiques de niveau recherche, publiés ou non, émanant des établissements d'enseignement et de recherche français ou étrangers, des laboratoires publics ou privés.



Distributed under a Creative Commons Attribution - NonCommercial - NoDerivatives 4.0 International License



# Bilateral Breast Ulcers: Granulomatosis with Polyangiitis

Pierre-André Jarrot, MD,<sup>a</sup> Marie-Laure Pelletier, MD,<sup>b</sup> Marion Brun, MD,<sup>a</sup> Martin Penicaud, MD,<sup>c</sup> Karin Mazodier, MD,<sup>a</sup> Audrey Benyamine, MD, PhD,<sup>d</sup> Jean Del Grande, MD,<sup>e</sup> Rodolphe Jean, MD,<sup>a</sup> Dominique Casanova, MD,<sup>f</sup> Gilles Kaplanski, MD, PhD,<sup>a</sup> Pierre-Jean Weiller, MD<sup>g</sup>

<sup>a</sup>Service de Médecine Interne et d'Immunologie Clinique, CHU Conception, Assistance Publique-Hôpitaux de Marseille (AP-HM), Marseille, France; <sup>b</sup>Service de Chirurgie Esthétique, Clinique de La Casamance, Aubagne, France; <sup>c</sup>Service de chirurgie ORL, CHU Conception, AP-HM, Marseille, France; <sup>d</sup>Service de Médecine Interne, CHU Nord, AP-HM, Marseille, France; <sup>e</sup>Laboratoire d'Anatomopathologie, CHU Timone AP-HM, Marseille, France; <sup>f</sup>Service de Chirurgie Plastique, CHU Conception, AP-HM, Marseille, France; <sup>g</sup>Service d'Onco-Hématologie, Institut Paoli-Calmettes, Marseille, France.

## PRESENTATION

An investigation into the patient's unusual dermatologic symptoms identified an underlying autoimmune disease. Fourteen days after breast-reduction surgery, the patient, a 25-year-old white woman, was completely recovered. But at 20 days after surgery, she had bilateral mammary ulcerative lesions and was admitted to another hospital. The lesions were painless, and she was afebrile. Negative pressure wound therapy failed to accomplish secondary intention healing. For 6 weeks, she was treated with oral prednisolone, 1 mg/kg/day, and hyperbaric oxygen therapy, but these had limited effect. She then underwent a biopsy of the right breast.

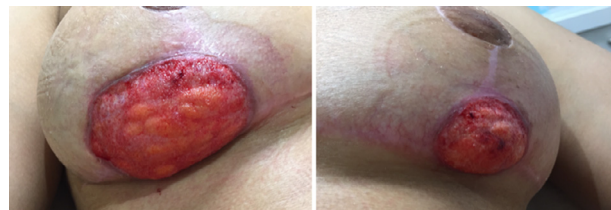The specimen showed perivascular inflammation of the superficial and deep dermis, as denoted by an infiltrate of numerous neutrophils, eosinophils, lymphocytes, and some giant cells. Areas of nonfibrinoid necrosis were evident in the superficial dermis. Bacterial cultures of the wound and blood were negative. A diagnosis of pyoderma gangrenosum was suspected based on the necrotic ulceration and characteristic violaceous undermined borders of the patient's lesions, the high proportion of neutrophils in the biopsy specimen, and the appearance of lesions on the scar site after a complete recovery. Yet, though the biopsy

findings suggested pyoderma gangrenosum, there was some atypia, such as the absence of a central necrotic zone. Treatment with prednisolone and hyperbaric oxygen was restarted 5 days after biopsy results returned. She was then referred to our internal medicine department for further work-up.

## ASSESSMENT

On admission, the patient was afebrile. She had bilateral, painless, inframammary ulcerations with inflammatory borders (Figure 1A). These measured 5 cm in diameter and ran horizontally across the surgical scar line. She also had pain in the sinus region. She reported a 1-year history of rhinitis with crusting and bleeding in both nostrils. Treatment had consisted of several courses of corticosteroids and antibiotics, which offered transient relief from symptoms, and ultimately, she underwent nasal septum surgery. Interestingly, the patient's ear, nose, and throat symptoms improved while she was being treated with prednisolone for her mammary lesions.

Laboratory tests revealed elevations in the plasma fibrinogen level (5.4 g/L) and the C-reactive protein levels



**Figure 1** On presentation, the patient had bilateral ulcerative mammary lesions.

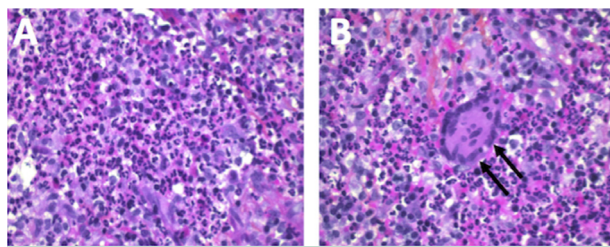
**Funding:** None.

**Conflict of interest:** None.

**Authorship:** All authors had full access to data and contributed to the writing of this manuscript.

Requests for reprints should be addressed to Dr Pierre-André Jarrot, Department of Internal Medicine and Clinical Immunology, CHU Conception, Assistance Publique-Hôpitaux de Marseille, 135 boulevard Baille, 13005 Marseille, France, Phone: +33 4 91 38 35 22

E-mail address: [Pierre.jarrot@ap-hm.fr](mailto:Pierre.jarrot@ap-hm.fr)



**Figure 2** An endonasal biopsy was performed. The specimen showed a perinecrotic inflammatory infiltrate with numerous eosinophils (A). A granulomatous reaction was also noted. The arrows indicate a giant cell (arrows) (B).

(20 mg/L). Serologic tests for hepatitis B, hepatitis C, and HIV were negative. A blood polymerase chain reaction test for Epstein-Barr virus was negative, as were repeated bacterial cultures of the lesion and blood. An interferon-gamma release assay (Quantiferon-TB Gold, Qiagen, Venlo, Netherlands) was negative for *Mycobacterium tuberculosis*. A serum angiotensin-converting enzyme level was normal. Indirect immunofluorescence was repeatedly positive for cytoplasmic antineutrophil cytoplasmic antibodies (c-ANCA), and an enzyme-linked immunosorbent assay identified the c-ANCAs as having anti-proteinase-3 specificity (99 U/mL; normal, < 10). The patient had a normal serum creatinine level, and a urinalysis was negative for sediment and protein.

Nasal endoscopy disclosed an inflamed, bleeding nasal septum. Computed tomography showed thickening of the maxillary sinus wall but no additional lesions. An endonasal biopsy demonstrated severely inflamed mucosa with numerous neutrophils and eosinophils, focal necrotic areas, and a granulomatous reaction (Figures 2A and 2B).

## DIAGNOSIS

Together, the clinical, laboratory, and histologic findings supported a diagnosis of granulomatosis with polyangiitis, formerly known as Wegener's granulomatosis, with breast and sinus involvement. Patients with this ANCA-associated vasculitis typically present with granulomas of the ear, nose, throat, and upper and lower respiratory tract and pauci-immune glomerulonephritis.<sup>1</sup> In contrast, our patient presented with malignant pyoderma. Laboratory testing usually discloses positive c-ANCA levels directed to the anti-proteinase-3 subtype of c-ANCA.

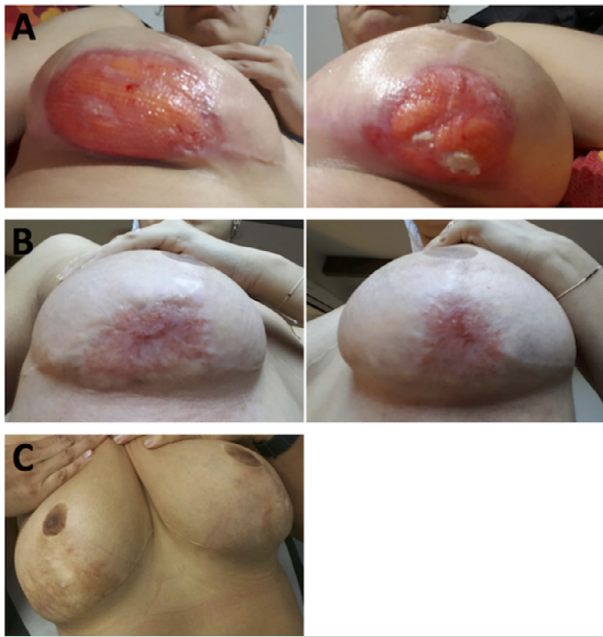After ruling out an infection, we initially suspected pyoderma gangrenosum. This rare but well-known and feared postoperative inflammatory complication has potentially devastating consequences. Characterized by a rapidly expanding cutaneous ulcer at the incision site, it has mainly been reported after breast surgery, particularly breast-reduction surgery.<sup>2</sup> Although the patient's recent history of breast surgery and the initial presentation of the lesions were suggestive of pyoderma gangrenosum, the painlessness, the absence of dermal fibrinoid necrosis, and

the relative resistance to corticosteroids were unusual for that condition. Research has found that 10% of patients believed to have pyoderma gangrenosum actually had a disease that mimics it.<sup>3</sup>

Our patient's ear, nose, and throat manifestations prompted us to consider a diagnosis of granulomatosis with polyangiitis. The supporting evidence included the histopathological necrotic intranasal granulomatous reaction and the recurrent positive tests for c-ANCA anti-proteinase-3 antibodies. Breast involvement in granulomatosis with polyangiitis, first described in 1969, is rare, affecting just 2.3% of women in a series of 216 patients.<sup>4,5</sup> In a systematic review of 27 patients, women presenting with a granulomatous mastitis had other systemic manifestations of granulomatosis with polyangiitis or had already been diagnosed. However, no specific local trigger for breast involvement, such as recent breast surgery, was identified in any of them.<sup>6</sup>

Although there is no record of our patient's presurgical c-ANCA measurement, it is tempting to speculate that the local trauma caused by mammary reduction induced local inflammation, cytokine production, and neutrophil activation, which in combination with the presence of circulating c-ANCAs, favored the emergence of focal vasculitis at the surgical site. The process would resemble the so-called Koebner phenomenon, in which lesions develop at a site where skin trauma has occurred. Notably, this occurs in patients with autoimmune disease, particularly psoriasis and systemic lupus erythematosus—and sometimes in patients with no previous history of cutaneous lesions. Moreover, this idea is in accordance with the concept that ANCA-associated vasculitis is a two-hit disease, requiring both the presence of ANCAs and an inflammatory trigger, usually infectious, but in this case mechanical, to induce neutrophil priming and activation.<sup>7</sup>

Dermatological symptoms, mainly presenting with palpable purpura, segmentary edema, or nodules, have been reported in approximately 30-50% of patients who have granulomatosis with polyangiitis.<sup>8</sup> These manifestations, however, might on occasion mimic other diseases, such as the neutrophilic dermatoses. Then again, patients might actually have a neutrophilic dermatosis or a disorder that closely resembles one. In one recent study examining a possible connection between neutrophilic dermatoses and ANCA-associated vasculitis, pyoderma gangrenosum was identified in 8 of 17 patients, and all 8 had granulomatosis with polyangiitis.<sup>9</sup> Of an additional 50 patients described in the literature, 29 of 38 with a diagnosis of granulomatosis with polyangiitis also had pyoderma gangrenosum. Only 4 with pyoderma gangrenosum had a different form of vasculitis, specifically microscopic polyangiitis. The findings suggest a possible common pathophysiological link, perhaps because of neutrophil dysregulation, between granulomatosis with polyangiitis and pyoderma gangrenosum.



**Figure 3** With treatment, the patient's bilateral ulcerative mammary lesions resolved over time. The lesions at 2 months (A). The lesions at 5 months (B). One year after induction therapy, the patient had a complete recovery (C).

Thus, pyoderma gangrenosum could be a cutaneous manifestation of granulomatosis with polyangiitis in some patients. Malignant pyoderma, a different disorder that looks like pyoderma gangrenosum, has been documented infrequently in this group. Unlike pyoderma gangrenosum, it occurs mainly on the face. Severe inflammation is compounded by extreme damage to ulcerated areas, and often, systemic symptoms. To differentiate between malignant pyoderma and pyoderma gangrenosum, physicians should pay attention to extracutaneous symptoms. Additionally, the histologic findings are atypical for pyoderma gangrenosum, and the lesions can progress, despite treatment. The possibility exists that patients who present with pyoderma gangrenosum—or malignant pyoderma, as in our patient's case—have an underlying granulomatosis with polyangiitis, so ANCA testing and histopathology should be considered.

To the best of our knowledge, we are reporting the first case of granulomatosis with polyangiitis to present as a pseudo-pyoderma gangrenosum following breast-reduction surgery. Although our patient did not have any history of dermatitis, the occurrence of lesions in healthy skin could be, as noted, related to a process like the Koebner phenomenon. To date, only two cases of the Koebner phenomenon have been reported in patients with ANCA-associated

vasculitis; in one, a patient with recurring leg ulcers was found to have a high level of perinuclear ANCA.<sup>10,11</sup>

## MANAGEMENT

Our patient received induction therapy with oral corticosteroids, 0.7 mg/kg/day, and rituximab, 375 mg/m<sup>2</sup>, once weekly for 4 weeks, according to recommendations from the European Vasculitis Society.<sup>12</sup> Rituximab is thought to deplete the population of B cells with a CD20 marker; B cells responsible for the manufacture of ANCA. Clinical remission was slowly achieved, and a final complete recovery occurred after 5 months (Figure 3A and 3B). To date, with a follow-up of 2 years, the patient is still in remission with negative ANCA tests (Figure 3C). She is maintained on rituximab, 500 mg, administered every 6 months.

## References

- Jarrot PA, Kaplanski G. Pathogenesis of ANCA-associated vasculitis: An update. *Autoimmun Rev*. 2016;15:704–713.
- Zuo KJ, Fung E, Tredget EE, Lin AN. A systematic review of post-surgical pyoderma gangrenosum: identification of risk factors and proposed management strategy. *J Plast Reconstr Aesthet Surg*. 2015;68:295–303.
- Weenig RH, Davis MD, Dahl PR, Su WP. Skin ulcers misdiagnosed as pyoderma gangrenosum. *N Engl J Med*. 2002;347:1412–1418.
- Elsner B, Harper FB. Disseminated Wegener's granulomatosis with breast involvement. Report of a case. *Arch Pathol*. 1969;87:544–547.
- Lie JT. Wegener's granulomatosis: histological documentation of common and uncommon manifestations in 216 patients. *Vasa*. 1997;26:261–270.
- Allende DS, Booth CN. Wegener's granulomatosis of the breast: a rare entity with daily clinical relevance. *Ann Diagn Pathol*. 2009;13:351–357.
- Falk RJ, Jennette JC. ANCA disease: where is this field heading? *J Am Soc Nephrol*. 2010;21:745–752.
- Frumholtz L, Laurent-Roussel S, Aumaitre O, et al. French Vasculitis Study Group. Clinical and pathological significance of cutaneous manifestations in ANCA-associated vasculitides. *Autoimmun Rev*. 2017;16:1138–1146.
- de Boysson H, Martin Silva N, de Moreuil C, et al. French Vasculitis Study Group, French Internal Medicine Society. Neutrophilic dermatoses in antineutrophil cytoplasmic antibody-associated vasculitis: a French multicenter study of 17 cases and literature review. *Medicine (Baltimore)*. 2016;95:e2957.
- Papi M, Didona B, Chinni LM, et al. Koebner phenomenon in an ANCA-positive patient with pyoderma gangrenosum. *J Dermatol*. 1997;24:583–586.
- Tourte M, Lheure C, Gras J, et al. Koebner phenomenon in eosinophilic granulomatosis with polyangiitis (Churg-Strauss). *Acta Derm Venereol*. 2017;97:965–966.
- Yates M, Watts RA, Bajema IM, et al. EULAR/ERA-EDTA recommendations for the management of ANCA-associated vasculitis. *Ann Rheum Dis*. 2016;75:1583–1594.