



HAL
open science

Rhythmic rocking stereotypies in frontal lobe seizures: A quantified video study

Jen-Cheng Hou, Monique Thonnat, Raoul Huys, Fabrice Bartolomei, Aileen
Mcgonigal

► **To cite this version:**

Jen-Cheng Hou, Monique Thonnat, Raoul Huys, Fabrice Bartolomei, Aileen Mcgonigal. Rhythmic rocking stereotypies in frontal lobe seizures: A quantified video study. *Neurophysiologie Clinique = Clinical Neurophysiology*, 2020, 50 (2), pp.75 - 80. 10.1016/j.neucli.2020.02.003 . hal-02878968

HAL Id: hal-02878968

<https://amu.hal.science/hal-02878968v1>

Submitted on 23 Jun 2020

HAL is a multi-disciplinary open access archive for the deposit and dissemination of scientific research documents, whether they are published or not. The documents may come from teaching and research institutions in France or abroad, or from public or private research centers.

L'archive ouverte pluridisciplinaire **HAL**, est destinée au dépôt et à la diffusion de documents scientifiques de niveau recherche, publiés ou non, émanant des établissements d'enseignement et de recherche français ou étrangers, des laboratoires publics ou privés.



Distributed under a Creative Commons Attribution - NonCommercial - NoDerivatives 4.0
International License

Rhythmic rocking stereotypies in frontal lobe seizures: A quantified video study

Jen-Cheng Hou, Monique Thonnat, Raoul Huys, Fabrice Bartolomei, Aileen
Mcgonigal

► **To cite this version:**

Jen-Cheng Hou, Monique Thonnat, Raoul Huys, Fabrice Bartolomei, Aileen Mcgonigal. Rhythmic rocking stereotypies in frontal lobe seizures: A quantified video study. *Neurophysiologie Clinique/Clinical Neurophysiology*, Elsevier Masson, 2020, 50, pp.75 - 80. 10.1016/j.neucli.2020.02.003 . hal-02878968

HAL Id: hal-02878968

<https://hal-amu.archives-ouvertes.fr/hal-02878968>

Submitted on 23 Jun 2020

HAL is a multi-disciplinary open access archive for the deposit and dissemination of scientific research documents, whether they are published or not. The documents may come from teaching and research institutions in France or abroad, or from public or private research centers.

L'archive ouverte pluridisciplinaire **HAL**, est destinée au dépôt et à la diffusion de documents scientifiques de niveau recherche, publiés ou non, émanant des établissements d'enseignement et de recherche français ou étrangers, des laboratoires publics ou privés.

Rhythmic rocking stereotypies in frontal lobe seizures: A quantified video study

Jen-Cheng Hou^a, Monique Thonnat^a, Raoul Huys^b,
Fabrice Bartolomei^{c,d}, Aileen McGonigal^{c,d,*}

^a INRIA Sophie Antipolis – Méditerranée, université Nice Côte d'Azur, 06902 Valbonne, France

^b CNRS UMR 5549 CERCO (centre de recherche cerveau et cognition), université de Toulouse, CHU Purpan, pavillon Baudot, 31052 Toulouse cedex, France

^c Inserm, INS (institut de neurosciences des systèmes), Aix-Marseille université, 13005 Marseille, France^d
Service de neurophysiologie clinique, hôpital de la Timone, AP–HM, 13005 Marseille, France

Received 1st November 2019; accepted 15 February 2020

Available online 4 March 2020

KEYWORDS

Frequency;
Frontal seizures;
Rocking;
Stereotypies;
Video quantification

Summary

Objectives. – Rhythmic, stereotyped movements occur in some epileptic seizures. We aimed to document time-evolving frequencies of antero-posterior rocking occurring during prefrontal seizures, using a quantitative video analysis.

Methods. – Six seizures from 3 patients with prefrontal epilepsy yet different sublobar localizations were analyzed using a deep learning-based head-tracking method.

Results. – Mean rocking frequency varied between patients and seizures (0.37–1.0 Hz). Coefficient of variation of frequency was low ($\leq 12\%$).

Discussion. – Regularity of body rocking movements suggests a mechanism involving intrinsic oscillatory generators. Since localization of seizure onset varied within prefrontal cortex across patients, altered dynamics converging on a ‘‘final common pathway’’ of seizure propagation involving cortico-subcortical circuits is hypothesized.

© 2020 Elsevier Masson SAS. All rights reserved.

Introduction

Rhythmic movement patterns constitute typical functional motor behaviors across species and across the lifes-

Corresponding author. Service de neurophysiologie clinique, CHU Timone, AP–HM, Marseille, France.

pan [14], and are considered to arise from subcortical central pattern generators [19,28]. Stereotyped non-functional rhythmic movements are observed in sleep disorders [26], movement disorders [11,13], and epilepsy [38]. To date, very little data exist quantifying the time-evolving frequencies of these movement sequences, which is unfortunate as these may help in elucidating the mechanisms underlying such pathological behaviors. Semiological ‘‘fingerprints’’ of similar rhythmic movements occurring in both epileptic seizures and sleep disorders have led to

E-mail address: aileen.mcgonigal@univ-amu.fr (A. McGonigal).

speculation of possible shared mechanisms [38]. However, understanding of these is limited, notably in terms of how higher cortical circuits might interact with subcortical components of the motor system to produce similar clinical expressions in conditions with different physiopathologies [13,30,38], even though the neural circuitry involved in repetitive behaviors is increasingly well characterized from animal models, notably in terms of defining the cortico-striatal circuitry involved. Methods allowing more precise documentation of clinical and physiological phenomena involving complex motor patterns might facilitate further investigation and understanding of this relatively unknown domain [6,30].

Rhythmic movements are a common feature of epileptic seizures, the best-known example being clonic jerk movements in the context of generalized tonic-clonic seizures [16,27]. Other seizure-related rhythmic movements involve multi-segmental motor behaviors, which can involve the axial segment (e.g. rocking movements of the trunk) [34] or upper or lower limbs (e.g. bicycling-like movements of the lower limbs, hand tapping) [5]. Oro-alimentary automatisms may also occur rhythmically [3,31]. Amongst possible methods of movement quantification in neurological disorders (for comprehensive review, see [12]), there is increasing interest in video analysis techniques, including those based on deep learning or machine learning, for automated analysis of movements in epileptic seizures [1,2,7,8,33] and for motor stereotypies (e.g., in autism [20]). However, such studies have tended to focus on detection and categorization of movement patterns; quantification of multi-segmental rhythmic behaviors in terms of time-evolving movement frequencies has not yet been reported. Here, we describe a series of prefrontal seizures characterized by highly stereotyped rhythmic antero-posterior body rocking movements, analyzed using quantitative video methods as well as electroencephalography (EEG).

Methods

Clinical data

Videos recorded in the context of presurgical epilepsy evaluation in Timone University Hospital, Marseille, France were studied. All patients provided written informed consent for use of data. From a series of 220 cases of frontal epilepsy, 3 patients demonstrated a characteristic pattern of antero-posterior rocking during epileptic seizures. Two patients had intracerebral electrode exploration with stereoelectroencephalography (SEEG) and one had surface video-EEG. All had full presurgical work-up including neuroimaging.

Video method

Videos of seizures with rocking movements were analyzed using a head tracking method (see [Video file](#)). Recorded seizures in which rocking movements were not clearly visible were excluded. Each seizure video was converted into an image sequence under 25 frame-per-second and resized to 512×512 pixels dimension.

Video processing consisted of four parts: head detection, denoising, peak detection, and frequency analysis. First, the

head of the patient was detected in each video by utilizing a robust detector: the Single Shot Multibox Detector (SSD) network [24], a deep learning-based model. We opted for this approach as partial occlusions and changing environmental lighting conditions, could have jeopardized the performance of simpler head detection approaches. The location of the head was manually annotated for 10-15% of the image samples per video, selected randomly, then SSD was used for head detection. The SSD network is pre-trained on ImageNet [10], a large-scaled image recognition dataset. The pre-trained weights were used as the initialization weights for the SSD network while the network was retrained with the manually labelled samples for fine-tuning the network. After head detection throughout the whole video, the head movement trace was computed in the horizontal and vertical direction. This was then normalized between 0 and 1, and denoised in both directions by filtering with Empirical Mode Decomposition (EMD) [42], which breaks down signals into different components. The method is purely data-driven and suitable for non-stationary and nonlinear signals, which corresponds to the conditions for our movement traces. The head movement trace was decomposed into several components, Intrinsic Mode Functions (IMFs). By adding the IMFs except the first, which revealed higher frequency components, we reconstructed and obtained the denoised trace signal.

Peaks of the traces in both directions were next detected for calculating the cyclic head movement frequencies. To identify peaks corresponding to real antero-posterior movements, we referred to the traces in both directions. We defined two functions f and g , such that $f(n_x)$ and $g(n_y)$ represent the trace value in the horizontal and vertical directions at time-sampled points n_x and n_y . In addition, n_x and n_y are denoted as n_{xp} and n_{yp} respectively, once $f(n_x)$ and $g(n_y)$ are viewed as peaks. If $|n_{xp} - n_{yp}| < T$ where T is a threshold for deciding how close the peaks in the traces from both directions are to be considered as real peaks associated with antero-posterior head movement.

Results

Clinical and neurophysiological results

Localization by SEEG showed low voltage fast epileptic discharge in a widespread right dorsolateral prefrontal distribution for patient 1, and focally in the left orbitofrontal cortex for patient 2. Patient 3 did not require SEEG for presurgical work-up since non-invasive investigations including high resolution scalp EEG and positron emission tomography confirmed focal right prefrontal epilepsy organization (right intermediate frontal sulcus). All 3 patients had normal neuroimaging. All 3 underwent subsequent cortectomy, with cure of epileptic seizures and disappearance of stereotyped behavior, with minimally 2 years' follow-up. Etiology of epilepsy was cryptogenic in patient 1 and due to focal cortical dysplasia in patients 2 and 3.

Video analysis

Six seizure videos with antero-posterior rocking movement from the 3 patients were included. Duration of rock-

Table 1 Data for each video on frequency of rocking movements, as calculated using automated head tracking.

	Seizure 1 (patient 1)	Seizure 2 (patient 1)	Seizure 3 (patient 1)	Seizure 4 (patient 1)	Seizure 5 (patient 2)	Seizure 6 (patient 3)
Duration of seizure-related rocking (sec)	16	20	17	14	40	15
Maximum (Hz)	0.49	1.23	0.76	0.97	0.42	0.79
Minimum (Hz)	0.46	0.77	0.54	0.73	0.33	0.63
Median (Hz)	0.48	1.01	0.63	0.92	0.36	0.72
Standard deviation (Hz)	0.02	0.12	0.06	0.08	0.03	0.05
Mean (Hz)	0.48	1.00	0.63	0.90	0.37	0.71
Coefficient of variation (%)	4.17	12	9.52	8.89	8.11	7.04

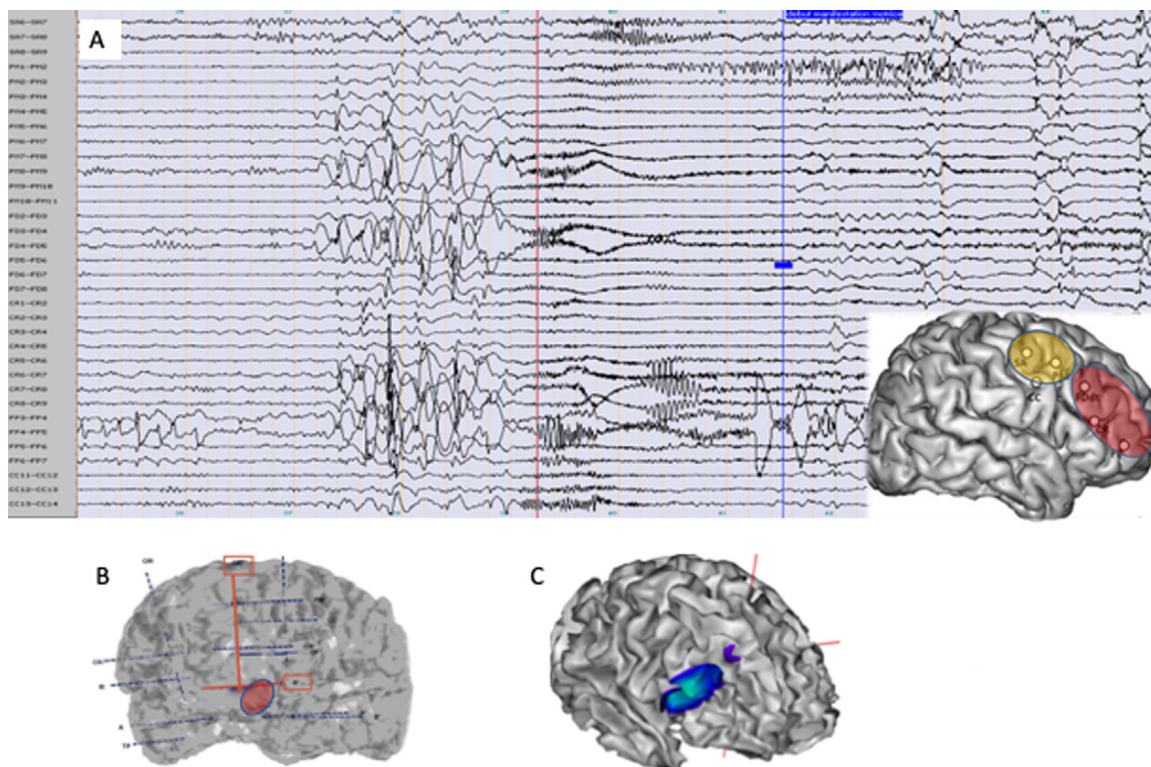


Figure 1 A. Ictal SEEG trace from patient 1 (10seconds per page, 50 microV/mm). Note preictal spiking across a widespread right predominantly dorsolateral prefrontal distribution, followed by abrupt transition to a low voltage fast discharge in the gamma band (vertical red line), showing similar distribution as the preictal spikes. A less tonic and slightly later discharge is seen in electrodes exploring right premotor cortex (top of SEEG trace). The first semiological sign (sudden onset of antero-posterior rhythmic rocking and altered contact; vertical blue line) occurs approximately 3 seconds after electrical seizure onset, at which point slower diffuse rhythmic activity is seen on SEEG. Inset to panel A: schematic illustration of epileptogenic zone of Patient 1, with right dorsolateral prefrontal organisation projecting to premotor areas. B. Patient 2: focal left orbitofrontal organisation of epileptogenic zone, based on SEEG exploration. C. Patient 3: focal right intermediate frontal sulcus organisation of epileptogenic zone, based on non-invasive presurgical evaluation; here, source localisation of HR-EEG interictal data is shown.

ing within seizures lasted 15-40sec (mean 16.5). Mean frequency of rocking movements was 0.37–1.00 Hz (median 0.67) (Table 1). Each seizure was characterized by a stable frequency of rocking throughout its duration, with a mean coefficient of variation 8.3% (Table 1, Figs. 1 and 2).

Discussion

The directionality and regularity of rhythmic axial rocking movements were highly stereotyped across seizures

and patients, without goal-directed or habitual behavior [37]. Body rocking also occurs in sleep-related movement disorder [29], or “self-stimulatory behaviors” [25] e.g., in autism, as well as in normal infant development [39]. Anteroposterior spinal rocking is relatively uncommon in epileptic seizures and has only been seen by us in a context of prefrontal epilepsy; such a pattern occurs in only a small proportion of seizures involving prefrontal cortex (around 1% in our series). The 3 cases reported here represent the only ones with this characteristic semiology

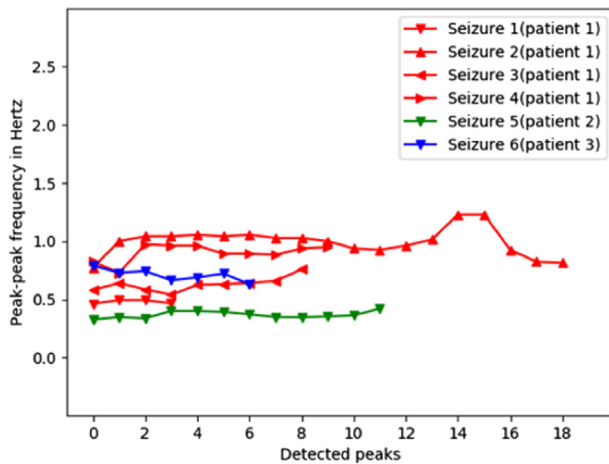


Figure 2 Peak-peak frequency in hertz for each detected peak in each seizure video. The color represents individual patients.

ical pattern seen in our Epilepsy Unit over decades of recording.

The repetition, rhythmicity, cyclicity and topographical similarity suggest a pathophysiological role for a temporal assembly of neural structures acting as an oscillator [18,23], with clinical expression reflecting interaction between nervous system activity and biomechanical dynamics of the musculoskeletal system [21]. Rocking frequency varied between individuals and between seizures, within a mean range (0.37–1.0 Hz) overlapping with but slightly lower than that associated with most physiological rhythmic behaviors (0.8–2 Hz) [32] and those occurring in sleep disorders (0.5–2 Hz) [26]. Despite the short durations available for calculation, each sequence showed a stable frequency throughout, in keeping with the reduced variability typically associated with stereotyped movements [41]. The coefficient of variation was similar to that reported for healthy gait [22]. It is of interest that patient 1, who presented 4 seizures with rocking, showed slight differences in rocking frequency between seizures, suggesting that these were not caused by rigidly predetermined rhythmic generators. The observation that the rocking frequency differed somewhat between seizures may reflect individual differences, as for spontaneous natural rocking [35]. Seizure-specific factors may also have played a role, for example, variations in frequency of cortical seizure discharge, and degree of synchrony between key structures, may contribute to differences in clinical output. Higher rocking frequencies were related to smaller amplitudes (e.g. upper trunk rocking rather than whole body), in keeping with known biomechanical effects of inertia [4]. Antero-posterior directionality remained the same throughout each seizure.

Repetitive, rhythmic movement patterns in frontal lobe seizures may be characterized as stereotypies [5,13], whose segmental distribution was previously shown to be correlated with localization of the epileptogenic zone along a rostro-caudal axis: axial/proximal motor stereotypies were associated with more posterior frontal regions and distal stereotypies with anterior prefrontal regions [30]. All seizures here showed prefrontal cortex epileptic discharge, but with different sublobar localization across

patients. Thus, the here observed movement patterns were not directly related to epileptic activity within a single specific cortical region [5], but suggested an effect involving associative motor regions that might project to a “final common pathway” underlying the repetitive movements. Clinical expression would likely depend on subcortical circuits triggered by different possible cortical localizations of epileptic activity [40] and probably specific temporal (frequency, synchrony) conditions of discharge [3,6].

From a hierarchical perspective of nervous system organization, abnormal triggering of innate movement patterns may occur by top-down “release” due to transiently altered dynamics within topographically organized cortico-subcortical motor control circuits [36], as has been suggested for some other seizure patterns involving “programmed” behaviors (e.g. rhythmic movements related to locomotion or mastication) [15]. From an ontogenetic perspective, fetal somersaults around the transverse axis occur from around 12 weeks’ gestation [9]; in addition, rhythmic stereotypies seem to play a specific developmental role in normal infants, with rhythmic trunk movements occurring mainly between 6 and 12 months of age [39]. Phylogenetically, rhythmic spinal flexion underlies rectilinear locomotion in some limbless vertebrates [17].

In previous SEEG work on seizure-related orolimentary automatism, the authors suggested that functional coupling between cortical structures during seizures may be responsible for a top-down effect on outflow pathways from masticatory cortex [3]. Similarly, specific synchronization dynamics created during certain prefrontal seizures might allow expression of subcortical generators of regular, stereotyped, rhythmic movement, in this case involving spinal musculature.

Limitations of our work include the use of a single camera, which allowed 2-D video analysis. More data allowing more detailed characterization of movements could have been achieved using a 3-D video approach, through recording with multiple cameras placed at different angles to the subject. A novel 3-D method, NeuroKinect, has recently been used to successfully record and quantify movements in epileptic seizures [7]. One specific advantage of a multi-camera approach in the present series would have been a lateral view of these movements, which could have allowed assessment of their amplitude. However, since the present data came from a retrospective series recorded in the conventional way in our videotelemetry unit, we were obliged to work with the available video data. The other major limitation is the small number of cases (due to the rarity of this specific semiological pattern), and the possibility that including several seizures from the same patient was a source of bias in determining the mean rocking frequency of the whole group.

Conclusion

Automated video analysis confirmed stable frequency throughout rocking sequences in the prefrontal seizures, suggesting a mechanism involving intrinsic oscillatory generators. Since localization of seizure onset varied within prefrontal cortex across patients, altered dynamics within a “final common pathway” involving cortico-subcortical

movement circuits is hypothesized. Further work on time-evolving frequencies of stereotyped movements across a range of pathologies could help shed light on possible shared pathophysiological mechanisms; to this end, documentation of kinematic properties of stereotypies using automated video analysis could be a useful tool. Future studies could focus on a larger series of seizures with complex motor behaviors, aiming to identify clinical subgroups based on automated video analysis (including a control group), and to correlate these with intracerebral EEG signal analysis.

Disclosure of interest

The authors declare that they have no competing interest.

Acknowledgements

The authors wish to thank Daniele Schön and Benjamin Morillon, INS Marseille, for helpful discussion. This paper has been carried out within the Federation Hospitalo-Universitaire (FHU) EPINEXT thanks to the support of the A*MIDEX project (ANR-11-IDEX-0001-02) funded by the "Investissements d'Avenir" French Government program managed by the French National Research Agency (ANR).

Appendix A. Supplementary data

Supplementary data associated with this article can be found, in the online version, at <https://doi.org/10.1016/j.neucli.2020.02.003>.

References

- [1] Abbasi B, Goldenholz DM. Machine learning applications in epilepsy. *Epilepsia* 2019;60:2037–47.
- [2] Ahmedt-Aristizabal D, Fookes C, Dionisio S, Nguyen K, Cunha JPS, Sridharan S. Automated analysis of seizure semiology and brain electrical activity in presurgery evaluation of epilepsy: a focused survey. *Epilepsia* 2017;58:1817–31.
- [3] Aupy J, Noviauwaty I, Krishnan B, Suwankpakdee P, Bulacio J, Gonzalez-Martinez J, et al. Insulo-opercular cortex generates orolimentary automatism in temporal seizures. *Epilepsia* 2018;59:583–94.
- [4] Beek P, Peper C, Stegeman D. Dynamical models of movement coordination. *Hum Mov Sci* 1995;14:573–608.
- [5] Bonini F, McGonigal A, Trébuchon A, Gavaret M, Bartolomei F, Giusiano B, et al. Frontal lobe seizures: from clinical semiology to localization. *Epilepsia* 2014;55:264–77.
- [6] Chauvel P, McGonigal A. Emergence of semiology in epileptic seizures. *Epilepsy Behav* 2014;38:94–103.
- [7] Cunha JPS, Choupina HMP, Rocha AP, Fernandes JM, Achilles F, Loesch AM, et al. NeuroKinect: a novel low-cost 3D video-EEG system for epileptic seizure motion quantification. *PLoS One* 2016;11:e0145669.
- [8] Cunha JPS, Paula LM, Bento VF, Bilgin C, Dias E, Noachtar S. Movement quantification in epileptic seizures: a feasibility study for a new 3D approach. *Med Eng Phys* 2012;34:938–45.
- [9] De Vries JI, Visser GH, Prechtel HF. The emergence of fetal behaviour. I. Qualitative aspects. *Early Hum Dev* 1982;7:301–22.
- [10] Deng J, Dong W, Socher R, Li L-J, Li K, Fei-Fei L. Imagenet: a large-scale hierarchical image database. *Proceedings of the IEEE Computer Society Conference on Computer Vision and Pattern Recognition*; 2009. p. 248–55, <http://dx.doi.org/10.1109/CVPR.2009.5206848>.
- [11] Deuschl G, Bain P, Brin M. Consensus statement of the Movement Disorder Society on Tremor. *Ad Hoc Scientific Committee. Mov Disord* 1998;13(Suppl 3):2–23.
- [12] do Carmo Vilas-Boas M, Silva Cunha JP. Movement quantification in neurological diseases: methods and applications. *IEEE Rev Biomed Eng* 2016;9:15–31.
- [13] Edwards MJ, Lang AE, Bhatia KP. Stereotypies: a critical appraisal and suggestion of a clinically useful definition. *Mov Disord* 2012;27:179–85.
- [14] Gallistel CR. *The organization of action: a new synthesis*. London: Psychology Press; 2013.
- [15] Gardella E, Rubboli G, Francione S, Tassi L, Lo Russo G, Grillner S, et al. Seizure-related automatic locomotion triggered by intracerebral electrical stimulation. *Epileptic Disord* 2008;10:247–52.
- [16] Gastaut H, Broughton RJ. *Epileptic seizures: clinical and electrographic features, diagnosis and treatment*. Springfield, IL: Charles C. Thomas Publisher; 1972.
- [17] Gaymer R. New method of locomotion in limbless terrestrial vertebrates. *Nature* 1971;234:150.
- [18] Graybiel AM. Habits, rituals, and the evaluative brain. *Annu Rev Neurosci* 2008;31:359–87.
- [19] Grillner S. Biological pattern generation: the cellular and computational logic of networks in motion. *Neuron* 2006;52:751–66.
- [20] Großekathöfer U, Manyakov NV, Mihajlović V, Pandina G, Skalkin A, Ness S, et al. Automated detection of stereotypical motor movements in autism spectrum disorder using recurrence quantification analysis. *Front Neuroinform* 2017;11:9.
- [21] Hatsopoulos NG. Coupling the neural and physical dynamics in rhythmic movements. *Neural Comput* 1996;8:567–81.
- [22] Hollman JH, Kovash FM, Kubik JJ, Linbo RA. Age-related differences in spatiotemporal markers of gait stability during dual task walking. *Gait Posture* 2007;26:113–9.
- [23] Lewis MH, Baumeister AA, Mailman RB. A neurobiological alternative to the perceptual reinforcement hypothesis of stereotyped behavior: a commentary on "Self-stimulatory behavior and perceptual reinforcement". *J Appl Behav Anal* 1987;20:253–8.
- [24] Liu W, Anguelov D, Erhan D, Szegedy C, Reed S, Fu C-Y, et al. SSD: single shot multibox detector. In: Leibe B, Matas J, Sebe N, Welling M, editors. *Computer Vision – Proceedings of the European conference on computer vision. ECCV 2016. Lecture Notes in Computer Science*, volume 9905. Cham: Springer; 2016. p. 21–37.
- [25] Lovaas I, Newsom C, Hickman C. Self-stimulatory behavior and perceptual reinforcement. *J Appl Behav Anal* 1987;20:45–68.
- [26] Manni R, Terzaghi M. Rhythmic movements during sleep: a physiological and pathological profile. *Neurol Sci* 2005;26:s181–5.
- [27] Marchi A, Giusiano B, King M, Lagarde S, Trébuchon-Dafonseca A, Bernard C, et al. Postictal electroencephalographic (EEG) suppression: a stereo-EEG study of 100 focal to bilateral tonic-clonic seizures. *Epilepsia* 2019;60:63–73.
- [28] Marder E, Bucher D. Central pattern generators and the control of rhythmic movements. *Curr Biol* 2001;11:R986–96.
- [29] Mayer G, Wilde-Frenz J, Kurella B. Sleep related rhythmic movement disorder revisited. *J Sleep Res* 2007;16:110–6.
- [30] McGonigal A, Chauvel P. Prefrontal seizures manifesting as motor stereotypies. *Mov Disord* 2014;29:1181–5.
- [31] Meletti S, Cantalupo G, Volpi L, Rubboli G, Magaouda A, Tassinari C. Rhythmic teeth grinding induced by temporal lobe seizures. *Neurology* 2004;62:2306–9.
- [32] Morillon B, Arnal LH, Schroeder CE, Keitel A. Prominence of delta oscillatory rhythms in the motor cortex and their rele-

- vance for auditory and speech perception. *Neurosci Biobehav Rev* 2019;107:136–42.
- [33] Rémi J, Cunha JPS, Vollmar C, Topçuoğlu ÖB, Meier A, Ulowetz S, et al. Quantitative movement analysis differentiates focal seizures characterized by automatisms. *Epilepsy Behav* 2011;20:642–7.
- [34] Rheims S, Ryvlin P, Scherer C, Minotti L, Hoffmann D, Guenot M, et al. Analysis of clinical patterns and underlying epileptogenic zones of hypermotor seizures. *Epilepsia* 2008;49:2030–40.
- [35] Richardson MJ, Marsh KL, Isenhowe RW, Goodman JR, Schmidt RC. Rocking together: dynamics of intentional and unintentional interpersonal coordination. *Hum Mov Sci* 2007;26:867–91.
- [36] Schmahmann JD, Pandya DN. Disconnection syndromes of basal ganglia, thalamus, and cerebocerebellar systems. *Cortex* 2008;44:1037–66.
- [37] Singer HS. Motor control, habits, complex motor stereotypies, and Tourette syndrome. *Ann N Y Acad Sci* 2013;1304:22–31.
- [38] Tassinari CA, Cantalupo G, Högl B, Cortelli P, Tassi L, Francione S, et al. Neuroethological approach to frontolimbic epileptic seizures and parasomnias: the same central pattern generators for the same behaviours. *Rev Neurol* 2009;165:762–8.
- [39] Thelen E. Kicking, rocking, and waving: contextual analysis of rhythmical stereotypies in normal human infants. *Anim Behav* 1981;29:3–11.
- [40] Vaugier L, McGonigal A, Lagarde S, Trébuchon A, Szurhaj W, Derambure P, et al. Hyperkinetic motor seizures: a common semiology generated by two different cortical seizure origins. *Epileptic Disord* 2017;19:362–6.
- [41] Yamada N. Nature of variability in rhythmical movement. *Hum Mov Sci* 1995;14:371–84.
- [42] Zeiler A, Faltermeier R, Keck IR, Tomé AM, Puntinet CG, Lang EW. Empirical mode decomposition-an introduction. *Proceedings of the International Joint Conference on Neural Networks, IJCNN*; 2010. p. 1–8, <http://dx.doi.org/10.1109/IJCNN.2010.5596829>.