



HAL
open science

Novel CAPN3 variant associated with an autosomal dominant calpainopathy

Mathieu Cerino, Emmanuelle Salort-Campana, Alexandra Salvi, P Cintas, D. Renard, R Juntas Morales, C Tard, F. Leturcq, T Stojkovic, Nathalie Bonello-Palot, et al.

► To cite this version:

Mathieu Cerino, Emmanuelle Salort-Campana, Alexandra Salvi, P Cintas, D. Renard, et al.. Novel CAPN3 variant associated with an autosomal dominant calpainopathy. *Neuropathology and Applied Neurobiology*, 2020, 10.1111/nan.12624 . hal-02901906

HAL Id: hal-02901906

<https://amu.hal.science/hal-02901906v1>

Submitted on 31 Aug 2020

HAL is a multi-disciplinary open access archive for the deposit and dissemination of scientific research documents, whether they are published or not. The documents may come from teaching and research institutions in France or abroad, or from public or private research centers.

L'archive ouverte pluridisciplinaire **HAL**, est destinée au dépôt et à la diffusion de documents scientifiques de niveau recherche, publiés ou non, émanant des établissements d'enseignement et de recherche français ou étrangers, des laboratoires publics ou privés.

Novel *CAPN3* variant associated with an autosomal dominant calpainopathy

M. Cerino*†‡, E. Campana-Salort*§, A. Salvi*, P. Cintas¶¹, D. Renard**¹,
R. Juntas Morales††‡‡, C. Tard§§¶¶, F. Leturcq***, T. Stojkovic†††, N. Bonello-Palot*†, S. Gorokhova*†, J. Mortreux*†, A. Maues De Paula*†††, N. Lévy*†, J. Pouget§, M. Cossée††§§§, M. Bartoli*, M. Krahn*†¹ and S. Attarian*§¹

*Aix Marseille Univ, Inserm, U1251-MMG, Marseille Medical Genetics, Marseille, †APHM, Hôpital Timone Enfants, Département de Génétique Médicale, ‡APHM, Laboratoire de Biochimie, Hôpital de la Conception, Marseille, §APHM, centre de référence des maladies neuromusculaires et de la SLA, CHU La Timone, Marseille, ¶Centre de référence de pathologie neuromusculaires, Hôpital Purpan, CHU de Toulouse, Toulouse, **Service de Neurologie, CHU de Nîmes, Univ. Montpellier, Nîmes, ††Laboratoire de Génétique de Maladies Rares, Université de Montpellier, ‡‡Service de Neurologie, CHU de Montpellier, Montpellier, §§U1172, Service de Neurologie, CHU de Lille, Lille, ¶¶Centre de référence des maladies neuromusculaires Nord/Est/Ile de France, ***APHP, Laboratoire de génétique et biologie moléculaires, HUPC Cochin, †††APHP, Centre de référence des maladies neuromusculaires Nord/Est/Ile de France, Hôpital Pitié-Salpêtrière, Paris, ‡‡‡APHM, Service d'anatomie pathologique et de neuropathologie, CHU La Timone, Marseille and §§§Laboratoire de Génétique moléculaire, CHRU Montpellier, Montpellier, France

M. Cerino, E. Campana-Salort, A. Salvi, P. Cintas, D. Renard, R. Juntas Morales, C. Tard, F. Leturcq, T. Stojkovic, N. Bonello-Palot, S. Gorokhova, J. Mortreux, A. Maues De Paula, N. Lévy, J. Pouget, M. Cossée, M. Bartoli, M. Krahn and S. Attarian (2020) *Neuropathology and Applied Neurobiology*

Novel *CAPN3* variant associated with an autosomal dominant calpainopathy

Aims: The most common autosomal recessive limb girdle muscular dystrophy is associated with the *CAPN3* gene. The exclusively recessive inheritance of this disorder has been recently challenged by the description of the recurrent variants, c.643_663del21 [p.(Ser215_Gly221del)] and c.598_612del15 [p.(Phe200_Leu204-del)], associated with autosomal dominant inheritance. Our objective was to confirm the existence of autosomal dominant calpainopathies. **Methods:** Through our activity as one of the reference centres for genetic diagnosis of calpainopathies in France and the resulting collaborations through the French National Network for Rare Neuromuscular Diseases (FILNEMUS), we identified four families harbouring the same *CAPN3* heterozygous variant with supposedly autosomal dominant inheritance. **Results:** We identified a novel dominantly inherited *CAPN3* variant, c.1333G>A [p.(Gly445Arg)] in 14

affected patients from four unrelated families. The complementary phenotypic, functional and genetic findings correlate with an autosomal dominant inheritance in these families, emphasizing the existence of this novel transmission mode for calpainopathies. The mild phenotype associated with these autosomal dominant cases widens the phenotypic spectrum of calpainopathies and should therefore be considered in clinical practice. **Conclusions:** We confirm the existence of autosomal dominant calpainopathies as an entity beyond the cases related to the in-frame deletions c.643_663del21 and c.598_612del15, with the identification of a novel dominantly inherited and well-documented *CAPN3* missense variant, c.1333G>A [p.(Gly445Arg)]. In addition to the consequences for genetic counselling, the confirmation of an autosomal dominant transmission mode for calpainopathies underlines the importance of re-assessing

other myopathies for which the inheritance is considered as strictly autosomal recessive.

Keywords: dominant, calpainopathy, NGS, myopathy, *CAPN3*

Introduction

Calpainopathies, also known as Limb-Girdle Muscular Dystrophy Recessive type 1 (LGMDR1, formerly LGMD2A), are considered the most frequent recessive LGMD [1,2] and are typically associated with symmetric and progressive weakness of proximal limb-girdle muscles, but with significant clinical heterogeneity [3,4]. *CAPN3* variants were initially linked to LGMDR1 in 1995 [5]. The *CAPN3* gene encodes a calcium-dependent cysteine protease, calpain-3, that is expressed predominantly in skeletal muscle and could play an important role in processing various proteins involved in sarcomere maintenance [6-8].

The majority of known *CAPN3* pathogenic variants are loss-of-function resulting in a recessive disease. Recently, this exclusive autosomal recessive transmission mode has been reconsidered with the description of the recurrent variant, c.643_663del21, associated with an autosomal dominant inheritance in 10 families [9]. Shortly after, three additional families harbouring the same variant in an autosomal dominant transmission mode were described [10], followed by the reporting of 17 additional index cases carrying the c.643_663del21 variant [11]. Based on these observations, the LGMD classification was revised [12], introducing the *CAPN3* associated Limb-Girdle Muscular Dystrophy Dominant type 4 (LGMD4). Another *CAPN3* variant with supposedly autosomal dominant inheritance, c.598_612del15, has since been reported in 15 index cases in a very large cohort of 4656 LGMD patients [11].

However, no documented phenotype nor familial segregation analysis was available for these cases in order to confirm that the c.598_612del15 variant caused the dominant form of the disease.

Our activity as one of the reference centres for the genetic diagnosis of calpainopathies in France and the resulting national collaborations through the French National Network for Rare Neuromuscular Diseases FILNEMUS (www.filnemus.fr) enabled us to identify four independent families harbouring the same,

c.1333G>A [p.(Gly445Arg)], *CAPN3* heterozygous variant associated with autosomal dominant inheritance as confirmed by the familial segregation analysis. Therefore, we describe here the first missense variant and the third well-documented *CAPN3* variant associated with LGMD4, underlining the importance of this clinical and genetic entity to be considered in future diagnostic strategies for myopathies.

Materials and methods

Patients

Among our cohorts of patients investigated for a diagnostic suspicion of calpainopathy, we identified four families harbouring the same *CAPN3* heterozygous variant with supposedly autosomal dominant inheritance. All families originated from France. Informed consent was obtained according to the Declaration of Helsinki. Phenotype and familial clinical history were systematically reviewed for each proband. When possible, clinical examination was extended to family members. Otherwise, the review of the family medical records was undertaken. Serum creatine kinase (CK) levels were tested in probands and in available family members. Muscle MRI and/or CT-scan was also performed for the four index cases and four additional family members (Table 1 and Figure 2). Muscle biopsies were obtained for the four probands and two family members for histological analyses and western blotting.

Molecular analyses

During the past decade, our molecular diagnosis strategy has been altered to include next-generation sequencing (NGS) technologies and follow the associated recommendations [13]. The timeline of our study overlaps those changes in sequencing strategy. Therefore, mutational analysis was performed via different technologies ranging from Sanger sequencing [14] to whole-exome sequencing (WES).

+NGS (panel of 138 genes associated with neuromuscular disorders); +negative CAPN3 MLPA sequencing; Sanger targeted CAPN3 gene	type II fibres Aspecific atrophy	300–900	semimembranosus, biceps femoris and tibialis anterior muscles Semitendinosus,	and abductor muscles in thighs; right scapula alata Gluteal, hamstring	lower limbs weakness of Proximal muscle	F	84	60	2/III.1
c.1333G>A CAPN3 variant, by targeted Sanger sequencing analysis of the Segregation	Not performed regeneration fibres; endomyisial inflammatory infiltrates; uniform overexpression of MHC-I; normal membrane protein (immunohistochemistry); caffeine/halothane in-vitro contracture test positive	5000	Hamstring muscles	No	hyperCKaemia Myalgia,	F	18	Adolescence	1/IV.2
+CAPN3 gene targeted Sanger sequencing whole exome); exome and NGS (clinical targeted Sanger sequencing whole exome); exome and NGS) (clinical sequencing Next-generation	Few necrosis/ atrophy II fibres Aspecific type	1600–6000	paraspinal muscles and hamstring (adductors and semimembranosus muscles+++) Lombosacral	(later) Fatigability	hyperCKaemia Myalgia,	M	42	Adolescence	1/III.5
Genetic analysis	Creatine kinase	Muscle biopsy	Abnormalities on muscle imaging (MRI and/or CT scan)	Other symptoms	Age (years)	Sex	Initial symptoms	Onset (years)	patient Family/
		400–1800	Not performed	No	hyperCKaemia Myalgia,	F	59	35	1/II.3

Table 1. Clinical and biological observations for the patients of the four families harbouring the c.1333G>A CAPN3 variant

Table 1. (Continued)

<i>Family/ patient</i>	<i>Onset (years)</i>	<i>Age (years)</i>	<i>Sex</i>	<i>Initial symptoms</i>	<i>Muscle weakness</i>	<i>Other symptoms</i>	<i>Abnormalities on muscle imaging (MRI and/or CT scan)</i>	<i>Creatine kinase</i>	<i>Muscle biopsy</i>	<i>Genetic analysis</i>
2/III.2	Not documented	83	M	Isolated hyperCKaemia	No	No	Not performed	490	Not performed	Segregation analysis of the c.1333G>A CAPN3 variant, by targeted Sanger sequencing
2/III.3	60	81	M	Proximal muscle weakness of lower limbs	Lower limbs proximal muscles	No	Bilateral hamstrings, right medial gastrocnemius muscle, and left medial and lateral gastrocnemius and sural muscles	257	Not performed	Segregation analysis of the c.1333G>A CAPN3 variant, by targeted Sanger sequencing
2/IV.6	/	53	F	Asymptomatic	No	No	Bilateral (predominant on the right side) hamstrings, and bilateral medial gastrocnemius muscles	82	Not performed	Segregation analysis of the c.1333G>A CAPN3 variant, by targeted Sanger sequencing
3/III.6	50	77	F	Myalgia	Axial weakness; paraspinal muscles and scapula fixators muscles	Myalgia; camptocormia; scapula alata	Hamstring and the serratus anterior muscles	400–1500	Fibres size irregularity; endomyxial fibrosis	CAPN3 gene targeted Sanger sequencing; +NGS (panel of 306 genes associated with neuromuscular disorders) + negative CAPN3 MLPA
3/III.1	55	55	M	Isolated hyperCKaemia and exertional rhabdomyolysis	No	No	Not performed	285 (+8 to 10 fold increase after effort)	Not performed	Segregation analysis of the c.1333G>A CAPN3 variant, by targeted Sanger sequencing
3/III.2	50	50	F	Isolated hyperCKaemia and exertional rhabdomyolysis	No	No	Not performed	575 (+8 to 10 fold increase after effort)	Not performed	Segregation analysis of the c.1333G>A CAPN3 variant, by targeted Sanger sequencing

Table 1. (Continued)

Family/ patient	Onset (years)	Age (years)	Sex	Initial symptoms	Muscle weakness	Other symptoms	Abnormalities on muscle imaging (MRI and/or CT scan)	Creatine kinase	Muscle biopsy	Genetic analysis
4/II.1	40	78	F	Hyperlordosis	Axial weakness (abdominal and paravertebral muscles); scapula fixators muscles; deltoid, triceps and pelvic muscles	Campyocormia (severe); orthopnea (cardiac)	Not performed	260	Not performed	Segregation analysis of the c.1333G>A CAPN3 variant, by targeted Sanger sequencing
4/II.1	45	58	F	Muscle weakness and hyperCKaemia	Axial weakness (abdominal and paravertebral muscles); scapula fixators muscles; deltoid and pelvic muscles	Myalgia – low back pain; scapula alata	Bilateral minimal gluteus, hamstrings, soleus, gastrocnemius medialis muscles	1000	Fibres size irregularity, increased numbers of internal nuclei; normal membrane protein (immunohistochemistry); normal expression of MHC-I	Molecular diagnosis of FSHD1; no contraction of D4Z4 array; gene panel sequencing (38 LGMD associated genes); +CAPN3 gene targetedSanger sequencing
4/II.2	25	56	M	Muscle weakness and hyperCKaemia	Axial and pelvic weakness	Hyperlordosis	Bilateral minimal gluteus and gluteus medialis, semitendinosus, semimembranosus	1200–2600	Wide variation in fibre size; presence of few angular fibres; normal membrane protein (immunohistochemistry)	Molecular diagnosis of FSHD1; no contraction of D4Z4 array; ANO5 gene targeted Sanger sequencing; no pathogenic variant; +CAPN3 gene targeted Sanger sequencing
4/III.4	25	29	M	Isolated hyperCKaemia	No	No	Not performed	344	Not performed	Segregation analysis of the c.1333G>A CAPN3 variant, by targeted Sanger sequencing

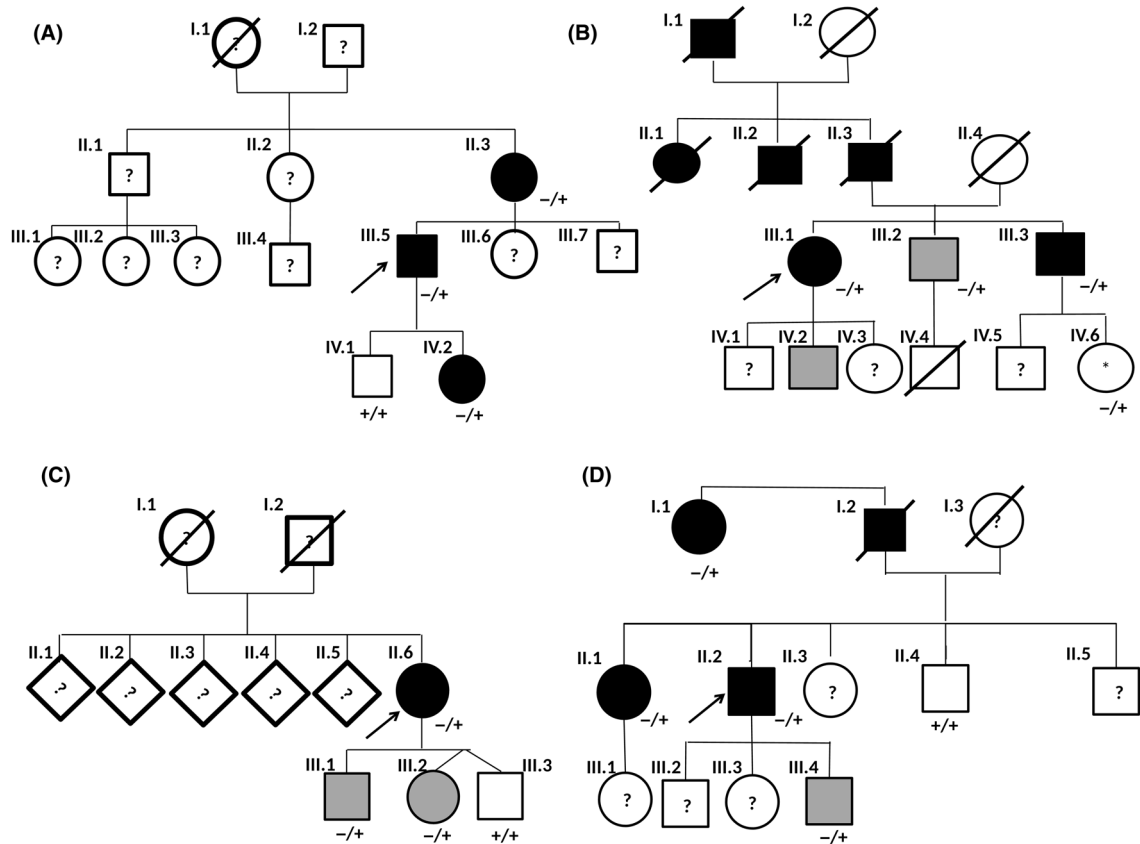


Figure 1. Pedigrees and segregation analysis of the c.1333G>A *CAPN3* variant for family 1 (A), family 2 (B), family 3 (C) and family 4 (D). (+) A nonmutated allele for the c.1333G>A *CAPN3* variant; (-) a mutated allele for the c.1333G>A *CAPN3* variant; (?) individuals with unknown clinical status and/or ongoing clinical exploration; (*) clinically asymptomatic subject associated with muscular impairment on MRI analysis; black colour indicates clinically symptomatic patients; grey colour indicates subjects with isolated hyperCKaemia.

CAPN3 gene targeted Sanger sequencing was performed on a 3500XL Genetic Analyzer[®] (Thermo Fisher Scientific, Waltham, MA, USA) for 17 patients (Figure 1).

Targeted NGS analysis used different genes panels, depending on the genetic laboratory, but covered at least the initial 'Limb Girdle Muscular Dystrophies' clinical entry-diagnosis group defined by the FILNEMUS network guidelines, with the exception of a few newly involved genes added very recently to the corresponding genes list [13]. Therefore, targeted NGS sequencing was performed for 306 genes [15], 135 genes [16] or 38 genes associated to neuromuscular disorder [17], depending on the genetic laboratory, respectively for index cases from family 2 (2/III.1) and family 3 (3/II.6) as well as for a symptomatic patient from family 4 (4/II.1). See Supporting Information for detailed genes panels and genes lists (Appendix S1). Targeted NGS of 2742 genes known to cause inherited

disorders (=clinical exome) was performed for the index case from family 1 (1/III.5). WES was performed for two patients of family 1 (1/III.5 and 1/II.3).

The NGS approach used HaloPlex (Agilent, Santa Clara, CA, USA), Nimblegen (Roche, Basel, Switzerland) or ClearSeq Inherited Disease Panel (Agilent) target enrichment systems, whereas WES was performed with the SureSelect Human All Exon Kit version 5 (Agilent). Sequencing was then done either with the MiSeq, the Next Seq550 (Illumina, San Diego, CA, USA), the HiSeq 2000 (Illumina) sequencers or on an Ion Proton platform (Thermo Fisher Scientific).

Finally, complementary *CAPN3* Multiplex Ligation-dependent Probe Amplification (MLPA; MRC-Holland, Amsterdam, the Netherlands) analysis was also done for two patients (2/III.1 and 3/II.6).

All these results are detailed in Table 1.

Confirmation of variants identified by NGS as well as variant familial segregation analyses was undertaken by targeted Sanger sequencing.

Sequence variants were described using the Human Genome Variation Society recommendations [18] for the *CAPN3* transcript reference NM_000070.2.

***In vitro* functional assay**

Intramolecular and intermolecular autolytic activities of different calpain-3 forms were assessed by western blotting after transfection of different mutated calpain-3, including the c.1333G>A [p.(Gly445Arg)] *CAPN3* variant, in human immortalized calpain-3 deficient myoblasts. These *in vitro* functional assays have been performed according to the experiments described by Milic *et al.* [19].

DNA constructs

The human calpain-3 (ENST00000397163.8) sequence was subcloned in pEGFPN1 (addgene #6085-1) to produce recombinant protein fused with green fluorescent protein (GFP). Site directed mutagenesis was performed using Quick Change II site-directed mutagenesis kit (Agilent).

Cell culture and transfection

Immortalized human skeletal muscle cells derived from a LGMDR1 patient harbouring a homozygous variant of exon 13, c.1699G>T [p.(Gly767Trp)], in the *CAPN3* gene were generated in the Institute of Myology human cell immortalization platform, as previously described [20].

Cells were cultured in medium 199 and Dubelcco's modified Eagle medium (Thermo Fisher Scientific) in a 1/4 ratio, supplemented with 20% (v/v) fetal bovine serum (Thermo Fisher Scientific), 25 µg/ml fetuin (Thermo Fisher Scientific), 5 ng/µl hEGF (Thermo Fisher Scientific), 0.5 ng/µl bFGF (Thermo Fisher Scientific), 5 µG/ml insu-lin (Sigma-Aldrich, Saint-Louis, MO, USA) and 0.2 µg/ml dexamethasone (Sigma-Aldrich). Two micrograms of each plasmids was transfected in cells with 6 µl Lipofectamine 2000 (Thermo Fisher Scientific). An equimolar concentration was used for co-transfection.

Western blot

Western blot analysis was performed on protein extracts from transfected cells with anti-GFP antibody

1/5000 (ab5449, lot number GR178625-1; Abcam, Cambridge, UK) and anti-V5tag antibody 1/1000 (ab27671, lot number GR322548-6; Abcam).

Results

Diagnostic course and molecular testing

We undertook genetic analysis on DNA from the pro-band of family 1 (patient 1/III.5 in Table 1 and **Figure 1A**). This patient had complained of diffuse myalgia since adolescence with high CK levels ranging from 1600 to 6000 IU/l. Clinical examination was normal. The family history suggested autosomal dominant inheritance as the proband's mother presented with a similar phenotype with an onset at 35 years of age. The proband's daughter also had myalgia and hyperCKaemia.

For the proband, the clinical exome NGS analysis filtered initially on 44 genes (see Supporting Information, Appendix S1) associated with neuromuscular disorders [17] revealed only a heterozygous, c.1333G>A [p.(Gly445Arg)], *CAPN3* variant. This variant was also identified in the affected mother and daughter of the pro-band, but not in the nonaffected son of the proband (**Figure 1A**). The c.1333G>A *CAPN3* variant was not initially considered as disease-causing due to the absence of a second *CAPN3* variant. Complementary WES was thus performed for this index case and his mother (patient 1/II.3 in **Figure 1A** and Table 1) revealing no other alternative molecular diagnosis. Therefore, the possibility of a *CAPN3* autosomal dominant inheritance was considered, especially after the first description of a *CAPN3* variant with that novel transmission mode [9] and strengthened by the consistent familial segregation analysis of the c.1333G>A variant (family 1 in **Figure 1A**).

Since the segregation data for this family was highly suggestive of an autosomal dominant role for the c.1333G>A variant, we retrospectively reanalysed our suspected calpainopathy patient database and found two additional index cases harbouring this *CAPN3* variant. Interestingly, these patients' mutational status was also heterozygous for this variant, whereas familial clinical and molecular explorations for these two additional families were consistent with autosomal dominant inheritance (**Figure 1B,C** and Table 1). A fourth family (**Figure 1D**) was subsequently identified through the FILNEMUS network, resulting in a

total of 14 affected patients in four different families harbouring this c.1333G>A *CAPN3* variant (Table 1). Moreover, for the index cases from these three additional families (Figure 1B–D), complementary analyses were performed by targeted *CAPN3* MLPA and/or NGS explorations revealing no alternative molecular diagnosis (Table 1). The fact that no convincing alternative molecular diagnosis was identified despite extensive genetic exploration strongly suggests that the c.1333G>A *CAPN3* variant is the underlying cause of the phenotype observed in the 14 affected patients.

This class 5 (pathogenic) c.1333G>A *CAPN3* variant [21] has been previously reported 18 times in the LOVD database [22] (<http://www.lovd.nl>, 16 July 2019) and twice in the ClinVar database [23] (<https://www.ncbi.nlm.nih.gov/clinvar>, 16 July 2019) as well as in the literature [2,24–29], but only for supposedly autosomal recessive calpainopathies. Thus, out of 20 reported individuals harbouring the c.1333G>A *CAPN3* variant (in LOVD database and literature referenced above), 16 patients (80%) were single heterozygous for this variant (see Table 2 for the summary of all previously identified cases). If patients described here are included, in 30 out of 34 reported cases (88%) the c.1333G>A *CAPN3* variant is heterozygous without any second pathogenic *CAPN3* variant identified *in trans* to date. Interestingly, there is approximately the same percentage (90%) of patients reported in the LOVD database with the initial autosomal dominant *CAPN3* variant, c.643_663del21, without a second mutation found in this gene, contrasting significantly with other known pathogenic *CAPN3* variants in exon 10 such as c.1343G>A and c.1322delG variants for which no second mutation was identified in respectively only 30% (3/10) and 12.5% (1/8) reported cases in LOVD database. In addition, this c.1333G>A *CAPN3* variant was described in a heterozygous state for supposedly mild and/or late onset phenotypes in the literature [2,24,26], without available familial segregation data, but potentially compatible with the phenotype associated with autosomal dominant inherited calpainopathies.

Furthermore, the c.1333G>A *CAPN3* variant is present in only 3 out of 107778 alleles in the European non-Finish population (allele frequency of 0.00002783) and is absent from other populations (132490 alleles) (GnomAD, <http://gnomad.broadinstitute.org/>, 16 July 2019). This extremely low frequency in the general population is compatible with an

autosomal dominant inheritance of a relatively mild adult-onset disease.

Taken together, our findings strongly suggest that the c.1333G>A *CAPN3* variant can be responsible for an autosomal dominant form of calpainopathy, confirming the initial findings of Vissing *et al.* [9]. Thus, the previously identified cases of milder and late onset myopathy cases associated with this variant could have been misinterpreted as partial diagnoses due to putative absence of the second *CAPN3* variant.

Clinical phenotype

The 14 patients harbouring the c.1333G>A *CAPN3* variant revealed significant variability of severity ranging from isolated hyperCKaemia to late onset clinical presentations, predominated by mild proximal muscular impairment, more prominent in the lower limbs (Table 1). Mean age at onset was 39.3 years (range 12–60). Six subjects presented with isolated hyperCKaemia, without any weakness. Among them, two siblings had exertional rhabdomyolysis. Myalgia was a common feature, observed in five out of 14 patients. The muscle weakness affected preferentially the proximal lower limbs, notably the hamstring muscles, and dorsal as well as spinal column muscles. Prominent axial involvement was noticed in five out of 14 patients. Among them, three presented with camptocormia. Muscle atrophy was rare, present in only two patients (Table 1). All patients but one (patient 2/IV.6) had high CK levels (Table 1).

These observations are consistent with the first autosomal dominant calpainopathy description associated with the c.643_663del21 *CAPN3* variant in 13 different families [9,10], which showed a milder and late-onset muscular phenotype for this novel transmission mode for calpainopathies.

Complementary analyses

Muscle imaging In eight patients, muscle imaging (CT scan or MRI) was performed (Figure 2). Fatty degenerative changes at the thigh level were present in all, but one patient (1/IV.2). Their distribution was variable and sometimes asymmetrical, but a common feature was the prominent involvement of the hamstring muscles. Semitendinosus and semimembranosus muscles were also frequently affected. At the lower leg

Table 2. Summary of all previously identified cases associated with the c.1333G>A CAPN3 variant

CAPN3 (NM_000070.2): c.1333G>A [p.(Gly445Arg)]

Source	Classification†	Second CAPN3 pathogenic variant	Phenotype‡
ClinVar database [23]	ClinVar SCV000791979.1 Likely pathogenic	Not provided	LGMD2A
LOVD database [22]	ClinVar SCV000337170.4 Pathogenic	Not provided	Not provided
	LOVD #0000264269 (no individual ID) Pathogenic	No second pathogenic variant reported	Not provided
	LOVD #0000324031 (no individual ID) Pathogenic	No second pathogenic variant reported	Not provided
	LOVD #0000447298 (individual ID: #00213752) Pathogenic	c.1333G>A [p.(Gly445Arg)]	LGMD2A
	LOVD #0000447299 (individual ID: #00213752)* Pathogenic	c.1333G>A [p.(Gly445Arg)]	LGMD2A
	LOVD #0000447622 (individual ID: #00213950) Pathogenic	c.1746-20C>G‡	LGMD2A (moderate)
	LOVD #0000447624 (individual ID: #00213951) Pathogenic	No second pathogenic variant reported	LGMD2A
	LOVD #0000447625 (individual ID: #00213952) Pathogenic	No second pathogenic variant reported	LGMD2A
	LOVD #0000447834 (individual ID: #00214106) Pathogenic	c.1505T>C [p.(Ile502Thr)]	LGMD2A
	LOVD #0000448278 (individual ID: #00214328) Pathogenic	No second pathogenic variant reported	LGMD2A
	LOVD #0000448615 (individual ID: #00214538) Pathogenic	No second pathogenic variant reported	LGMD2A (moderate)
	LOVD #0000448631 (individual ID: #00214546) Pathogenic	c.662G>T [p.(Gly221Val)]	LGMD2A
	LOVD #0000448651 (individual ID: #00214559) Pathogenic	No second pathogenic variant reported	LGMD2A
	LOVD #0000460647 (individual ID: #00220099) Pathogenic	No second pathogenic variant reported	LGMD
	LOVD #0000460712 (individual ID: #00220437) Pathogenic	No second pathogenic variant reported	LGMD
	LOVD #0000460931 (individual ID: #00221637) VUS	No second pathogenic variant reported	LGMD
	LOVD #0000460973 (individual ID: #00221919) Pathogenic	No second pathogenic variant reported	LGMD
	LOVD #0000460990 (individual ID: #00221975) Pathogenic	No second pathogenic variant reported	LGMD
	LOVD #0000461066 (individual ID: #00222408) Pathogenic	No second pathogenic variant reported	LGMD
Literature	Richard <i>et al.</i> , 1999 [24] + Guglieri <i>et al.</i> , 2008 [2] + Magri <i>et al.</i> , 2015 [29] Pathogenic	No second pathogenic variant reported	LGMD2A
	Richard <i>et al.</i> , 1999 [24] + Guglieri <i>et al.</i> , 2008 [2] Pathogenic	No second pathogenic variant reported	Late-onset LGMD2A
	Richard <i>et al.</i> , 1999 [24] + Guglieri <i>et al.</i> , 2008 [2] (=Individual LOVD ID: #00214546)* Pathogenic	c.662G>T [p.(Gly221Val)]	LGMD2A
	Fanin <i>et al.</i> , 2004 [25] + Nascimbeni <i>et al.</i> , 2010 [27] (=Individual LOVD ID: #00213950)* Pathogenic	c.1746-20C>G‡	LGMD2A
	Saenz <i>et al.</i> , 2005 [26] (=individual LOVD ID: #00214328)* Pathogenic	No second pathogenic variant reported	Late-onset LGMD2A
	Schröder <i>et al.</i> , 2013 [28] Pathogenic	No second pathogenic variant reported	LGMD2A
Nallamilli <i>et al.</i> , 2018 [11] (=individual LOVD ID: #00221637)* VUS	No second pathogenic variant reported	LGMD2A	

LGMD2A, Limb-Girdle Muscular Dystrophy type 2A; VUS, variant of uncertain significance.

*Second description of a same individual in LOVD and/or literature.

†Classification and phenotype suggested by source.

‡Deleterious splicing effect later confirmed by Nascimbeni *et al.* [27].

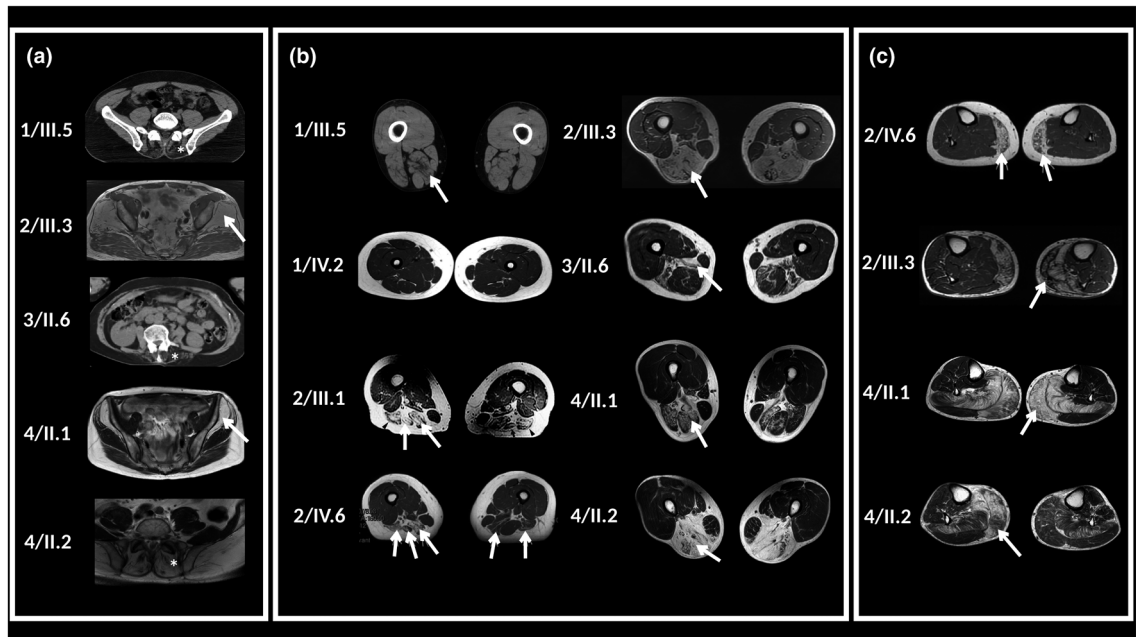


Figure 2. Muscle imaging findings in eight patients harbouring the c.1333G>A *CAPN3* variant. CT muscle imaging was performed in patients 1/III.5 and 3/II.6 and muscle MRI was performed in patients 1/IV.2, 2/III.1, 2/III.3, 2/IV.6, 4/II.1, 4/II.2. Patients numbers are indicated in this figure and correspond to those indicated in the family trees in Figure 1. (A) CT and MRI imaging of lumbar and pelvic muscles of five patients. Patients 1/III.5, 3/II.6 and 4/II.2 have severe fatty replacement of lumbar paraspinal muscles (asterisk). Patients 2/III.3 and 4/II.1 have heavy fibro-fatty bilateral changes in glutei minimi and medii muscles (arrows) with respect of gluteus maximus. (B) CT and MRI imaging of thighs of eight patients. CT muscle scan of patient 1/III.5 shows selective hypodensities in semitendinosus and semimembranosus more pronounced on the right side (arrow). Axial imaging (T1 sequences) of patient 1/IV.2 at 8 years, shows no involvement of thighs muscles. MRI imaging (T1 sequences) of patient 2/III.1, 2/III.3 and 4/II.2 shows severe fatty degenerative changes in hamstrings on both sides with preservation of sartorius and gracilis muscles. Patient 2/IV.6 fatty degenerative changes are present in the hamstrings predominantly on the right side, bilaterally in semimembranosus and long head of biceps femoris and in semitendinosus also on the right side. In T1 axial slice of patient 3/II.6, selective hypodensities are present in hamstring muscles, mainly on the left side. Biceps femoris and adductor magnus are the most seriously affected by fatty infiltration. (C) CT and MRI imaging of legs of four patients. On T1 axial slices of both lower legs of patients 2/III.3, 2/IV.6, 4/II.1, 4/II.2, fatty degenerative changes were present at the posterior compartment of legs, mainly in gastrocnemius medialis (arrows). On muscle imaging of the other four patients, legs muscles were unaffected (data not shown). In patient 2/III.3, there was a significant muscle atrophy of the posterior compartment on the left side. In patients 4/II.1 and 4/II.2, fatty degeneration on gastrocnemius medialis and soleus muscles is pronounced, whereas gastrocnemius lateralis is relatively spared.

level, the medial gastrocnemius muscle was the most frequently affected (Table 1 and Figure 2).

The nonspecific, mild and even subclinical presentation of autosomal dominant calpainopathies contrasts with the consistent muscular damage found by muscle imaging, especially MRI. Indeed, this approach enabled us to confirm the muscle involvement in patient 2/IV.6 (Figure 2) harbouring the c.1333G>A *CAPN3* variant, even though she was asymptomatic with normal CK levels (Table 1 and Figure 1). MRI revealed a similar muscle involvement as her symptomatic father (patient 2/III.3 in Figure 2), that is predominant in the hamstring and medial gastrocnemius muscles, but obviously to a lesser extent. Interestingly, a very similar case was

described by Vissing *et al.*, but no muscle imaging was performed, which could well have revealed presymptomatic muscular involvement in their patient [9].

Muscle tissue histology and protein analysis In the available samples, muscle histology showed nonspecific myopathic changes, with mild to moderate variation in fibre size, nonspecific atrophy of type II fibres and few necrotic/regenerating fibres (Table 1). In patient 1/III.5, mild endomysial infiltrates and uniform overexpression of MHC-I were observed. Caffeine/halothane *in vitro* contracture tests were performed in this patient and were positive, classifying the patient as having malignant hyperthermia susceptibility (Table 1).

The calpain-3 western blot analysis of muscle biop-sies from the four index cases, performed in different laboratories more than 10 years ago, revealed contra-dictory information. Only patient 3/II.6 had total cal-pain-3 loss. Another patient (4/II.2) presented with a partial calpain-3 defect, whereas the other two index cases had seemingly normal expression of calpain-3. However, it is known that it is difficult to obtain reliable calpain-3 western blot analysis. Moreover, inter-laboratory as well as intralaboratory variability is not rare for this type of analysis.

Modified catalytic activity of the calpain-3 p.(Gly445Arg) mutant In order to investigate the effect of c.1333G>A CAPN3 variant on calpain-3 protein function, we transfected mutated CAPN3 constructs into human immortalized myoblasts lacking endogenous calpain-3, alone or in combination with other constructs. Inactive calpain-3 p.(Cys129Ser) was used as a specific substrate to evaluate the catalytic activity of transfected mutants (Figure 3). As expected, the inactive calpain-3 p.(Cys129Ser) was not degraded when transfected alone, as only one specific band is visible corresponding to the full-length calpain-3 p.(Cys129Ser) fused with GFP at 121 kDa (Figure 3A) or fused with V5tag at 92 kDa (Figure 3B). The calpain-3 p.(Gly445Arg) mutant expressed alone had the same proteolytic profile as the calpain-3 p.(Cys129Ser) mutant (Figure 3A), indicating the absence of autolytic activity.

In the second experiment, we co-transfected calpain-3 p.(Cys129Ser) as a substrate and the different cal-pain-3 constructs and mutants to examine catalytic activities. Co-expression with WT calpain-3 led to par-tial degradation of calpain-3 p.(Cys129Ser), as seen by the presence of a fragment at 56 kDa (Figure 3B).

The co-expression with calpain-3 p.(Gly445Arg) mutant shows only the calpain-3 full-length band (Figure 3B), which means that this mutated protein is not effective at cleaving other calpain-3.

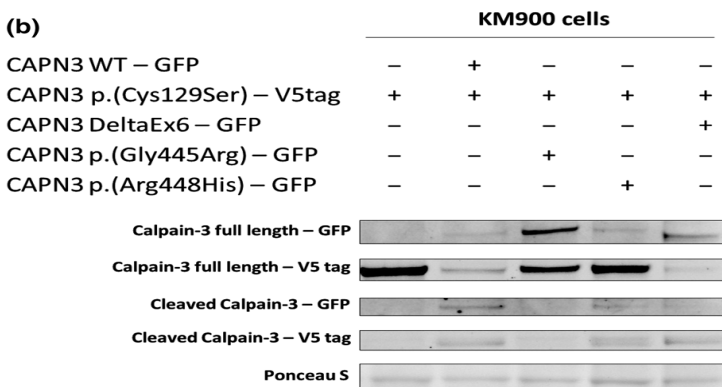
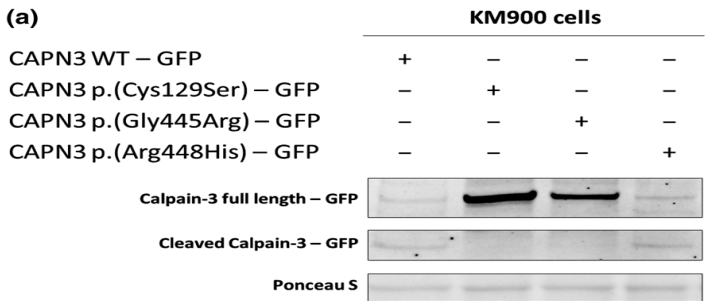
Another c.1343G>A p.(Arg448His) CAPN3 variant, close to our variant, is known to retain catalytic activ-ity but loses the interaction with titin [30]. As previ-ously described, we show that this calpain-3 p.(Arg448His) mutant cleaves the calpain-3 p.(Cys129-Ser) protein (Figure 3B). All together, these results indi-cate that the c.1333G>A [p.(Gly445Arg)] variant impacts calpain-3 catalytic activity and intra/inter-molecular autolysis.

Figure 3. Intramolecular and intermolecular autolytic activity of different calpain-3 forms. Cells were transfected with different plasmid construction alone (A) or in combination (B) with CAPN3 p.(Cys129Ser). Forty-eight hours after transfection, cells were harvested and lysed for protein extraction. Western blot analysis was performed using an anti-GFP (1/5000, ab5449; Abcam) and an anti-V5tag (1/1000, ab27671; Abcam).

Discussion

We report here the second well-documented CAPN3 variant associated with autosomal dominant inherited calpainopathies. Indeed, we identified a single heterozy-gous c.1333G>A [p.(Gly445Arg)] CAPN3 variant in 14 patients from four independent families. The familial segregation analysis performed for members of the four families described here is strongly suggestive of an autosomal dominant inheritance. Our findings confirm the existence of autosomal dominant calpainopathies, as an entity beyond the cases related to the initially described recurrent CAPN3 variant [9].

This autosomal dominant inheritance was recently described for late-onset and mild forms of calpain-opathies [9,10]. Interestingly, patients from the four families described here also presented with a mild phe-notype, with hyperCKaemia, myalgia and/ or moderate



proximal muscle weakness, predominantly affecting the hamstrings as shown by muscle imaging (Figure 2), therefore expanding the phenotypic spectrum of cal-painopathies.

Three subjects from our cohort had camptocormia. The same presentation of late-onset axial myopathy has been previously described in a patient carrying a single heterozygous *CAPN3* variant, c.759_761delGAA, suggesting a possible familial autosomal dominant cal-painopathy [31]. Moreover, among patients carrying the c.643_663del21 *CAPN3* variant, paraspinal muscles were particularly affected on MRI studies [9].

These observations suggest that an autosomal dominant calpainopathy should be considered when faced with a prominent axial myopathy, widening the spectrum of neuromuscular disorders for which MRI is useful in assisting genetic testing beyond the recent observations for distal myopathies [32].

Thus, it is reasonable to conceive a broad continuum of clinical phenotypes for calpainopathies, from severe early childhood onset to moderate adult-onset autosomal recessive forms [24,33], possibly depending on the *CAPN3* mutational combination, overlapping with milder late-onset autosomal dominant forms that could extend to the extreme end of the spectrum to isolated hyperCKaemia. The evaluation of serum CK levels, despite its nonspecificity, seems to be of importance for autosomal dominant calpainopathies as it is a significant presenting finding. However, there is great variability in terms of levels and positivity for this biomarker, as demonstrated by patient 2/IV.6 (Table 1 and Figure 1), similar to other cases reported in the literature [9].

It is likely that some of these late-onset mild clinical phenotypes could easily have been confused with supposedly natural muscular senescence or even missed because of the patient's premature death, only to be discovered recently as life expectancy gradually extended and novel biomarkers, notably CK measurement, as well as complementary diagnosis tool, such as muscle MRI, were available, enabling us to objectify and label these atypical clinical phenotypes.

In addition, we describe exertional rhabdomyolysis in two siblings (3/III.1 and 3/III.2 in Figure 1). Although this clinical presentation has to be confirmed for other reported cases before considering it a definite feature of calpainopathies, such a presentation has already been described for other genes associated with LGMD, such

as *CAV3*, *GMPPB* and more recently *SGCA* and *TCAP* [34-36]. Thus, autosomal dominant inherited calpainopathy should be considered when faced by a wide range of initial phenotypic presentations from hyperCKaemia (asymptomatic or not), myalgia with or without exertional rhabdomyolysis to mild LGMD.

This experience demonstrates that despite the advent of NGS, the simplest assumption remains the first one to consider; in the present case, the probable existence of an autosomal dominant form of calpainopathy associated with the c.1333G>A *CAPN3* variant. Indeed, despite numerous molecular analyses, especially by NGS, no alternative molecular diagnosis could be established for these four different families, thus consolidating the implication of this *CAPN3* variant in an autosomal dominant inherited calpainopathy.

At the functional level, c.1333G>A [p.(Gly445Arg)] *CAPN3* variant involves a modification of calpain-3 catalytic activity in cells, with a loss of intramolecular and intermolecular autolysis (Figure 3). The origin of this modification of activity could be an indirect loss of catalytic activity and possibly a modification of interactions with partners due to conformational changes in the protein structure. Indeed, using the available information regarding the calpain-3 structure, we locate the

c.1333G>A [p.(Gly445Arg)] *CAPN3* variant in the cal-pain β -sandwich domain (CBSW) interacting with the penta-EF-hand domain (PEF) supposedly involved in the dimerization of two calpain-3 units [37]. Interestingly, the c.1333G>A [p.(Gly445Arg)] *CAPN3* variant is located on a loop of the CBSW domain that has interactions with the PEF domain, and is expected to be involved in the communication of Ca^{2+} -induced conformational change throughout these domains. Therefore, the charge alteration associated with the

c.1333G>A [p.(Gly445Arg)] *CAPN3* variant could disrupt communication between Ca^{2+} -induced alteration in the PEF domain and the rest of the molecule [38]. Consequently, the c.1333G>A [p.(Gly445Arg)] *CAPN3* variant could indirectly impair the catalytic activity of the mutated calpain-3 protein and secondarily, due to conformation changes, disrupt interactions with partners potentially resulting in the retention of calpain-3 in the sarcomere due to strong interaction with titin and/or to the other functional calpain-3 allele in case of homodimerization. This suggestion is reinforced by the fact that calpain-3 has already been shown to interact with titin in the region of the p.(Gly445Arg)

variant [39] and a modification of arginine in the nearby 448 amino acid position induces a loss of this interaction [30]. The c.1333G>A [p.(Gly445Arg)] variant adds an arginine in proximity to this interaction site which could increase the interaction with titin, leading to retention of calpain-3 in the sarcomere. Therefore, our favoured hypothesis for the pathophysiological mechanisms associated with the c.1333G>A [p.(Gly445Arg)] *CAPN3* variant is a dominant-negative effect, as also suggested for the c.643_663del21 *CAPN3* variant [9].

Identification of the c.1333G>A [p.(Gly445Arg)] *CAPN3* variant, initially considered pathogenic for autosomal recessive calpainopathies, also reveals an important issue for diagnostic genetics laboratories. Indeed, it can be very difficult to establish a causal link between a variant, described as pathogenic in the literature and different databases, and an unexpected phenotype and/or transmission mode for the considered gene. For instance this must be taken into account for mild and late-onset phenotypes or subclinical phenotypes such as isolated hyperCKaemia for which the genetic aetiology could legitimately be questioned. However, in the present case, isolated hyperCKaemia should not be neglected because it reveals a potential deleterious muscular process, that can stay clinically silent for the first fifth or sixth decades of life, only to be at a later stage associated to functional and clinical manifestations, thus revealing the variable limits of the muscular resilience for each individual, even within the same family. Furthermore, this autosomal dominant inheritance could be particularly prone to modifying genetic or environmental effects, therefore explaining the phenotypic heterogeneity and even the seemingly incomplete penetrance already observed for autosomal dominant inherited calpainopathies [9]. In fact, this point has already been raised at the time of the initial description by Vissing *et al.*, regarding especially haplotype combinations or *cis*-variants potentially affecting regulatory regions of the *CAPN3* expression [40,41]. However, for the families described here, all available information clearly indicates an autosomal dominant inheritance associated with the c.1333G>A *CAPN3* variant. Therefore, in addition to the clear impact for genetic counselling, these findings could also lead the way to the reassessment of other forms of myopathies where the genetic inheritance is, to date, considered to be strictly autosomal recessive.

Acknowledgements

We sincerely thank Nathalie Da Silva, Valérie Delague, Karine Bertaux, Cécile Mouradian, Pierre Cacciagli, Catherine Badens, Rafaëlle Bernard, Jean-Pierre Desvignes, David Salgado and Christophe Bérourd for their contribution to this work. We would like to thank GIP-TIS (Genetics Institute for Patients, Therapies Innovation and Science) for its generous support. We also wish to thank the patients, families and health professionals whose participation made possible this research.

Author contributions

MC, ECS, MB, MK and SA contributed to conception and design of the study. MC, ECS, PC, DR, AS, RJM, CT, FL, TS, AMDP, JP, MC, MB, MK and SA contributed to data acquisition and analysis. MC, ECS, DR, AS, CT, TS, NBP, SG, JM, AMDP, NL, JP, MC, MB, MK and SA contributed to drafting the manuscript and preparing tables and figures.

Funding information

FHU A*MIDEX project MARCHE n.ANR-11-IDEX-001-02 funded by the “Investissement d’avenir” French government program, managed by the French National Research Agency (ANR).

Disclosure

The authors have no conflicts of interest to disclose.

Ethical approval

Informed consent was obtained for all patients, according to the Declaration of Helsinki.

Data availability statement

The data that support the findings of this study are available on request from the corresponding author. The data are not publicly available due to privacy or ethical restrictions.

References

- 1 Zatz M, Starling A. Calpains and disease. *N Engl J Med* 2005; 352: 2413–23

- 2 Guglieri M, Magri F, D'Angelo MG, Prelle A, Morandi L, Rodolico C, et al. Clinical, molecular, and protein correlations in a large sample of genetically diagnosed Italian limb girdle muscular dystrophy patients. *Hum Mutat* 2008; **29**: 258–66
- 3 Angelini C, Nardetto L, Borsato C, Padoan R, Fanin M, Nascimbeni AC, Tasca E. The clinical course of calpainopathy (LGMD2A) and dysferlinopathy (LGMD2B). *Neurol Res* 2010; **32**: 41–6
- 4 Luo S-S, Xi J-Y, Zhu W-H, Zhao C-B, Lu J-H, Lin J, et al. Genetic variability and clinical spectrum of Chinese patients with limb-girdle muscular dystrophy type 2A. *Muscle Nerve* 2012; **46**: 723–9
- 5 Richard I, Broux O, Allamand V, Fougerousse F, Chinnilkulchai N, Bourg N, et al. Mutations in the proteolytic enzyme calpain 3 cause limb-girdle muscular dystrophy type 2A. *Cell* 1995; **81**: 27–40
- 6 Kramerova I, Kudryashova E, Venkatraman G, Spencer MJ. Calpain 3 participates in sarcomere remodeling by acting upstream of the ubiquitin-proteasome pathway. *Hum Mol Genet* 2005; **14**: 2125–34
- 7 Duguez S, Bartoli M, Richard I. Calpain 3: a key regulator of the sarcomere? *FEBS J* 2006; **273**: 3427–36
- 8 Ono Y, Ojima K, Torii F, Takaya E, Doi N, Nakagawa K, et al. Skeletal muscle-specific calpain is an intracellular Na⁺-dependent protease. *J Biol Chem* 2010; **285**: 22986–98
- 9 Vissing J, Barresi R, Witting N, Van Ghelue M, Gammelgaard L, Bindoff LA, et al. A heterozygous 21-bp deletion in CAPN3 causes dominantly inherited limb girdle muscular dystrophy. *Brain* 2016; **139**: 2154–63
- 10 Martinez-Thompson JM, Niu Z, Tracy JA, Moore SA, Swenson A, Wieben ED, et al. Autosomal dominant calpainopathy due to heterozygous CAPN3 C.643_663del21. *Muscle Nerve* 2018; **57**: 679–83
- 11 Nallamilli BRR, Chakravorty S, Kesari A, Tanner A, Ankala A, Schneider T, et al. Genetic landscape and novel disease mechanisms from a large LGMD cohort of 4656 patients. *Ann Clin TranslNeurol* 2018; **5**: 1574–87
- 12 Straub V, Murphy A, Udd B, Corrado A, Aymé S, Bönneman C, et al. 229th ENMC international workshop: limb girdle muscular dystrophies – nomenclature and reformed classification Naarden, the Netherlands, 17–19 March 2017. *Neuromuscular Disord* 2018; **28**: 702–10
- 13 Krahn M, Biancalana V, Cerino M, Perrin A, Michel-Calemard L, Nectoux J, et al. A National French consensus on gene lists for the diagnosis of myopathies using next-generation sequencing. *Eur J Hum Genet* 2019; **27**: 349–52
- 14 Krahn M, Lopez de Munain A, Streichenberger N, Bernard R, Pécheux C, Testard H, et al. CAPN3 mutations in patients with idiopathic eosinophilic myositis. *Ann Neurol* 2006; **59**: 905–11
- 15 Gorokhova S, Cerino M, Mathieu Y, Courrier S, Desvignes JP, Salgado D, et al. Comparing targeted exome and whole exome approaches for genetic diagnosis of neuromuscular disorders. *Appl Transl Genom* 2015; **7**: 26–31
- 16 Zenagui R, Lacourt D, Pegeot H, Yaou K, Juntas Morales R, Theze C, et al. A reliable targeted next-generation sequencing strategy for diagnosis of myopathies and muscular dystrophies, especially for the giant titin and nebulin genes. *J Mol Diagn* 2018; **20**: 533–49
- 17 Kaplan J-C, Hamroun D. The 2014 version of the gene table of monogenic neuromuscular disorders (nuclear genome). *Neuromuscul Disord* 2013; **23**: 1081–111
- 18 den Dunnen JT, Dalgleish R, Maglott DR, Hart RK, Greenblatt MS, McGowan-Jordan J, et al. HGVS recommendations for the description of sequence variants: 2016 update. *Hum Mutat* 2016; **37**: 564–9
- 19 Milic A, Daniele N, Lochmüller H, Mora M, Comi GP, Moggio M, et al. A third of LGMD2A biopsies have normal calpain 3 proteolytic activity as determined by an in vitro assay. *Neuromuscul Disord*. 2007; **17**: 148–56
- 20 Mamchaoui K, Trollet C, Bigot A, Negroni E, Chaouch S, Wolff A, et al. Immortalized pathological human myoblasts: towards a universal tool for the study of neuromuscular disorders. *Skelet Muscle* 2011; **1**: 34
- 21 Richards S, Aziz N, Bale S, Bick D, Das S, Gastier-Foster J, et al. Standards and guidelines for the interpretation of sequence variants: a joint consensus recommendation of the American College of Medical Genetics and Genomics and the Association for Molecular Pathology. *Genet Med* 2015; **17**: 405–24
- 22 Fokkema IFAC, Taschner PEM, Schaafsma GCP, Celli J, Laros JF, den Dunnen JT LOVD vol 2.0: the next generation in gene variant databases. *Hum Mutat* 2011; **32**: 557–63
- 23 Landrum MJ, Lee JM, Benson M, Brown GR, Chao C, Chitipiralla S, et al. ClinVar: improving access to variant interpretations and supporting evidence. *Nucleic Acids Res* 2018; **46**: D1062–7
- 24 Richard I, Roudaut C, Saenz A, Pogue R, Grimbergen J, Anderson L, et al. Calpainopathy—a survey of mutations and polymorphisms. *Am J Hum Genet* 1999; **64**: 1524–40
- 25 Fanin M, Fulizio L, Nascimbeni AC, Spinazzi M, Piluso G, Ventriglia V, et al. Molecular diagnosis in LGMD2A: mutation analysis or protein testing? *Hum Mutat* 2004; **24**: 52–62
- 26 Sáenz A, Leturcq F, Cobo AM, Poza JJ, Ferrer X, Otaegui D, et al. LGMD2A: genotype-phenotype correlations based on a large mutational survey on the calpain 3 gene. *Brain* 2005; **128**: 732–42
- 27 Nascimbeni AC, Fanin M, Tasca E, Angelini C. Transcriptional and translational effects of intronic CAPN3 gene mutations. *Hum Mutat* 2010; **31**: E1658–69

- 28 Schröder T, Fuchss J, Schneider I, Stoltenburg-Didinger G, Hanisch F. Eosinophils in hereditary and inflammatory myopathies. *Acta Myol* 2013; **32**: 148–53
- 29 Magri F, Colombo I, Del Bo R, Previtali S, Brusa R, Ciscato P, et al. ISPD mutations account for a small proportion of Italian Limb Girdle Muscular Dystrophy cases. *BMC Neurol* 2015; **15**: 172
- 30 Ermolova N, Kudryashova E, DiFranco M, Vergara J, Kramerova I, Spencer MJ. Pathogenicity of some limb girdle muscular dystrophy mutations can result from reduced anchorage to myofibrils and altered stability of calpain 3. *Hum Mol Genet* 2011; **20**: 3331–45
- 31 Liewluck T, Goodman BP. Late-onset axial myopathy and camptocormia in a calpainopathy carrier. *J Clin Neuromuscul Dis* 2012; **13**: 209–13
- 32 Bugiardini E, Morrow JM, Shah S, Wood CL, Lynch DS, Pitmann AM, Lynch DS, Pitmann AM, et al. The diagnostic value of MRI pattern recognition in distal myopathies. *Front Neurol* 2018; **9**: 456
- 33 Fanin M, Angelini C. Protein and genetic diagnosis of limb girdle muscular dystrophy type 2A: the yield and the pitfalls. *Muscle Nerve* 2015; **52**: 163–73
- 34 Scalco RS, Gardiner AR, Pitceathly RDS, Hilton-Jones D, Schapira AH, Turner C, et al. CAV3 mutations causing exercise intolerance, myalgia and rhabdomyolysis: Expanding the phenotypic spectrum of caveolinopathies. *Neuromuscul Disord.* 2016; **26**: 504–10
- 35 Cabrera-Serrano M, Ghaoui R, Ravenscroft G, Johnsen RD, Davis MR, Corbett A, et al. Expanding the phenotype of GMPPB mutations. *Brain* 2015; **138**: 836–44
- 36 Rubegni A, Malandrini A, Dosi C, Astrea G, Baldacci J, Battisti C, et al. Next-generation sequencing approach to hyperCKemia: a 2-year cohort study. *Neurol Genet.* 2019; **5**: e352
- 37 Ye Q, Campbell RL, Davies PL. Structures of human calpain-3 protease core with and without bound inhibitor reveal mechanisms of calpain activation. *J Biol Chem* 2018; **293**: 4056–70
- 38 Jia Z, Petrounevitch V, Wong A, Moldoveanu T, Davies PL, Elce JS, Davies PL, Elce JS, et al. Mutations in calpain 3 associated with limb girdle muscular dystrophy: analysis by molecular modeling and by mutation in m-calpain. *Biophys J* 2001; **80**: 2590–6
- 39 Ono Y, Torii F, Ojima K, Doi N, Yoshioka K, Kawabata Y, et al. Suppressed disassembly of autolyzing p94/CAPN3 by N2A connectin/titin in a genetic reporter system. *J Biol Chem* 2006; **281**: 18519–31
- 40 Sáenz A, López de Munain A. Dominant LGMD2A: alternative diagnosis or hidden digenism? *Brain* 2017; **140**: e7
- 41 Vissing J, Duno M. Reply: dominant LGMD2A: alternative diagnosis or hidden digenism? *Brain* 2017; **140**: e8

Supporting information

Additional Supporting Information may be found in the online version of this article at the publisher's web-site:

Appendix S1. Detailed genes panels and genes lists.