



**HAL**  
open science

## The phenotype caused by recessive variations in SLC25A22: Report of a new case and literature review

M.-V. André, Pierre Cacciagli, A. Cano, L. Vaugier, M. Roussel, N. Girard,  
Brigitte Chabrol, Laurent Villard, Mathieu Milh

### ► To cite this version:

M.-V. André, Pierre Cacciagli, A. Cano, L. Vaugier, M. Roussel, et al.. The phenotype caused by recessive variations in SLC25A22: Report of a new case and literature review. Archives de Pédiatrie, 2021, 28 (1), pp.87-92. 10.1016/j.arcped.2020.10.015 . hal-03148905

**HAL Id: hal-03148905**

**<https://amu.hal.science/hal-03148905>**

Submitted on 3 Feb 2023

**HAL** is a multi-disciplinary open access archive for the deposit and dissemination of scientific research documents, whether they are published or not. The documents may come from teaching and research institutions in France or abroad, or from public or private research centers.

L'archive ouverte pluridisciplinaire **HAL**, est destinée au dépôt et à la diffusion de documents scientifiques de niveau recherche, publiés ou non, émanant des établissements d'enseignement et de recherche français ou étrangers, des laboratoires publics ou privés.



Distributed under a Creative Commons Attribution - NonCommercial 4.0 International License

## **The phenotype caused by recessive variations in SLC25A22: report of a new case and literature review**

Short title: Phenotype caused by recessive variations in SLC25A22

M.-V. André<sup>a\*</sup>, P. Cacciagli<sup>b,c</sup>, A. Cano<sup>a</sup>, L. Vaugier<sup>d</sup>, M. Roussel<sup>e</sup>, N. Girard<sup>f</sup>, B. Chabrol<sup>a</sup>, L. Villard<sup>b,c</sup>, M. Milh<sup>a,b</sup>

<sup>a</sup>APHM, Department of Pediatric Neurology, Hôpital de la Timone, 13085 Marseille, France

<sup>b</sup> Aix-Marseille University, INSERM, GMGF, UMR\_S 910, Faculté de médecine, 13085 Marseille, France

<sup>c</sup> APHM Department of Medical Genetics, Hôpital de La Timone, 13085 Marseille, France

<sup>d</sup> APHM, Department of Clinical Neurophysiology, Hôpital de la Timone, 13085 Marseille, France

<sup>e</sup> APHM, Department of Clinical Neurophysiologie, Hôpital Nord, 13015 Marseille, France

<sup>f</sup> Department of Neuroradiology, Aix-Marseille University, AP-HM, 13085 Marseille, France

\*Corresponding author: mvcanavese@outlook.com

Conflicts of interest: The authors declare no conflicts of interest

### **Abstract**

We describe the clinical, electroencephalography (EEG), and developmental features of a patient with developmental and epileptic encephalopathy due to a homozygous pathogenic variation of mitochondrial glutamate/H<sup>+</sup> symporter SLC25A22. Epilepsy began during the first week of life with focal onset seizures. Interictal EEG revealed a suppression-burst pattern with extensive periods of non-activity. The prospective follow-up confirmed developmental

encephalopathy as well as ongoing active epilepsy and almost no sign of development at 8 years of age.

We confirm in the following paper that SLC25A22 recessive variations may cause a severe developmental and epileptic encephalopathy characterized by a suppression-burst pattern. On the basis of an in-depth literature review, we also provide an overview of this rare genetic cause of neonatal onset epilepsy.

**Keyword:** SLC25A22, early developmental and epileptic encephalopathy, suppression-burst, myoclonic seizures.

## 1. Introduction

Homozygous variations in the SLC25A22 gene were first identified in four siblings from a consanguineous family who presented with early-onset developmental and epileptic encephalopathy and a suppression-burst pattern on electroencephalograms (EEGs) [1]. This highly recognizable pattern is described as entanglements of generalized and multifocal, high-voltage, spikes and sharp waves alternating with periods of suppression. This pattern is a distinctive feature of two severe epilepsies with neonatal onset: Ohtahara syndrome and Early myoclonic encephalopathy (EME) [2].

Functional analysis of the variant proteins demonstrated that the variations impaired the mitochondrial transport of glutamate without altering the mitochondrial respiratory chain function [3].

Since then, the cases of 11 patients from several families have been reported [1-5]. Their phenotype was quite diverse in terms of epileptic syndrome, but relatively similar in terms of age of onset, severity of epilepsy, and poor outcome.

In the current case, we describe a child prospectively followed up in our institution for early-onset developmental and epileptic encephalopathy with initial EEGs showing poor activity

with a suppression-burst pattern, as well as initial severe neonatal distress followed by ongoing active epilepsy with epileptic spasms and tonic seizures and acquired microcephaly with absence of any development.

## **2. Case study**

The proband is the third child of consanguineous parents, without any familial history of epilepsy. She was born at 39 weeks of gestation (GA). Her mother had gestational diabetes that was treated with diet. The infant was born by cesarean section before the due date because of uterine scarring; with normal measurements (head circumference [HC] 36 cm, birth height [BH]: 47cm, birth weight [BW]: 3,200g). She received initial noninvasive ventilatory support for neonatal poor adaptation. A predominantly bilateral subependymal hemorrhage on the right and a bilateral intraventricular hemorrhage were found on transfontanellar ultrasound on the first day of life.

Epilepsy began on the first day of life with seizures characterized by an access of cyanosis, bradycardia, and hypotonia. The first EEG (Figure 1) performed on the first day of life depicted a discontinuous pattern of flattening periods alternating with periods of bursts of theta activity in temporal regions. Focal hemispheric seizures were also recorded: hypertonic posture for 10 s with cyanosis followed by bilateral clonic jerks of the arms and mouth. Seizures were very frequent and highly resistant to treatment. Only with phenobarbital could the seizure duration be reduced and the cyanosis eliminated. Under treatment, focal seizure consisted in facial twitching with head rejection and hypersialorrhea, and occurred an average of three times a day.

Epilepsy remained active ever since. Myoclonic epileptic jerks were observed at 12 months and epileptic spasms were recorded at 16 months of age. They occurred in clusters, mostly

during the awake state and were followed by chewing for several seconds. At this time, EEG showed a hypsarrhythmic pattern.

The patient experienced a significant developmental delay: She has showed no or very poor signs of development and has acquired microcephaly (Figure 2). At the age of 5 years, she failed to display any eye contact or voluntary movements and performed few spontaneous movements. She showed global and severe hypotonia without any pyramidal sign. Tonic seizures occurred in clusters during transition periods between wakefulness and sleep (Figure 1).

Several treatments were tried, e.g., topiramate, carbamazepine, vigabatrin, clonazepam, and levetiracetam, with the most effective being phenobarbital.

Initial brain magnetic resonance imaging (MRI) did not show any abnormality. At 17 months of age, the second MRI showed a prominent aspect of the lateral ventricles with atrophy of the cerebral parenchyma. The frontal horns of the ventricles appeared pointed. There was a hypersignal of serrated nuclei in the posterior fossa combined with a hypersignal of the trunk sensory bundles at the protuberance level (Figure 3). The posterior periventricular white matter appeared as a hypersignal. An electroretinogram was normal (3y), visual evoked potential (VEP) was symmetrically altered, and an electromyogram was normal. An extensive metabolic work-up found intermittently elevated plasma ornithine (197  $\mu\text{mol/L}$ , reference range: 59–99) (Table 1).

Array-based comparative genomic hybridization analysis using a next-generation sequencing method yielded normal results. This method relies on a disease-related gene set (supplementary methods), and a c.835dupG (p.Glu279Glyfs\*138) homozygous variation was found in the SLC25A22 gene.

### **3. Discussion**

We describe here a patient with a neonatal onset of developmental and epileptic encephalopathy related to a homozygous truncating mutation of SLC25A22.

The phenotype is very severe, and our patient had a poor and discontinuous initial EEG showing a suppression-burst pattern, with very active and resistant multifocal epilepsy evolving to West syndrome, and subsequent multifocal epilepsy with tonic seizures, almost no developmental acquisition, no brain malformation on MRI but progressive atrophy with acquired microcephaly.

These features are relatively close to what has already been described in patients with bi-allelic variations of SLC25A22 (Table 2): early onset of seizures in the first week of life or before the third month in almost all cases, abnormal initial EEG, poor and discontinuous or multifocal abnormalities, acquired microcephaly, and very severe developmental delay and abnormal VEPs.

It should be noted that the mutation in our patient is truncating while those of other cases are failed mutations, which may explain the less severe phenotype of some patients. This is the case of the patient with a milder phenotype, i.e., isolated developmental delay and well-controlled epilepsy that began at the age of 7 [5].

Reid et al. also reported elevated plasma proline levels, the presence of vacuolated fibroblasts, and intermittently elevated plasma ornithine or arginine levels in their patients. Interestingly, while reviewing the metabolic work-up of the patient we describe here, we also found intermittently elevated plasma ornithine levels. In patients with SLC25A22 deficiency, defective mitochondrial export of glutamate or P5C could lead to high intramitochondrial

concentrations and eventually reduced catabolism of proline and increased synthesis of ornithine and arginine [5].

SLC25A22 belongs to solute carrier mitochondrial transporters. It is involved in glutamate transmission and is key to brain and liver homeostasis [5, 6]. Functional in vitro studies have recently shown that silencing SLC25A22 in primary astrocytes resulted in a reduced nicotinamide adenine dinucleotide (Phosphate) (NAD(P)H) formation upon glutamate stimulation, a lower level of cellular adenosine triphosphate (ATP) in silenced astrocytes compared with control cells, as well as an intracellular glutamate accumulation following deficient glutamate clearance. Interestingly, as shown in previous analyses, deficiency in glutamate clearance leads to epileptic-like discharges episodes in vitro and to a burst-suppression pattern in rat pups [6-9]. Therefore, glutamate accumulation in astrocytes might be the starting point for hyper-excitability formation.

An EEG suppression-burst pattern is highly recognizable from the first day and during awakeness. Moreover, periods of silence have been detected in normal neonates who did not receive any treatment. Two epileptic syndromes have been associated with an initial suppression-burst pattern on EEG: EME and early infantile epileptic encephalopathy (EIEE).

The main differences between these two epileptic syndromes are the seizure phenotype, i.e., myoclonic seizures in EME, epileptic spasms and tonic seizures in EIEE, and the EEGs in EME, contrary to EIEE, show bursts of activity that are shorter than the silent periods.

These two syndromes probably overlap, both in terms of phenotype and in terms of a genetic basis. In the present case, the patient showed partial, vegetative seizures. This seizure is not a common feature of the two syndromes. Moreover, a very poor initial EEG favors an EME

diagnosis. In fact, it is very difficult to define the epileptic phenotype of our patient using this dichotomous classification, as already reported in several cases [3].

#### **4. Conclusion**

SLC25A22 recessive variations may cause a severe developmental and epileptic encephalopathy characterized by a suppression-burst pattern as well as metabolic abnormalities.

#### **Acknowledgments**

This work was partially funded by the JED Fondation Belgique, Inserm, and Aix Marseille University.

#### **References**

1. Cohen R, Basel-Vanagaite L, Goldberg-Stern H, et al. Two siblings with early infantile myoclonic encephalopathy due to mutation in the gene encoding mitochondrial glutamate/H<sup>+</sup> symporter SLC25A22. *Eur J Paediatr Neurol* 2014;18:801-5.
2. Molinari F, Raas-Rothschild A, Rio M, Fiermonte G, et al. Impaired mitochondrial glutamate transport in autosomal recessive neonatal myoclonic epilepsy. *Am J Hum Genet* 2005;76:334-9.
3. Molinari F, Kaminska A, Fiermonte G, et al. Mutations in the mitochondrial glutamate carrier SLC25A22 in neonatal epileptic encephalopathy with suppression bursts. *Clin Genet* 2009;76:188-94.
4. Poduri A, Heinzen EL, Chitsazzadeh V, et al. SLC25A22 is a novel gene for migrating partial seizures in infancy. *Ann Neurol* 2013;74:873-82.



5. Reid ES, Williams H, Anderson G, et al. Mutations in SLC25A22: hyperprolinaemia, vacuolated fibroblasts and presentation with developmental delay. *J Inherit Metab Dis* 2017;40:385-94.
6. Cattani AA, Bonfardin VD, Represa A,. Generation of slow network oscillations in the developing rat hippocampus after blockade of glutamate uptake. *J Neurophysiol* 2007;98:2324-36.
7. Milh M, Becq H, Villeneuve N, et al. Inhibition of glutamate transporters results in a « suppression-burst » pattern and partial seizures in the newborn rat. *Epilepsia* 2007;48:169-74.
8. Molinari F, Cattani AA, Mdzomba JB, et al. Glutamate transporters control metabotropic glutamate receptors activation to prevent the genesis of paroxysmal burst in the developing hippocampus. *Neuroscience* 2012;207:25-36.
9. Goubert E, Mircheva Y, Lasorsa FM, et al. Inhibition of the Mitochondrial Glutamate Carrier SLC25A22 in Astrocytes Leads to Intracellular Glutamate Accumulation. *Front Cell Neurosci* 2017;11:149

	2 months and 4 days ( $\mu\text{mol/L}$ )	2 months and 5 days ( $\mu\text{mol/L}$ )	2 months and 22 days ( $\mu\text{mol/L}$ )	Reference range ( $\mu\text{mol/L}$ )
TAURINE	83	213	91	29-143
AC.ASPART+ASPARAGINE	59	103	42	48-80
HYDROXYPROLINE	18	23	25	traces-73
THREONINE	105	145	108	102-176
SERINE	139	198	188	111-165
AC.GLUTAM+GLUTAMINE	650	732	471	500-674

**Table 1:** Plasma amino acids measured in our patient.

Amino acid concentrations elevated above the reference range are shown in yellow and those below the reference range are shown in green

PROLINE	99	142	107	135-239
GLYCINE	171	271	233	182-264
ALANINE	197	335	289	253-427
CITRULLINE	30	30	27	20-34
AC ALPHA AMINO BUTYR	12	12	8	10-28
VALINE	165	208	125	186-264
CYSTEINE	83	56	53	64-100
METHIONINE	22	30	15	23-35
ISOLEUCINE	51	76	47	40-80
LEUCINE	100	151	76	79-157
TYROSINE	54	70	46	59-101
PHENYLALANINE	38	59	31	49-67
ORNITHINE	93	197	98	59-99
HISTIDINE	64	94	67	69-101
LYSINE	153	211	122	153-239
ARGININE	73	32	43	56-104

**Table 2:** Clinical and paraclinical features of patients with *SCL25A22* variations

References	Gender	Age at onset	Neurological examination	Seizure type	EEG pattern	Brain imaging	Eye abnormalities	SLC25A22 mutation
Case report	F	1st day	Progressive microcephaly, hypotonia	focal and secondary generalization erratic myoclonic epileptic spasms	Burst suppression (BS)	Thin corpus callosum and brain atrophy (MRI)	ERG was normal, VEP was symmetrically altered	c.835dupG; p.Glu279Gly
Molinari et al. 2005 [2]	M	Birth	Hypotonia, microcephaly	Myoclonic	BS	Brain atrophy (CT)	Abnormal VEP	c.617C>T; p.Pro206Leu
	F	Birth	Hypotonia, microcephaly	Probably myoclonic	unknown	Brain atrophy (CT)	Unknown	c.617C>T; p.Pro206Leu
	F	Birth	Hypotonia, microcephaly	Myoclonic	BS	Subarachnoid enlargement and abnormal corpus callosum (MRI)	Abnormal VEP and ERG	c.617C>T; p.Pro206Leu
	M	Birth	Progressive microcephaly, first hypotonia, later spastic. Death at 8 years	Myoclonic, intractable	unknown	Unknown	Unknown	c.617C>T; p.Pro206Leu
Molinari et al. 2009 –[ 3]	M	5 days	Hypotonia, microcephaly, no psychomotor acquisition	Focal and secondary generalization evolving to West syndrome	BS and later hypsarrhythmia	Cerebellar hypoplasia, dysmorphism of the corpus callosum, abnormal gyration of both temporo-parietal regions, and abnormal myelination of temporal poles with lack of differentiation of white and gray matters (MRI)	Abnormal VEP and abnormal ERG	c.706G>T; p.Gly236Trp
Cohen et al. 2014-[1]	M	2 weeks	Progressive microcephaly, limb hypotonia, opisthotonos, no psychomotor acquisition	Focal seizures	BS	Thin corpus callosum, increased Virchow Robin spaces increased subarachnoid spaces and brain atrophy (MRI)	No response to light or movement, normal VEP	c.617C>T;p.Pro206Leu
	F	First month	Progressive microcephaly, first hypotonia, later spastic, no psychomotor	Erratic myoclonic focal seizures	BS	Thin corpus callosum and brain atrophy (MRI)	no response to light or movement, retinal pigmentation, normal VEP	c.617C>T;p.Pro206Leu

	acquisition							
Poduri et al. 2013 [4]	M	1 week	Hypotonic brisks deep tendon reflexes. Death at 14 months	Hemiconvulsive with color change and staring	Delta brush pattern in the left midtemporal region (T7), positive spikes in the right midtemporal region (T8), and high-voltage focal spikes in the right and left frontal regions	Normal at 1 month	VEPs and ERG were all normal	c.328G>C; p.Gly110Arg
	F	2 weeks	Hypotonic brisk deep tendon reflexes. Death at 47 months	Hemiconvulsive	Independent focal spikes in a multifocal distribution and partial seizures of multifocal origin.	Delayed myelination pattern and diffuse thinning of the corpus callosum (MRI)	ERGs were normal, but VEPs suggested bilateral optic pathway involvement.	c.328G>C; p.Gly110Arg
Reid et al. 2017 [5]	M	1 week	Hypotonic brisks deep tendon reflexes. Death at 14 months	Hemiconvulsive with color change and staring	Delta brush pattern in the left midtemporal region (T7), positive spikes in the right midtemporal region (T8), and high-voltage focal spikes in the right and left frontal regions	Normal at 1 month	VEPs and ERG were all normal	c.328G>C; p.Gly110Arg
	M	6 weeks	Severe global developmental delay	Myoclonic and generalized tonic-clonic seizures	Abnormal EEG	Frontotemporal hypoplasia, delayed myelination, prominent cerebellar folia and small splenium (MRI)	Abnormal VEP	c.166A>C; p.Thr56Pro
	M	16 weeks	Hypotonia, occasionally fixes and smiles	Flexor spasm-like semiology and generalized tonic-clonic seizures	Multifocal EEG abnormalities			c.166A>C; p.Thr56Pro

	F	First month	Hypotonia, sitting at 2 years and a half; she can babble at 7 years	tonic seizures, sometimes in clusters	Symmetrical diffuse irregular slow wave activity	Symmetrical signal abnormalities of the insular cortex and adjacent capsular white matter, delayed temporal lobe pole myelination, prominent folia and a small splenium (MRI)	c.166A>C; p.Thr56Pro	
	F	7 years	Walking at 3 years; 10 words at 3 years and a half; microcephaly	Absence of seizures		Delayed temporal lobe myelination, prominent cerebellar folia and a small splenium (MRI)	Hypermetropia, astigmatism and a right convergent squint	c.886G>A; p.Ala296Thr
	F	6 weeks	Hypotonia, delayed feeding and delayed visual development	Asymmetric clonic episodes. Evolves toward clusters of infantile spasms	Ictal EEG: right parietal lobe origin of the seizure. Multifocal discharges. Interictal EEG: semi discontinuous pattern with high-amplitude multifocal discharges	Normal (MRI)		c.235G>A; p.Glu79Lys c.246T>A; p.Val249Glu

EEG: electroencephalogram, BS: burst suppression, M: male, F: female

MRI: magnetic resonance imaging, CT: computed tomography, VEP: visual evoked potential, ERG: electroretinogram

## **Legend figure**

**Figure 1:** Representative electroencephalogram (EEG) pattern of the patient.

**A:** EEG performed on day 3 showing a focal-onset seizure (right temporal) with cyanosis, bradycardia, and extension of the four limbs at the end. **B:** Interictal EEG pattern showing very poor and disorganized activity with prolonged periods of silence alternating with short bursts of activity that are either asymptomatic or accompanied by a myoclonic jerk. **C:** Interictal EEG at 5 years of age showing multifocal spikes of short amplitude. **D:** EEG during a tonic seizure recorded at 5 years of age.

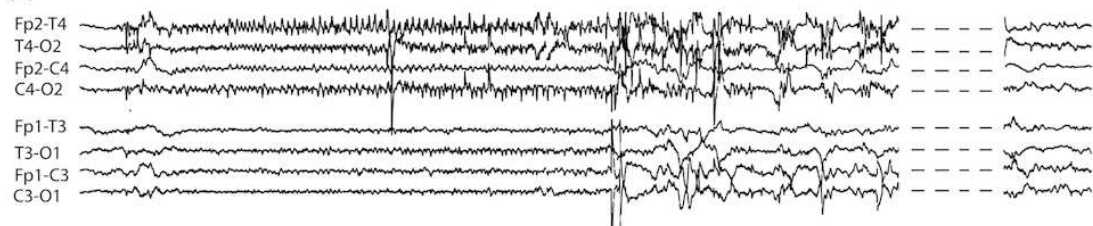
**Figure 2:** Head circumferences of patients with *SLC25A22* variations.

Violet: Case report; Yellow, clear green, blue, orange: Molinari et al. 2005; Dark green: Cohen et al. 2014; Black: Molinari et al. 2009.

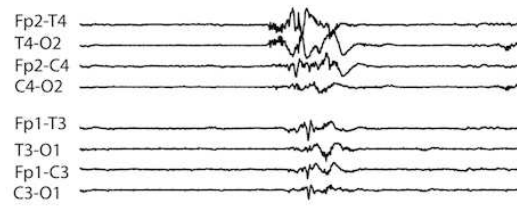
**Figure 3:** Magnetic resonance imaging of the patient's brain.

T2-weighted axial view of atrophy of the cerebral parenchyma (A); prominent aspect of the lateral ventricles; the frontal horns of the ventricles appear pointed (B); hypersignal of the sensory bundles of the trunk at the level of the protuberance (C); hypersignal T2-weighted image of serrated nuclei (D).

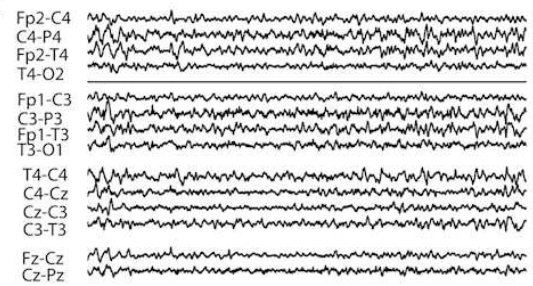
**A**



**B**



**C**



**D**





