



Severe adenovirus pneumonia with hemophagocytic syndrome and respiratory failure

C. La Fay, E. Bosdure, M. Baravalle-Einaudi, N. Stremler-Le Bel, J-C Dubus, J. Mazenq

► To cite this version:

C. La Fay, E. Bosdure, M. Baravalle-Einaudi, N. Stremler-Le Bel, J-C Dubus, et al.. Severe adenovirus pneumonia with hemophagocytic syndrome and respiratory failure. Archives de Pédiatrie, 2020, 27 (7), pp.383-385. 10.1016/j.arcped.2020.07.003 . hal-03149702

HAL Id: hal-03149702

<https://amu.hal.science/hal-03149702>

Submitted on 17 Oct 2022

HAL is a multi-disciplinary open access archive for the deposit and dissemination of scientific research documents, whether they are published or not. The documents may come from teaching and research institutions in France or abroad, or from public or private research centers.

L'archive ouverte pluridisciplinaire **HAL**, est destinée au dépôt et à la diffusion de documents scientifiques de niveau recherche, publiés ou non, émanant des établissements d'enseignement et de recherche français ou étrangers, des laboratoires publics ou privés.



Distributed under a Creative Commons Attribution - NonCommercial 4.0 International License

Severe adenovirus pneumonia with hemophagocytic syndrome and respiratory failure

Short title: Adenovirus pneumonia and hemophagocytic syndrome

C. La Fay^{1*}, E. Bosdure¹, M. Baravalle-Einaudi¹, N. Stremler-Le Bel¹, J.-C. Dubus^{1,2},
J. Mazenq¹

¹ Pediatric Pulmonology Department, Timone Children's Hospital, 264 rue Saint
Pierre, 13385 Marseille Cedex 5, France

² Aix-Marseille Université, AP-HM, IRD, MEPHI, IHU-Méditerranée Infection,
13005 Marseille

*Corresponding author: Charlotte La Fay

Charlotte.la-fay@ap-hm.fr

264 rue Saint-Pierre, 13385 Marseille, France

04 91 38 68 07

Conflicts of interest: none

Acknowledgements: We thank the editor who has edited the English version of the manuscript.

ABSTRACT

We report the case of an 18-month-old infant with severe serotype 3 adenovirus pneumonia, exceptionally associated with hemophagocytic syndrome. Treatment included cidofovir and mechanical ventilation for 13 days. The child developed chronic respiratory insufficiency due to bronchiectasis and bronchiolitis obliterans.

Keywords: Adenovirus, bronchiectasis, bronchiolitis obliterans, chronic respiratory failure, cidofovir

1. INTRODUCTION

Human adenovirus (HAdV) affects the upper and lower respiratory tracts, conjunctivae, gastrointestinal tract, and brain. HAdV is ubiquitous in the environment throughout the world and is transmitted via direct contact, the water system, small droplet aerosols, and fecal-oral spread [1]. Epidemics occur in the winter or early spring, affecting preferentially young children (<4 years of age) and immunosuppressed individuals. Concerning respiratory infections, HAdV account for at least 5–10% of pediatric respiratory tract infections and 3.9% of pediatric asthma attacks [1]. Respiratory sequelae may be severe. We report here the case of an 18-month-old infant with no past medical history, who presented severe HAdV pneumonia associated with hemophagocytic syndrome (HS) responsible for chronic respiratory failure due to both bronchiectasis and bronchiolitis obliterans (BO).

2. OBSERVATION

An Algerian 18-month-old infant with no past medical history was admitted in December 2017 for acute respiratory distress with chest indrawing, wheezing, and oxygen needs up to 3 L/min to keep pulsed oxygen saturation above 92%. The chest x-ray showed middle-lobe pneumonia that we treated with amoxicillin (100 mg/kg/day), as recommended by the French Pediatric Society (Figure 1). The microbiology of nasopharyngeal aspirations with polymerase chain reaction (PCR) were negative for respiratory syncytial virus and influenza A viruses, but positive for HAdV. The HAdV species identified later was species B serotype 3.

Antibiotics were switched to cefotaxime and vancomycin on day 5 due to clinical respiratory deterioration and biological inflammatory syndrome (CRP 204 mg/L). The infant was transferred to the pediatric intensive care unit and was intubated on day 10 to provide mechanical ventilation because of respiratory failure, increasing oxygen needs up to 5 L/min, and right upper lobe atelectasis (Figure 2). On day 12 a pericardial effusion and a right pleural effusion appeared, requiring drainage. HS was suspected because of persistent fever and occurrence of a pancytopenia (white blood cells 12 G/L, hemoglobin 9 g/dL, platelets 130 G/L), which was confirmed by myelogram and then treated with corticoids at 2 mg/kg for 24 h.

Cidofovir (5 mg/kg/week) was introduced on day 13 given that the HAdV PCR assay was positive in blood and pleural fluid and the viral load high (10^9 copies/mL). The infant was extubated on day 23 and switched to high-flow nasal canula (2 L/kg/min, FiO₂ 35–40%) for 10 days, then to standard nasal canula. Cidofovir was stopped on day 31 because of negative viral load. On day 37, acute infectious exacerbation with *Pseudomonas aeruginosa* required reuse of the high-flow nasal canula as well as 10 days of ciprofloxacin and long-term nebulized colimycin. A chest CT scan was performed on day 42 showing upper- and lower-lobe bronchiectasis and signs of BO

(Figures 3 and 4). This led to the decision to begin long-term treatment with azithromycin for its anti-inflammatory features, associated with monthly corticosteroid boluses (300 mg/m² 3 consecutive days per month), as recommended in French Pediatric Pneumology Guidelines. On day 46 we set up 24-h-a-day nonintensive ventilation. The infant was discharged from the pediatric intensive care unit on day 80.

The immune screening was normal (lymphocyte phenotyping, quantitative immunoglobulins, perforin dosage, and susceptibility to encapsulated bacteria). A chest CT scan at 6 months showed an increase in bronchiectasis. One year later, the child still needed oxygen support with high-flow nasal canula during the day with oxygen 2 L/min, every night switched to noninvasive ventilation with oxygen at 1 L/min. His treatments were monthly corticosteroid boluses, sequential antibiotics, anti-inflammatory azithromycin, and respiratory physiotherapy. This patient should eventually benefit from a lung transplant.

3. DISCUSSION

We report herein the case of an 18-month-old infant hospitalized for serotype 3 HAdV pneumonia complicated by HS and acute respiratory distress syndrome, leading to chronic respiratory disease with bronchiectasis and BO.

HAdV, a nonenveloped double-stranded DNA virus, is usually rapidly detected from nasopharyngeal aspirates using an indirect immunofluorescence assay with monoclonal antibody. Molecular typing with PCR assay is performed to determine the species and serotype [2]. Fifty-one serotypes and over 70 genotypes classified into seven species (A–G) have been described. Species B, C, D, and E are implicated in respiratory infections [1]. There is a higher prevalence of species B serotypes 7 and 3

HAdV in lower respiratory tract infection. These serotypes are also associated with more severe respiratory outcomes, higher mortality rates, more long-term sequelae, and a higher intensive care unit admission requirement rate [1]. Only a few cases have described adenovirus-associated HS but mostly in immunodeficient individuals. We have found only one published case of a non-immunodeficient 15-month-old infant admitted for pneumonia with acute respiratory distress syndrome and macrophage activation syndrome [3]. The PCR assay identified species B serotype 7 HAdV, but unlike our case, long-term sequelae were less severe, with bronchiectasis but no BO or oxygen support.

Bronchiectasis and BO are the classical long-term sequelae of serotype 3 or 7 HAdV infection. Persistent HAdV infection may indeed elicit chronic neutrophilic inflammation within the airways, protracted bacterial bronchitis, and bronchiectasis.

BO is a chronic obstruction of the airflow associated with inflammatory lesions of the small airways. BO is diagnosed according to clinical symptoms (tachypnea, increased anteroposterior chest diameter, crackles, wheezing, and hypoxemia for at least 30 days after the initial injury), by exclusion of the main differential diagnoses and with complementary tests. Chest CT with images obtained during inspiration and expiration shows characteristic mosaic patterns and bronchiectasis.

BO has a number of causes, including infection, connective tissue disorders, bone marrow or lung transplantation, and severe mucocutaneous allergic disorders such as Stevens-Johnson syndrome, and the inhalation of toxic substances. BO following a severe infectious lung disease is the most common form reported in children [4].

Colom et al. showed in a case–control study that HAdV infection and the need for mechanical ventilation are strong independent risk factors for developing

postinfectious BO in children under 3 years of age. Moreover, in the postinfectious BO patients tested, HAdV was detected in 72% of cases [5].

A retrospective observational study including 415 children under 6 years of age with acute lower respiratory tract infection caused by HAdV and no past medical history showed that 36% developed sequelae such as BO in 78% of these patients and bronchiectasis without BO in 22% of them. Oxygen supplementation after discharge was required for a median period of 33 months; 15% died, 16% of them due to progressive respiratory failure [2].

The risk factors of respiratory complications are young age at the time of pneumonia, coinfection with measles (before vaccination emergence), and low respiratory tract infection. A family history of atopy or smoking are not considered to be among the risk factors. Factors predisposing to BO are length of hospitalization (more than 30 days), multifocal pneumonia, and hypercapnia. There are the same risk factors for death as for BO as well as respiratory mechanical assistance needs, coagulation disorders, neurological symptoms, and coinfection with measles [2]. Our patient had every risk factor predisposing to BO, but, to our knowledge, the association of bronchiectasis and BO has not yet been reported.

Although the recommendations are clear on treatment of HAdV infection with immunodeficient patients [6], there are no guidelines regarding antiviral treatment in immunocompetent children. Yet a retrospective study reporting seven immunocompetent young adults with severe HAdV pneumonia who had received early cidofovir administration showed clinical and radiological improvement after a median of 12 and 21 days, respectively [7]. The potential nephrotoxicity of cidofovir means that it has limited use in pediatric patients. A study on 16 immunodeficient

children who received cidofovir for HAdV infection showed an average 50% increase of serum creatinine from their baseline, but renal dysfunction was transient in the majority of the patients [6]. Therefore, cidofovir could be proposed to immunocompetent children with severe clinical adenovirus lower respiratory tract infection who have risk factors predisposing to BO. The use of cidofovir in our case was motivated by clinical severity and the very high viral load. The viral load was then monitored, and treatment was stopped when the viral load turned negative.

4. CONCLUSION

Severe damage can result from HAdV lower respiratory tract infection even with immunocompetent children. There are higher risks of chronic respiratory disease with serotypes 3 and 7. It could be useful to discuss the indication of systematic antiviral treatment for those infections in immunocompetent children when they have severe clinical presentation and high viral load.

REFERENCES

1. Chehadeh W, Al-Adwani A, John SE, et al. Adenovirus types associated with severe respiratory diseases: A retrospective 4-year study in Kuwait. *J Med Virol* 2018;90:1033-9.
2. Murtagh P, Giubergia V, Viale D, et al. Lower respiratory infections by adenovirus in children. Clinical features and risk factors for bronchiolitis obliterans and mortality. *Pediatr Pulmonol* 2009;44:450-6.
3. Odièvre MH, Daněková N, Picard C, et al. Pneumopathie hypoxémiante à

adénovirus de type 7 chez un nourrisson sans déficit immunitaire. Arch Pédiatr 2011;18:772-7

4. Colom AJ, Maffey A, Bournissen FG, et al. Pulmonary function of a paediatric cohort of patients with postinfectious bronchiolitis obliterans. A long term follow-up. Thorax 2015;70:169- 74.
5. Colom AJ, Teper AM, Vollmer WM, et al. Risk factors for the development of bronchiolitis obliterans in children with bronchiolitis. Thorax 2006; 61:503-6.
6. Ganapathi L, Arnold A, Jones S, et al. Use of cidofovir in pediatric patients with adenovirus infection. Version 2. F1000Res 2016;5:758.
7. Kim SJ, Kim K, Park SB, et al. Outcomes of early administration of cidofovir in non-immunocompromised patients with severe adenovirus pneumonia. PLoS One 2015;10: e0122642.

Figures:

Figure 1. Chest x-ray at admission

Perihilar infiltration and middle lobe pneumonia

Figure 2. Chest x-ray at day 10

Respiratory deterioration with right upper lobe atelectasis

Figure 3. Chest CT in February 2018

Upper- and lower-lobe bronchiectasis

Figure 4. Chest CT in February 2018. Bronchiolitis obliterans

Mosaic-like images for bronchiolitis obliterans

Figure 1.

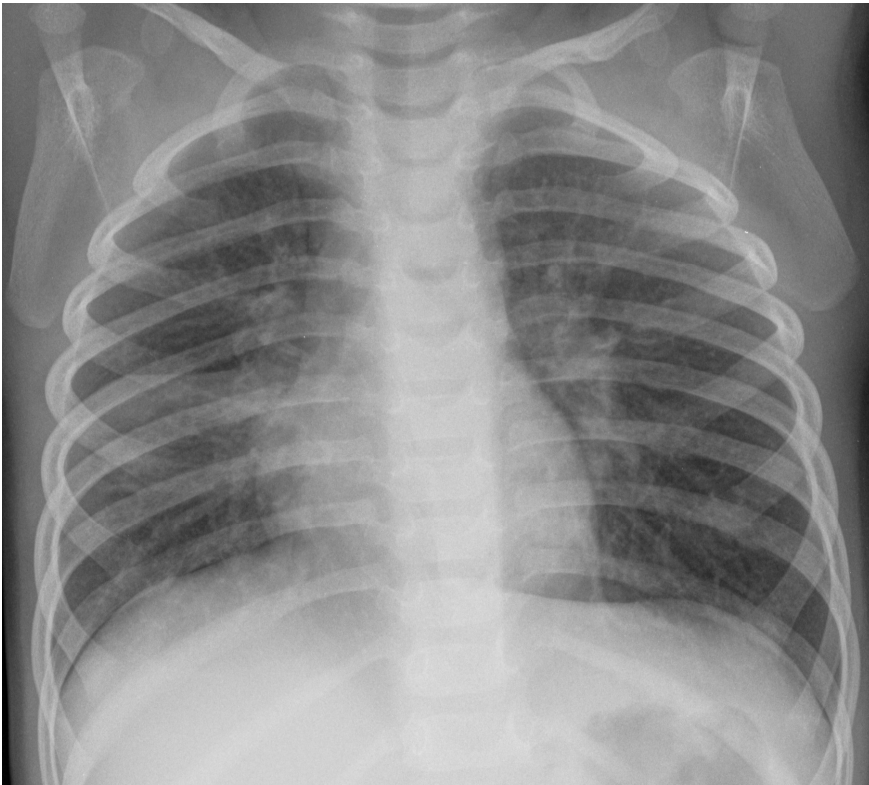


Figure 2.

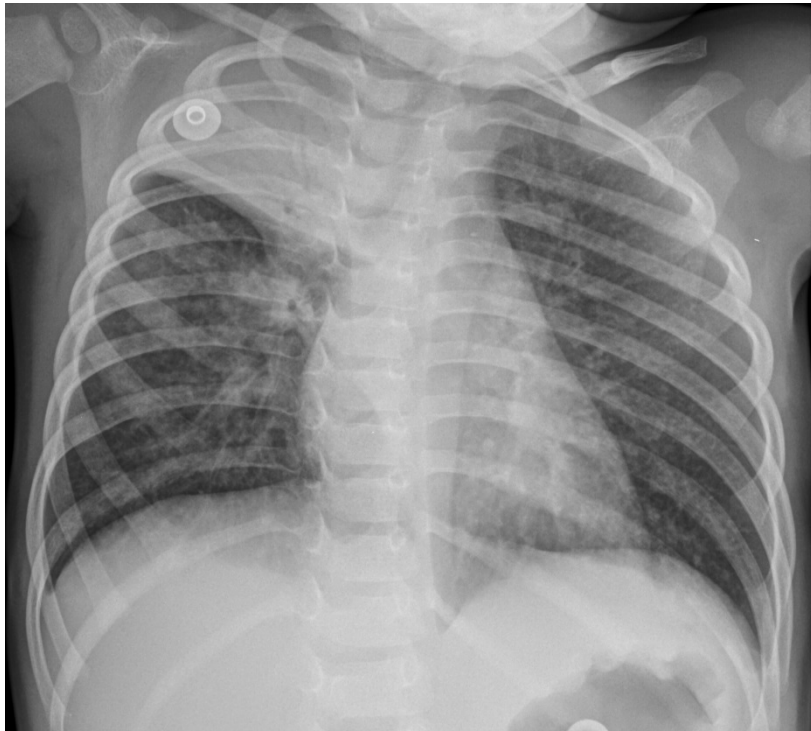


Figure 3:

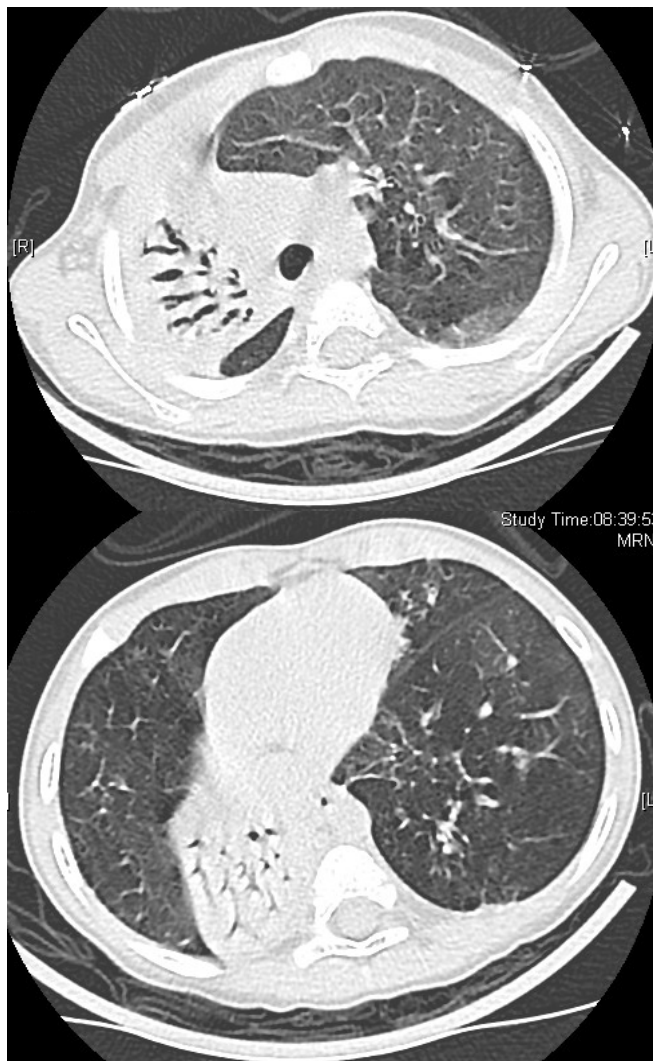

Figure 4 :

