



HAL
open science

Autochthonous human and animal leptospirosis, Marseille, France

Pablo Sanchez Fernandez, Angeli Kodjo, Hacene Medkour, Younes Laidoudi,
Gregory Dubourg, Carole Eldin, Philippe Parola, Bernard Davoust,
Jean-Christophe J.-C. Lagier

► **To cite this version:**

Pablo Sanchez Fernandez, Angeli Kodjo, Hacene Medkour, Younes Laidoudi, Gregory Dubourg, et al.. Autochthonous human and animal leptospirosis, Marseille, France. IDCASES, 2020, 21, 10.1016/j.idcr.2020.e00899 . hal-03150175

HAL Id: hal-03150175

<https://amu.hal.science/hal-03150175v1>

Submitted on 18 Jul 2022

HAL is a multi-disciplinary open access archive for the deposit and dissemination of scientific research documents, whether they are published or not. The documents may come from teaching and research institutions in France or abroad, or from public or private research centers.

L'archive ouverte pluridisciplinaire **HAL**, est destinée au dépôt et à la diffusion de documents scientifiques de niveau recherche, publiés ou non, émanant des établissements d'enseignement et de recherche français ou étrangers, des laboratoires publics ou privés.



Distributed under a Creative Commons Attribution - NonCommercial 4.0 International License

1 **IDCases**

2 **Case report**

3

4 **Autochthonous human and animal leptospirosis, Marseille, France**

5 Pablo Sanchez Fernandez^a, Angeli Kodjo^b, Hacène Medkour^{a, c}, Younes Laidoudi^{a, c},

6 Grégory Dubourg^{a, c}, Carole Eldin^{c,d}, Philippe Parola^{c,d}, Bernard Davoust^{a,c*}, Jean-

7 Christophe Lagier^{a,c}

8

9 ^a Aix Marseille Univ, IRD, AP-HM, MEPHI, Marseille, France

10 ^b Leptospirosis Laboratory, VetAgro Sup, Veterinary Campus of Lyon, Marcy l'Etoile,

11 France

12 ^c IHU Méditerranée Infection, Marseille, France

13 ^d Aix Marseille Univ, IRD, AP-HM, SSA, VITROME, Marseille, France

14 *Corresponding author

15 Email: bernard.davoust@gmail.com (B. Davoust)

16 Tel: (33) 413 73 24 01

17 Fax: (33) 413 73 24 02

18

19 Running title: Autochthonous leptospirosis, France

20 Keywords: France, Leptospirosis, *Leptospira interrogans*, *Rattus norvegicus*, Zoonosis

21

22 **ABSTRACT**

23 Autochthonous leptospirosis is an emerging zoonotic disease in Europe, particularly in France.

24 **We report a case** of leptospirosis in a 36 year-old man, who is a recently **arrived migrant from**

25 **Tunisia** and lives in a squat. He suffered from pulmonary and neurological involvement as

26 well as hepatitis. Seven rats (*Rattus norvegicus*) were trapped in the squat where the patient

27 lived. *Leptospira* spp. DNA was detected in the kidney of one rat, highlighting the most likely

28 source of contamination. **In addition to** the classic recreational or professional exposure to

29 fresh water and practice of outdoor sports as a source of leptospirosis contamination,

30 unhealthy living conditions (homeless or squatting) and therefore frequent exposure to rats,

31 are another risk factor for leptospirosis in Europe.

32

33 **Introduction**

34 Leptospirosis is an endemic zoonosis worldwide with a million cases per year, including

35 500,000 severe cases, and a mortality of around 60,000 cases per year (1). This infectious

36 disease is mainly encountered in South America, the Caribbean, South Asia and Oceania,

37 favored by the tropical climate, stagnant waters and floods, as well as precariousness in urban

38 areas (1). **Severe forms of human leptospirosis** are mainly associated with the serovar

39 Icterohaemorrhagiae present in *Rattus norvegicus* (2, 3). In France, the incidence of all forms
40 of leptospirosis is one of the highest in Europe with an increase in the number of cases since
41 2014, i.e. 600 cases per year with an incidence of 1 case per 100,000 inhabitants (4).
42 Nevertheless, most of the cases (85%) are imported (4). Here, we report the clinical case of a
43 patient suffering from autochthonous leptospirosis in Marseille, France, as well as the
44 epidemiological survey of this patient living in a squat.

45

46 Case report

47 In 2018, during the winter season in December, a 36-year-old man was admitted in infectious
48 diseases ward in Marseille (France) with fever, cough with hemoptysis, headache, stiff neck
49 and photophobia, arthralgia, myalgia and jaundice. The symptoms were present for five days
50 ago. This man was born in Tunisia and arrived in France three months ago. He left with his
51 two children and wife in unsanitary conditions in a squat with presence of rat's infestation.
52 Upon arrival to the emergency department, the patient had fever at 38.5°C and dyspnea
53 (respiratory rate 28/min) with cough and hemoptysis. He also presented meningismus
54 syndrome with headache, neck stiffness, photophobia, phonophobia and scleral icterus. His
55 main complaint was diffuse body pain with severe myalgia, especially his involving calves.
56 Laboratory revealed an inflammatory syndrome with white blood cells at 18 giga/L, hepatic
57 dysfunction (AST: 70 UI/L, ALT: 105 IU/L), jaundice (Total bilirubin: 54 µmol/L,
58 conjugated bilirubin: 44 µmol/L,) and acute kidney injury (creatinin 16 µmol/L). A chest and
59 CT scan showed bilateral interstitial infiltrates (Fig. 1). A lumbar puncture was performed and
60 revealed liquid that looks like rock water with hypercellularity (lymphocyte count at: 100
61 cells/mm³, including 80% mononuclear cells); glucose was 2.10 mmol/L and proteins were
62 0.67 g/L. Cerebrospinal fluid (CSF) cultures were sterile. Treatment with ceftriaxone 100

63 mg/kg every 12 hours daily and acyclovir 15 mg/kg every 8 hours was empirically initiated.

64 After negative Herpes virus specific PCR, acyclovir was stopped and ceftriaxone was

65 continued alone. Leptospirosis specific PCR targeting the 16S rRNA gene (6) was performed

66 as from blood and urine and was found to be positive while detection was negative from CSF.

67 In addition, the serology performed with a commercially available ELISA kit for both IgG

68 and IgM (Institut Virion Serion GmbH, Warburg, Germany) showed positive IgM. The

69 microscopic agglutination test (MAT) performed on serum was positive antibody titers for

70 *Leptospira interrogans* Icterohaemorrhagiae Copenhageni (1/640), Bratislava (1/10) and

71 Serjoe (1/160). Two and a half months later, the patient's serum was positive for Copenhageni

72 (1/640), Icterohaemorrhagiae (1/160) and Serjoe (1/80). The patient received seven day of

73 ceftriaxone resulting clinical improvement and discharge from hospital. He had complete

74 clinical recovery one month post hospitalization. Interrogation of the patient showed that he

75 lived with his family on the ground floor of a building. He had observed rat infestation

76 outside his front door. Five weeks post hospitalization, an epidemiological veterinary

77 investigation was conducted at the patient's home. Trapping was performed for four

78 consecutive nights along the vicinity of a river and seven rats (*Rattus norvegicus*) were

79 captured. After general anesthesia (ketamine) and euthanasia, the rats were autopsied.

80 Serological analyses of these rats were performed using a MAT with a dilution threshold of

81 1:10 of 23 leptospire serovars. All the rats were serologically negative. The detection of *L.*

82 *interrogans* DNA was performed according to the amplification protocol of the 16S locus of

83 ribosomal DNA to which duplex PCR, amplification of the secY locus was added (5, 6). PCR

84 was positive on the kidneys of one rat. Sequencing was not possible. All liver, lungs and urine

85 samples were negative.

86

87 Discussion

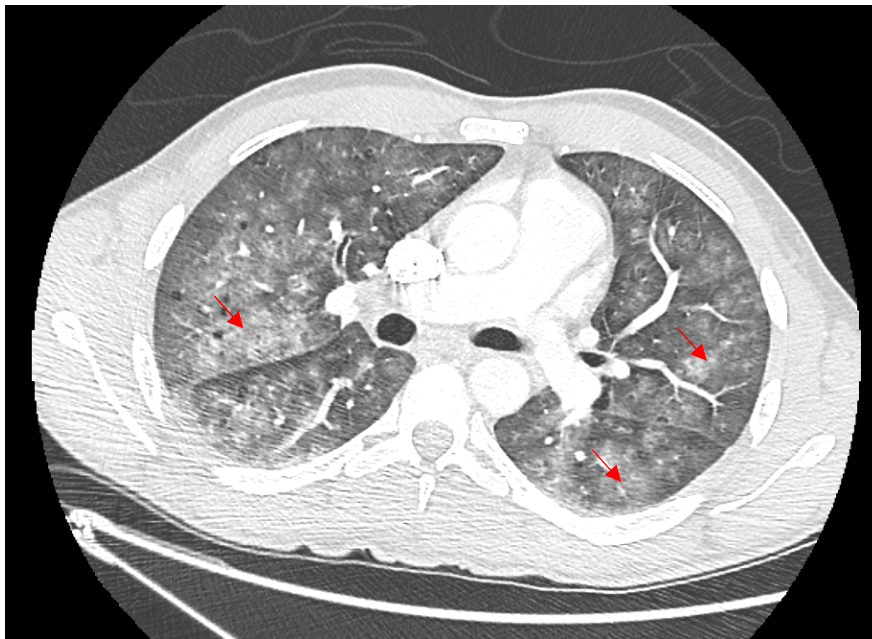
88 We report a case of autochthonous human leptospirosis in Marseille (France) assessed by a
89 veterinary survey exploring the source of contamination. We detected Leptospiral DNA in the
90 kidney of one rat surrounding the housing of the patient, suggesting that it could be a possible
91 source of contamination. We used a validated PCR technique with validated positive and
92 negative controls, allowing prompt diagnosis in the patient, and DNA detection in the rat. The
93 rat with positive kidney PCR had negative serology (at 1:10), which can be explained by the
94 fact that animal reservoirs generally have immune tolerance to host strains (5). It is also
95 possible that the infection in the trapped rat had occurred recently before it seroconverted.
96 The genus *Leptospira* includes 24 species, including 10 pathogens and more than 300
97 serovars. Some mammals are likely to harbor leptospires. Nevertheless, rodents are
98 asymptomatic carriers, while dogs and livestock are susceptible animals (1, 7). Classical risks
99 factors for Leptospirosis in Europe are recreational or professional exposure to fresh water
100 and practice of outdoor sports, especially in the rivers after heavy rain (8, 9). However, urban
101 or peri-urban leptospirosis has been reemerging in Europe in recent years, with reports from
102 Italy, Greece and south of France (Marseille) (3, 7, 9, 10). France reports one of the highest
103 endemicity levels in Europe, but this is mainly due to cases from the French overseas
104 territories, with an incidence in these regions up to 10 to 100 times higher than in mainland
105 France (4). In a clinically compatible context, the association of fever, hepatitis with jaundice,
106 acute kidney injury, conjunctivitis and neurological symptoms could evoke the diagnosis. In
107 most leptospirosis human cases diagnosed in metropolitan France, the origin of leptospires is
108 unknown. They are often summer cases related to the aquatic activities (4,12). No case of
109 infection in the city among precarious people (immigrants without papers living in squats) has
110 been described in France and only few case in the USA, Japan and Portugal, in a homeless
111 person (13, 14,15,16). The proliferation of rats has already been implicated as a possible

112 reservoir and source of **transmission of leptospirosis** in Marseille France, associated with the
113 accumulation of garbage and rainfall (7). Our case is original and the associated veterinary
114 investigations, rarely highlighted in the literature, illustrate the persistence of this reservoir in
115 Marseille. This case also highlights that recent immigration and unstable housing (homeless
116 or squatting) with subsequent rat exposure is another risk factor for leptospirosis that should
117 be taken into account by the clinicians. **Our case is in addition to those already described**
118 **recently. Leptospirosis of the homeless in cities is a topical disease (17).**

119

120 **Fig. 1.** Chest Ct-Scan of the patient showing interstitial bilateral pneumonia.

121
122



123

124 **Funding source**

125 This work has benefited from the French State support, managed by ‘Agence Nationale pour
126 la Recherche’ including the ‘Programme d’Investissements d’avenir’ under the reference
127 Méditerranée Infection 10-IAHU-03. This work was supported by the Région Provence-
128 Alpes-Côte d’Azur and European funding FEDER PRIM1.

129 **Acknowledgments**

130 We thank Audrey Chapron and Sergei Castañeda for their kind cooperation.

131 **Contribution**

132 Study design: JCL, BD; Management of the patient: PS, CE, GD, JCL; Data collection: PS,
133 AK, HM, YL, GD, PP; Data analysis: PS, CE, GD, PP, BD, JCL; Writing: PS, PP, BD, JCL

134 **Conflict of interest statement**

135 None

136 **Ethical approval**

137 Not required

138 **Affiliations**

- 139 Pablo SANCHEZ FERNANDEZ, Aix Marseille Univ, IRD, AP-HM, MEPHI, IHU
140 Méditerranée Infection, Marseille, France ; sanchezpfernandez@gmail.com
- 141 Angeli KODJO, Leptospirosis Laboratory, VetAgro Sup, Veterinary Campus of Lyon, Marcy
142 l'Etoile, France; angeli.kodjo@vetagro-sup.fr
- 143 Hacène MEDKOUR, Aix Marseille Univ, IRD, AP-HM, MEPHI, IHU Méditerranée
144 Infection, Marseille, France ; hacenevet1990@yahoo.fr
- 145 Younes LAIDOUDI, Aix Marseille Univ, IRD, AP-HM, MEPHI, IHU Méditerranée
146 Infection, Marseille, France ; younes.laidoudi@yahoo.com
- 147 Grégory DUBOURG: Aix Marseille Univ, IRD, AP-HM, MEPHI, IHU Méditerranée
148 Infection, Marseille, France ; gregory.dubourg@univ-amu.fr
- 149 Carole ELDIN : Aix-Marseille Univ, IRD, AP-HM, SSA, VITROME, IHU
150 Méditerranée Infection, Marseille, France ; carole.eldin@univ-amu.fr
- 151 Philippe PAROLA : Aix-Marseille Univ, IRD, AP-HM, SSA, VITROME, IHU
152 Méditerranée Infection, Marseille, France ; philippe.parola@univ-amu.fr
- 153 Bernard DAVOUST: Aix Marseille Univ, IRD, AP-HM, MEPHI, IHU Méditerranée
154 Infection, Marseille, France ; bernard.davoust@gmail.com
- 155 Jean-Christophe LAGIER: Aix Marseille Univ, IRD, AP-HM, MEPHI, IHU Méditerranée
156 Infection, Marseille, France ; jclagier@yahoo.fr

157 **References**

158

159

1. Levett PN. Leptospirosis. Clin Microbiol Rev 2001;14(2):296-326.

160

2. Dupouey J, Faucher B, Edouard S, Richet H, Kodjo A, Drancourt M, et al. Human

161

leptospirosis: an emerging risk in Europe? Comp Immunol Microbiol Infect Dis

162

2014;37(2):77-83.

163

3. Dupouey J, Faucher B, Edouard S, Richet H, de Broucker C-A, Marié J-L, et al.

164

Epidemiological investigation of a human leptospirosis case reported in a suburban area

165

near Marseille. New Microbes New Infect 2014;2(3):82-3.

166

4. Bourhy P, Septfonds A, Picardeau M. Diagnostic, surveillance et épidémiologie de la

167

leptospirose en France. Bull Epidémiol Hebd 2017;(8-9):131-7.

168

http://invs.santepubliquefrance.fr/beh/2017/8-9/2017_8-9_1.html

169

5. Morel AS, Dubourg G, Prudent E, Edouard S, Gouriet F, Casalta JP, et al.

170

Complementarity between targeted real-time specific PCR and conventional broad-range

171

16S rDNA PCR in the syndrome-driven diagnosis of infectious diseases. Eur J Clin

172

Microbiol Infect Dis 2015;34(3):561-70.

173

6. Mérien F, Amouriaux P, Perolat P, Baranton G, Saint Girons I. Polymerase chain reaction

174

for detection of *Leptospira* spp. in clinical samples. J Clin Microbiol 1992;30(9):2219-24.

175

7. Socolovschi C, Angelakis E, Renvoisé A, Fournier P-E, Marié JL, Davoust B, et al.

176

Strikes, flooding, rats, and leptospirosis in Marseille, France. Int J Infect Dis

177

2011;15(10):e710-715.

178

8. Matsushita N, Ng CFS, Kim Y, Suzuki M, Saito N, Ariyoshi K, et al. The non-linear and

179

lagged short-term relationship between rainfall and leptospirosis and the intermediate role of

180

floods in the Philippines. PLoS Negl Trop Dis 2018;12(4):e0006331.

181

- 182
- 183 9. Vitale M, Agnello S, Chetta M, Amato B, Vitale G, Bella CD, et al. Human leptospirosis
184 cases in Palermo Italy. The role of rodents and climate. J Infect Public Health
185 2018;11(2):209-14.
- 186 10. Panagopoulos P, Ganitis A, Papanas N, Iosifidou G, Maltsan T, Kioutsouk S, et al.
187 Leptospirosis: a report on a series of five autochthonous cases in a Greek region. J
188 Chemother 2016;28(5):428-31.
- 189 11. Koizumi N, Muto M, Tanikawa T, Mizutani H, Sohmura Y, Hayashi E, et al. Human
190 leptospirosis cases and the prevalence of rats harbouring *Leptospira interrogans* in urban
191 areas of Tokyo, Japan. J Med Microbiol 2009;58(9):1227-30.
- 192 12. Brockmann S, Piechotowski I, Bock-Hensley O, Winter C, Oehme R, Zimmermann S, et
193 al. Outbreak of leptospirosis among triathlon participants in Germany, 2006. BMC Infect
194 Dis. 2010;10:91.
- 195 13. Jones S, Kim T. Fulminant leptospirosis in a patient with human immunodeficiency virus
196 infection: case report and review of the literature. Clin Infect Dis 2001;33(5):E31-3.
- 197 14. Bini Viotti J, Chan JC, Rivera C, Tuda C. Sporadic leptospirosis case in Florida
198 presenting as Weil's disease. IDCases 2019;19:e00686.
- 199 15. Kang YM, Hagiwara A, Uemura T. Leptospirosis infection in a homeless patient in
200 December in Tokyo: a case report. J Med Case Rep 2015;9:198.
- 201 16. Moreira Marques T, Nascimento PO, Almeida A, Tosatto V. Weil's disease in a young
202 homeless man living in Lisbon. BMJ Case Rep. 2020;13(6):e233543.

203 17. Hagan JE, Moraga P, Costa F, Capián N, Ribeiro GS, Wunder EA Jr. Prospective study of
204 leptospirosis transmission in an urban slum community: Role of poor environment in repeated
205 exposures to the *Leptospira* agent. PLoS Negl Trop Dis 2016;10(1):e0004275.