



Autochthonous human and animal leptospirosis, Marseille, France

Pablo Sanchez Fernandez, Angeli Kodjo, Hacene Medkour, Younes Laidoudi,
Gregory Dubourg, Carole Eldin, Philippe Parola, Bernard Davoust,
Jean-Christophe J.-C. Lagier

► To cite this version:

Pablo Sanchez Fernandez, Angeli Kodjo, Hacene Medkour, Younes Laidoudi, Gregory Dubourg, et al.. Autochthonous human and animal leptospirosis, Marseille, France. IDCASES, 2020, 21, 10.1016/j.idcr.2020.e00899 . hal-03150175

HAL Id: hal-03150175

<https://amu.hal.science/hal-03150175>

Submitted on 18 Jul 2022

HAL is a multi-disciplinary open access archive for the deposit and dissemination of scientific research documents, whether they are published or not. The documents may come from teaching and research institutions in France or abroad, or from public or private research centers.

L'archive ouverte pluridisciplinaire **HAL**, est destinée au dépôt et à la diffusion de documents scientifiques de niveau recherche, publiés ou non, émanant des établissements d'enseignement et de recherche français ou étrangers, des laboratoires publics ou privés.



Distributed under a Creative Commons Attribution - NonCommercial 4.0 International License

1 **IDCases**

2 **Case report**

3

4 **Autochthonous human and animal leptospirosis, Marseille, France**

5 Pablo Sanchez Fernandez^a, Angeli Kodjo^b, Hacène Medkour^{a, c}, Younes Laidoudi^{a, c},

6 Grégory Dubourg^{a, c}, Carole Eldin^{c,d}, Philippe Parola^{c,d}, Bernard Davoust^{a,c*}, Jean-

7 Christophe Lagier^{a,c}

8

9 ^a Aix Marseille Univ, IRD, AP-HM, MEPHI, Marseille, France

10 ^b Leptospirosis Laboratory, VetAgro Sup, Veterinary Campus of Lyon, Marcy l'Etoile,

11 France

12 ^c IHU Méditerranée Infection, Marseille, France

13 ^d Aix Marseille Univ, IRD, AP-HM, SSA, VITROME, Marseille, France

14 *Corresponding author

15 Email: bernard.davoust@gmail.com (B. Davoust)

16 Tel: (33) 413 73 24 01

17 Fax: (33) 413 73 24 02

18

19 Running title: Autochthonous leptospirosis, France

20 Keywords: France, Leptospirosis, *Leptospira interrogans*, *Rattus norvegicus*, Zoonosis

21

22 **ABSTRACT**

23 Autochthonous leptospirosis is an emerging zoonotic disease in Europe, particularly in France.
24 **We report a case** of leptospirosis in a 36 year-old man, who is a recently **arrived migrant from**
25 **Tunisia** and lives in a squat. He suffered from pulmonary and neurological involvement as
26 well as hepatitis. Seven rats (*Rattus norvegicus*) were trapped in the squat where the patient
27 lived. *Leptospira* spp. DNA was detected in the kidney of one rat, highlighting the most likely
28 source of contamination. **In addition to** the classic recreational or professional exposure to
29 fresh water and practice of outdoor sports as a source of leptospirosis contamination,
30 unhealthy living conditions (homeless or squatting) and therefore frequent exposure to rats,
31 are another risk factor for leptospirosis in Europe.

32

33 **Introduction**

34 Leptospirosis is an endemic zoonosis worldwide with a million cases per year, including
35 500,000 severe cases, and a mortality of around 60,000 cases per year (1). This infectious
36 disease is mainly encountered in South America, the Caribbean, South Asia and Oceania,
37 favored by the tropical climate, stagnant waters and floods, as well as precariousness in urban
38 areas (1). **Severe forms of human leptospirosis** are mainly associated with the serovar

Icterohaemorrhagiae present in *Rattus norvegicus* (2, 3). In France, the incidence of all forms of leptospirosis is one of the highest in Europe with an increase in the number of cases since 2014, i.e. 600 cases per year with an incidence of 1 case per 100,000 inhabitants (4). Nevertheless, most of the cases (85%) are imported (4). Here, we report the clinical case of a patient suffering from autochthonous leptospirosis in Marseille, France, as well as the epidemiological survey of this patient living in a squat.

Case report

In 2018, during the winter season in December, a 36-year-old man was admitted in infectious diseases ward in Marseille (France) with fever, cough with hemoptysis, headache, stiff neck and photophobia, arthralgia, myalgia and jaundice. The symptoms were present for five days ago. This man was born in Tunisia and arrived in France three months ago. He left with his two children and wife in unsanitary conditions in a squat with presence of rat's infestation. Upon arrival to the emergency department, the patient had fever at 38.5°C and dyspnea (respiratory rate 28/min) with cough and hemoptysis. He also presented meningismus syndrome with headache, neck stiffness, photophobia, phonophobia and scleral icterus. His main complaint was diffuse body pain with severe myalgia, especially his involving calves. Laboratory revealed an inflammatory syndrome with white blood cells at 18 giga/L, hepatic dysfunction (AST: 70 UI/L, ALT: 105 IU/L), jaundice (Total bilirubin: 54 µmol/L, conjugated bilirubin: 44 µmol/L,) and acute kidney injury (creatinin 16 µmol/L). A chest and CT scan showed bilateral interstitial infiltrates (Fig. 1). A lumbar puncture was performed and revealed liquid that looks like rock water with hypercellularity (lymphocyte count at: 100 cells/mm³, including 80% mononuclear cells); glucose was 2.10 mmol/L and proteins were 0.67 g/L. Cerebrospinal fluid (CSF) cultures were sterile. Treatment with ceftriaxone 100

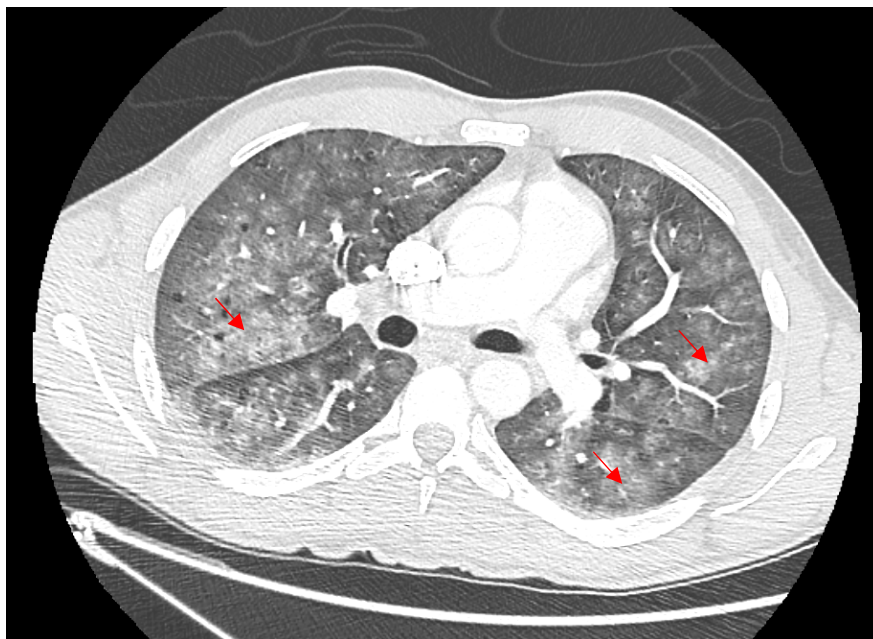
mg/kg every 12 hours daily and acyclovir 15 mg/kg every 8 hours was empirically initiated. After negative Herpes virus specific PCR, acyclovir was stopped and ceftriaxone was continued alone. Leptospirosis specific PCR targeting the 16S rRNA gene (6) was performed as from blood and urine and was found to be positive while detection was negative from CSF. In addition, the serology performed with a commercially available ELISA kit for both IgG and IgM (Institut Virion Serion GmbH, Warburg, Germany) showed positive IgM. The microscopic agglutination test (MAT) performed on serum was positive antibody titers for *Leptospira interrogans* Icterohaemorrhagiae Copenhageni (1/640), Bratislava (1/10) and Serjoe (1/160). Two and a half months later, the patient's serum was positive for Copenhageni (1/640), Icterohaemorrhagiae (1/160) and Serjoe (1/80). The patient received seven day of ceftriaxone resulting clinical improvement and discharge from hospital. He had complete clinical recovery one month post hospitalization. Interrogation of the patient showed that he lived with his family on the ground floor of a building. He had observed rat infestation outside his front door. Five weeks post hospitalization, an epidemiological veterinary investigation was conducted at the patient's home. Trapping was performed for four consecutive nights along the vicinity of a river and seven rats (*Rattus norvegicus*) were captured. After general anesthesia (ketamine) and euthanasia, the rats were autopsied. Serological analyses of these rats were performed using a MAT with a dilution threshold of 1:10 of 23 leptospire serovars. All the rats were serologically negative. The detection of *L. interrogans* DNA was performed according to the amplification protocol of the 16S locus of ribosomal DNA to which duplex PCR, amplification of the secY locus was added (5, 6). PCR was positive on the kidneys of one rat. Sequencing was not possible. All liver, lungs and urine samples were negative.

Discussion

We report a case of autochthonous human leptospirosis in Marseille (France) assessed by a veterinary survey exploring the source of contamination. We detected Leptospiral DNA in the kidney of one rat surrounding the housing of the patient, suggesting that it could be a possible source of contamination. We used a validated PCR technique with validated positive and negative controls, allowing prompt diagnosis in the patient, and DNA detection in the rat. The rat with positive kidney PCR had negative serology (at 1:10), which can be explained by the fact that animal reservoirs generally have immune tolerance to host strains (5). It is also possible that the infection in the trapped rat had occurred recently before it seroconverted. The genus *Leptospira* includes 24 species, including 10 pathogens and more than 300 serovars. Some mammals are likely to harbor leptospires. Nevertheless, rodents are asymptomatic carriers, while dogs and livestock are susceptible animals (1, 7). Classical risk factors for Leptospirosis in Europe are recreational or professional exposure to fresh water and practice of outdoor sports, especially in the rivers after heavy rain (8, 9). However, urban or peri-urban leptospirosis has been reemerging in Europe in recent years, with reports from Italy, Greece and south of France (Marseille) (3, 7, 9, 10). France reports one of the highest endemicity levels in Europe, but this is mainly due to cases from the French overseas territories, with an incidence in these regions up to 10 to 100 times higher than in mainland France (4). In a clinically compatible context, the association of fever, hepatitis with jaundice, acute kidney injury, conjunctivitis and neurological symptoms should evoke the diagnosis. In most leptospirosis human cases diagnosed in metropolitan France, the origin of leptospires is unknown. They are often summer cases related to the aquatic activities (4,12). No case of infection in the city among precarious people (immigrants without papers living in squats) has been described in France and only few cases in the USA, Japan and Portugal, in a homeless person (13, 14,15,16). The proliferation of rats has already been implicated as a possible

reservoir and source of **transmission of leptospirosis** in Marseille France, associated with the accumulation of garbage and rainfall (7). Our case is original and the associated veterinary investigations, rarely highlighted in the literature, illustrate the persistence of this reservoir in Marseille. This case also highlights that recent immigration and unstable housing (homeless or squatting) with subsequent rat exposure is another risk factor for leptospirosis that should be taken into account by the clinicians. **Our case is in addition to those already described recently. Leptospirosis of the homeless in cities is a topical disease (17).**

Fig. 1. Chest Ct-Scan of the patient showing interstitial bilateral pneumonia.



124 **Funding source**

125 This work has benefited from the French State support, managed by ‘Agence Nationale pour
126 la Recherche’ including the ‘Programme d’Investissements d’avenir’ under the reference
127 Méditerranée Infection 10-IAHU-03. This work was supported by the Région Provence-
128 Alpes-Côte d’Azur and European funding FEDER PRIM1.

129 **Acknowledgments**

130 We thank Audrey Chapron and Sergei Castañeda for their kind cooperation.

131 **Contribution**

132 Study design: JCL, BD; Management of the patient: PS, CE, GD, JCL; Data collection: PS,
133 AK, HM, YL, GD, PP; Data analysis: PS, CE, GD, PP, BD, JCL; Writing: PS, PP, BD, JCL

134 **Conflict of interest statement**

135 None

136 **Ethical approval**

137 Not required

138 **Affiliations**

- 139 Pablo SANCHEZ FERNANDEZ, Aix Marseille Univ, IRD, AP-HM, MEPHI, IHU
140 Méditerranée Infection, Marseille, France ; sanchezpfernandez@gmail.com
- 141 Angeli KODJO, Leptospirosis Laboratory, VetAgro Sup, Veterinary Campus of Lyon, Marcy
142 l'Etoile, France; angeli.kodjo@vetagro-sup.fr
- 143 Hacène MEDKOUR, Aix Marseille Univ, IRD, AP-HM, MEPHI, IHU Méditerranée
144 Infection, Marseille, France ; hacenevet1990@yahoo.fr
- 145 Younes LAIDOUDI, Aix Marseille Univ, IRD, AP-HM, MEPHI, IHU Méditerranée
146 Infection, Marseille, France ; younes.laidoudi@yahoo.com
- 147 Grégory DUBOURG: Aix Marseille Univ, IRD, AP-HM, MEPHI, IHU Méditerranée
148 Infection, Marseille, France ; gregory.dubourg@univ-amu.fr
- 149 Carole ELDIN : Aix-Marseille Univ, IRD, AP-HM, SSA, VITROME, IHU
150 Méditerranée Infection, Marseille, France ; carole.eldin@univ-amu.fr
- 151 Philippe PAROLA : Aix-Marseille Univ, IRD, AP-HM, SSA, VITROME, IHU
152 Méditerranée Infection, Marseille, France ; philippe.parola@univ-amu.fr
- 153 Bernard DAVOUST: Aix Marseille Univ, IRD, AP-HM, MEPHI, IHU Méditerranée
154 Infection, Marseille, France ; bernard.davoust@gmail.com
- 155 Jean-Christophe LAGIER: Aix Marseille Univ, IRD, AP-HM, MEPHI, IHU Méditerranée
156 Infection, Marseille, France ; jclagier@yahoo.fr

References

1. Levett PN. Leptospirosis. Clin Microbiol Rev 2001;14(2):296-326.
2. Dupouey J, Faucher B, Edouard S, Richet H, Kodjo A, Drancourt M, et al. Human leptospirosis: an emerging risk in Europe? Comp Immunol Microbiol Infect Dis 2014;37(2):77-83.
3. Dupouey J, Faucher B, Edouard S, Richet H, de Broucker C-A, Marié J-L, et al. Epidemiological investigation of a human leptospirosis case reported in a suburban area near Marseille. New Microbes New Infect 2014;2(3):82-3.
4. Bourhy P, Septfons A, Picardeau M. Diagnostic, surveillance et épidémiologie de la leptospirose en France. Bull Epidémiol Hebd 2017;(8-9):131-7.
http://invs.santepubliquefrance.fr/beh/2017/8-9/2017_8-9_1.html
5. Morel AS, Dubourg G, Prudent E, Edouard S, Gouriet F, Casalta JP, et al. Complementarity between targeted real-time specific PCR and conventional broad-range 16S rDNA PCR in the syndrome-driven diagnosis of infectious diseases. Eur J Clin Microbiol Infect Dis 2015;34(3):561-70.
6. Mérien F, Amouriaux P, Perolat P, Baranton G, Saint Girons I. Polymerase chain reaction for detection of *Leptospira* spp. in clinical samples. J Clin Microbiol 1992;30(9):2219-24.
7. Socolovschi C, Angelakis E, Renvoisé A, Fournier P-E, Marié JL, Davoust B, et al. Strikes, flooding, rats, and leptospirosis in Marseille, France. Int J Infect Dis 2011;15(10):e710-715.
8. Matsushita N, Ng CFS, Kim Y, Suzuki M, Saito N, Ariyoshi K, et al. The non-linear and lagged short-term relationship between rainfall and leptospirosis and the intermediate role of floods in the Philippines. PLoS Negl Trop Dis 2018;12(4):e0006331.

182

183 9. Vitale M, Agnello S, Chetta M, Amato B, Vitale G, Bella CD, et al. Human leptospirosis
184 cases in Palermo Italy. The role of rodents and climate. J Infect Public Health
185 2018;11(2):209-14.

186 10. Panagopoulos P, Ganitis A, Papanas N, Iosifidou G, Maltsan T, Kioutsouk S, et al.
187 Leptospirosis: a report on a series of five autochthonous cases in a Greek region. J
188 Chemother 2016;28(5):428-31.

189 11. Koizumi N, Muto M, Tanikawa T, Mizutani H, Sohmura Y, Hayashi E, et al. Human
190 leptospirosis cases and the prevalence of rats harbouring *Leptospira interrogans* in urban
191 areas of Tokyo, Japan. J Med Microbiol 2009;58(9):1227-30.

192 12. Brockmann S, Piechotowski I, Bock-Hensley O, Winter C, Oehme R, Zimmermann S, et
193 al. Outbreak of leptospirosis among triathlon participants in Germany, 2006. BMC Infect
194 Dis. 2010;10:91.

195 13. Jones S, Kim T. Fulminant leptospirosis in a patient with human immunodeficiency virus
196 infection: case report and review of the literature. Clin Infect Dis 2001;33(5):E31-3.

197 14. Bini Viotti J, Chan JC, Rivera C, Tuda C. Sporadic leptospirosis case in Florida
198 presenting as Weil's disease. IDCases 2019;19:e00686.

199 15. Kang YM, Hagiwara A, Uemura T. Leptospirosis infection in a homeless patient in
200 December in Tokyo: a case report. J Med Case Rep 2015;9:198.

201 16. Moreira Marques T, Nascimento PO, Almeida A, Tosatto V. Weil's disease in a young
202 homeless man living in Lisbon. BMJ Case Rep. 2020;13(6):e233543.

203 17. Hagan JE, Moraga P, Costa F, Capián N, Ribeiro GS, Wunder EA Jr. Prospective study of
204 leptospirosis transmission in an urban slum community: Role of poor environment in repeated
205 exposures to the *Leptospira* agent. PLoS Negl Trop Dis 2016;10(1):e0004275.