



HAL
open science

Acral FibroChondroMyxoid tumor: imaging features of a new entity

Thomas Le Corroller, Nicolas Macagno, Hugo Nihous, Pierre Champsaur,
Corinne Bouvier

► **To cite this version:**

Thomas Le Corroller, Nicolas Macagno, Hugo Nihous, Pierre Champsaur, Corinne Bouvier. Acral FibroChondroMyxoid tumor: imaging features of a new entity. *Skeletal Radiology*, 2020, 50 (3), pp.603-607. 10.1007/s00256-020-03592-9 . hal-03151350

HAL Id: hal-03151350

<https://amu.hal.science/hal-03151350>

Submitted on 2 Mar 2021

HAL is a multi-disciplinary open access archive for the deposit and dissemination of scientific research documents, whether they are published or not. The documents may come from teaching and research institutions in France or abroad, or from public or private research centers.

L'archive ouverte pluridisciplinaire **HAL**, est destinée au dépôt et à la diffusion de documents scientifiques de niveau recherche, publiés ou non, émanant des établissements d'enseignement et de recherche français ou étrangers, des laboratoires publics ou privés.

Acral FibroChondroMyxoid tumor: imaging features of a new entity

Thomas Le Corroller^{1,2} · Nicolas Macagno³ · Hugo Nihous³ · Pierre Champsaur^{1,2} · Corinne Bouvier³

Abstract

“Acral FibroChondroMyxoid tumor” (AFCMT) is a recently described distinctive subtype of acral soft tissue tumor that typically arises on the fingers and toes. We herein present the unreported imaging features of AFCMT in a 44-year-old woman. This otherwise healthy patient was referred for a painful, slow-growing, soft tissue mass in the middle finger of her right hand. Initial radiographs and computed tomography showed a small lesion centered in the soft tissue of the ulnar aspect of the proximal phalanx, associated with scalloping of the underlying bone. Magnetic resonance imaging confirmed the presence of a well-circumscribed soft tissue tumor that exhibited relatively high T2-weighted signal intensity and marked enhancement after contrast administration. Subsequent excisional biopsy was performed. Histologically, the tumor was characterized by an abundant stroma displaying fibrous, chondroid, and myxoid areas. By immunohistochemistry, tumor cells stained for *CD34*, *ERG*, and focally *S100* protein. RNA-sequencing allowed detection of *THBS1-ADGFR5* gene fusion which confirmed the diagnosis of AFCMT. At 2-year follow-up, the patient remains free of recurrence. AFCMT is a previously unrecognized entity that may mimic chondroma and should be considered in the differential diagnosis of soft tissue tumors with cartilaginous or myxoid stroma in the extremities.

Keywords Extremity · Tumor · Soft tissue

Introduction

“Acral FibroChondroMyxoid tumor” (AFCMT) is a recently described soft tissue tumor that occurs electively in the hands and feet and may involve the underlying bone in half of cases [1]. Histologically, this tumor presents a multinodular growth pattern composed of a proliferation of small monotonous ovoid to spindle cells. AFCMT is characterized by an abundant fibrous or chondromyxoid stroma which may account for the previous misclassification of this entity as chondroma. Immunohistochemistry is of limited help with tumor cells usually expressing *CD34*, *ERG*, *SOX 9*, and *S100*, hinting at a partial cartilaginous differentiation [1, 2]. Yet, RNA-

sequencing recently led to the identification of a recurrent *THBS1-ADGFR5* gene fusion in all cases of AFCMT allowing better delineation of this entity [1].

Thus far, the imaging features of this tumor have not been described. Here, we describe the imaging appearances, including radiography, computed tomography (CT) and magnetic resonance (MR) imaging, and histological features of AFCMT arising from the soft tissue of the proximal phalanx of the middle finger in a 44-year-old patient.

Case report

An otherwise healthy 44-year-old woman was evaluated for a slow-growing soft tissue mass present for 5 years in the middle finger of her right hand, associated with increasing pain. There was no history of trauma or prior surgery. Physical examination revealed a tender prominence just proximal to the ulnar aspect of the proximal interphalangeal (PIP) joint of the right medius. Plain radiographs showed a focal soft tissue fullness immediately medial to the proximal phalanx head of the third digit. There was associated saucerization of the underlying proximal phalanx cortex (Fig. 1). Computed

✉ Thomas Le Corroller
Thomas.LeCorroller@ap-hm.fr

¹ Radiology Department, APHM, Marseille, France

² CNRS, ISM UMR 7287, Aix Marseille University, Marseille, France

³ INSERM, MMG, APHM, CHU Timone, Department of Pathology, Aix Marseille University, Marseille, France

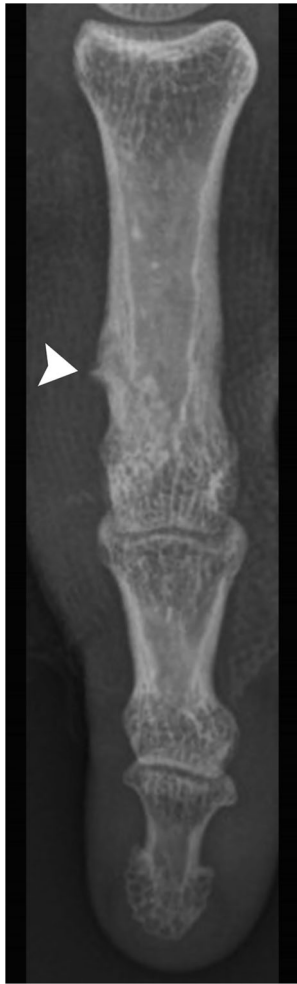

Fig. 1 Frontal radiographic view of the third digit showing a focal soft tissue fullness medial to the proximal phalanx head with saucerization of the underlying cortex and subtle cortical buttressing at the proximal aspect of the lesion (arrowhead)

tomography (CT) demonstrated a small soft tissue tumor at the ulnar aspect of the head of the proximal phalanx (Fig. 2). Subtle cortical buttressing at the proximal and dorsal aspects of the lesion indicated chronic pressure erosion. The tumor exhibited attenuation similar to that of water. There was no mineralization within the lesion. At MR imaging, the lesion exhibited intermediate signal on T1-weighted images and markedly hyperintense signal on T2-weighted images (Fig. 3). After intravenous contrast medium injection, the tumor displayed marked heterogeneous enhancement (Fig. 4). The lesion was well-circumscribed and did not extend into the PIP joint. As also seen on radiograph and CT, there was smooth scalloping of the underlying cortex of the proximal phalanx head. There was no associated perilesional bone marrow or soft tissue edema. At this point, a periosteal or soft tissue chondroma was thought likely, and the patient underwent an excisional biopsy.

Histological examination of the curettage specimens revealed a multilobulated tumor with fibrovascular septa (Fig. 5). The tumor was composed of round cells with scant eosinophilic cytoplasm arranged in small clusters or in columns within an abundant myxoid stroma. Neoplastic cells displayed round monotonous nuclei, without nucleoli. No mitosis was found. Immunohistochemistry study revealed diffuse expression of *ERG* and *CD34*, and focal expression of *PS100*, while *SOX9*, *AE1-AE3*, *EMA*, *P63*, and *smooth muscle actin alpha* were negative. *Ki67* labeling index was 2%. A provisional diagnosis of chondroma was done, and *IDH* gene mutations were searched but not found. Because the microscopic features of this tumor were unusual, the molecular study was carried on. RNA-sequencing identified a *THBS1-ADGFR5* gene fusion confirmed by RT-PCR. Finally, the histomorphologic findings combined with immunohistochemical and molecular findings led to the diagnostic of Acral FibroChondroMyxoid tumor.

The patient made complete recovery and remains free of recurrence at 2-year follow-up.

Discussion

Our case belongs to the recently published series reporting ten cases of a new mesenchymal acral tumor named Acral FibroChondroMyxoid tumor [1]. In this series, AFCMT typically arose in the hands and feet, affecting mostly the fingers and phalanges, but also sometimes the metacarpophalangeal joint of adult patients with a median age of 42 years. The tumor appeared to be more common in males, with an apparent male to female ratio of 2/1. Clinically, the tumor presented as a painless nodule of the extremity, although moderate pain was reported in a minority of cases. Although AFCMT was not associated with aggressive clinical or morphological features, the tumor involved the adjacent cortical bone in half of cases. In all patients, AFCMT was surgically treated with marginal resection. Tumor recurrence was reported in two cases of this series, likely related to incomplete primary excision. Because prior radiological work-up was not available in most cases, the imaging features of this new entity have not been described yet.

Radiologically, the tumor presented in our case as a focal soft tissue fullness adjacent to the proximal phalanx head of the third digit, with saucerization of the underlying cortical bone. CT confirmed a small, well-circumscribed mass centered in the soft tissue of the ulnar aspect of the proximal phalanx. The tumor exhibited attenuation similar to that of water. On MR imaging, the lesion was slightly hyperintense to skeletal muscle on T1-weighted images and markedly hyperintense on T2-weighted images. As previously seen on radiograph and CT, there was smooth scalloping of the underlying cortex of the proximal phalanx head, and interestingly

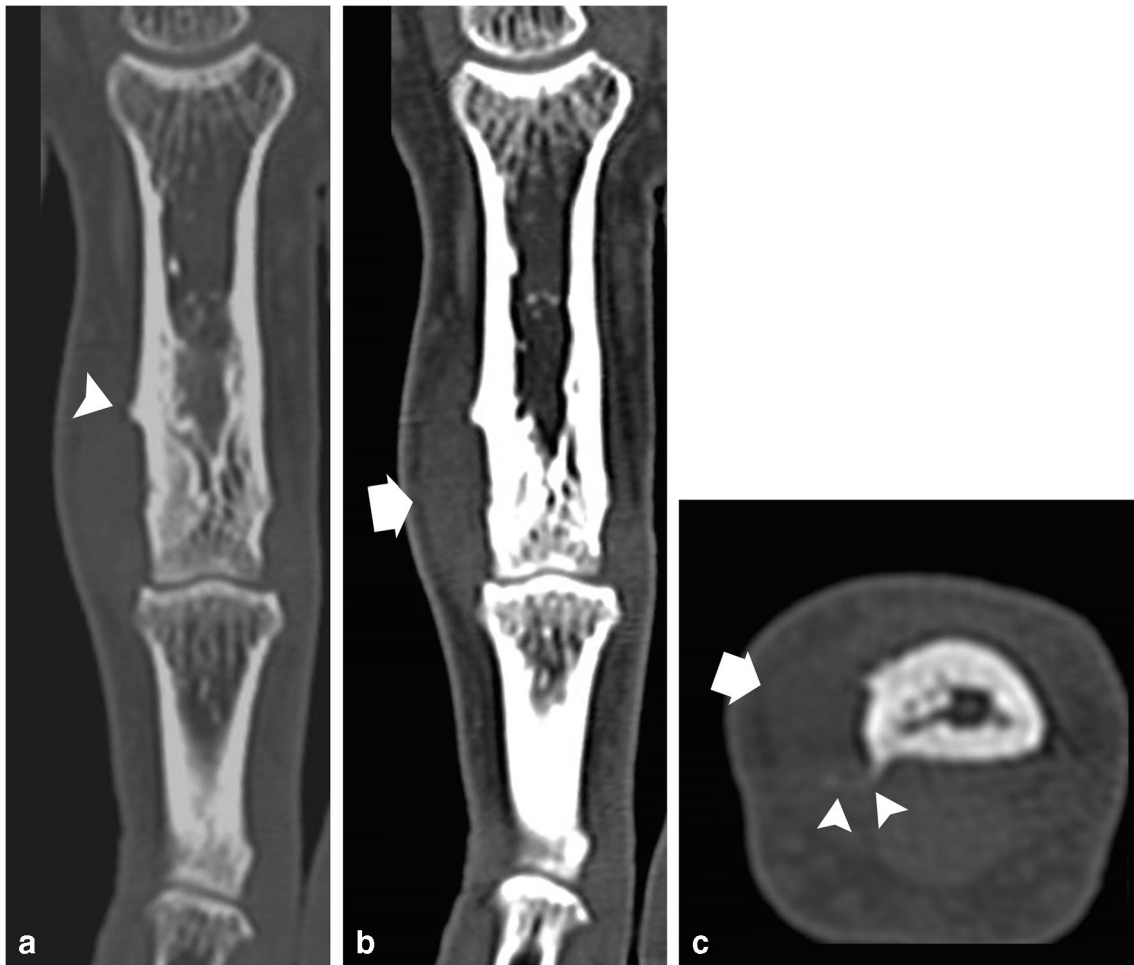


Fig. 2 Frontal (**a, b**) and axial (**c**) CT reformatted images demonstrating a small soft tissue tumor at the ulnar aspect of the head of the proximal phalanx (thick arrows) and subtle cortical buttressing from a chronic periosteal reaction at the proximal and dorsal aspects of the lesion (arrowheads)

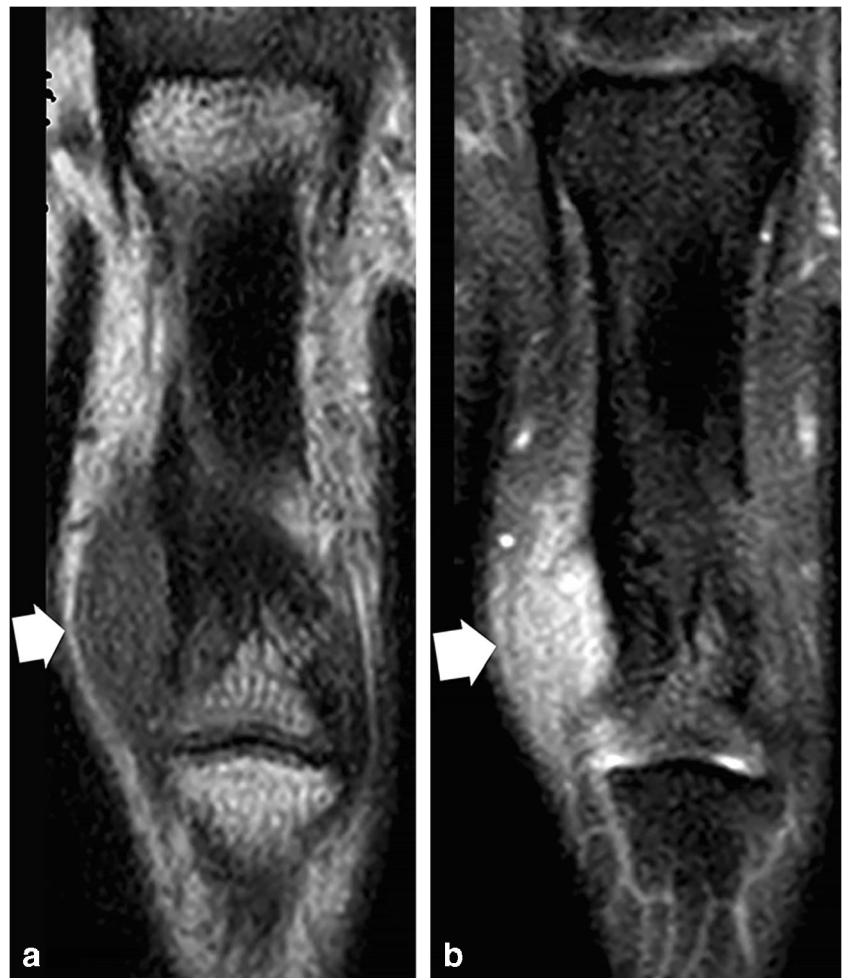
subtle cortical buttressing from a chronic pressure erosion. After intravenous contrast administration, the enhancement pattern was marked and peripheral. The tumor did not exhibit locally aggressive features. At the time of imaging, the diagnosis of juxtacortical chondroma was favored.

Radiologically, the differential diagnosis of a well-circumscribed tumor in the soft tissue of a finger with pressure erosion of the underlying bone includes periosteal chondroma, giant cell tumor of tendon sheath, glomus tumor, inclusion cyst, and periosteal ganglion [3–5]. Based on imaging, however, the major differential diagnoses in our case were matrix-rich mesenchymal tumors such as soft tissue chondroma, superficial acral fibromyxoma, and myoepithelioma [5].

Indeed, in our patient, it was difficult to determine the exact nature of the neoplasm on preoperative imaging as well as on microscopy. The advent of next-generation sequencing has enabled the identification of novel recurrent gene fusion that can help redefine the classification of many previously unclassified mesenchymal tumors. The identification of a recurrent *THBS1-ADGRF5* gene fusion in a group of acral soft tissue

tumors associated with an abundant chondromyxoid matrix allowed the description of a new distinctive subtype of acral mesenchymal tumor called Acral FibroChondroMyxoid tumor [1]. This neoplasm is characterized by a lobular pattern with fibrovascular septa, chondromyxoid stroma, and round or spindle cells, with immunophenotype that highlights a partial cartilaginous differentiation. Histologically, it has to be distinguished from periosteal or soft tissue chondroma, synovial chondromatosis, superficial acral fibromyxoma, and myoepithelial neoplasms. Periosteal and soft tissue chondromas exhibit a more hyaline cartilaginous matrix though myxoid features could focally be present. Molecular studies have respectively found *IDH* gene mutations in periosteal chondromas and *FNI* fusions in soft tissue chondromas [6, 7]. Synovial chondromatosis is characterized by mature cartilage formation and is connected to the synovium. *FNI-ACVR2A* fusions have been reported in half of cases [7]. Superficial acral fibromyxoma is made of hypocellular myxoid nodules with bland spindle cells arranged in a storiform pattern. Exceptional cases with cartilaginous

Fig. 3 Frontal T1-weighted (a) and fat-suppressed T2 (b) SE MR images showing a well-circumscribed tumor (thick arrows) at the ulnar aspect of the proximal phalanx head of the third digit that does not extend into the PIP joint or medulla



metaplasia have been reported [8, 9]. Myoepithelial soft tissue tumors are usually multinodular as AFCMT and have a variable myxoid or chondroid stroma. However, tumor cells coexpress epithelial markers and *Sox10* and/or *S100* protein, and often also present *EWSR1* or *FUS* fusions [10].

In summary, we reported the exhaustive radiographic, CT, MR imaging, and histological appearances of a case of AFCMT at the hand in a middle-aged woman. In our patient, this neoplasm exhibited overall non-specific imaging features and did not display aggressive behavior, supporting its benign

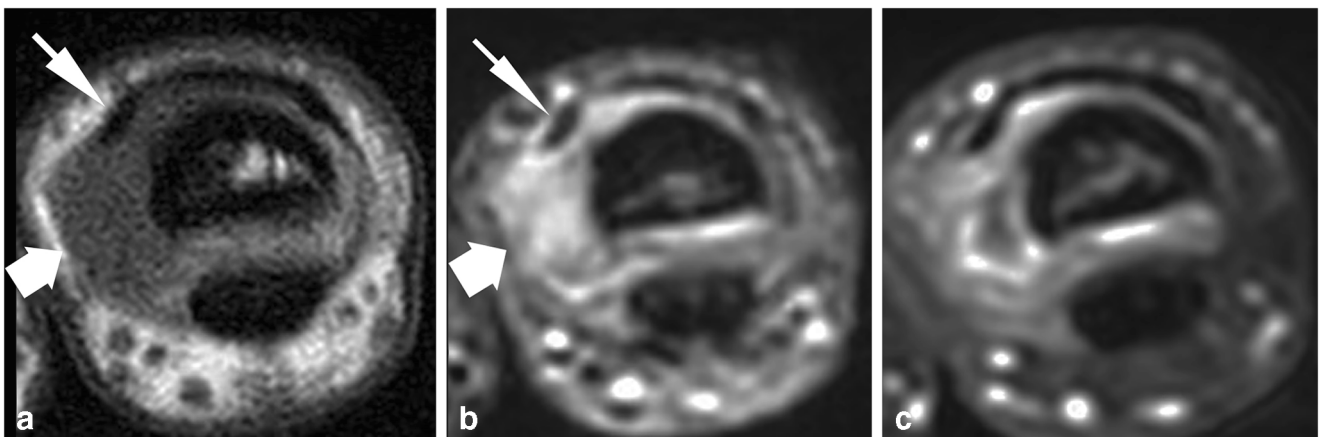


Fig. 4 Axial T1-weighted (a), fat-suppressed T2 (b), and post-contrast fat-suppressed T1 (c) SE MR images demonstrating an extension of the tumor (thick arrows) beneath the ulnar band of the extensor tendon of the

third digit (short arrows). After intravenous contrast medium injection (c), the tumor displays marked heterogeneous enhancement

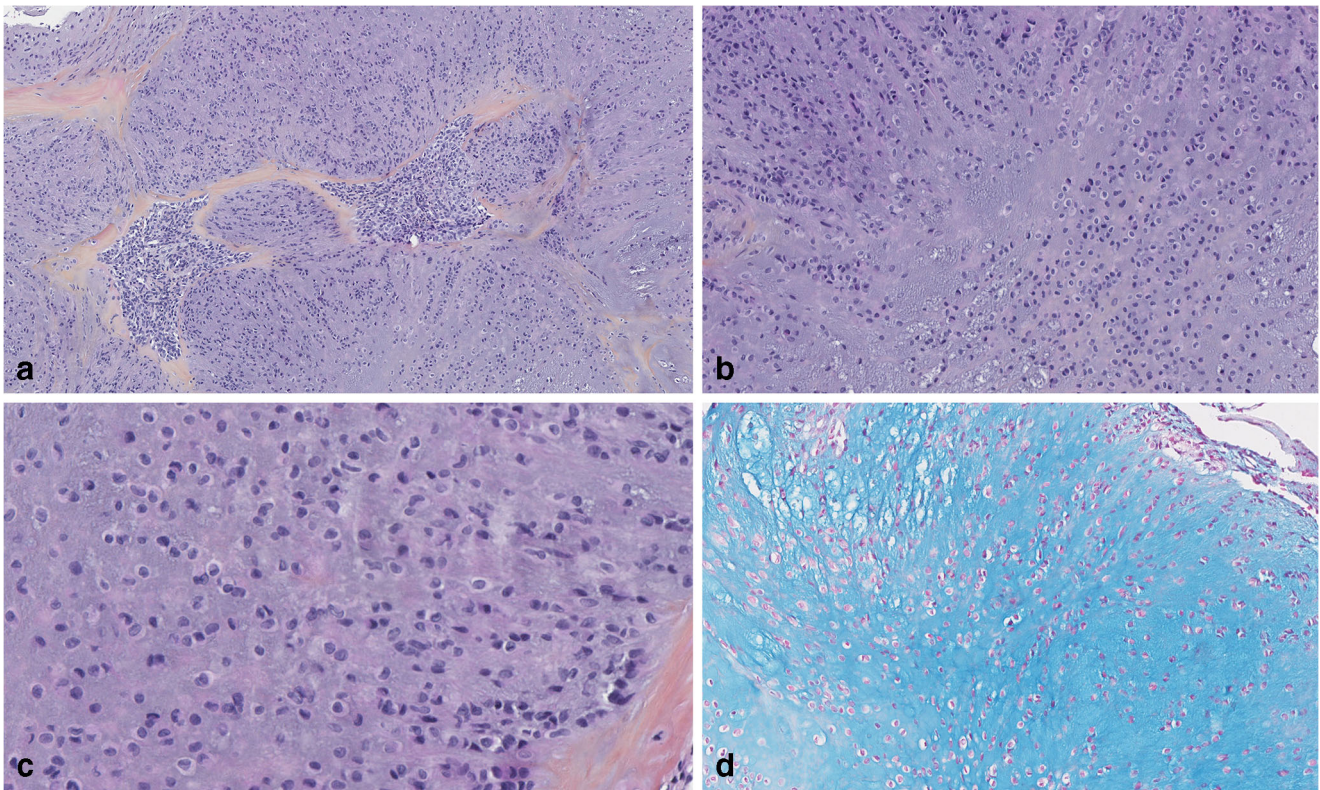


Fig. 5 Microscopic features. **a** At low power view, the tumor has a multilobular growth and is composed of myxoid lobules delineated by fibrovascular septa. **b** In the lobules neoplastic cells are arranged in

columns or clusters. **c** The cells are round with scant eosinophilic cytoplasm and round or reniform nucleus. There is no mitosis. **d** The myxoid matrix is stained with Alcian Blue

nature. AFCMT should be included in the differential diagnosis of slowly growing soft tissue lesions of the digits eroding bone.

Compliance with ethical standards

Conflict of interest The authors declare that they have no conflict of interest.

References

1. Bouvier C, Le Loarer F, Macagno N, et al. Recurrent novel THBS1-ADGRF5 gene fusion in a new tumor subtype “acral FibroChondroMyxoid tumors”. *Mod Pathol.* 2020;33:1360–8.
2. Shon W, Folpe AL, Fritchie KJ. ERG expression in chondrogenic bone and soft tissue tumours. *J Clin Pathol.* 2015;68:125–9.
3. Varikatt W, Soper J, Simmons G, Dave C, Munk J, Bonar F. Superficial acral fibromyxoma: a report of two cases with radiological findings. *Skelet Radiol.* 2008;37:499–503.
4. Douis H, Saifuddin A. The imaging of cartilaginous bone tumours. I. Benign lesions. *Skelet Radiol.* 2012;41:1195–212.
5. Kwee RM, Kwee TC. Calcified or ossified benign soft tissue lesions that may simulate malignancy. *Skelet Radiol.* 2019;48:1875–90.
6. Amary MF, Bacsı K, Maggiani F, et al. IDH1 and IDH2 mutations are frequent events in central chondrosarcomas and central and periosteal chondromas but not in other mesenchymal tumors. *J Pathol.* 2011;224:334–43.
7. Amary F, Perez-Casanova L, Ye H, et al. Synovial chondromatosis and soft tissue chondroma: extraosseous cartilaginous tumor defined by FN1 gene rearrangement. *Mod Pathol.* 2019;32:1762–71.
8. Moulouguet I, Goettmann S, Zaraa I. Superficial acral fibromyxoma with cartilaginous metaplasia. *Am J Dermatopathol.* 2019;41:316–7.
9. Hollmann TJ, Bovée JVMG, Fletcher CDM. Digital fibromyxoma (superficial acral fibromyxoma): a detailed characterization of 124 cases. *Am J Surg Pathol.* 2012;36:789–98.
10. Antonescu CR, Zhang L, Chang N-E, et al. EWSR1-POU5F1 fusion in soft tissue myoepithelial tumors. A molecular analysis of sixty-six cases, including soft tissue, bone, and visceral lesions, showing common involvement of the EWSR1 gene. *Genes Chromosom Cancer.* 2010;49:1114–24.