



HAL
open science

Q Fever Endocarditis and a New Genotype of *Coxiella burnetii*, Greece

Ioulia Karageorgou, Nektarios Kogerakis, Stavroula Labropoulou, Sophia Hatzianastasiou, Andreas Mentis, George Stavridis, Emmanouil Angelakis

► **To cite this version:**

Ioulia Karageorgou, Nektarios Kogerakis, Stavroula Labropoulou, Sophia Hatzianastasiou, Andreas Mentis, et al.. Q Fever Endocarditis and a New Genotype of *Coxiella burnetii*, Greece. *Emerging Infectious Diseases*, 2020, 26 (10), pp.2527-2529. 10.3201/eid2610.191616 . hal-03164932

HAL Id: hal-03164932

<https://amu.hal.science/hal-03164932>

Submitted on 7 Sep 2021

HAL is a multi-disciplinary open access archive for the deposit and dissemination of scientific research documents, whether they are published or not. The documents may come from teaching and research institutions in France or abroad, or from public or private research centers.

L'archive ouverte pluridisciplinaire **HAL**, est destinée au dépôt et à la diffusion de documents scientifiques de niveau recherche, publiés ou non, émanant des établissements d'enseignement et de recherche français ou étrangers, des laboratoires publics ou privés.



Distributed under a Creative Commons Attribution 4.0 International License

Q Fever Endocarditis and a New Genotype of *Coxiella burnetii*, Greece

Ioulia Karageorgou, Nektarios Kogerakis, Stavroula Labropoulou, Sophia Hatzianastasiou, Andreas Mentis, George Stavridis, Emmanouil Angelakis

Author affiliations: Hellenic Pasteur Institute, Athens, Greece (I. Karageorgou, S. Labropoulou, A. Mentis, E. Angelakis); Onassis Cardiac Surgery Center, Athens (N. Kogerakis, S. Hatzianastasiou, G. Stavridis); Aix Marseille Université, Marseille, France (E. Angelakis)

DOI: <https://doi.org/10.3201/eid2610.191616>

Underdiagnosis of *Coxiella burnetii* infections in Greece is possible because of lack of awareness by physicians, and most suspected cases are in patients with no bovine contact. We found serologic evidence of *C. burnetii* infection throughout Greece and identified a new *C. burnetii* genotype in the aortic valve of a patient with Q fever endocarditis.

Q fever is a worldwide zoonosis caused by an obligate intracellular bacterium, *Coxiella burnetii* (1,2). Although the classification of *C. burnetii* by the Centers for Disease Control and Prevention (Atlanta, GA, USA) as a potential bioterrorism agent resulted in the disease becoming reportable in many countries (3), Q fever is not considered a public health problem in Greece, and few cases have been recorded (3).

etymologia

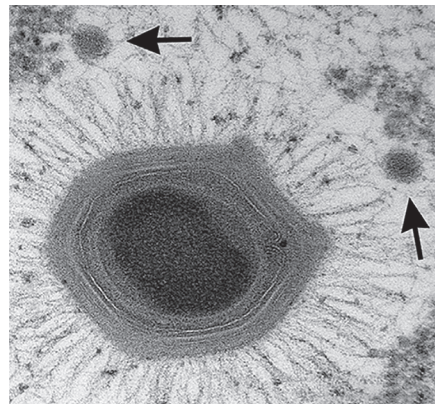
Mimivirus [mīm'ī-vī'rəs]

Clyde Partin

If virus (Latin: slimy) challenges the definition of what constitutes life, the DNA mimivirus tests how we define virus. This unidentifiable “bacterium” infecting *Acanthamoeba polyphaga*, was isolated in 1992 from a hospital cooling tower in Bradford, England. Thus, the original name was *Bradfordcoccus*, and it was considered a culprit for a pneumonia outbreak at this hospital.

Researchers brought samples to Didier Raoult and colleagues at Aix-Marseille University, who eventually identified this “bacterium” as a novel virus in 2003. The physical size, genomic content, and ability of the outer protein coat to stain gram positive, thus mimicking (Latin: imitate) prokaryotic bacteria, indicated that this pathogen might be a bacterium.

Raoult initially claimed that the moniker meant “mimicking microbe” but later sheepishly recounted a childhood memory about his father, a physician–scientist, who created stories to explain evolution. Featured prominently in these whimsical narratives was an anthropomorphic character named “Mimi the amoeba.”



Acanthamoeba polyphaga mimivirus, with two satellite Sputnik virophages (arrows). Thin-section electron microscopy courtesy of J.Y. Bou Khalil and B. La Scola, IHU Mediterranée Infection, France.

Sources

1. Redefining life [cited 2020 Jul 2]. <https://www.rsb.org.uk/biologist-features/158-biologist/features/1490-larger-than-life>
2. Viruses reconsidered [cited 2020 Jul 20]. <https://www.the-scientist.com/features/viruses-reconsidered-37867>

Author affiliation: Emory University School of Medicine, Atlanta, Georgia, USA

Address for correspondence: Clyde Partin, Emory University School of Medicine, 1365 Clifton Rd NE, Clinic A, 1st Fl, Atlanta, GA 30322, USA; email: wpart01@emory.edu

DOI: <https://doi.org/10.3201/eid2610.ET2610>

Our referent laboratory for the diagnosis of Q fever was deployed in the Hellenic Pasteur Institute in February 2019. We tested serum samples from all patients by using an immunofluorescence assay (IFA) for *C. burnetii* phase I and II antigens as described (4,5). Patients are classified as having acute Q fever; persistent, focalized *C. burnetii* infection; or evidence of past infection (6). Moreover, anticardiolipin IgG is routinely measured for patients given a diagnosis of acute Q fever (6).

During the first 7 months of testing, we received 209 serum samples from patients suspected of having Q fever. We provided diagnoses of acute Q fever for 1 (0.5%) patient and persistent *C. burnetii* focalized endocarditis for 2 (1.0%) patients; 12 (6.0%) patients showed evidence of *C. burnetii* infection. The patient given a diagnosis of acute Q fever also had high levels of anticardiolipin IgG (>140 GPLU). Further investigation also showed large, transient, aortic vegetation. Thus, this patient was considered as possibly having acute Q fever endocarditis (4,7), but contact with the patient was lost.

Epidemiologic information was obtained for 102 patients, including all patients with a positive IFA result for *C. burnetii*. This information showed that only 22% of these patients reported previous contact with bovinds. Most patients reported a previous tick bite (35%); contact with cats (16%), dogs (7%), rats (4%), or other animals (7%). In addition, 9% of these patients reported no animal contact.

We provide a detailed history for 1 patient given a diagnosis of persistent *C. burnetii* focalized endocarditis. A 45-year-old shepherd, a resident of a rural area in southern Greece, came to the local district hospital with a 2-week history of spiking fevers, peripheral edema, and night sweats. He reported non-specific symptoms gradually leading to anorexia and debilitating weakness for the previous year.

Cardiac ultrasound showed a severely regurgitant bicuspid aortic valve, a paravalvular abscess (2.6 cm × 1.6 cm), aortic root dilatation (5.3 cm), and vegetations. Cardiac computed tomography confirmed the ultrasound findings. IFA results were positive for

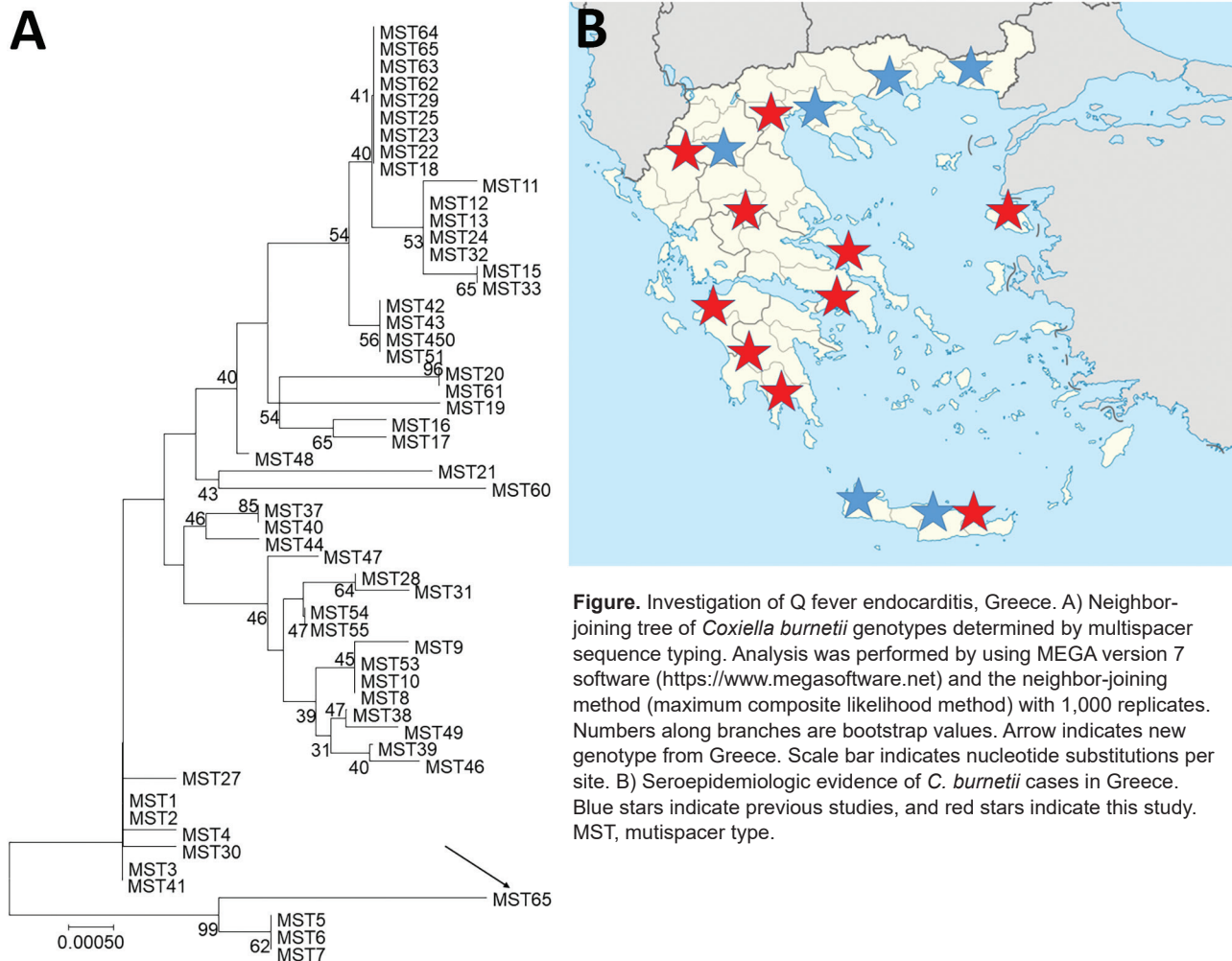


Figure. Investigation of Q fever endocarditis, Greece. A) Neighbor-joining tree of *Coxiella burnetii* genotypes determined by multispacer sequence typing. Analysis was performed by using MEGA version 7 software (<https://www.megasoftware.net>) and the neighbor-joining method (maximum composite likelihood method) with 1,000 replicates. Numbers along branches are bootstrap values. Arrow indicates new genotype from Greece. Scale bar indicates nucleotide substitutions per site. B) Seroepidemiologic evidence of *C. burnetii* cases in Greece. Blue stars indicate previous studies, and red stars indicate this study. MST, mutispacer type.

C. burnetii: phase I IgG titer 1:3,200, phase I IgM titer 0; and phase II IgG titer 1:3,200, phase II IgM titer 0. This serum sample was negative for *C. burnetii* by real-time PCR for insertion sequence (IS) 1111 and the IS30A spacers (8). Thus, we provided a diagnosis of *C. burnetii* endocarditis, and the patient was transferred to a tertiary care center for surgical management.

The patient underwent an aortic root replacement (Bentall procedure) with pericardial composite graft after extensive debridement and reconstruction of the root with the use of autologous pericardium. His aortic valve was positive for *C. burnetii* for IS1111 and IS30A spacers by real-time PCR. Multispacer sequence typing (MST) was performed as described and consisted of 10 different spacers of the *C. burnetii* genome: Cox2, 5, 6, 18, 20, 22, 37, 51, 56, and 57 (5). We identified a new MST genotype (MST65) by using web-based MST database (http://ifr48.timone.univ-mrs.fr/MST_Coxiella/mst) (Figure, panel A).

The patient was given oral doxycycline (100 mg 2×/d) and hydroxychloroquine (200 mg 3×/d) for ≥24 months (9). A convalescence-phase serum sample obtained after 6 months of treatment was positive for *C. burnetii*: phase I IgG titer 1:800, phase I IgM titer 0, and phase II IgG titer 1:800, phase II IgM 0.

Our preliminary data show that physicians in Greece are not familiar with Q fever because most of the suspected cases were in patients without bovine contact. A limitation of our study was that culture was not performed because of the absence of a Biosafety Level 3 laboratory. The fact that we did not provide diagnoses of classic, acute Q fever showed that *C. burnetii* infection is suspected mostly in culture-negative serious endocarditis case-patients. Moreover, we identified a new *C. burnetii* genotype in the aortic valve of a patient who had Q fever endocarditis. Recently, it was found that *C. burnetii* genotype 32 is circulating in sheep and goat in 8 different areas of Greece (10). The clinical manifestations of Q fever depend, at least in part, on the *C. burnetii* genotype (5). However, although acute clinical manifestations are strain-specific, all genotypes have been associated with endocarditis (5).

We raise the question of underdiagnosis of *C. burnetii* infections in Greece. Our data have affected local clinical practice because we found serologic evidence of *C. burnetii* infection throughout most of Greece (Figure, panel B).

About the Author

Dr. Karageorgou is a biologist and researcher at the Hellenic Pasteur Institute in Athens, Greece. Her primary research interest is zoonotic pathogens.

References

1. Angelakis E, Raoult D. Q fever. *Vet Microbiol*. 2010;140:297–309. <https://doi.org/10.1016/j.vetmic.2009.07.016>
2. Eldin C, Mélenotte C, Mediannikov O, Ghigo E, Million M, Edouard S, et al. From Q fever to *Coxiella burnetii* infection: a paradigm change. *Clin Microbiol Rev*. 2017;30:115–90. <https://doi.org/10.1128/CMR.00045-16>
3. Kokkini S, Chochlakis D, Vranakis I, Angelakis E, Tselentis Y, Gikas A, et al. Antibody kinetics in serological indication of chronic Q fever: the Greek experience. *Int J Infect Dis*. 2013;17:e977–80. <https://doi.org/10.1016/j.ijid.2013.04.010>
4. Million M, Thuny F, Bardin N, Angelakis E, Edouard S, Bessis S, et al. Antiphospholipid antibody syndrome with alvular vegetations in acute Q fever. *Clin Infect Dis*. 2016;62:537–44. <https://doi.org/10.1093/cid/civ956>
5. Angelakis E, Million M, D'Amato F, Rouli L, Richet H, Stein A, et al. Q fever and pregnancy: disease, prevention, and strain specificity. *Eur J Clin Microbiol Infect Dis*. 2013;32:361–8. <https://doi.org/10.1007/s10096-012-1750-3>
6. Melenotte C, Protopopescu C, Million M, Edouard S, Carrieri MP, Eldin C, et al. Clinical features and complications of *Coxiella burnetii* infections from the French National Reference Center for Q Fever. *JAMA Netw Open*. 2018;1:e181580. <https://doi.org/10.1001/jamanetworkopen.2018.1580>
7. Melenotte C, Epelboin L, Million M, Hubert S, Monsec T, Djossou F, et al. Acute Q fever endocarditis: a paradigm shift following the systematic use of transthoracic echocardiography during acute Q fever. *Clin Infect Dis*. 2019;69:1987–95. <https://doi.org/10.1093/cid/ciz120>
8. Angelakis E, Mediannikov O, Socolovschi C, Mouffok N, Bassene H, Tall A, et al. *Coxiella burnetii*-positive PCR in febrile patients in rural and urban Africa. *Int J Infect Dis*. 2014;28:107–10. <https://doi.org/10.1016/j.ijid.2014.05.029>
9. Melenotte C, Million M, Raoult D. New insights in *Coxiella burnetii* infection: diagnosis and therapeutic update. *Expert Rev Anti Infect Ther*. 2020;18:75–86. <https://doi.org/10.1080/14787210.2020.1699055>
10. Chochlakis D, Santos AS, Giadinis ND, Papadopoulos D, Boubaris L, Kalaitzakis E, et al. Genotyping of *Coxiella burnetii* in sheep and goat abortion samples. *BMC Microbiol*. 2018;18:204. <https://doi.org/10.1186/s12866-018-1353-y>

Address for correspondence: Emmanouil Angelakis, Aix Marseille Université, Institut de Recherche pour le Développement, Assistance Publique Hôpitaux de Marseille, Vecteurs Infections Tropicales et Méditerranéennes, Institut Méditerranée Infection, 19–21 Blvd Jean Moulin, Marseille 13005, France; email: e.angelakis@hotmail.com