



HAL
open science

In Vivo Feasibility of Arterial Embolization with Permanent and Absorbable Suture: The FAIR-Embo Concept

V Vidal, J F Hak, P Brige, S Chopinet, F Tradi, M Bobot, P Gach, A Haffner, G Soulez, A Jacquier, et al.

► **To cite this version:**

V Vidal, J F Hak, P Brige, S Chopinet, F Tradi, et al.. In Vivo Feasibility of Arterial Embolization with Permanent and Absorbable Suture: The FAIR-Embo Concept. CardioVascular and Interventional Radiology, 2019, 42, pp.1175 - 1182. 10.1007/s00270-019-02211-y . hal-03168989

HAL Id: hal-03168989

<https://amu.hal.science/hal-03168989>

Submitted on 15 Mar 2021

HAL is a multi-disciplinary open access archive for the deposit and dissemination of scientific research documents, whether they are published or not. The documents may come from teaching and research institutions in France or abroad, or from public or private research centers.

L'archive ouverte pluridisciplinaire **HAL**, est destinée au dépôt et à la diffusion de documents scientifiques de niveau recherche, publiés ou non, émanant des établissements d'enseignement et de recherche français ou étrangers, des laboratoires publics ou privés.

In Vivo Feasibility of Arterial Embolization with Permanent and Absorbable Suture: The FAIR-Embo Concept

V. Vidal^{1,2,3} · J. F. Hak^{1,2,3} · P. Brige^{2,3} · S. Chopinet^{2,3,4} · F. Tradi^{1,2,3} · M. Bobot^{3,5,6} · P. Gach^{1,2,3} · A. Haffner⁷ · G. Soulez⁸ · A. Jacquier¹ · G. Moulin¹ · J. M. Bartoli¹ · B. Guillet^{3,6,9}

Abstract

Purpose Arterial embolization has been shown to be effective and safe for the management of bleeding, especially for postpartum and pelvic traumatic bleeding. We propose to evaluate the proof of concept of feasibility and effectiveness of arterial embolization with absorbable and non-absorbable sutures in a porcine model.

Materials and Methods In the acute setting ($n = 1$), several different arteries (mesenteric, splenic, pharyngeal, kidney)

were embolized using non-absorbable sutures (NAS): MersuturesTM braided sutures (polyethylene terephthalate). In the chronic setting ($n = 3$), only lower pole renal arteries were embolized. On the right side, NAS was used, whereas on the left side embolization was realized with absorbable suture (AS): Vicryl[®] braided suture (polyglactin 910). The chronic group was followed for 3 months. The pigs received contrast-enhanced CT the day before embolization (D-1), after the embolization (D0), at 1 month and 3 months after embolization (M1 and M3); digital subtraction angiography (DSA) was done at D0 and M3 and histological analysis at M3.

Results All vascular targets were effectively embolized without any pre- or postoperative complications. Both DSAs and CTs at M3 showed a 100% recanalization rate for the AS embolization and a partial reversal rate for the NAS embolization. A renal hypotrophy in the embolized region was observed during both the M1 and M3 scans for both sutures (AS and NAS) with a clear hypotrophy for the NAS embolized kidney.

Conclusion Embolization by AS and NAS (FAIR-Embo) is a feasible and effective treatment which opens up the possibility of global use of this inexpensive and widely available embolization agent.

Keywords Embolization · Absorbable suture · Non-absorbable suture · Life-threatening bleeding · Emerging countries

Abbreviations

CT Computed tomography
NAS Non-absorbable suture
AS Absorbable suture
DSA Digital subtraction angiography

Authors V. Vidal and J. F. Hak contributed equally to this work.

✉ V. Vidal
vincent.vidal@ap-hm.fr

✉ J. F. Hak
jeanfrancois.hak@gmail.com

¹ Interventional Radiology Section, Department of Medical Imaging, University Hospital Timone APHM, Marseille, France

² LIIE, Aix Marseille Univ, Marseille, France

³ CERIMED, Aix Marseille Univ, Marseille, France

⁴ Department of Digestive Surgery, University Hospital Timone APHM, Marseille, France

⁵ Department of Nephrology, University Hospital Conception APHM, Marseille, France

⁶ INSERM 1263, INRA 1260, C2VN, Aix Marseille Univ, Marseille, France

⁷ Department of Pathological Anatomy, University Hospital Timone APHM, Marseille, France

⁸ Department of Radiology, Centre Hospitalier de l'Université de Montréal, 1560 Sherbrooke East, Montreal H2L 4M1, Canada

⁹ Department of Radiopharmacy, APHM, Marseille, France

Fr	French
Mm	Millimetre
Mg	Milligram
IMDs	Implantable medical devices
VR	Volume Rendering

Introduction

The arterial embolization knows an important development illustrated by the widening of the indications to various medico-surgical fields. Radiologists have an increasingly important role in oncological [1, 2], gynecological [3, 4] and post-traumatic management [5, 6].

Over the past 45 years, interventional radiology research has developed numerous embolic agents that are classified into permanent or temporary occlusion categories.

To our knowledge, the suture embolization has only been made with the use of silk-based thread. This embolic material used in combination with PVA particles often using 6-0 size and 0.5 mm to 3 cm fragments through ordinary catheter and microcatheter allows effective and safe embolization without increasing bleeding and inflammatory risk [7–9].

Embolization with polyglactin 910 and polyethylene terephthalate was not yet evaluated.

The suture morphology should enable an easy release through a catheter, a technique equivalent with the use of a gelatin torpedo.

Suture-based embolizations should be definitive or transient depending on whether they are non-absorbable (NAS) or absorbable (AS).

FAIR-Embo is a concept based on the hope to use interventional radiology in emerging countries, by the development of safe, available and cheap embolic material.

This study evaluates the feasibility and safety of arterial embolization of absorbable and permanent sutures using the porcine model.

Materials and Methods

Animal Experiments

This work was conducted on Swine model because of its anatomy similarities with humans. This model allowed us to use the interventional radiology equipment used in humans and to have sufficient quantities of renal tissue.

The animals were used in accordance with institutional and national guidelines for the care and use of animals. Four Piétrans pigs of 40 ± 5 kg were used after agreement of the Committee of Ethical Animal (APAFIS#5432-2016052312473717).

The animals were placed in a dorsal, recumbent position and then sedated with 20 mg/kg ketamine and 0.03 mg/kg acepromazine. A venous catheter was inserted into a large ear vein for blood sampling and intravenous access. Induction of anesthesia was obtained by 2 mg/kg propofol. After orotracheal intubation, anesthesia was maintained with gaseous sevoflurane (2%) by mechanical respiration (Zeus Dräger Inc.). Aseptic techniques were used throughout the procedure.

After the intervention, an extubation was done once the halogens were stopped, the swallowing and ocular reflexes were checked, and a spontaneous ventilation had occurred.

The animals in the acute group were euthanized immediately afterward, and the chronic group was euthanized 3 months (M3) after performing a DSA/CT evaluation. These evaluations were performed under general anesthesia.

Each CT was performed on Discovery CT 750 (GE Healthcare, Chicago, Illinois, US) using contrast medium (Ioméron 300, Bracco Imaging France).

Embolization Procedure

A digital subtraction angiography system (DSA) (Fluorostar, General Electric Medical System, Minneapolis, MN USA) was used for the radiological procedures. Aseptic percutaneous access was performed by femoral arterial puncture under ultrasound guidance with the placement of a 6-F vascular introducer by Seldinger method.

Catheterization of arterial vascular targets, using a Cobra Wirebraid 4F probe (Cordis, Fremont, California, USA), was performed by an experienced interventional radiologist. A series of diagnostic angiographies (Visipaque 320 mg I/ml, GE) were performed before and after selective catheter embolizations.

Embolization was performed once the catheter was placed within the target artery by inserting a suture fragment into the lumen of a 5-mL syringe and then pushing it through the catheter (Fig. 1) with a syringe filled with contrast medium (5 mL; Visipaque 320 mg I/ml, GE).

Repeated diagnostic arteriographic monitoring artery canalization state and suture fragments released.

The embolization endpoint occurred when a complete occlusion of the artery by an experienced interventional radiologist was achieved. The amount in centimeter (cm) (corresponding in fragment number) and in milligram (mg) of sutures used to occlude the arteries was evaluated.

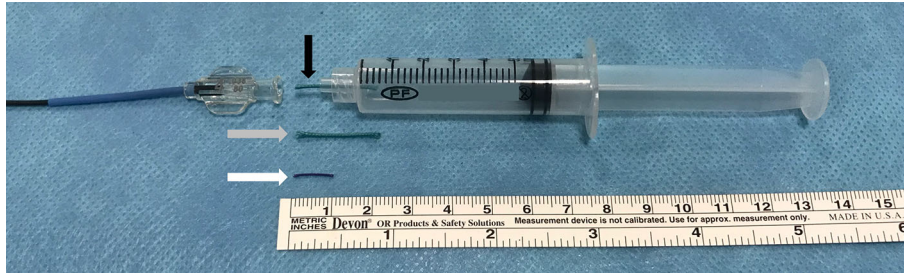


Fig. 1 Embolization fragment suture placed in a 5-mL syringe before release (Black arrow). Gray arrow: Representative Mersutures™ suture fragments (2 cm, 0.9 mm diameter, acute group). White arrow: Representative Vicryl suture fragments (1 cm, 0.5 mm diameter, chronic group)

Animal Settings

In the acute setting ($n = 1$), several different arteries (mesenteric, splenic, pharyngeal, kidney) (Fig. 2) were embolized using non-absorbable sutures (NAS): Mersutures™ braided sutures (polyethylene terephthalate: Ethicon, Cincinnati, Ohio, USA, 1992).

Embolization of the digestive, splenic, pharyngeal and kidney arteries of the animals ($n = 1$) was performed to evaluate the feasibility of suture releasing through the catheter. The safety aspect (risk of non-target embolization) and the immediate effectiveness (technical success) of the embolization were also evaluated.

Mersutures™ 6, Ethicon® non-absorbable (polyethylene terephthalate) suture with a diameter between 0.8 and 0.899 mm was used and was sterilely prepared in 1 to 3 cm fragments for embolization.

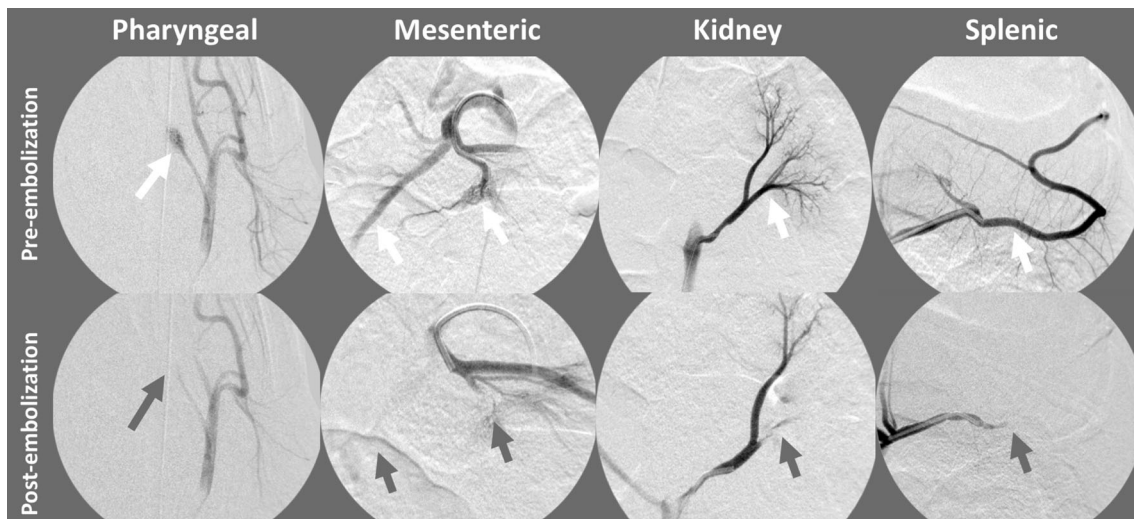
In the chronic setting ($n = 3$), only lower pole renal arteries were embolized. On the right side, NAS was used, whereas on the left side embolization was realized with absorbable suture (AS): Vicryl® braided suture

(polyglactin 910: Ethicon, Cincinnati, Ohio, USA, 1992). The chronic group was followed for 3 months.

The efficacy and short- to medium-term tolerance of absorbable and non-absorbable suture embolization was assessed in three pigs. The sutures' behavior during embolization (reproducibility) and tissue effects in the medium-term testing involved embolization of the lower lobar renal arteries. For reasons of reproducibility, we embolized all right renal arteries with non-absorbable suture (NAS) and all left renal arteries with absorbable suture (AS). Each suture had a size 1 according to the diameter USP (US Pharmacopoeia), corresponding to a diameter of between 0.4 and 0.5 mm. The superior lobar arteries had been safeguarded in order to keep the animals alive with a correct residual renal function.

Each suture was prepared aseptically cutting it into fragments of 1 cm (corresponding to 3 mg for AS and NAS) in order to use it for the embolization procedures.

The 3-month (M3) follow-up studied the effects of implanted products in the medium term in agreement with reference standard for ISO10993-6 animal studies.



Each pig was explored by CT scan the day before embolization (D-1), immediately after embolization (D0), at 1 month (M1) and at 3 month (M3) after the procedure before they were euthanized. Subsequently, renal explanation and histological tissue studies were performed.

The CT scans evaluated arterial occlusion, an absence of any complications and each kidney's volume.

Histological Study

Post-embolization tissue recovery was evaluated using histological analysis of kidneys. The kidneys were then dissected into both the medullary and cortical parts and incorporated into paraffin. Slides for each part (4 μm thick) were prepared using a microtome (Microm, France) and stained with hematoxylin–eosin (HE) (AutoStainer, DRS 2000 Sakura). A qualitative and semi-quantitative evaluation was carried out by an experienced anatomopathologist.

The following parameters were evaluated using a semi-quantitative scoring system (0–3): fibrin, neovascularization, hemorrhage, revascularization, cellular inflammatory parameters (fibroblasts, polynuclear, lymphocytes, macrophages, giant cells) and acute tubular necrosis [10, 11].

Results

Acute Group: Security Aspect (Non-target Embolization) and Immediate Effectiveness (Technical Success) of Embolization

Polyethylene terephthalate 6 USP (0.8–0.9 mm) fragments enabled an effective embolization of all different vascular targets tested (Fig. 2).

Technically, we demonstrated that a fragment of 0.8–0.9 mm is easily releasable through a 4 Fr (0.97 mm) diameter catheter flushed with saline. It is possible to vary the length of the fragment by 1 to 3 cm in order to increase its vessel occlusion capacity. Vessel occlusion was quickly obtained after injecting 2 to 4 fragments (9.3 ± 3.4 cm) of suture. No off-target embolization was observed.

For pharyngeal, splenic, kidney and mesenteric artery occlusion, the total amount of needed sutures was, respectively, 12, 6, 12 and 7.

Figure 3 shows the suture diameter as compatible with the different catheter and microcatheter diameters most frequently used by interventional radiologists.

Chronic Group: Embolization Procedure, Occlusion Efficacy and Immediate Tolerance

Right kidney: NAS; polyethylene terephthalate (Ethicon, Cincinnati, Ohio, USA, 1992).

The average number of 1 cm USP 1 braided suture fragments required for total occlusion was 21.3 ± 5.6 fragments ($0.064 \text{ g} \pm 0.017$, $n = 3$).

Left kidney: AS; polyglactin 910 (Ethicon, Cincinnati, Ohio, USA, 1992).

The average number of 1 cm USP 1 braided suture fragments USP required for total occlusion was 17.7 ± 4.6 fragments ($0.053 \text{ g} \pm 0.014$, $n = 3$).

Chronic Group: Medium-Term Permeability of Embolization

DSA Monitoring

DSA 3 months after AS embolization objectified 100% of recanalization (Fig. 4).

After NAS embolization (Fig. 4), the M3 DSA showed a partial recanalization with a thin appearance of the target arteries compared to the initial DSA.

Chronic Group: CT D-1, D0 and M3

The 1- and 3-month CT examinations showed no complications (abscess, urinoma). At D0, CT scan allowed to show a hypoperfusion in the embolized kidney territory. At M3, a cortical defect and a hypotrophy were visualized within the embolized renal territory for all the animals. Embolization of one pig (right kidney) showed severe renal hypotrophy with persistence of parenchymography and a correct renal excretion (Kidney volume D-1: NAS = 77.30 mL; AS = 78.1 mL and M3: NAS = 19.6 mL; AS = 127.8 mL).

Chronic Group: Histology

Three months after embolization on tissue section, NAS arterial embolic material has been found without fragmentation in arteries for all the right kidneys (NAS) but none in the left one (AS). There was no any perivascular granulocytic infiltration. So, AS was totally decomposed at M3.

Histological analysis of AS and NAS embolized kidneys sections showed no significant difference of tissue fibroplasia, edema, neovascularization, hemorrhage, necrosis (inflammatory parameters) or polymorph nuclear cells, lymphocytes, plasma cells, macrophages and giant cells (cellular inflammation) has been observed in all the sections (Fig. 5).

SUTURE	USP Decimal														
		10	9	8	7	6	5	3+4	2	1	0	2-0	3-0	4-0	
	Diameter (mm)	1.2-1.3	1.1-1.2	1.0-1.1	0.9-1.0	0.8-0.9	0.7-0.8	0.6-0.7	0.5-0.6	0.4-0.5	0.35-0.4	0.3-0.35	0.25-0.3	0.2-0.25	0.15-0.2
CATHETER 6F	Outer diameter (French)	6 Fr													
	Internal diameter (inch)	0.070" to 0.071"													
	Internal diameter (mm)	1.78 to 1.80													
CATHETER 5F	Outer diameter (French)	5 Fr													
	Internal diameter (inch)	0.040" to 0.059"													
	Internal diameter (mm)	1.02 to 1.50													
CATHETER 4F	Outer diameter (French)	4 Fr													
	Internal diameter (inch)	0.035" to 0.038"													
	Internal diameter (mm)	0.89 to 0.97													
MICROCATHETER 1.7F	Outer diameter (French)	Proximal extremity: 2.4 F Distal end: 1.7 F													
	Internal diameter (inch)	0.014" to 0.017"													
	Internal diameter (mm)	0.36 to 0.43													

Fig. 3 Suture diameter correspondence to the most commonly used catheter and microcatheter diameters for suture fragments releasing

Fig. 4 Lower left renal lobar artery embolization with AS. Lower right renal lobar artery embolization with NAS

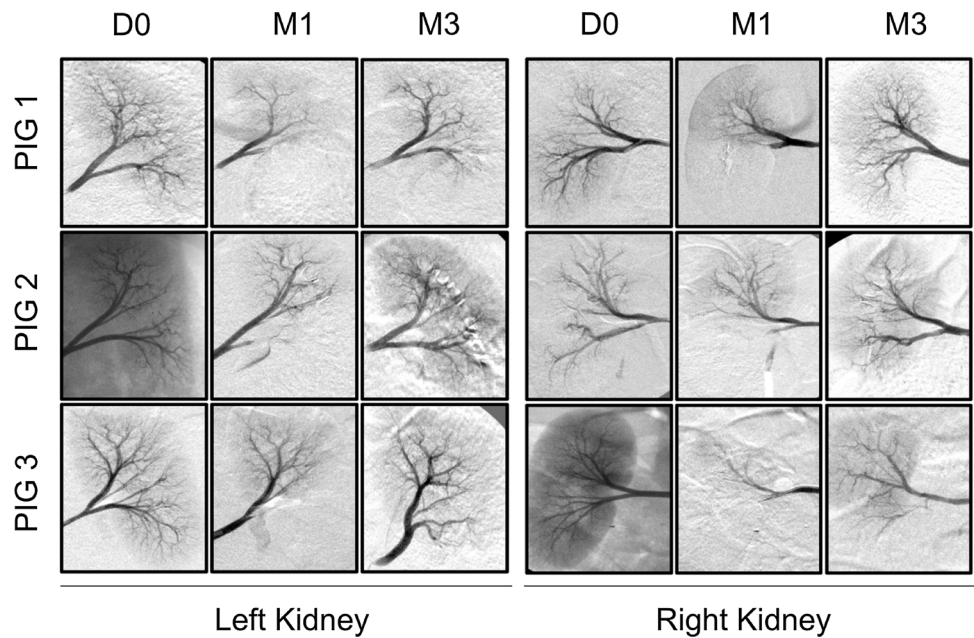
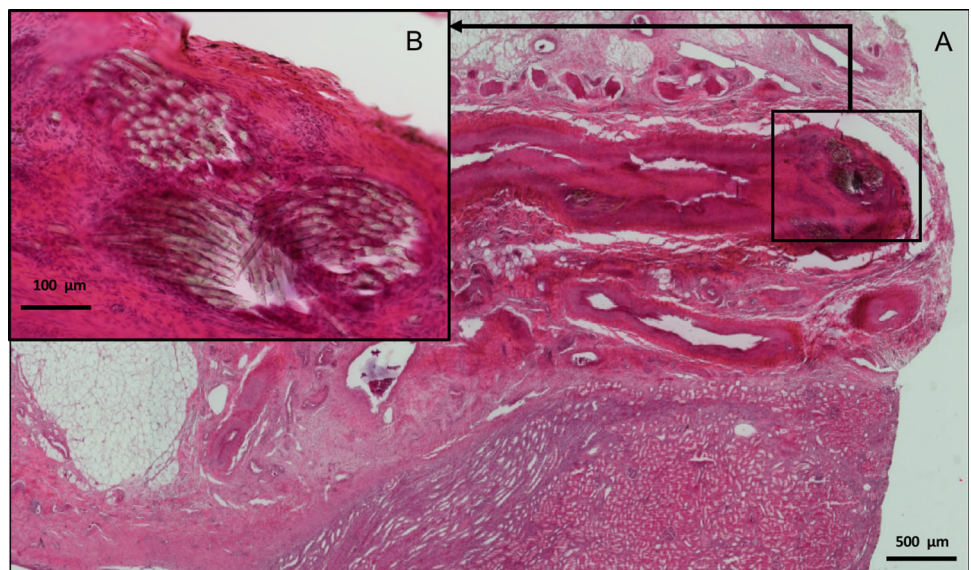


Fig. 5 **A** Light microscopy ($\times 2$): centered on NAS without perivascular inflammatory granuloma at M3. **B** Light microscopy ($\times 10$) centered on NAS with intra-arterial localization at M3



Discussion

This work is a proof of concept of feasibility and safety of FAIR-Embo procedure consisting in homemade suture fragments use from a worldwide available suture material in the aim to make arterial embolization available in the greatest number of countries.

This proof of concept allowed showing the feasibility of FAIR-Embo. The suture is almost ready to use, simply flushed with saline or iodinated contrast medium without any resistance and stops either when it contacts a wall or is against a vascular bifurcation. An additional bench-work needs to be done to demonstrate how the consistency and morphology of the sutures makes them easy to use through the catheter for an embolization. Anyway, silk sutures are already used for arterial embolization [7–9].

Knowing the diameter of the catheter's inner lumen helps determine which maximum diameter can pass through the catheter.

Figure 3 summarizes compatibilities of the different suture diameters, and the catheters and microcatheters available on the market.

The lack of suture radiopacity renders the FAIR-Embo technique similar to a gelatin embolization. In our study, the selective catheterization, along with an experienced operator, has resulted in selective embolizations without any off-target embolizations.

Considering tissue suturing and according manufacturer information, the most absorbable suture on the market (Vicryl, polyglactin 910) has resorption rates of: 25% at 14 days, 50% at 21 days, 75% at 30 days and 100% at 42 days and might be shorter within the vascular compartment when used for embolization resulting in a transient artery occlusion [12]. On the contrary, one of the least expensive NAS on the market is MersuturesTM (polyethylene terephthalate) which seems to be worldwide accessible, is not absorbable and induces nearly definitive embolization according to our results.

There was a wide variation of suture material between animals from the chronic setting. For this work which is a proof of concept, our main endpoint was total artery occlusion and our second endpoint was the histological analyses. The amount of thread needed was only to report our procedure. These variations do not take in consideration any time procedure and artery characteristics (relation between the size of artery and the diameter of suture). But with this positive proof of concept, a standardization of the procedure according to the size of the artery and the amount of needed suture can be studied and will be the aim of another study.

To our knowledge, the suture embolization has only been made with the use of silk-based thread from a 6-0 size

from 0.5 mm to 3 cm fragments through ordinary catheter and microcatheter. This silk suture allowed effective and safe embolization without increasing bleeding and inflammatory risk [7–9]. Besides, embolization cases described with silk suture do not report cases of recanalization. However, silk suture is not as common in hospitals as sutures based on polyglactin or polyethylene terephthalate which are used every day by emergency and surgical departments.

Our work investigated the feasibility and outcomes after arterial embolization with polyethylene terephthalate (NAS) and polyglactin 910 (AS).

Our results showed a complete recanalization at 3 months for AS, and a partial recanalization for NAS. Histological analysis proved absence of organ and tissue damage apart from those relative to embolization procedure.

Other cheap embolic agents (autologous blood clot, gelfoam) are potentially competitive in terms of price but not in availability. Sutures are widely available without pharmaceutical circuit constraints. Any medical facility with primary surgery department and emergency department has suture.

Arterial embolization has been shown to be effective and safe in some oncological procedures [1, 2], postpartum hemorrhage management [3, 4] as well as in post-traumatic abdominal bleeding and is particularly true with splenic and pelvic embolizations [5, 6].

The embolic agents on the market include gelatins, releasable implantable medical devices (coils, stents, plugs), microparticles and liquid agents (cyanoacrylate and polymers) [8].

Over the long term, embolic non-biodegradable substances caused chronic inflammation *in vivo* which subsequently caused tissue damage [11, 13, 14].

To avoid these complications and to maintain the physiological function of the treated organs, biodegradable embolic materials are sometimes preferred [15–17]. The most commonly used biodegradable embolic agent is a porcine derivative gelatin sponge use in endovascular procedures since 1964 [18]. This agent exhibits complete resorption after 30 days.

FAIR-Embo could allow the same results with an arterial embolization without any significant inflammation according to our histological results at M3.

There are advantages and disadvantages of these sutures when compared to “traditional” embolic agents. These advantages are: low cost, available worldwide, ease of use (release and choice of length) and long-term safety.

The disadvantages are: the linear shape (lack of attachment in the vessel lumen if diameter is greater than that of the suture, comparable to the gelatin torpedoes), and the absence of radio-opacity (such as particles and gelatin).

According to our pre-clinical results, this procedure based on arterial embolization with sutures could not yet be used in oncological procedure. But this embolic agent could be thought to be effective and safe in post-traumatic and postpartum bleeding. Particles and not only fragments (1–3 cm) made from sutures could be thought in order to be used as an embolic agent for oncological procedures. This project is part of the FAIR-Embo concept and will be the aim of another future work.

FAIR-Embo concept presents a real potential clinical impact for patient. In fact, exsanguination within the first 24 h after delivery has a high mortality rate and is the main cause of postpartum hemorrhage and post-traumatic abdominal-pelvic hemorrhagic wounds.

These embolism techniques are able to be immediately performed in the operating room with a simple mobile C-Arm X-Ray System. This procedure requires only the very basic materials of a needle and 4Fr catheters for vascular access (Seldinger technique) and navigation in the hypogastric arteries and its collaterals.

Embolic agent, on the other hand, is an obvious limitation of this technique. Indeed, implantable medical devices (IMDs) are required by law to comply with complex hospital pharmaceutical guidelines. In some countries, IMDs are fully reimbursed as well as its associated care and hospitalization costs but actually IMDs, such as some embolic agents, still remained not available for numerous developing countries mainly for economic concerns.

FAIR-Embo could meet the needs of a health system that does not fully reimburse this care, thus allowing more hemorrhagic patients access to arterial embolization.

Study Limitations

Although the porcine model has similarities to humans, reproducibility of these results in humans must be proven. This is particularly true for the recanalization rate with non-absorbable sutures, given the porcine's more efficient coagulation parameters.

Conclusion

Embolization by AS and NAS (FAIR-Embo) is feasible, safe and effective in the medium term, in the porcine model. These results merit considerations for their use as an inexpensive and widely available embolization agent in hospitals worldwide.

Acknowledgements My sincere thanks to Pr. Jafar Golzarian who, through our many friendly discussions, indirectly inspired me to do this study.

Compliance with Ethical Standards

Conflict of interest The authors declare that they have no conflict of interest.

Ethical Approval All procedures performed in studies involving animals were in accordance with the ethical standards of the institution or practice at which the studies were conducted.

References

1. Sakurai M, Okamura J, Kuroda C. Transcatheter chemo-embolization effective for treating hepatocellular carcinoma. A histopathologic study. *Cancer*. 1984;54(3):387–92.
2. Lencioni R, de Baere T, Burrel M, Caridi JG, Lammer J, Malgari K, et al. Transcatheter treatment of hepatocellular carcinoma with Doxorubicin-loaded DC Bead (DEBDOX): technical recommendations. *Cardiovasc Intervent Radiol*. 2012;35(5):980–5.
3. Pelage J, Le Dref O, Mateo J, Soyer P, et al. Life-threatening primary postpartum hemorrhage: treatment with emergency selective arterial embolization. *Radiology*. 1998;208(2):359–62.
4. Pelage J, Soyer P, Herbreteau D, Houdart E, et al. Secondary postpartum hemorrhage: treatment with selective arterial embolization. *Radiology*. 1999;212(2):385–9.
5. Lang E. Transcatheter embolization of pelvic vessels for control of intractable hemorrhage. *Radiology*. 1981;140(2):331–9.
6. Scemama U, Dabadie A, Varoquaux A, Louis G, et al. Pelvic trauma and vascular emergencies. *Diagn Interv Imag*. 2015;96(7–8):717–29.
7. Conger JR, Ding D, Raper DM, Starke RM, Durst CR, Liu KC, et al. Preoperative embolization of cerebral arteriovenous malformations with silk suture and particles: technical considerations and outcomes. *J Cerebrovasc Endovasc Neurosurg*. 2016;18(2):90–9 **Epub 2016 Jun 30**.
8. Ding D, Sheehan JP, Starke RM, Durst CR, Raper DM, Conger JR, Evans AJ. Embolization of cerebral arteriovenous malformations with silk suture particles prior to stereotactic radiosurgery. *J Clin Neurosci*. 2015;22(10):1643–9.
9. Schmutz F, McAuliffe W, Anderson DM, Elliott JP, Eskridge JM, Winn HR. Embolization of cerebral arteriovenous malformations with silk: histopathologic changes and hemorrhagic complications. *AJNR Am J Neuroradiol*. 1997;18(7):1233–7.
10. Wan X, Liu L, Zhang Q, et al. IKK is involved in kidney recovery and regeneration of acute ischemia/reperfusion injury in mice through IL10-producing regulatory T cells. *Dis Models Mech*. 2015;8(7):733–42.
11. Natarajan S, Born D, Britz G, Sekhar L. Histopathological changes in brain arteriovenous malformations after embolization using onyx or N-butyl cyanoacrylate. *J Neurosurg*. 2009;111(1):105–13.
12. Dossier technique destiné à l'usage des pharmaciens hospitaliers [Internet]. [cité 15 août 2018]. Disponible sur: <http://docs.exhausmed.com/docs/ethicon/2008/VICRYL%20RAPIDE%20dossier%20pharmaciens.pdf>.
13. Link D, Strandberg J, Mourtada F, Samphilipo M. Histopathologic appearance of arterial occlusions with hydrogel and polyvinyl alcohol embolic material in domestic swine. *J Vasc Interv Radiol*. 1996;7(6):897–906.
14. Su C, Takahashi A, Yoshimoto T, Sugawara T. Histopathological studies of a new liquid embolization method using estrogen-alcohol and polyvinyl acetate. *Surg Neurol*. 1991;36(1):4–11.

15. Chua K, McLucas B. Pregnancy after uterine artery embolization using Gelfoam™. *Minim Invasive Ther Allied Technol.* 2017;27(4):246–8.
16. Doucet J, Kiri L, Lewandowski R, Liu D, et al. Advances in degradable embolic microspheres: a state of the art review. *J Funct Biomater.* 2018;9(1):14.
17. Keussen I, Bengtsson J, Gavier-Widén D, Karlstam E. Uterine artery embolization in a sheep model: biodegradable versus non-degradable microspheres. *Acta Radiol.* 2018;59(10):1210–7.
18. Abada HT, Golzarian J. Gelatine sponge particles: handling characteristics for endovascular use. *Tech Vasc Interv Radiol.* 2007;10(4):257–60.

Publisher's Note Springer Nature remains neutral with regard to jurisdictional claims in published maps and institutional affiliations.