



HAL
open science

Management of surgical complications of previous bariatric surgery in pregnant women. A systematic review from the BARIA-MAT Study Group

Cecile Ciangura, Tarek Debs, Muriel Coupaye, Philippe Deruelle, Geraldine Gascoin, Daniela Calabrese, Emmanuel Cosson, Guillaume Ducarme, Benedicte Gaborit, Benedicte Lelievre, et al.

► To cite this version:

Cecile Ciangura, Tarek Debs, Muriel Coupaye, Philippe Deruelle, Geraldine Gascoin, et al.. Management of surgical complications of previous bariatric surgery in pregnant women. A systematic review from the BARIA-MAT Study Group. *Surgery for Obesity and Related Diseases*, 2020, 16 (2), pp.312-331. 10.1016/j.soard.2019.10.022 . hal-03169644

HAL Id: hal-03169644

<https://amu.hal.science/hal-03169644>

Submitted on 21 Jul 2022

HAL is a multi-disciplinary open access archive for the deposit and dissemination of scientific research documents, whether they are published or not. The documents may come from teaching and research institutions in France or abroad, or from public or private research centers.

L'archive ouverte pluridisciplinaire **HAL**, est destinée au dépôt et à la diffusion de documents scientifiques de niveau recherche, publiés ou non, émanant des établissements d'enseignement et de recherche français ou étrangers, des laboratoires publics ou privés.



Distributed under a Creative Commons Attribution - NonCommercial 4.0 International License

Management of surgical complications of previous bariatric surgery in pregnant women.

A systematic review from the BARIA-MAT Study Group*

Short title: Bariatric surgical complications during pregnancy

Niccolo Petrucciani (1,2), MD, PhD, Cecile Ciangura (3), MD, Tarek Debs (1), MD, Guillaume Ducarme (4), MD, PhD, Daniela Calabrese (5), MD, Jean Gugenheim (1), MD, PhD and the BARIA-MAT Study Group*

- 1) Division of Digestive Surgery and Liver Transplantation, Nice University Hospital, Nice, France
- 2) Department of Medical and Surgical Sciences and Translational Medicine, Sant' Andrea Hospital, Sapienza University, Rome, Italy.
- 3) Assistance Publique-Hôpitaux de Paris, Pitié-Salpêtrière Hospital, Department of Nutrition, Sorbonne Université, Institute of Cardiometabolism and Nutrition (ICAN); Paris, France
- 4) Department of Obstetrics and Gynecology, Centre Hospitalier Departemental, La Roche-sur-Yon, France.
- 5) Assistance Publique-Hôpitaux de Paris, Louis Mourier Hospital, Digestive Surgery Department, Sorbonne Paris Cité Diderot, Colombes, France

Emails of all authors: niccolo.petrucciani@uniroma1.it; cecile.ciangura@aphp.fr;
debs.t@chu-nice.fr; g.ducarme@gmail.com; daniela.calabrese@aphp.fr;
gugenheim.j@chu-nice.fr

Running head: Surgical complications of bariatric surgery in pregnant women

No funding received.

*** BARIA-MAT Study Group is composed by:** Cécile Ciangura, Muriel Coupaye, Philippe Deruelle, Géraldine Gascoin, Daniela Calabrese, Emmanuel Cosson, Guillaume Ducarme, Bénédicte Gaborit, Bénédicte Lelièvre, Laurent Mandelbrot, Niccolo Petrucciani, Didier Quilliot, Patrick Ritz, Geoffroy Robin, Agnès Sallé, Jean Gugenheim, Jacky Nizard, MD, Virginie Castera, Régis Coutant, Thierry Dupré, Hubert Johanet, Marie Pigeyre, Brigitte Rochereau, Véronique Taillard, Claudine Canale and Anne-Sophie Joly.

Corresponding author:

Dr Niccolo Petrucciani, Department of Medical and Surgical Sciences and Translational Medicine, Sant'Andrea Hospital, via di Grottarossa 1035-1039, Sapienza University, 00189 Rome, Italy.

Email: niccolo.petrucciani@uniroma1.it

Fax +390633775322; Tel: +39068558620

Management of surgical complications of previous bariatric surgery in pregnant women.

A systematic review from the BARIA-MAT Study Group

Running head: Surgical complications of bariatric surgery in pregnant women

5

Abstract:

Considering the large and increasing population of women of childbearing age with history of bariatric surgery, surgical complications of bariatric surgery during pregnancy may become more frequent in the future. The aim of this study is to analyze the clinical presentation,
10 diagnostic procedures, and treatment of surgical complications of bariatric surgery during pregnancies.

A systematic literature search according to the PRISMA guidelines was performed to identify all studies published up to and including December 2018 that included women with previous bariatric surgery undergoing emergency surgery during pregnancy.

15 Sixty-eight studies were selected, including 120 women with previous bariatric surgery undergoing emergency surgery during pregnancy. Fifty cases were reported as case reports and 70 in case series. Included patients had previous history of Roux-en-Y gastric bypass (RYGB) (N=99), laparoscopic adjustable gastric banding (LAGB) (N=17), Scopinaro procedure (N=2), vertical banded gastroplasty (VBG) (N=1), one anastomosis gastric bypass
20 (OAGB) (N=1). Final diagnosis in 50 case reports was: internal hernia in 26 cases, bowel intussusception in 10, intestinal obstruction in 2, LAGB slippage in 3, bowel volvulus in 3, gastric or jejunal perforation in 2 and other in 4 cases. Maternal and fetal death occurred in 3 (2.5%) and 9 cases (7.5%), respectively. In the case series, the majority of women were operated for internal hernia and LAGB slippage.

25 Surgical complications of previous bariatric surgery during pregnancy have potentially severe
outcomes. Availability of multidisciplinary expertise, including bariatric/digestive surgeons,
and education of healthcare providers and women on clinical signs that require urgent
surgical examination are recommended in this setting. Prompt diagnosis is fundamental,
based on clinical and laboratory findings and on radiological examinations if needed,
30 including CT scan. Rapid surgical exploration is mandatory in case of high clinical and
radiological suspicion.

Keywords: bariatric surgery, pregnancy; surgery; emergency; gastric bypass; sleeve

35 gastrectomy; gastric banding

40

45

50 Introduction

Bariatric surgery in the last decades has emerged as the most effective treatment for morbid obesity, able to provide weight loss and resolution/amelioration of obesity-related diseases in a consistent percentage of patients, and to improve the expectancy and quality of life of obese patients ^{(1) (2) (3)(4)(5)}. Furthermore, technical advancements and increased surgeons' experience have allowed the widespread use of minimally invasive technique for bariatric procedures, and a diminution of the postoperative morbidity and mortality ⁽⁶⁾⁽⁷⁾.

Worldwide, it has been estimated that approximately 634 897 persons undergo bariatric procedures each year, with sleeve gastrectomy and gastric bypass accounting for 53.6% and 30%, respectively, of all procedures ⁽⁸⁾. Among operated patients, approximately half are women in reproductive age ^{(9) (10)}. The benefits of bariatric surgery in female patients of reproductive age include the improvement of the fertility ⁽¹¹⁻¹³⁾ and the reduction of the risk of severe obstetrical complications such as pregnancy-induced hypertension, preeclampsia, gestational diabetes, macrosomia and cesarean section ^(12,13).

Furthermore, bariatric surgery is associated with improvement or resolution of several obesity-related comorbidities, such as arterial hypertension, diabetes, sleep apnea syndrome, dyslipidemia⁽¹⁴⁾. Maternal obesity increases the risk for offspring in developing obesity and has an impact on the offspring's cardiometabolic health ⁽¹⁵⁾. Actually, if the fetus is exposed to the intrauterine environment associated with maternal obesity, lasting effects on the offspring's long-term metabolic health have been demonstrated, independent of genetic predisposition and postnatal environmental factors ⁽¹⁵⁻¹⁹⁾. Epidemiological studies have demonstrated that offspring born to obese mothers are at an increased risk of obesity, type 2 diabetes, cardiovascular disease, cerebrovascular disease, non-alcoholic fatty liver disease ^(16,20-26).

75 Findings from retrospective cohort studies in Helsinki indicated that maternal obesity in pregnancy is an important determinant of the risk of cardiovascular morbidity and mortality in the offspring ^(17,27). A large study using birth records in the UK showed that higher maternal BMI was associated with an increased risk of premature all-cause mortality (hazard ratio 1.35) and hospital admissions for cardiovascular events in adult offspring (hazard ratio 80 1.29) ⁽¹⁶⁾. These associations were independent of socioeconomic status and current age. In line with these findings, similar findings have been reported in the Helsinki Birth Cohort Study participants born 1934–44 and followed up between the years 1971 to 2010 ⁽¹⁹⁾. Cardiovascular disease, coronary heart disease, type 2 diabetes and stroke were all more common among offspring of obese mothers ⁽¹⁹⁾.

85 These studies have overwhelmingly supported the concept that maternal obesity has a role in programming the development of metabolic disease in adult and even aged offspring. Researchers have shown that the risk of developing obesity arises in fetal life, via altered epigenetic regulation of specific genes, in the intrauterine environment, that contributes to early nutritional fetal programming, increasing the risk of obesity and related diseases later in 90 life ⁽²⁶⁾. Guenard et al. ⁽²⁸⁾ have shown different methylation of genes involved in glucoregulatory and inflammatory diseases between siblings born before and after maternal bariatric surgery. Kral et al. ⁽²⁹⁾ have shown that siblings born after maternal surgery show lower prevalence of obesity, whereas Guenard et al. ⁽³⁰⁾ have shown less deviations in cardiometabolic risk markers via both differential gene methylation and expression patterns 95 in inflammatory pathways, compared to siblings born before maternal surgery. Berglind et al. ⁽²⁵⁾ studied women with at least one child born before and one after bariatric surgery in the Swedish national registers, analyzing blood samples of siblings for epigenetic methylation. They found that in total 3,074 genes, with corresponding 23,449 CpG methylation sites, were differently methylated and associated with an overrepresentation of differently methylated

100 CpG sites in genes involved with insulin receptor signaling, type 2 diabetes signaling, and
leptin signaling in obesity, when comparing siblings born before and after bariatric surgery
(²⁵). All these arguments are in favor of performing bariatric surgery before pregnancy, to
maximize the short and long-term health benefits for mothers and child. On the other hand,
bariatric surgery may have serious complications not allowing subsequent pregnancy (severe
105 surgical or nutritional complications, psychiatric complications including depression and
suicide). Furthermore, previous bariatric surgery is associated to an increase in small-for-
gestational-age infants (odds ratio, 2.16), intrauterine growth restriction (odds ratio, 2.16),
and preterm deliveries (odds ratio, 1.35) (¹²).

Pregnant women with history of bariatric surgery should be considered as a-high-risk group,
110 requiring special attention and considerations (³¹). Indeed, this subset of patients is exposed,
more than the general population of pregnant women, at potential medical and surgical
complications. The medical complications include micronutrient deficiencies (¹⁴) and the
increased risks of a small-for-gestational-age fetus and prematurity (¹²).

Furthermore, the pregnant status may favor the development of surgical complications of
115 previous bariatric surgery, via several factors including hyperemesis and increase in the
volume of the uterus and the abdominal pressure (³²). At first, complications of bariatric
surgery requiring surgical treatment during pregnancies have been reported as sporadic cases
(³³). Considering the large and increasing population of women of childbearing age with
history of bariatric surgery, surgical complications of bariatric surgery during pregnancy may
120 become more frequent in the future.

Surgical complications of bariatric surgery during pregnancies are potentially serious, and
may even lead to catastrophic outcomes including maternal and fetal deaths (³⁴). Indeed, their

diagnosis and management are challenging, and require knowledge and experience enclosing several disciplines.

125 The BARIA-MAT group is a French multidisciplinary research group including experts in all fields involved in the management of pregnant women with history of bariatric surgery, that provided national recommendations for clinical practice on the management of pregnancy in this subset of women according to a methodology including 1) a comprehensive literature search; 2) a series of workshops attended by members of the working group, and 3) an
130 amendment of the guidelines considering the opinions expressed by a large multidisciplinary reading group obtained through a critical reading ⁽³⁵⁾.

In the present study, the BARIA-MAT Study Group reports the systematic review of the English-language literature of all cases of pregnant women undergoing emergency surgery for complications related to previous bariatric surgery. The aim is to analyze the clinical
135 presentation, diagnostic procedures, and treatment of surgical complications of bariatric surgery during pregnancies, in the effort to share knowledge on this subject and to discuss the best management of these complex cases.

140

145 **Materials and Methods**

Protocol approval

The systematic review design was approved by the BARIA-MAT study group, a French study created for research on pregnancy in women with previous bariatric surgery⁽³⁵⁾. No
150 ethical approval was needed in consideration of the type of study.

Study selection

A systematic literature search was performed using Embase, Medline, Cochrane, and PubMed databases to identify all studies published up to and including December 2018 that included women with previous bariatric surgery undergoing emergency surgery during
155 pregnancy. The systematic review was conducted according to the PRISMA guidelines⁽³⁶⁾.

The following MESH search headings were used (last search December 26, 2018):

“pregnancy AND bariatric”; “pregnancy AND gastric bypass”; “pregnancy AND sleeve
gastrectomy”; “pregnancy AND gastric banding”; “pregnancy AND biliopancreatic
diversion”; “pregnancy AND vertical banded gastroplasty”, “bariatric surgery AND
160 pregnancy AND complications”; “gastric bypass AND pregnancy AND complications”;
“sleeve gastrectomy AND pregnancy AND complications” ; “gastric banding AND
pregnancy AND complications”; “bariatric surgery AND pregnancy AND emergency
surgery”; “gastric bypass AND pregnancy AND emergency surgery”; “sleeve gastrectomy
AND pregnancy AND emergency surgery”; “gastric banding AND pregnancy AND
165 emergency surgery”.

The “related articles” function was used to broaden the search, and all abstracts, studies, and citations scanned were reviewed. Using the criteria of the PRISMA statement, two authors (NP and TD) independently searched the literature for relevant studies. A third author (JG) adjudicated conflicts.

170 *Inclusion and exclusion criteria*

The studies included had to report data about patients with previous history of bariatric surgery who underwent emergency surgery during pregnancy. All bariatric procedures were included. Studies reporting cases of complications of bariatric surgery during pregnancy not needing surgery were not included. Studies not clearly reporting the diagnosis and the
175 treatment of the surgical complications during pregnancy were not included. Non-English language studies were excluded.

Quality assessment

Quality assessment was performed according to the 8-item scale developed by Murad et al.
(37). As suggested, an overall judgment about methodological quality was done during the
180 study selection process.

Data extraction and outcomes of interest and definition

Data were extracted on the base of a piloted form and registered in a spreadsheet for comprehensive analysis. The two reviewers independently extracted the following information from each study: first author, year of publication, study design, study population
185 characteristics, type of previous bariatric procedure, signs and symptoms at admission, diagnosis and imaging findings, surgical treatment, maternal and fetal outcomes.

Clinical findings were synthesized through a narrative review with full tabulation of results of the included studies. Case report and case series were reported separately for several reasons:
a) they represent different types of study from a methodological point of view; b) case report
190 may present very rare and exceptional cases whereas case series usually report several observations of a less rare condition; c) the information that may be collected are different (and so it is their tabulation), because case reports usually provide detailed and complete information about the reported patient, whereas case series may not report data of every

single included patient but the mean or median values of the series, and single patients' data

195 may be less detailed.

200

205

210

215

Results

220

Study selection

Systematic search process is showed in Figure 1. Sixty-eight studies reporting data on surgical complications in pregnant women with previous history of bariatric procedures were retrieved with a systematic literature search ^{(33,34,38-80) (81-93)}. The included studies were
225 published between 1988 and 2018, and they were all retrospective. Forty-five of them were case reports including 50 patients, whereas 13 were patients' series including 70 women. Included patients had previous history of Roux-en-Y gastric bypass (RYGB) (N=99), laparoscopic adjustable gastric banding (LAGB) (N=17), Scopinaro procedure (N=2), vertical banded gastroplasty (VBG) (N=1), one anastomosis gastric bypass (OAGB) (N=1). The
230 systematic review included a total of 120 patients. Quality of case reports was judged as sufficient in all cases according to the 8-item scale proposed by Murad et al. ⁽³⁷⁾.

Case reports studies: 50 patients

Patients' characteristics and clinical presentation

Patients' characteristics of patients reported as case reports are detailed in Table 1. Mean age
235 was 30.3 years old. Previous bariatric surgery included RYGB in 40 cases, LAGB in 6, OAGB in 1, Scopinaro procedure in 2 and VBG in 1 case. Mean body mass index (BMI) was 30.4 kg/m². Mean gestational age at the time of emergency surgery was 27 weeks of gestation. Abdominal pain was among the symptoms at admission in 90% of cases, vomiting in 56%, and nausea in 52%.

Diagnostic methods

240

Results of blood test and imaging are reported in Table 2. Hyperleucocytosis was reported in 44.4% of cases providing the information. Among the imaging techniques, abdominal ultrasonography (US) was performed in 16 cases, and allowed a correct diagnosis in 2 cases, one with entero-enteral intussusception and the second with gastric pouch dilatation for LAGB slippage. Abdominal X-ray was performed in 7 cases but was never able to suggest the correct diagnosis. Six patients had abdominal magnetic resonance imaging (MRI), which was able to establish the diagnosis in 4 cases (66.7%). Computed tomography (CT) was performed in 25 cases and suggested the correct diagnosis or the indication for surgery in 23 patients (92%). Upper gastrointestinal endoscopy (GI) was performed in 10 patients with pathological findings in 6 cases (60%). Barium X-ray was done in one case suggesting mechanical obstruction in a case of stomach torsion on LAGB found at surgery. Final diagnosis in the 50 case reports was: internal hernia (IH) in 26 cases, bowel intussusception in 10, intestinal obstruction in 2, LAGB slippage in 3, bowel volvulus in 3, gastric or jejunal perforation in 2 and other in 4 cases.

255 *Surgical treatment*

The initial surgical approach consisted in a laparotomy in 31 cases, whereas laparoscopy was attempted in 19 patients. However, conversion to open surgery was needed in 9 of those patients. Among the 10 patients with intussusception, bowel resection was needed in 6 cases, whereas 4 cases were treated with simple reduction of the intussusception. Among the 26 patients with IH, 8 needed bowel resection for ischemia, whereas simple reduction of the herniated bowel and closure of the defect was performed in 17 cases. In one patient with extensive bowel necrosis, bowel resection was considered futile⁽⁶¹⁾. For LAGB complications, laparoscopic removal was possible in 4 cases, whereas one patient had removal during laparotomy. Surgical treatment of other less frequent complications is reported in Table 2.

Maternal and fetal outcomes

Maternal and fetal outcomes are fully reported in Table 2. Maternal death occurred in 3 cases, for extensive bowel necrosis due to IH at the 35th gestational week, ventricular fibrillatory arrest 3 hours after laparotomy and bowel resection for IH with bowel ischemia (31st week) and septic shock four days after laparotomy and bowel resection for volvulus with bowel necrosis (30th week), respectively. Non-fatal complications included sepsis and short bowel syndrome (1 case), sepsis (2 cases), pneumothorax (1 case), thrombosis of the superior mesenteric and iliac vein (1 patient), pneumonia and surgical site infection (1 case), wound infections or seroma (3 patients), urinary tract infection (1), pyelonephritis (1), lower extremity deep venous thrombosis and endometritis (1), relaparotomy (2). Fetal death occurred in 9 cases at a mean gestational age of 25.4 weeks. Non-fatal fetal complications included infant respiratory distress syndrome (IRDS) (1) and central nervous system hemorrhage (1). Thirty-nine children had uneventful recovery.

Case series: 70 patients

Patients' characteristics and clinical presentation

Table 3 reports data about the 13 series of surgical complications for pregnant women after bariatric surgery. Ten of them were monocentric series and 2 were series from National registries. One study included a single center series and a systematic review; only the original five cases were taken into account to avoid duplication of data with previously reported cases. Previous bariatric surgery consisted in RYGB in 59 patients and LAGB in 11 cases.

Diagnostic methods

Five series reported the information about the diagnostic methods. The diagnosis was mainly based on clinical suspicion and examination, with a selective use of CT or MRI. US was

mainly used to assess the conditions of the fetus. Upper gastrointestinal endoscopy was
290 selectively used.

Surgical treatment

For internal hernia, repair during laparoscopy or laparotomy was performed, with no bowel
resection needed in the majority of cases. For LAGB complications, removal of the LAGB
was the main operation, performed by a laparoscopic approach in the majority of cases. Cases
295 of concomitant cesarean section are reported in Table 3.

Maternal and fetal outcomes

The outcome was favorable in the majority of cases. Among patients with IH, one patient had
extensive bowel resection resulting in short bowel syndrome in the series by Vannevel et al.
(⁸²), one had extensive bowel necrosis and died in the series by Andreasen et al. (⁸⁶), and one
300 had bowel resection in the series by Santulli et al. (⁹¹). Adverse fetal outcomes included: I) 1
case of preterm rupture of membranes, grade II intraventricular hemorrhage, grade II
retinopathy of prematurity (ROP), and sepsis reported by Vannevel et al. (⁸²), II) 1 case of
preterm birth at 30 weeks of a baby with lip cleft palate and intestinal malformation, 3 weeks
after laparoscopy for IH reported by Gudbrand et al. (⁸³), III) 1 case of preterm delivery at 28
305 weeks, complicated by respiratory distress and bowel perforation requiring loop ileostomy
and reanastomosis before discharge reported by Altieri et al. (⁸⁴).

310

Discussion

Complications of previous bariatric surgery requiring emergency surgery during pregnancy are potentially serious and may lead to fatal maternal and/or fetal outcome.

315 The number of patients undergoing surgery during pregnancy for complications of bariatric procedure is expected to rise in the future, due to the increase in women of childbearing age with history of bariatric surgery. Stuart et al. estimated a rate of laparoscopy or laparotomy of 1.5% during the first pregnancy after bariatric procedures, versus 0.1% in the control group of pregnant obese patients without history of surgery ⁽³²⁾.

320 Complications of previous bariatric surgery requiring emergency surgery during pregnancy represent a peculiar condition, challenging in diagnosis and treatment, requiring a broad spectrum of competences to guarantee the best maternal and fetal outcomes.

325 Recommendations from National and International Societies on this subject are lacking. Only the European Association for the Study of Obesity for the Post-Bariatric Surgery Medical Management highlighted the need of thoroughly assess women with history of bariatric procedures and gastrointestinal symptoms during pregnancy keeping in mind a wide differential diagnosis list, including both obstetric complications as well as surgical complications relating to the primary bariatric procedure ⁽⁹⁴⁾. These guidelines recommend that women should be assessed by a bariatric surgeon, and diagnoses such as band slippage/erosion, herniation, small bowel obstruction and intussusception should be
330 considered ⁽⁹⁴⁾.

In this review, which is the first on this topic, to our knowledge, we collected 120 cases of women undergoing emergency surgery for complications of a previous bariatric procedure during pregnancy, analyzing the characteristics of this population, the diagnosis and

management, and the outcomes. Out of 50 case reports, the surgical complications during
335 pregnancy occurred less than 12 months after the bariatric procedure in 9 patients. Among the
previous bariatric procedures, the most frequent was RYGB, in 99 cases. Roux-en-Y gastric
bypass results in potential internal spaces that predispose to internal herniation, which can be
exacerbated by increased intra-abdominal pressure from a gravid uterus. Adjustable gastric
banding was the second most frequent procedure, resulting in 17 cases requiring surgery
340 mainly for LAGB slippage. We retrieved only anecdotal cases of complications after less
frequent used procedures such as VBG, OAGB and Scopinaro procedures, and no cases after
sleeve gastrectomy.

In the population of case reports, 28 out of 50 patients presented surgical complications
during the third trimester of pregnancy. The most frequent symptoms, as showed by our
345 review of previous cases, are abdominal pain, nausea, vomiting, that are very frequent in
pregnant patients, frequently do not necessitate any treatment, and then facilitate
misinterpretation of symptoms by healthcare professionals. Another cause of
misinterpretation of symptoms is that women during the third trimester of pregnancy are
systematically oriented to maternity emergency ward and initially evaluated by midwives
350 who are not always aware of specific complications of bariatric procedures during pregnancy.
Blood tests may show an inflammatory syndrome, or may be unremarkable in almost half of
cases, which may also be misleading in the diagnostic process. Radiological and diagnostic
examination included US, CT, MRI, X-ray, barium X-ray. US is useful to assess and monitor
the fetal status, however was able to establish the diagnosis of the emergency abdominal
355 condition only in 2 cases out of 16. CT scan was the most frequent and accurate diagnostic
tool, able to identify the abdominal complication in 23 cases out of 25. MRI is less available
than CT scan, in emergency setting, and it was performed in 6 patients, suggesting the
diagnosis in 4 cases. However, in two cases of IH, MRI was not able to establish the

diagnosis and it was considered as normal. Upper GI endoscopy has been performed in
360 patients with upper GI symptoms, such as epigastric pain and/or vomiting. It only allows the
exploration of the first segment of the bowel. In a few cases, it permitted clear visualization
of ischemic or necrotic proximal bowel, accelerating the surgical treatment. Abdominal X-ray
was performed in 8 patients, and was useful for the diagnosis only in one case of high
obstruction due to LAGB. Computed tomography, the most accurate diagnostic tool in the
365 literature reviewed, should be used early and preferentially in this patient group because the
delay and false hope of other modalities can result in delay in treatment, bowel necrosis and
patient and fetal death. A rapid CT scan with contrast enhancement is the best method to
diagnose internal hernia, intussusception, gastric or gastrojejunal perforation, volvulus, and
other causes of intestinal obstruction after RYGB, and to assess the bowel perfusion. In
370 patients with LAGB, X-ray may be useful to evaluate LAGB position, slippage, but CT scan
provides more detailed information about the perfusion or an eventual torsion of the stomach
on the LAGB. CT scan is indicated during pregnancy when a prompt and accurate diagnosis
is needed and where modalities that do not use ionizing radiation are unhelpful or unavailable
(⁹⁵). Furthermore, a radiation dose lower than 50 mGy is associated with a negligible risk for
375 the fetus; the mean radiation dose of CT scan has been reported to be 24 mGy in the series
pregnant patients by Goldberg et al. (⁹⁶).

The treatment of such complications should be prompt, because the delay may cause bowel
necrosis, with subsequent aggravation of the prognosis. Bowel resection is relatively
frequent, occurring in 20 out of 50 cases among the case reports studies. In the case series, 3
380 further cases of intestinal ischemia were collected. The two most frequent indications for
bowel resection were intestinal ischemia due to internal hernia or to jejunal intussusception.
A fully laparoscopic treatment of internal hernia and intussusception was possible only in 6
cases among the case reports, and attempted but converted to laparotomy in 7 patients.

Treatment of internal hernia consisted in reduction of the hernia, bowel resection in presence
385 of bowel necrosis, and closure of the defect. Intussusceptions were treated with reduction;
intestinal resection and anastomosis was associated in case of reduced viability of the
involved bowel. LAGB slippage was easily managed with laparoscopic removal in most cases.

The outcomes of the mother and the fetus were variable, ranging from smooth recovery
without any consequences, to serious short and long-term complications such as sepsis or
390 short bowel syndrome, to maternal and fetal deaths in most severe cases. Cases with worst
outcomes were related to bowel ischemia with diagnostic delay resulting in fetal death and
maternal short bowel syndrome⁽⁴⁴⁾, multiple abdominal procedures on the mother resulting in
fetal death⁽⁴⁵⁾, bowel ischemia resulting in fetal death or fetal severe complications
^(49,51,52,69,75), intrauterine fetal death due to delayed diagnosis of LAGB slippage⁽⁵³⁾,
395 prolonged maternal hospitalization with severe morbidity due to iterative abdominal surgeries
and bowel resections⁽⁵⁵⁾, maternal mortality for extensive bowel necrosis⁽⁶¹⁾, maternal and
fetal deaths due to late diagnosis of bowel ischemia^(33,34). Negative outcomes were related to
delayed treatment and/or misdiagnosis in the majority of cases.

Several aspects emerge from the analysis of the reviewed literature and should be
400 emphasized: 1) the importance of sharing knowledge and education among pregnant women
and healthcare professionals about potentially serious surgical complications related to
previous bariatric procedure and the clinical signs that require urgent clinical examination
during pregnancy; 2) the need of multidisciplinary expertise, including obstetricians and
abdominal/bariatric surgeons in case of intense gastrointestinal symptoms in pregnant
405 patients with history of bariatric surgery; 3) the need of rapid patients' management, to avoid
preventable bowel ischemia; 4) the importance of a prompt diagnosis, with the CT scan being
the most accurate exam in emergency setting; 5) the poor sensitivity of laboratory tests; 6) the
importance of rapid surgical exploration in case of high clinical and radiological suspicion of

a surgical complications (non-availability of imaging or bariatric surgeon should not delay
410 surgical exploration if clinical suspicion of a complication is strong).

Conclusions

Surgical complications of previous bariatric surgery during pregnancy represent a challenging
and complex clinical entity with potentially severe complications and outcomes. Availability
415 of multidisciplinary expertise, including bariatric/digestive surgeons, and education of
healthcare providers and pregnant women is recommended in this setting. Prompt diagnosis
is fundamental, and it should be based on clinical and laboratory findings and on radiological
examinations if needed, including CT scan. Rapid surgical exploration is mandatory in case
of high clinical and radiological suspicion of a surgical complication of previous bariatric
420 surgery in pregnant patients.

425

430 References

1. Gloy VL, Briel M, Bhatt DL, Kashyap SR, Schauer PR, Mingrone G, et al. Bariatric surgery versus non-surgical treatment for obesity: a systematic review and meta-analysis of randomised controlled trials. *BMJ*. 2013 Oct 22;347:f5934.
- 435 2. Schauer PR, Bhatt DL, Kirwan JP, Wolski K, Aminian A, Brethauer SA, et al. Bariatric Surgery versus Intensive Medical Therapy for Diabetes - 5-Year Outcomes. *N Engl J Med*. 2017 16;376(7):641–51.
3. Mingrone G, Panunzi S, De Gaetano A, Guidone C, Iaiconelli A, Nanni G, et al. Bariatric-metabolic surgery versus conventional medical treatment in obese patients with type 2 diabetes: 5 year follow-up of an open-label, single-centre, randomised controlled trial. *Lancet Lond Engl*. 2015 Sep 5;386(9997):964–73.
- 440 4. Schauer DP, Arterburn DE, Livingston EH, Coleman KJ, Sidney S, Fisher D, et al. Impact of bariatric surgery on life expectancy in severely obese patients with diabetes: a decision analysis. *Ann Surg*. 2015 May;261(5):914–9.
- 445 5. Hachem A, Brennan L. Quality of Life Outcomes of Bariatric Surgery: A Systematic Review. *Obes Surg*. 2016 Feb;26(2):395–409.
6. Debs T, Petrucciani N, Kassir R, Sejour E, Karam S, Ben Amor I, et al. Complications after laparoscopic sleeve gastrectomy: can we approach a 0% rate using the largest staple height with reinforcement all along the staple line? Short-term results and technical considerations. *Surg Obes Relat Dis Off J Am Soc Bariatr Surg*. 2018 Dec;14(12):1804–10.
- 450 7. Phillips BT, Shikora SA. The history of metabolic and bariatric surgery: Development of standards for patient safety and efficacy. *Metabolism*. 2018;79:97–107.
8. Angrisani L, Santonicola A, Iovino P, Vitiello A, Higa K, Himpens J, et al. IFSO Worldwide Survey 2016: Primary, Endoluminal, and Revisional Procedures. *Obes Surg*. 2018 Dec;28(12):3783–94.
- 455 9. Debs T, Petrucciani N, Kassir R, Iannelli A, Amor IB, Gugenheim J. Trends of bariatric surgery in France during the last 10 years: analysis of 267,466 procedures from 2005-2014. *Surg Obes Relat Dis Off J Am Soc Bariatr Surg*. 2016 Oct;12(8):1602–9.
10. Shekelle PG, Newberry S, Maglione M, Li Z, Yermilov I, Hilton L, et al. Bariatric surgery in women of reproductive age: special concerns for pregnancy. *Evid ReportTechnology Assess*. 2008 Nov;(169):1–51.
- 460 11. Kominiarek MA, Jungheim ES, Hoeger KM, Rogers AM, Kahan S, Kim JJ. American Society for Metabolic and Bariatric Surgery position statement on the impact of obesity and obesity treatment on fertility and fertility therapy Endorsed by the American College of Obstetricians and Gynecologists and the Obesity Society. *Surg Obes Relat Dis Off J Am Soc Bariatr Surg*. 2017 May;13(5):750–7.
- 465 12. Kwong W, Tomlinson G, Feig DS. Maternal and neonatal outcomes after bariatric surgery; a systematic review and meta-analysis: do the benefits outweigh the risks? *Am J Obstet Gynecol*. 2018 Jun;218(6):573–80.

13. Li Y. Epigenetic Mechanisms Link Maternal Diets and Gut Microbiome to Obesity in the Offspring. *Front Genet.* 2018;9:342.
- 470 14. Fouse T, Brethauer S. Resolution of Comorbidities and Impact on Longevity Following Bariatric and Metabolic Surgery. *Surg Clin North Am.* 2016 Aug;96(4):717–32.
15. Drake AJ, Reynolds RM. Impact of maternal obesity on offspring obesity and cardiometabolic disease risk. *Reprod Camb Engl.* 2010 Sep;140(3):387–98.
- 475 16. Reynolds RM, Allan KM, Raja EA, Bhattacharya S, McNeill G, Hannaford PC, et al. Maternal obesity during pregnancy and premature mortality from cardiovascular event in adult offspring: follow-up of 1 323 275 person years. *BMJ.* 2013 Aug 13;347:f4539.
17. Forsén T, Eriksson JG, Tuomilehto J, Teramo K, Osmond C, Barker DJ. Mother’s weight in pregnancy and coronary heart disease in a cohort of Finnish men: follow up study. *BMJ.* 1997 Oct 4;315(7112):837–40.
- 480 18. Schack-Nielsen L, Michaelsen KF, Gamborg M, Mortensen EL, Sørensen TIA. Gestational weight gain in relation to offspring body mass index and obesity from infancy through adulthood. *Int J Obes.* 2010 Jan;34(1):67–74.
19. Eriksson JG, Sandboge S, Salonen MK, Kajantie E, Osmond C. Long-term consequences of maternal overweight in pregnancy on offspring later health: findings from the Helsinki Birth Cohort Study. *Ann Med.* 2014 Sep;46(6):434–8.
- 485 20. Tanvig M. Offspring body size and metabolic profile - effects of lifestyle intervention in obese pregnant women. *Dan Med J.* 2014 Jul;61(7):B4893.
21. Lee KK, Raja EA, Lee AJ, Bhattacharya S, Bhattacharya S, Norman JE, et al. Maternal Obesity During Pregnancy Associates With Premature Mortality and Major Cardiovascular Events in Later Life. *Hypertens Dallas Tex* 1979. 2015 Nov;66(5):938–44.
- 490 22. Lahti-Pulkkinen M, Bhattacharya S, Wild SH, Lindsay RS, Räikkönen K, Norman JE, et al. Consequences of being overweight or obese during pregnancy on diabetes in the offspring: a record linkage study in Aberdeen, Scotland. *Diabetologia.* 2019 Aug;62(8):1412–9.
- 495 23. Gomes D, von Kries R, Delius M, Mansmann U, Nast M, Stubert M, et al. Late-pregnancy dysglycemia in obese pregnancies after negative testing for gestational diabetes and risk of future childhood overweight: An interim analysis from a longitudinal mother-child cohort study. *PLoS Med.* 2018;15(10):e1002681.
24. Hussen HI, Persson M, Moradi T. Maternal overweight and obesity are associated with increased risk of type 1 diabetes in offspring of parents without diabetes regardless of ethnicity. *Diabetologia.* 2015 Jul;58(7):1464–73.
- 500 25. Berglind D, Müller P, Willmer M, Sinha I, Tynelius P, Näslund E, et al. Differential methylation in inflammation and type 2 diabetes genes in siblings born before and after maternal bariatric surgery. *Obes Silver Spring Md.* 2016 Jan;24(1):250–61.
- 505 26. Adamo KB, Ferraro ZM, Brett KE. Can we modify the intrauterine environment to halt the intergenerational cycle of obesity? *Int J Environ Res Public Health.* 2012;9(4):1263–307.

27. Eriksson JG, Sandboge S, Salonen M, Kajantie E, Osmond C. Maternal weight in pregnancy and offspring body composition in late adulthood: findings from the Helsinki Birth Cohort Study (HBCS). *Ann Med*. 2015 Mar;47(2):94–9.
- 510 28. Guénard F, Deshaies Y, Cianflone K, Kral JG, Marceau P, Vohl M-C. Differential methylation in glucoregulatory genes of offspring born before vs. after maternal gastrointestinal bypass surgery. *Proc Natl Acad Sci U S A*. 2013 Jul 9;110(28):11439–44.
29. Kral JG, Biron S, Simard S, Hould F-S, Lebel S, Marceau S, et al. Large maternal weight loss from obesity surgery prevents transmission of obesity to children who were followed for 2 to 18 years. *Pediatrics*. 2006 Dec;118(6):e1644-1649.
- 515 30. Guénard F, Tchernof A, Deshaies Y, Cianflone K, Kral JG, Marceau P, et al. Methylation and expression of immune and inflammatory genes in the offspring of bariatric bypass surgery patients. *J Obes*. 2013;2013:492170.
31. Johansson K, Cnattingius S, Näslund I, Roos N, Trolle Lagerros Y, Granath F, et al. Outcomes of pregnancy after bariatric surgery. *N Engl J Med*. 2015 Feb 26;372(9):814–24.
- 520 32. Stuart A, Källen K. Risk of Abdominal Surgery in Pregnancy Among Women Who Have Undergone Bariatric Surgery. *Obstet Gynecol*. 2017;129(5):887–95.
33. Moore KA, Ouyang DW, Whang EE. Maternal and fetal deaths after gastric bypass surgery for morbid obesity. *N Engl J Med*. 2004 Aug 12;351(7):721–2.
- 525 34. Graubard Z, Graham KM, Schein M. Small-bowel obstruction in pregnancy after Scopinaro weight reduction operation. A case report. *South Afr Med J Suid-Afr Tydskr Vir Geneesk*. 1988 Jan 23;73(2):127–8.
35. Ciangura C, Coupaye M, Deruelle P, Gascoin G, Calabrese D, Cosson E, et al. Clinical Practice Guidelines for Childbearing Female Candidates for Bariatric Surgery, Pregnancy, and Postpartum Management After Bariatric Surgery. *Obes Surg*. 2019 Sep 6;
- 530 36. Shamseer L, Moher D, Clarke M, Ghersi D, Liberati A, Petticrew M, et al. Preferred reporting items for systematic review and meta-analysis protocols (PRISMA-P) 2015: elaboration and explanation. *BMJ*. 2015 02;350:g7647.
37. Murad MH, Sultan S, Haffar S, Bazerbachi F. Methodological quality and synthesis of case series and case reports. *BMJ Evid-Based Med*. 2018 Apr;23(2):60–3.
- 535 38. Moliere S, Cavillon V, Mesli Y. The case for magnetic resonance imaging in bowel obstruction during pregnancy: Intussusception in a pregnant woman with Roux-en-Y gastric bypass. *Am J Obstet Gynecol*. 2018 Aug 14;
39. Kannan U, Gupta R, Gilchrist BF, Kella VN. Laparoscopic management of an internal hernia in a pregnant woman with Roux-en-Y gastric bypass. *BMJ Case Rep*. 2018 Apr 19;2018.
- 540 40. Bhadra R, Somasundaram M, Nowak MM, Ravakhah K. A near-fatal case of intussusception and ischaemic perforation of stomach in first-trimester pregnancy: eight years after laparoscopic Roux-en-Y gastric bypass. *BMJ Case Rep*. 2018 Nov 28;11(1).
41. Warsza B, Richter B. Internal Hernia in Pregnant Woman after Roux-en-Y Gastric Bypass Surgery. *J Radiol Case Rep*. 2018 Jan;12(1):9–16.

- 545 42. Ongso YF, Beh HN. Gastric band tubing-related complication during pregnancy. *J Surg Case Rep*. 2017 Nov;2017(11):rjx241.
43. Arapis K, Tammaro P, Goujon G, Becheur H, Augustin P, Marmuse JP. Elevated plasma pancreatic enzyme concentrations after Roux-en-Y gastric bypass may indicate closed loop obstruction. *Ann R Coll Surg Engl*. 2017 Feb;99(2):e62–4.
- 550 44. Petrucciani N, Debs T, Ciampi D, Massalou D, Kassir R, Amor IB, et al. Rare Cause of Small Bowel Ischemia During Pregnancy After Roux-en-Y Gastric Bypass. *Obes Surg*. 2017;27(7):1879–81.
45. Nimeri A, Maasher A, Al Shaban T. Efferent limb obstruction and unexpected perforated marginal ulcer in a pregnant patient after one anastomosis gastric bypass/mini gastric bypass. *Surg Obes Relat Dis Off J Am Soc Bariatr Surg*. 2017 Apr;13(4):713–5.
- 555 46. de Raaff CAL, Eshuis WJ, van Wagenveld BA, van Veen RN. Complications of banded laparoscopic Roux-en-Y gastric bypass in a 33-week pregnant woman. *J Surg Case Rep*. 2016 Aug 25;2016(8).
47. Mortelmans D, Mannaerts D, Van den Broeck S, Jacquemyn Y, Hubens G. Intussusception in pregnancy after gastric bypass: a case report. *Acta Chir Belg*. 2016 Dec;116(6):379–82.
- 560 48. Reijnierse A, Burgers JA, Go AT, Zengerink JF, van der Weiden RM. Late complications of bariatric surgery in pregnancy. *JRSM Open*. 2016 Nov;7(11):2054270416660935.
49. Guilbaud T, Bouayed A, Ouaiissi M. Emergency reversal of gastric bypass for missed diagnosis of internal hernia and bowel ischemia in a pregnant woman. *Surg Obes Relat Dis Off J Am Soc Bariatr Surg*. 2016 Oct;12(8):e68–71.
- 565 50. Gruetter F, Kraljević M, Nebiker CA, Delko T. Internal hernia in late pregnancy after laparoscopic Roux-en-Y gastric bypass. *BMJ Case Rep*. 2014 Dec 23;2014.
51. Bokslag A, Jebbink J, De Wit L, Oudijk M, Ribbert L, Tahri S, et al. Intussusception during pregnancy after laparoscopic Roux-en-Y gastric bypass. *BMJ Case Rep*. 2014 Nov 18;2014.
- 570 52. Socas Macías M, Reguera Rosal J, Alarcón Del Agua I, Pérez Vega H, Morales-Conde S. Vomitting, pregnancy and gastric bypass: a bariatric emergency? *Cirugia Espanola*. 2014 Nov;92(9):626–7.
53. Jacquemyn Y, Meesters J. Pregnancy as a risk factor for undertreatment after bariatric surgery. *BMJ Case Rep*. 2014 Jan 9;2014.
- 575 54. Deront Bourdin F, Iannelli A, Delotte J. Phytobezoar: an unexpected cause of bowel obstruction in a pregnant woman with a history of Roux-en-Y gastric bypass. *Surg Obes Relat Dis Off J Am Soc Bariatr Surg*. 2014 Dec;10(6):e49-51.
55. Borghede MK, Vinter-Jensen L, Andersen JC, Mortensen PB, Rasmussen HH. Reconstruction of short bowel syndrome after internal hernia in a pregnant woman with previous bariatric surgery. *Int J Surg Case Rep*. 2013;4(12):1100–3.
- 580 56. Navarro JM, Molto M, Alcobilla E, Morcillo MA. Intestinal perforation in the immediate puerperium: A rare complication of bariatric surgery. *Rev Espanola Enfermedades Dig Organo Of Soc Espanola Patol Dig*. 2013 Jun;105(5):307–8.

57. Ranade A, Shah BC, Oleynikov D. Intussusception during pregnancy of a gastric bypass patient. *Surg Obes Relat Dis Off J Am Soc Bariatr Surg.* 2013 Oct;9(5):e84-85.
- 585 58. Leal-González R, De la Garza-Ramos R, Guajardo-Pérez H, Ayala-Aguilera F, Rumbaut R. Internal hernias in pregnant women with history of gastric bypass surgery: Case series and review of literature. *Int J Surg Case Rep.* 2013;4(1):44–7.
59. Pilone V, Di Micco R, Monda A, Villamaina E, Gentile M, Forestieri P. LAGB in pregnancy: slippage after hyperemesis gravidarum. Report of a case. *Ann Ital Chir.* 2012 Oct;83(5):429–32.
- 590 60. Polavarapu HV, Kurian A, Antanavicius G, Myers VS. Intraoperative fetal monitoring an invaluable tool in pregnant patients with internal hernia after gastric bypass and review of literature. *Surg Obes Relat Dis Off J Am Soc Bariatr Surg.* 2012 Jun;8(3):e40-42.
61. Renault K, Gyrtrup HJ, Damgaard K, Hedegaard M, Sørensen JL. Pregnant woman with fatal complication after laparoscopic Roux-en-Y gastric bypass. *Acta Obstet Gynecol Scand.* 2012 Jul;91(7):873–5.
- 595 62. Tuyeras G, Pappalardo E, Msika S. Acute small bowel obstruction following laparoscopic Roux-en-Y gastric bypass during pregnancy: two different presentations. *J Surg Case Rep.* 2012 Jul 1;2012(7):1.
63. Mohamed D, El Hadi A, Smajer B. Stomach torsion in pregnancy as a complication of laparoscopic adjustable gastric banding. *J Surg Case Rep.* 2012 Mar 1;2012(3):1.
- 600 64. Kang T, Richardson W. Late pregnancy should not delay abdominal exploration for internal hernia after gastric bypass surgery. *Am Surg.* 2011 Apr;77(4):502–3.
65. Naef M, Mouton WG, Wagner HE. Small-bowel volvulus in late pregnancy due to internal hernia after laparoscopic Roux-en-Y gastric bypass. *Obes Surg.* 2010 Dec;20(12):1737–9.
- 605 66. Rosenkrantz AB, Kurian M, Kim D. MRI appearance of internal hernia following Roux-en-Y gastric bypass surgery in the pregnant patient. *Clin Radiol.* 2010 Mar;65(3):246–9.
67. Gazzalle A, Braun D, Cavazzola LT, Wendt LR, Navarini D, Fauri M de A, et al. Late intestinal obstruction due to an intestinal volvulus in a pregnant patient with a previous Roux-en-Y gastric bypass. *Obes Surg.* 2010 Dec;20(12):1740–2.
- 610 68. Hooks WB, Westbrook AD, Clancy TV, Hope WW. Small bowel obstruction in a postpartum woman after laparoscopic Roux-en-Y gastric bypass. *Surg Obes Relat Dis Off J Am Soc Bariatr Surg.* 2010 Mar 4;6(2):209–10.
69. Efthimiou E, Stein L, Court O, Christou N. Internal hernia after gastric bypass surgery during middle trimester pregnancy resulting in fetal loss: risk of internal hernia never ends. *Surg Obes Relat Dis Off J Am Soc Bariatr Surg.* 2009 Jun;5(3):378–80.
- 615 70. Torres-Villalobos GM, Kellogg TA, Leslie DB, Antanavicius G, Andrade RS, Slusarek B, et al. Small bowel obstruction and internal hernias during pregnancy after gastric bypass surgery. *Obes Surg.* 2009 Jul;19(7):944–50.
71. Wax JR, Wolff R, Cobean R, Pinette MG, Blackstone J, Cartin A. Intussusception complicating pregnancy following laparoscopic Roux-en-Y gastric bypass. *Obes Surg.* 2007 Jul;17(7):977–9.
- 620

72. Ahmed AR, O'Malley W. Internal hernia with Roux loop obstruction during pregnancy after gastric bypass surgery. *Obes Surg.* 2006 Sep;16(9):1246–8.
73. Bellanger DE, Ruiz JF, Solar K. Small bowel obstruction complicating pregnancy after laparoscopic gastric bypass. *Surg Obes Relat Dis Off J Am Soc Bariatr Surg.* 2006 Aug;2(4):490–2.
- 625
74. Baker MT, Kothari SN. Successful surgical treatment of a pregnancy-induced Petersen's hernia after laparoscopic gastric bypass. *Surg Obes Relat Dis Off J Am Soc Bariatr Surg.* 2005 Oct;1(5):506–8.
75. Charles A, Domingo S, Goldfadden A, Fader J, Lampmann R, Mazzeo R. Small bowel ischemia after Roux-en-Y gastric bypass complicated by pregnancy: a case report. *Am Surg.* 2005 Mar;71(3):231–4.
- 630
76. Kakarla N, Dailey C, Marino T, Shikora SA, Chelmow D. Pregnancy after gastric bypass surgery and internal hernia formation. *Obstet Gynecol.* 2005 May;105(5 Pt 2):1195–8.
77. Erez O, Maymon E, Mazor M. Acute gastric ulcer perforation in a 35 weeks' nulliparous patient with gastric banding. *Am J Obstet Gynecol.* 2004 Nov;191(5):1721–2.
- 635
78. Ramirez MM, Turrentine MA. Gastrointestinal hemorrhage during pregnancy in a patient with a history of vertical-banded gastroplasty. *Am J Obstet Gynecol.* 1995 Nov;173(5):1630–1.
79. Tohamy AE, Eid GM. Laparoscopic reduction of small bowel intussusception in a 33-week pregnant gastric bypass patient: surgical technique and review of literature. *Surg Obes Relat Dis Off J Am Soc Bariatr Surg.* 2009 Feb;5(1):111–5.
- 640
80. Wang C-B, Hsieh C-C, Chen C-H, Lin Y-H, Lee C-Y, Tseng C-J. Strangulation of upper jejunum in subsequent pregnancy following gastric bypass surgery. *Taiwan J Obstet Gynecol.* 2007 Sep;46(3):267–71.
81. Petersen L, Lauenborg J, Svare J, Nilas L. The Impact of Upper Abdominal Pain During Pregnancy Following a Gastric Bypass. *Obes Surg.* 2017;27(3):688–93.
- 645
82. Vannevel V, Jans G, Bialecka M, Lannoo M, Devlieger R, Van Mieghem T. Internal Herniation in Pregnancy After Gastric Bypass: A Systematic Review. *Obstet Gynecol.* 2016 Jun;127(6):1013–20.
83. Gudbrand C, Andreasen LA, Boilesen AE. Internal Hernia in Pregnant Women After Gastric Bypass: a Retrospective Register-Based Cohort Study. *Obes Surg.* 2015 Dec;25(12):2257–62.
- 650
84. Altieri MS, Telem DA, Kim P, Gracia G, Pryor AD. Case review and consideration for imaging and work evaluation of the pregnant bariatric patient. *Surg Obes Relat Dis Off J Am Soc Bariatr Surg.* 2015 Jun;11(3):667–71.
85. Pilone V, Hasani A, Di Micco R, Vitiello A, Monda A, Izzo G, et al. Pregnancy after laparoscopic gastric banding: maternal and neonatal outcomes. *Int J Surg Lond Engl.* 2014;12 Suppl 1:S136-139.
- 655
86. Andreasen LA, Nilas L, Kjær MM. Operative complications during pregnancy after gastric bypass--a register-based cohort study. *Obes Surg.* 2014 Oct;24(10):1634–8.

- 660 87. Berlac JF, Skovlund CW, Lidegaard O. Obstetrical and neonatal outcomes in women following gastric bypass: a Danish national cohort study. *Acta Obstet Gynecol Scand.* 2014 May;93(5):447–53.
88. Facchiano E, Iannelli A, Santulli P, Mandelbrot L, Msika S. Pregnancy after laparoscopic bariatric surgery: comparative study of adjustable gastric banding and Roux-en-Y gastric bypass. *Surg Obes Relat Dis Off J Am Soc Bariatr Surg.* 2012 Aug;8(4):429–33.
- 665 89. Sheiner E, Edri A, Balaban E, Levi I, Aricha-Tamir B. Pregnancy outcome of patients who conceive during or after the first year following bariatric surgery. *Am J Obstet Gynecol.* 2011 Jan;204(1):50.e1-6.
- 670 90. Bebbler FE, Rizzolli J, Casagrande DS, Rodrigues MT, Padoin AV, Mottin CC, et al. Pregnancy after bariatric surgery: 39 pregnancies follow-up in a multidisciplinary team. *Obes Surg.* 2011 Oct;21(10):1546–51.
91. Santulli P, Mandelbrot L, Facchiano E, Dussaux C, Ceccaldi P-F, Ledoux S, et al. Obstetrical and neonatal outcomes of pregnancies following gastric bypass surgery: a retrospective cohort study in a French referral centre. *Obes Surg.* 2010 Nov;20(11):1501–8.
- 675 92. Patel JA, Patel NA, Thomas RL, Nelms JK, Colella JJ. Pregnancy outcomes after laparoscopic Roux-en-Y gastric bypass. *Surg Obes Relat Dis Off J Am Soc Bariatr Surg.* 2008 Feb;4(1):39–45.
93. Bar-Zohar D, Azem F, Klausner J, Abu-Abeid S. Pregnancy after laparoscopic adjustable gastric banding: perinatal outcome is favorable also for women with relatively high gestational weight gain. *Surg Endosc.* 2006 Oct;20(10):1580–3.
- 680 94. Busetto L, Dicker D, Azran C, Batterham RL, Farpour-Lambert N, Fried M, et al. Practical Recommendations of the Obesity Management Task Force of the European Association for the Study of Obesity for the Post-Bariatric Surgery Medical Management. *Obes Facts.* 2017;10(6):597–632.
95. Shetty MK. Abdominal computed tomography during pregnancy: a review of indications and fetal radiation exposure issues. *Semin Ultrasound CT MR.* 2010 Feb;31(1):3–7.
- 685 96. Goldberg-Stein S, Liu B, Hahn PF, Lee SI. Body CT during pregnancy: utilization trends, examination indications, and fetal radiation doses. *AJR Am J Roentgenol.* 2011 Jan;196(1):146–51.

690

Table 1. Case reports of surgical complications of previous bariatric surgery during pregnancy: patients' characteristics and clinical presentation

695 Table 2. Case reports of surgical complications of previous bariatric surgery during pregnancy: diagnosis, treatment, and maternal and fetal outcomes

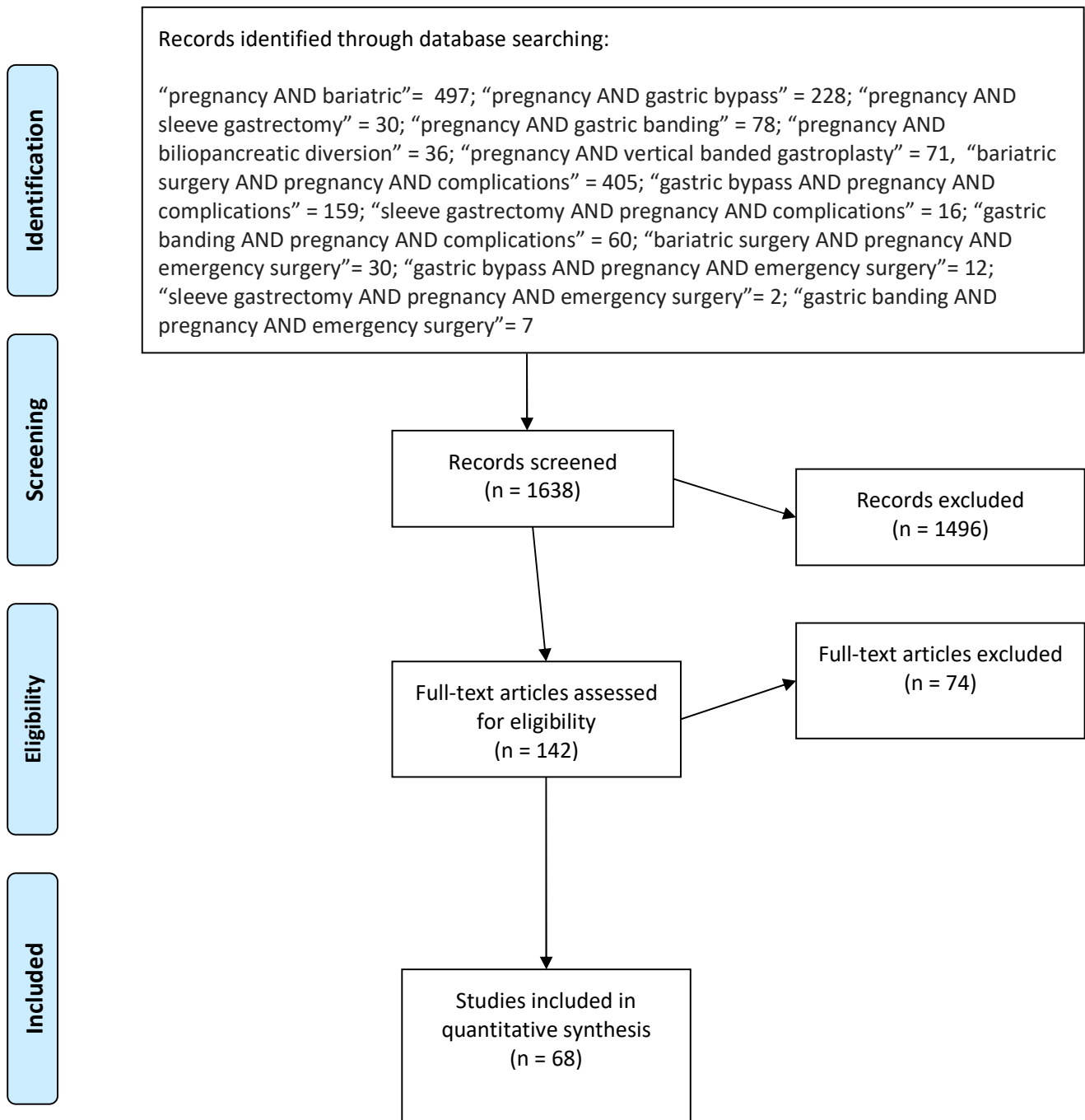
Table 3. Case series of surgical complications of previous bariatric surgery during pregnancy: disease's characteristics, diagnosis, treatment, and outcomes

Figure 1. Systematic search according to the PRISMA guidelines

700



PRISMA 2009 Flow Diagram



From: Moher D, Liberati A, Tetzlaff J, Altman DG, The PRISMA Group (2009). Preferred Reporting Items for Systematic Reviews and Meta-Analyses: The PRISMA Statement. PLoS Med 6(7): e1000097. doi:10.1371/journal.pmed1000097

For more information, visit www.prisma-statement.org.

Author, year	Type of study, N of included patients	Previous bariatric procedure	Age	BMI	Gestational week at admission	Clinical presentation	Final diagnosis
Bhadra, 2018	Case report, 1	RYGB 9 years before	40	nr	First trimester	Worsening abdominal pain	Jejunal intussusception with necrosis and ischemic perforation and necrosis of the gastric fundus
Moliere, 2018	Case report, 1	RYGB 4 years before	26	nr	27	Persistent abdominal pain and vomiting	Jejunojejunal intussusception
Kannan, 2018	Case report, 1	RYGB 3 years before	30	nr	21	Abdominal pain	IH at the jejunojejunostomy defect
Warsza, 2018	Case report, 1	RYGB 7 years before	37	nr	31	Acute diffuse epigastric pain and nausea, tachypnea	IH at the jejunojejunostomy defect with herniated common channel and volvulus
Ongso, 2017	Case report, 1	AGB 4 years before	27	25.9	6	Severe colicky periumbilical pain since 3 days, nausea	Small bowel obstruction on the AGB tubing
Arapis, 2017	Case report, 1	RYGB 2 years before	32	27	25	Abdominal pain since 2 days, nausea and vomiting, tachycardia	Intussusception at the jejunojejunostomy with short-segment bowel necrosis
Petruciani, 2017	Case report, 1	RYGB 6 years before	29	33.3	24	Intense abdominal pain with sudden onset	SMA thrombosis with small bowel ischemia
Nimeri, 2017	Case report, 1	OAGB/MGB	33	46	36	Bile reflux, inability to tolerate food, malnutrition	Efferent limb obstruction and marginal ulcer
de Raaff, 2016	Case report, 1	Banded RYGB 6 months before	30	37.5	33	Epigastric pain with radiation to the back	Slippage of the AGB with small bowel obstruction
Mortelmans, 2016	Case report, 1	RYGB in 2004	29	28.1	33	Acute abdominal pain with coffee-ground vomiting since one day	Intussusception of the proximal common loop into the entero-enteral anastomosis
Reijnierse, 2016	Case report, 1	RYGB 6 years before	29	nr	25	Acute intermittent abdominal pain with vomiting and nausea	IH at the Petersen space
Guilbaud, 2016	Case report, 1	RYGB 2 years before	36	nr	17	Abdominal pain and vomiting, hematemesis	IH at the Petersen space with necrosis of the Roux limb including the gastrojejunostomy and jejunojejunostomy
Gruetter, 2014	Case report, 1	RYGB 3 years before	27	nr	Late pregnancy	Crampy abdominal pain in the right flank	IH at the mesojejunal space with herniated common channel and volvulus of the anastomosis
Bokslag, 2014	Case report, 2	- RYGB 7 months before - RYGB 9 years before	24 28	30.7 25.7	34 24	- Abdominal pain, nausea - Abdominal pain, nausea	- Retrograde intussusception with perforation - Retrograde intussusception
Socas Macias, 2014	Case report, 1	RYGB 15 months before	35	nr	23	Persistent vomiting and malaise	IH at the Petersen space with bowel ischemia
Jacquemyn, 2014	Case report, 1	AGB 1 year before	30	nr	20	Persistent vomiting	AGB slippage
Deront	Case report, 1	RYGB 2 years before	33	36	9	Abdominal pain,	Jejunal phytobezoar

Bourdin, 2014		years before					nausea, vomiting	
Borghede, 2013	Case report, 1	RYGB 11 months before	22	nr	26		Sudden onset of abdominal pain	IH at the Peterson space with bowel necrosis
Navarro, 2013	Case report, 1	Scopinaro procedure 9 years before	30	33	36		Cramping abdominal pain and vomiting	Jejunioileal anastomosis perforation
Ranade, 2013	Case report, 1	RYGB 10 years before	27	24.6	33		Acute onset of epigastric pain and vomiting	Intussusception with bowel ischemia
Leal Gonzalez, 2013	Case reports, 2	- RYGB 2 years before - RYGB 7 years before	29 38	nr nr	37 26		- Severe abdominal pain in right hypocondrium - 48-h history of abdominal pain and nausea	IH at the Peterson space IH at the Peterson space
Pilone, 2012	Case report, 1	AGB 3 years before	25	22.2	13		Vomiting	Slippage of the AGB
Polavarapu, 2012	Case report, 1	RYGB 4 years before	28	nr	33		Severe abdominal pain, nausea, vomiting	IH at the Peterson space with reversible bowel ischemia
Renault, 2012	Case report, 1	RYGB 4 months before	22	26	35		Severe abdominal pain, nausea, vomiting, diarrhea	IH with extensive bowel necrosis
Tuyeras, 2012	Case report, 2	- RYGB 4 years before - AGB 7 years before	33 34	34 48	17 31		Acute epigastric pain, nausea, vomiting Abdominal pain	Retrograde intussusception IH at the mesojejunal space
Mohamed, 2012	Case report, 1	AGB in 2007	25	nr	29		Persistent vomiting and abdominal pain	Stomach torsion on AGB
Kang, 2011	Case report, 1	RYGB 3 years before	37	nr	33		Epigastric pain, nausea, vomiting	IH at the mesojejunal space
Naef, 2010	Case report, 1	RYGB 2 years before	34	26.8	35		Crampy abdominal pain	IH at the mesojejunal space
Rosenkrantz, 2010	Case report, 1	RYGB 6 years before	27	nr	18		Left upper quadrant abdominal pain, nausea, emesis	IH at the Petersen space
Gazzalle, 2010	Case report, 1	RYGB 2 years before	38	nr	33		Epigastric pain, nausea, anorexia	Small bowel volvulus with necrosis
Hooks, 2010	Case report, 1	RYGB 4 years before	38	nr	36		Nausea, vomiting, abdominal pain	Volvulus of the jejunojunal anastomosis with bowel necrosis
Efthimiou, 2009	Case report, 1	RYGB 9 years before	26	22	24		8-day history of colicky abdominal pain, nausea and vomiting	IH at the Petersen space with alimentary limb ischemia
Torres-Villalobos, 2009	Case reports, 2	RYGB 17 months before RYGB 28 months before	25 27	nr nr	32 30		- 5 days of postprandial epigastric pain, nausea, vomiting - severe abdominal pain since 48 h	IH at the Petersen space IH at the Petersen space

Tohamy, 2009	Case report, 1	RYGB in 2004	25	nr	33	Bilious vomiting and abdominal pain	Small bowel intussusception
Wang, 2007	Case report, 1	RYGB 2 months before pregnancy	32	30.4	37	Persistent epigastric pain, nausea and vomiting	IH with bowel necrosis
Wax, 2007	Case report, 1	RYGB 1 year before	35	nr	21	Sharp intermittent upper abdominal pain, nausea	Small bowel intussusception
Ahmed, 2006	Case report, 1	RYGB 8 months before	26	nr	30	24-hours history of cramping abdominal pain, nausea, vomiting	IH through the transverse mesocolic rent
Bellanger 2006	Case report, 1	RYGB 2 years before	25	25	33	Left flank pain, hematuria	IH at the jejunojejunostomy mesenteric space
Baker, 2005	Case report, 1	RYGB 10 months before	33	nr	25	Acute onset of left upper quadrant abdominal pain and nausea	IH at the Petersen space
Charles, 2005	Case report, 1	RYGB 6 months before	23	nr	25	1-day history of sudden diffuse abdominal pain and vomiting	IH at the Petersen space with bowel necrosis
Kakarla, 2005	Case reports, 2	- RYGB 18 months before - RYGB 9 months before	33 35	nr nr	12 34	6-week history of a periumbilical and left upper quadrant pain with nausea - 2-day history of epigastric pain, nausea, vomiting, decreased appetite	IH at the Petersen space IH at the mesenteric space
Erez, 2005	Case report, 1	AGB 2 years before	27	26	35	Vomiting and abdominal pain	Gastric ulcer perforation
Moore, 2004	Case report, 1	RYGB 18 months before	41	nr	31	Epigastric pain, nausea, vomiting	IH with bowel necrosis
Ramirez , 1995	Case report, 1	VBG 4 years before	28	nr	26	2-day complaint of abdominal cramps with hematemesis	Erosion of the esophagogastric junction by the synthetic graft of the previous VBG
Graubard, 1988	Case report, 1	Scopinaro procedure 3 years before	32	nr	30	3-day history of epigastric pain, nausea, vomiting, constipation	Small bowel volvulus with bowel necrosis and perforation
Total	50	RYGB = 40 AGB = 6 OAGB/MGB = 1 Scopinaro = 2 VBG=1					IH=26; intussusception=10; intestinal obstruction=2; AGB slippage=3; bowel volvulus=3; gastric or jejunal perforation=2; other=4

N, number; BMI, body mass index; RYGB, Roux en Y Gastric Bypass; IH, internal hernia; AGB, adjustable gastric banding; OAGB/MGB, one anastomosis gastric bypass/mini gastric bypass; VBG, vertical banded gastroplasty; SMA, superior mesenteric artery

Author, year	Laboratory findings	Endoscopic and Radiological findings	Surgical treatment	Maternal Outcome	Fetal Outcome	Final diagnosis
Bhadra, 2018	nr	MRI= intussusception of small bowel with obstruction	Laparotomy with bowel resection, gastric resection	Uneventful	Uneventful	Jejunal intussusception with necrosis and ischemic perforation and necrosis of the gastric fundus
Moliere, 2018	nr	US= not diagnostic; MRI= target sign centered by mesenteric vessels, diagnostic of intussusception	Laparotomic reduction of the intussusception	Uneventful	Uneventful	Jejunojunal intussusception
Kannan, 2018	nr	CT= suggestive of IH	Laparoscopic reduction and defect closure	Uneventful, discharged at POD 3	Uneventful, birth at term	IH at the jejunojunostomy defect
Warsza, 2018	WBC normal; lactate 1.4 mmol/L	Rx= dilated bowel loops in the epigastrium CT=suggestive of IH, abdominal fluid	Laparoscopic converted to laparotomic reduction of the hernia and closure of the defect	Uneventful, discharged at POD 7	Uneventful, birth at term	IH at the jejunojunostomy defect with herniated common channel and volvulus
Ongso, 2017	WBC 8.3x10 ⁹ /L CRP 22 mg/l	US= normal	Laparoscopic AGB removal	Uneventful, discharged at POD 1	Uneventful, birth at term	Small bowel obstruction on the AGB tubing
Arapis, 2017	WBC 20x10 ⁹ /L CRP 108 mg/l, lipase 537 u/L	US= normal Upper GI endoscopy= normal CT at 48 h= intussusception at the jejunojunostomy	Laparotomic resection and revision of the jejunojunostomy, gastrotomy for gastric decompression	Uneventful, discharged at POD 15	Uneventful, birth at term	Intussusception at the jejunojunostomy with short-segment bowel necrosis
Petruciani, 2017	WBC 40.1x10 ⁹ /L	US= perihepatic and perisplenic fluid CT = SMA thrombosis, bowel ischemia	Percutaneous angiography (failed), laparotomy with aorto-mesenteric bypass. 24h later, re-laparotomy, extensive bowel resection, fetus extraction	Septic shock, discharged at POD 16 from the ICU. Short bowel syndrome at long-term needing TPN	Fetal death	SMA thrombosis with small bowel ischemia
Nimeri, 2017	nr	US= reduced amniotic fluid Upper GI endoscopy=	Conversion to RYGB, gastrostomy	Uneventful recovery, but after several weeks	Fetal death	Efferent limb obstruction and marginal ulcer

		marginal ulcer and efferent limb obstruction		bowel obstruction for adhesions and IH at the Petersen defect, treated laparoscopically. Full recover 6 months after		
de Raaff, 2016	WBC 9.1x10 ⁹ /L CRP 36 mg/l	CT= dislocation of the ring with possible intestinal herniation of and bowel dilatation	Laparoscopic removal of the ring	Uneventful, discharged at POD 1	Uneventful, birth at term	Slippage of the AGB with small bowel obstruction
Mortelmans, 2016	WBC 18.7x10 ⁹ /L CRP 7.8 mg/l	US=entero-enteral intussusception over a length of 10cm without major fluid effusion	Laparotomy, incision of the entero-enteral anastomosis, reduction of the intussusception, closure of the enterotomy. Urgent CS after 7 hours	Wound infection, discharge at POD 10 in good conditions	Transfer in ICU after the CS, but no complication	Intussusception of the proximal common loop into the entero-enteral anastomosis
Reijnierse, 2016	WBC 10.8x10 ⁹ /L	MRI= no free fluid, no abnormalities Upper GI endoscopy= ischemia at the jejunum after passing the Roux limb	Laparotomic reduction of the bowel with no need for resection and closure of the Petersen defect	Uneventful, discharged at POD 4	Uneventful, birth at 38.4 weeks	IH at the Petersen space
Guilbaud, 2016	Inflammatory syndrome	Upper GI endoscopy= necrosis of the gastrojejunostomy CT= Roux-limb strangulation with ischemia and abdominal fluid	Laparotomy, bowel resection (1.5 m) including the gastrojejunostomy and jejunojejunostomy. Reversal of RYGB	Uneventful, discharge at POD 12	Fetal death, extraction at POD 3	IH at the Petersen space with necrosis of the Roux limb including the gastrojejunostomy and jejunojejunostomy
Gruetter, 2014	normal	US= right hydronephrosis	Laparoscopy converted to laparotomy,	Urinary tract infection,	Uneventful	IH at the mesojejunal space with herniated common channel and volvulus of the

			reduction of the IH, closure of the defect	discharge at POD 10		anastomosis
Bokslag, 2014	- Urinary tract infection - nr	- Obstetric US: fetal bradycardia - MRI = diagnosis of intussusception	- Emergency CS + laparotomy and resection of the intussuscepted bowel and anastomosis - laparoscopy converted to laparotomy, resection of the intussuscepted bowel and anastomosis, spontaneous vaginal delivery 7 days after	- Complicated by wound infection, discharged at POD 14 - pneumonia and wound infection, discharged at POD 17	- Admission to ICU, full recover and discharged at POD 14 - 2 girls admitted to the ICU, 1 died 10 days after for necrotizing enterocolitis, 1 IRDS discharged after 11 weeks	- Retrograde intussusception with perforation - Retrograde intussusception
Socas Macias, 2014	No relevant alterations	X-ray = air-fluid levels in the left hypocondrium US= massive fetal hemorrhage CT=transmesenteric hernia with occlusion and ischemia	Laparoscopy converted to laparotomy, bowel resection	Uneventful, pregnancy interruption at POD 10, discharged at POD 15	CNS hemorrhage, voluntary interruption of the pregnancy	IH at the Petersen space with bowel ischemia
Jacquemyn, 2014	hypokalemia	CT scan (after fetal death)= AGB slippage	Laparoscopic removal of the AGB	nr	Intrauterine death at 23 weeks, interruption of the pregnancy	AGB slippage
Deront Bourdin, 2014	nr	CT=phytobezoar in the common limb, pregnancy	Laparotomy and enterotomy for removal of the phytobezoar	Uneventful, discharge at POD 5	Uneventful	Jejunal phytobezoar
Borghede, 2013	nr	US=gallbladder stones MRI=normal Upper GI endoscopy at POD 6= blood in the jejunum	Open cholecystectomy, reoperated at POD 5 for cholascos. At POD 13, laparotomy with bowel resection for necrosis and CS,	Infectious complications, pneumothorax, thrombosis of the superior mesenteric vein and iliac veins, discharged	CS, deliver of a premature girl of 2010g	Internal hernia at the Peterson space with bowel necrosis

			reoperation during the next days with further small bowel resections	4 months later with TPN		
Navarro, 2013	WBC 28.5x10 ⁹ /L, CRP 18.4 mg/dl, procalcitonin 3.2 ng/ml	CT= pneumoperitoneum, free fluid and diffuse thickening and distension of the small bowel	Laparotomy, primary closure of the perforation and lavage	Uneventful	Labor induction before surgery, no fetal complications	Jejunioileal anastomosis perforation
Ranade, 2013	WBC 14.9x10 ⁹ /L	Upper GI endoscopy= no findings CT= intussusception of the common channel	Laparotomy, bowel resection (20 cm) and anastomosis	Uneventful, discharged at POD 6	Vaginal delivery before surgery, no fetal complications	Intussusception with bowel ischemia
Leal Gonzalez, 2013	normal normal	- X-ray= multiple air-fluid levels - X-ray= multiple air levels and U-shaped distended loop	- Laparotomy, CS, reduction of the hernia, repair of the defect - Laparotomy, reduction of the hernia, repair of the defect	Uneventful, discharged at POD 2 Uneventful, discharge at POD 2	No complications Uneventful	IH at the Peterson space IH at the Peterson space
Pilone, 2012	nr	US=gastric pouch dilatation	Laparoscopic removal of the band	Uneventful, discharged at POD 2	No complications	Slippage of the AGB
Polavarapu, 2012	WBC 11.7x10 ⁹ /L	CT=dilated small bowel loops with pneumatosis	Laparoscopic converted to laparotomy, reduction of herniated bowel, closure of the defect, emergency CS	Uneventful	Uneventful	IH at the Peterson space with reversible bowel ischemia
Renault, 2012	WBC 20.5x10 ⁹ /L, CRP 223 mg/dl	X-ray=dilatation of the caecum US= ascites CT after the first surgery=small bowel obstruction with ischemia	CS with delivery of a healthy baby and laparotomy without pathological findings. At POD 3, second laparotomy with findings of IH and extensive bowel necrosis	Maternal death	No complications	IH with extensive bowel necrosis

Tuyeras, 2012	nr	- not done	- Laparoscopic reduction of the intussusception, laparotomy and small bowel resection	-Uneventful, discharged at POD 2	Uneventful	Retrograde intussusception
	nr	- CT scan= distended proximal small bowel, no IH; gastroscopy= no abnormalities of the gastrojejunal anastomosis	- Laparoscopy converted to laparotomy, reduction of the IH, closure of the defect	-at POD 4, relaparotomy for volvulus of the jejunojejunal anastomosis, fixed without the need of bowel resection	Uneventful	IH at the mesojejunal space
Mohamed, 2012	nr	US= no abnormalities Upper GI endoscopy= no abnormalities Barium swallow=mechanical obstruction	CS at 32 weeks. At POD 5, laparotomy with removal of the AGB	Uneventful	Prematurity but no complication	Stomach torsion on AGB
Kang, 2011	normal	US= no signs of fetal distress	Laparotomy, reduction of the hernia, closure of the defect	Uneventful	Normal vaginal delivery 6 weeks later	IH at the mesojejunal space
Naef, 2010	normal	US= free abdominal fluid	CS and laparotomy with reduction of the bowel and closure of the defect	Uneventful, discharged at POD 10	Uneventful, discharged at POD 10	IH at the mesojejunal space
Rosenkrantz, 2010	normal	MRI=IH at the Petersen space	Laparoscopic reduction of the bowel and closure of the defect	Uneventful, discharged at POD 1	Uneventful	IH at the Petersen space
Gazzalle, 2010	nr	US= gallbladder thickening, lithiasis, perihepatic fluid US at POD 1= fetal distress, intraperitoneal fluid	Laparoscopic cholecystectomy. At POD 1, induction of the labor. After the delivery, laparotomy with 1.5 m small bowel resection	ICU hospitalization but no major complications (only wound seroma), discharged at POD 15	No complication, discharge at 2 weeks	Small bowel volvulus with necrosis

			including the gastrojejunostomy and re-anastomosis			
Hooks, 2010	nr	CT= small bowel obstruction	Uncomplicated vaginal delivery. After two days, laparoscopic exploration converted to laparotomy, bowel resection and anastomosis	Uneventful, discharged at POD 6	No complication	Small bowel volvulus with necrosis
Efthimiou, 2009	WBC 2.6x10 ⁹ /L, Hb 9.2 g/dL	CT= suggestive of internal hernia	Laparotomy, resection of the alimentary limb (100 cm), reconstruction of the bypass. Deliver of a death fetus 16 hours after surgery	Uneventful, discharged at POD 6	Fetal death	IH at the Petersen space with alimentary limb ischemia
Torres-Villalobos, 2009	- WBC 3.5x10 ⁹ /L, Hb 9.3 g/dL, lipase 264 U/L - WBC 15.5x10 ⁹ /L, Hb 7.4 g/dL	- CT= partial small bowel obstruction, consistent with IH - CT= consistent with IH	- Laparotomy, reduction of the hernia and repair, endoscopic decompression of Roux limb - Laparotomy, reduction of the hernias, repair of the defects	Pyelonephritis at POD 6, discharge POD 11 Uneventful with discharge at POD 5	Uneventful vaginal delivery at 37 weeks Uneventful vaginal delivery at 40 weeks	IH at the Petersen space IH at the Petersen and mesenteric space
Tohamy, 2009	nr	CT= small bowel distension proximal to the jejunojunostomy, and intussusception	Laparoscopic reduction of the intussusception	Uneventful, discharged at POD 3	Uneventful vaginal delivery 5 weeks after	Small bowel intussusception
Wang, 2007	WBC 14.6x10 ⁹ /L, lipase 71 U/L, no other abnormality	US= negative for gallstones	Emergent CT followed by laparotomy, bowel resection (20 cm) and anastomosis	Uneventful, discharged at POD 9	No complications	IH with bowel necrosis
Wax, 2007	WBC 6.6x10 ⁹ /L, no abnormality	Not done	Laparoscopic reduction of the intussusception, lysis of adhesions, resection of	Uneventful, discharged at POD 1	No complications	Small bowel intussusception of the proximal limb into the jejunojunostomy

			the jejunal remnant			
Ahmed, 2006	normal	CT=abundance of Roux limb into the lesser sac	Laparoscopic reduction of the hernia, suture of the defect	Uneventful, discharged at POD 2	Uneventful at term	IH through the transverse mesocolic rent
Bellanger, 2006	WBC 9.8x10 ⁹ /L, Hb 10.9 g/dL, no other abnormality	Gallbladder US= normal CT=proximal jejunum small bowel obstruction	Laparotomy, reduction of the hernia with bowel resection and reanastomosis, closure of the defect	Uneventful, discharged at POD 5	Uneventful deliver at 39 weeks	IH at the jejunojejunostomy mesenteric space
Baker, 2005	normal	US= viable intrauterine pregnancy and normal gallbladder CT= proximal segment of jejunum turned on itself with mild proximal dilatation Upper GI contrast study= obstruction of the Roux limb	Laparoscopy converted to laparotomy, reduction of the hernia, closure of the defect	Uneventful	Uneventful deliver 3 months later	IH at the Petersen space
Charles, 2005	Normal	X-ray= non specific bowel gas pattern CT=unremarkable Upper GI endoscopy= ischemia of the alimentary limb	Laparotomy, resection of the afferent limb, reversal of bypass	Uneventful, discharged at POD 5	Postoperative spontaneous delivery of a non viable fetus	IH at the Petersen space with bowel necrosis
Kakarla, 2005	normal	- CT= atypical appearance in the mid upper abdomen suspicious for rotation of the small bowel - CT= left upper quadrant obstructive process	Laparoscopy, reduction of the hernia, repair of the defect Laparotomy, CS, reduction and repair of an internal, mesenteric	No complications Lower extremity deep vein thrombosis, endometri	Uneventful delivery at term Viable infant weighing 2.346 g	IH at the Petersen space IH at the mesenteric space

			loop hernia	s		
Erez, 2005	AST 57 U/L, ALT 41 U/L, Hb 16 g/dl, amylase 248 U/L	Not done	Laparotomy, CS, suture of the gastric ulcer and removal of the AGB	Uneventful	Uneventful	Gastric ulcer perforation
Moore, 2004	WBC 14.5x10 ⁹ /L, amylase 500 U/L	US=negative for gallstones; fetal death	Laparotomy, resection of 61 cm of gangrenous bowel, CS for evacuation of the fetus	Death 3 hours after surgery for ventricular fibrillatory arrest	Fetal death	IH with bowel necrosis
Ramirez, 1995	Hb 7.6 mg/dL	Endoscopy= active bleeding obscured by blood clots	Emergency CS for delivery of a 774 g infant. Laparotomy with gastrostomy, removal of the synthetic collar and closure of the gastrostomy	Uneventful	nr	Erosion of the esophagogastric junction by the synthetic graft of the previous VBG
Graubard, 1988	Amylase 3000 U/L	X-ray= dilated loops of bowel	Laparotomy, bowel resection with anastomosis, CS	Maternal death for septic shock at POD 4	Fetal death post- partum	Small bowel volvulus with bowel necrosis and perforation

CT, computed tomography; POD, postoperative day; IH, internal hernia; WBC, white blood cells; AGB, adjustable gastric banding; US, ultrasonography; CRP, C-reactive protein; ICU, intensive care unit; TPN, total parenteral nutrition; SMA, superior mesenteric artery; GI, gastrointestinal; Hb, haemoglobin; CS, cesarean section; MRI, magnetic resonance imaging; CNS, central nervous system; ALT, alanine amino transferase; AST, aspartate aminotransferase; IRDS, infant respiratory distress syndrome, nr, not reported, CNS central nervous system, TPN, total parenteral nutrition; VBG, vertical banded gastroplasty

Author, year	Type of study	Surgical complications	Diagnosis	Treatment	Maternal outcome	Fetal outcome
Petersen, 2017	Monocenter series of 139 pregnancies with history of RYGB	22 cases of IH	Clinical, non-systematic CT scan	Laparoscopic or laparotomic repair, no cases of bowel resection	5 CS performed in relation to abdominal surgery	nr
Vannevel, 2016 (only the 5 original cases taken into account to avoid duplication)	Monocenter series of 5 patients with history of RYGB (+ 47 cases in the literature)	5 cases of IH	US=4, normal; MRI=3, 2 of them pathologic; upper endoscopy =1, normal	Laparoscopic (3 cases) or laparotomic repair (2 cases), 1 case of extensive bowel resection	1 emergency CS; 1 case of short bowel syndrome	1 case of preterm rupture of membranes, grade II intraventricular hemorrhage, grade II ROP, sepsis
Gudbrand, 2015	Series of 23 patients from the Danish registry with history of RYGB	24 surgical explorations in 23 patients, 18 cases of IH	Clinical, US in one case, no CT/MRI	12 laparoscopic repairs; laparotomy in the remaining cases. No bowel resection needed	9 concomitant CS	1 preterm birth at 30 weeks of a baby with lip cleft palate and intestinal malformation, 3 weeks after laparoscopy for IH
Altieri, 2015	Monocentric series of 4 patients with history of RYGB	2 cases of IH, 2 cases of bowel obstruction	Clinical in 2 cases, CT scan in 2 cases	Laparoscopic treatment of IH or adhesions in 3 cases, laparotomy in 1 case	No complications	1 preterm delivery at 28 weeks, complicated by respiratory distress and bowel perforation requiring loop ileostomy and reanastomosis before discharge
Pilone, 2014	Monocenter series of 32 pregnant patients with history of AGB	1 AGB slippage at 1 trimester	nr	Surgery	Uneventful	Uneventful
Andreasen, 2014	Series of 286 pregnant patients after RYGB from the Danish registry	3 cases of IH	US=2, CT=1	Laparoscopic treatment of IH in 2 cases, laparotomy	1 maternal death following extended bowel necrosis	2 uneventful

				y in 1 case		
Berlac, 2014	Monocentric series of 415 pregnant patients with history of RYGB	12.5% of women admitted for abdominal pain; bowel ileus in 3 cases	nr	2 laparotomies for ileus and adhesions	Planned CS in 16.1% of patients	20.1% of babies admitted to neonatal ICU
Facchiano, 2012	Monocenter series of 36 pregnant patients with history of AGB or RYGB	1 case of AGB slippage	nr	AGB removal in one case	Uneventful	Uneventful
Sheiner, 2011	Monocenter series of 489 pregnancies after bariatric surgery	7 cases of AGB slippage	nr	Surgery in 7 cases of AGB slippage	nr	nr
Bebber, 2011	Monocenter series of 39 pregnant patients with history of RYGB	2 cases of IH	nr	Surgery in 1 case	nr	nr
Santulli, 2010	Monocenter series of 24 pregnant patients with history of RYGB	1 case of IH	nr	Surgery with small bowel resection	Rate of CS higher in patients with history of RYGB (25%)	Rate of neonates small for gestational age higher in patients with history of RYGB (8.3%)
Patel, 2008	Monocenter series of 24 pregnant patients with history of RYGB	1 case of IH, 1 case of bowel obstruction	nr	Laparoscopic reduction of the IH and closure of the defect (1), laparotomy and lysis of adhesions (1)	Uneventful	Uneventful
Bar-Zohar, 2006	Monocenter series of 74 pregnant patients with history of AGB	2 cases of AGB slippage	nr	Laparoscopic removal	Uneventful	Uneventful
Total	13 series	IH = 54; intestinal obstruction = 5; AGB slippage = 11				

RYGB, Roux en Y gastric bypass; CT, computed tomography; nr, not reported; IH, internal hernia; US, ultrasonography; X-ray= abdominal radiography; MRI, magnetic resonance imaging; CS, caesarian section; AGB, adjustable gastric banding; nr, not reported; ICU, intensive care unit, ROP, retinopathy of prematurity