

Title

Surgical reconstruction of the foramen tympanicum: what is known and how we do it.

Authors

Mélanie Pons ^{a *}, Jean-Christophe Lutz ^b, Nicolas Sigaux ^c, Laurent Tavernier ^d, Nicolas Graillon ^e, Aurélien Louvrier ^f.

a. Resident, Department of Oral and Maxillofacial Surgery, University Hospital of Besançon, Besançon, France; INSERM, EFS BFC, UMR1098, Interactions Hôte-Greffon-Tumeur/Ingénierie Cellulaire et Génique, University of Bourgogne Franche-Comté, Besançon, France. Electronic address: mpons@chu-besancon.fr.

b. MD-PhD, Department of Maxillofacial and Plastic Surgery, University Hospital and UFR Medicine of Strasbourg, Strasbourg, France; Laboratory of Engineering Science, Computer Science and Imaging, CNRS, ICUBE University of Strasbourg, Strasbourg, France; INSERM, Regenerative Nanomedicine Laboratory, UMR 1260, Faculty of Medicine, Strasbourg, France. Electronic address: jean-christophe.lutz@chru-strasbourg.fr.

c. MD, Department of Maxillofacial and Stomatology, Lyon-Sud Hospital Center, Pierre-Benite, France. Electronic address: nicolas.sigaux@chu-lyon.fr.

d. MD-PhD, Otorhinolaryngology, University Hospital of Besançon, France. Electronic address: ltavernier@chu-besancon.fr.

e. MD, Aix-Marseille University, IFSTTAR, LBA UMR T24, Department of Oral and Maxillofacial Surgery, CHU Conception, APHM, Marseille, France. Electronic address: nicolas.graillon@ap-hm.fr.

f. MD, Department of Oral and Maxillofacial Surgery, University Hospital of Besançon, Besançon, France; Medical Faculty, University of Franche-Comté, Besançon, France; INSERM, EFS BFC, UMR1098, Interactions Hôte-Greffon-Tumeur/Ingénierie Cellulaire et Génique, University of Bourgogne Franche-Comté, Besançon, France. Electronic address: alouvrier@chu-besancon.fr.

*Corresponding author.

Title

Surgical reconstruction of the foramen tympanicum: what is known and how we do it.

Authors

Mélanie Pons, Jean-Christophe Lutz, Nicolas Sigaux, Laurent Tavernier, Nicolas Graillon, Aurélien Louvrier.

Abstract

Defects affecting the anterior wall of the tympanal bone can result from trauma, infection, neoplasm or previous local surgery. An anatomic variation, namely the persistence of the foramen tympanicum, can also be encountered. When symptomatic, surgical reconstruction may be indicated. The aim of this study was to identify the surgical treatments of symptomatic foramen tympanicum found in the literature and detail our innovative reconstruction technique. A bibliographic research was conducted in PubMed database in March 2020, without time limitation. Papers dealing with surgical management of a foramen tympanicum were included. Data collected were the publication date, the number of patients, their age and gender, the symptoms and the surgical treatment performed. We report, in addition, the case of a symptomatic persistent foramen tympanicum in a 30-year-old man with a follow-up of 18-months. A total of 17 studies (n=23 patients) were included for analysis. The main reconstruction techniques were, in equal proportion, cartilage graft (30%) and insertion of a titanium mesh (30%). We carried out an iliac crest bone graft using a preauricular approach on a patient suffering from chronic tinnitus and fullness in the left ear resulting from a persistent foramen tympanicum, confirmed by clinical and radiological examinations. It allowed the complete resolution of symptoms and no complication such as temporomandibular ankylosis occurred. Based on the review of the literature, we believe this technique has the advantage of providing durable reconstruction thanks to osseointegration.

Keywords

Foramen tympanicum; foramen of Huschke; tinnitus; surgery; iliac crest graft; temporomandibular joint.

This research did not receive any specific grant from funding agencies in the public, commercial, or not-for-profit sectors.

The authors have no conflict of interest to declare.

Introduction

The temporomandibular joint (TMJ) is in close proximity to the external auditory canal (EAC). Anterior tympanal wall defects mostly result from injuries and cholesteatoma (1). Infection, neoplasms or perforation during TMJ arthroscopy have also been previously reported (2) as a cause of TMJ herniation into the EAC. The tympanal bone is formed by an anterior and a posterior prominence growing towards each other and merging during the first year of life, thereby delineating the foramen tympanicum (FT). During growth, the FT becomes smaller and is usually closed by ossification before the age of five (3-6). Failure of fusion of the FT is a congenital condition of dehiscence of the EAC, also known as Huschke's foramen (7). Over time, the mechanical influence of masticatory movements may enlarge the defect (8). This could explain why such a congenital condition only reveals in adults. Subsequent symptoms are nonspecific, including either TMJ or otologic patterns such as tinnitus, otalgia, otorrhea, hearing loss and aural fullness (9). In symptomatic patients, surgery may be required to close the defect. The aim of this study was to report the surgical treatments of the FT found in the literature and detail our innovative reconstruction technique of this defect.

Material and methods

A bibliographic research was conducted in March 2020 in PubMed, without time limitation, employing "foramen tympanicum" or "foramen of Huschke" and "surgery" as search terms. Papers written in English as the language of publication, dealing with surgical management of a FT were included. Articles without available on-line abstracts were excluded. References of included studies were also searched to identify any relevant articles. For each selected article, we recorded the publication date, the number of patients, their age and gender, the symptoms and the surgical procedure. We report the case of a symptomatic persistent FT in a 30-year-old man with a follow-up of 18-months. This retrospective study was granted an exemption from the local institutional review board. The patient gave written informed consent for the publication of his case in agreement with the Declaration of Helsinki.

Results

Review of the literature

The study identification process is summarized in Figure 1. Through the research on Pubmed, 53 articles were initially identified. After screening of the abstracts, 31 were selected, and 13 met the inclusion criteria after full text reading. A further 4 articles were identified through references of these papers. Thus, a total of 17 studies were included for analysis. The characteristics of the included studies are presented in Table 1. The dates of publication ranged from 2000 (3) to 2019 (10). Overall, 23 patients (16 males and 7 females) were treated. The average age of patients was 53 years (ranging

from 35 to 73 years). Surgical approach used was: preauricular in 61% of the cases (n=14) (1,3,4,10-16), endaural in 26% (n=6) (1,8,17,18), postauricular in 9% (n=2) (19,20) and was not documented in one case (21).

The two main surgical reconstruction techniques were cartilage graft (tragal or conchal cartilages) in 30% (n=7) (4,8,11,12,18-20) as well as insertion of a titanium mesh (30%, n=7) (1,14,17). To a lesser extent, collagen mesh was used in 1 case (16), isolated temporoparietal fascia flap in 1 case (15), and skin graft in 2 cases (1). Combined techniques were also used as follow: cartilage graft and temporoparietal fascia flap in 2 cases (13,21), polypropylene implant and titanium miniplate in 2 cases (3), polypropylene implant with cartilage graft and titanium mesh in 1 case (10).

Illustrative case

A 30-year-old man was referred to our department for chronic tinnitus and aural fullness of the left ear. The symptoms, worsened by mouth opening, had increased over the previous two years, causing daily discomfort, and therefore becoming unbearable for the patient. He denied other otologic or facial symptoms and medical history found no trauma, ear infection, surgery or neoplastic disease. On the left side, otoscopic examination found a mobility of the anterior wall of the EAC in relation to mouth opening and closing. A CT scan was performed with 0.6 mm slice thickness and showed a tympanic bone defect between the EAC and the TMJ measuring 3.4 x 3.6 mm, respectively in the axial (Fig. 2A) and sagittal planes (Fig. 2B) attributed to a persistent FT.

The surgical procedure was carried out under general anesthesia. A preauricular approach, assisted by intraoperative tympanoscopy (Hopkins® Telescope, Storz, Tuttlingen, Germany), allowed accurate localization of the bone defect on the anterior wall of the EAC. The TMJ capsule was detached from the zygomatic arch in order to expose the superior compartment of the TMJ and to identify the tympanic bone defect avoiding injury of the disc and the mandibular condyle.

An iliac crest bone graft was harvested using a piezoelectric device (Piezosurgery® plus, Mectron, Loreto, Italia) with a minimally invasive surgical approach which preserves the surrounding tissues and minimizes scarring. The bone graft was contoured to perfectly fit the tympanic bone defect, taking into account the concavity of the recipient site (Fig. 3A). In order to prevent displacement, the graft was held in place by an absorbable thread (Vicryl® 3.0, Ethicon Inc., Johnson & Johnson, NE, USA) tied through a hole drilled with the piezoelectric device in the bony EAC of the tympanic bone (Fig. 3B). Closure was performed after attaching the articular capsule to the periosteum of the zygomatic arch, on a suction drain placed above the capsular plane.

The otologic symptoms resolved immediately after surgery. No malocclusion was noted. Maximum inter-incisal opening was temporarily reduced (27 mm for 3 months) and progressively returned to normal (48 mm at 6 months) with physical

therapy. A CT scan, at 3 months postoperatively, showed a complete osseointegration of the bone graft with no sign of TMJ ankylosis (Fig. 4A and B). No recurrence was observed after an 18-month follow-up.

Discussion

Our study highlighted the role of bone grafts in FT closure, which promote a durable and stable reconstruction due to osseointegration, contrary to cartilage grafts and alloplastic materials which are, however, still more used.

Tympanal bone defects can be diagnosed from otoscopic or radiological findings (14). Symptoms are non-specific and the most commonly reported are otalgia (32%), otorrhea (32%), clicking tinnitus (20%), hearing loss (20%) and aural fullness (10%). Ten percent remain asymptomatic (9). Examination of the EAC during mouth movement is helpful because the herniation retracts with mouth opening. TMJ herniation is noted in 27% of the persistent FT (1) and is correlated with the size of the defect. According to the review of 985 CT scans, the mean size of the bony defect was 3.1 x 2.7 mm (1). Radiologic investigations should also look for salivary fistula, because communication between the parotid gland and the EAC through a persistent FT has been reported (22,23). The prevalence of persistent FT is estimated at 9% in radiologic studies (24). A recent meta-analysis showed a higher prevalence in cadaveric studies with a 21% rate (24), suggesting a variable percentage of undetectable persistent FT on imaging techniques.

According to literature (5,16), treatment depends on the severity of the symptoms. A conservative strategy is often considered when symptoms are trivial. It consists of anxiolytic medication, muscle relaxant and a soft diet (5,25,26). Surgical closure of the defect is required when significant symptoms appear. The aim of the surgical treatment is to restore the integrity of the EAC in order to preserve hearing and TMJ functions.

Two kinds of surgical approaches are mainly used; a preauricular approach providing access to the TMJ and an endaural approach exposing the anterior aspect of the temporal bone (25). The latter is usually preferred by ENT surgeons who harvest autologous cartilage from the same incision and use it as a reconstructive graft (8). It only allows small reconstructions because the material must be small enough to be inserted through the defect. According to Yoo et al. (17), an extended endaural approach allows an easy separation of the canal skin from the joint capsule, and a correct exposure of both the TMJ capsule and the EAC through a single surgical field. It allows the insertion of a small titanium mesh but leaves a postoperative external scar. In the present case, we performed a conventional preauricular approach, which is widely used according to literature (1,3,4,10-12,15,16). It provided an easy, quick, and wide access to the bony defect with an inconspicuous residual scar.

Various materials, such as tragal cartilage, temporoparietal fascia, polypropylene implant, collagen or titanium mesh, are used to repair the defect. Although cartilage allows autologous reconstruction, the surgical repair can be compromised by

graft displacement (16) or its resorption over time (4,8). A temporoparietal fascia flap seems to ensure a more reliable surgical outcome, especially when alloplastic reconstruction of the TMJ is associated (15). Recent alloplastic materials have become popular because they do not require tissue from a donor site. However, inert implants (such as Silastic®) do not allow a vascular growth and increase the risks of displacement and infection (27). High density porous polyethylene implants (Medpor®) may improve tissue ingrowth (3), but have a higher extrusion rate (27). In several cases, thin titanium meshes were used because they combine easy material management and sufficient solidity to prevent recurrence (1). In cases of salivary fistula, surgery should include the ligation of the fistula and the closure of the bony defect (22); without bone reconstruction, recurrence may occur (18). According to Gillies principle of “replacing like with like” (28), we used an iliac crest bone graft, to avoid a foreign body reaction with a minimal donor site morbidity. Reconstruction of the TMJ after traumatic injuries is a common cause of temporomandibular ankylosis. However, a recent review by Monteiro et al. (29) showed that bony reconstruction of the glenoid fossa was not responsible for ankylosis. The surgical procedure must be carried out in the upper compartment of the TMJ and respect the integrity of the articular disc as well as the condylar head. Vigorous physical therapy, aimed at rehabilitating the TMJ functions, probably help to prevent temporomandibular ankylosis. Such a bone graft ensures a solid and durable reconstruction because of optimal osseointegration, as shown by radiological control in our case.

Conclusion

Considered as an anatomic variation, the persistence of the FT is responsible for a communication between the TMJ and the EAC. In symptomatic patients, surgical reconstruction mainly involves cartilage grafts or alloplastic materials. We described an original surgical treatment of a symptomatic persistent FT using an iliac crest bone graft. This procedure resulted in the complete resolution of all the symptoms with an uneventful postoperative course and no recurrence after an 18-month follow-up. The main advantage of this autologous correction is the osseointegration of the graft, which considerably lowers the risks of displacement and infection encountered when using exogenous materials.

Table 1. Symptomatology and surgical treatment of foramen tympanicum in the literature.

M: male, F: female, PeA: Preauricular approach, PoA: Postauricular approach, EA: Endaural approach, ND: Non documented.

Authors	Age	Gender	Symptoms	Treatment
Anand, 2000 (3)	51	F	Hearing loss, painful clicking	Polypropylene implant (Medpor®) fixed by a titanium miniplate via PeA
	46	F	Pain, noises	
Kaftan, 2004 (19)	64	F	Otorrhea	Conchal cartilage graft via PoA
Rushton, 2005 (13)	59	M	Ear discharge	Temporalis fascia and tragal cartilage graft via PeA
Moriyama, 2005 (8)	41	M	Tinnitus, crunching sound	Tragal cartilage graft fixed with fibrin glue via EA
Park, 2010 (1)	54	M	Aural fullness, clicking tinnitus	Titanium mesh via PeA
	48	M	Aural fullness, clicking tinnitus, hearing loss	“
	50	M	Aural fullness, clicking tinnitus, hearing loss	“
	73	F	Tinnitus, hearing loss	“
	56	M	Otalgia, otorrhea	Skin graft via EA
	61	M	Aural fullness, hearing loss, otorrhea	“
Akcam, 2011 (4)	48	F	Clicking sound, aural fullness	Tragal cartilage graft via PeA
Ajduk, 2012 (11)	53	F	Otorrhea	Tragal cartilage graft via PeA
Nakasato, 2013 (21)	61	M	Crunching sound	Auricular cartilage graft fixed by fibrin glue and temporalis fascia flap, approach ND
Bernstein, 2015 (12)	58	F	Aural fullness, otorrhea	Conchal cartilage graft via PeA
Shapiro, 2016 (15)	54	M	Otalgia, tinnitus	Discectomy, alloplastic reconstruction of the condyle, temporoparietal fascia flap via PeA
Yoo, 2015 (17)	66	M	Otalgia	Titanium mesh via EA
	47	M	Otalgia	“
Singh, 2017 (16)	35	M	Otorrhea, aural fullness	Collagen mesh via PeA
Ryu, 2017 (14)	46	M	Mastication induced tinnitus	Titanium mesh via PeA
Williams, 2017 (18)	46	M	Otorrhea	Tragal cartilage graft via EA
Burlak, 2018 (20)	52	M	Otorrhea	Tragal cartilage graft via PoA
Lim, 2019 (10)	55	M	Otorrhea, tinnitus	Polypropylene implant (Medpor®), titanium mesh and tragal cartilage graft via PeA
Mean	53	16M 7F		

Figure 1. Diagram of study identification process.

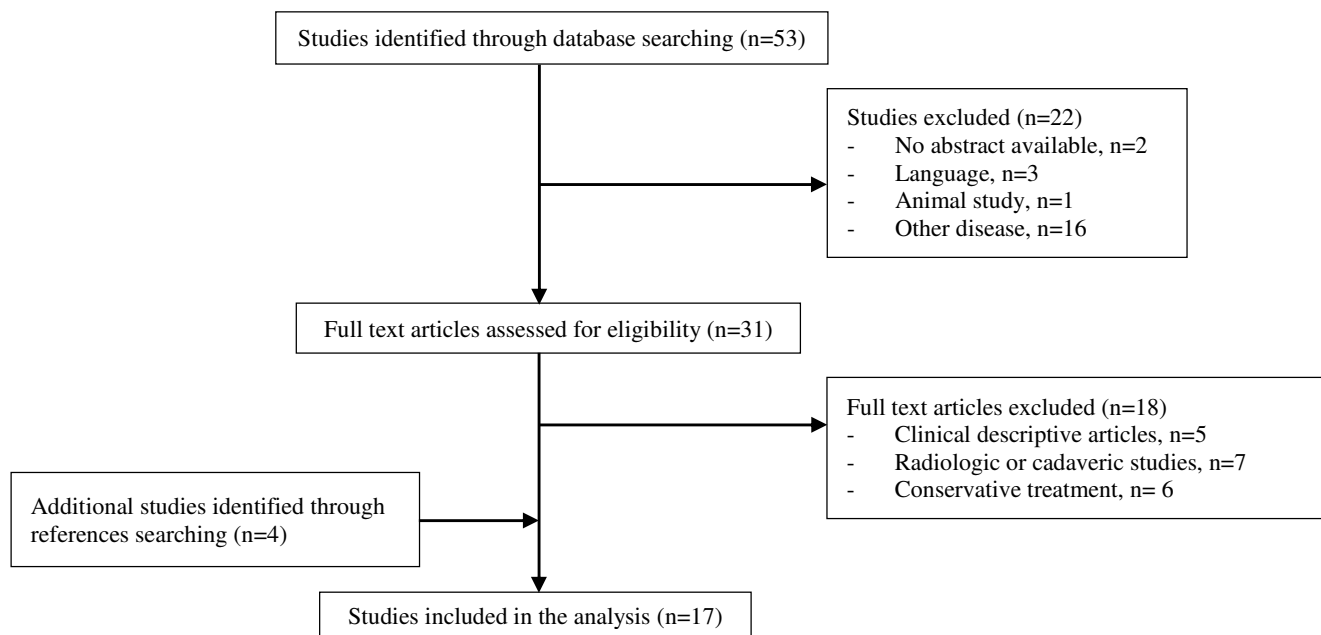


Figure 2. Preoperative CT scan (0.6 mm slice thickness) of the left external auditory canal demonstrating the bony defect (red arrow) measuring 3.4 x 3.6 mm. Axial view (A). Sagittal view (B).

P: posterior, L: lateral, I: inferior

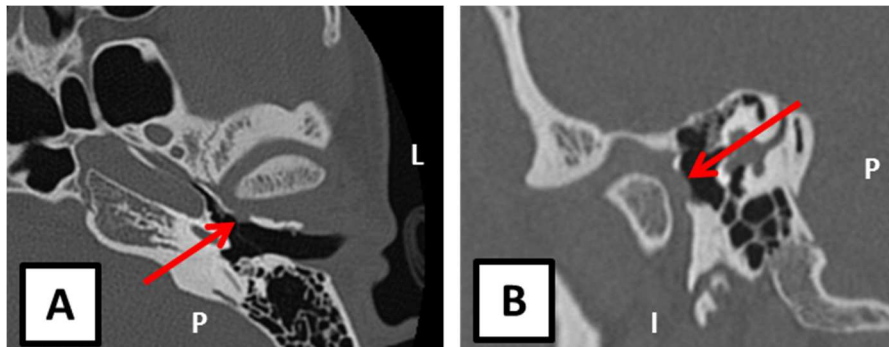

Figure 3. Contoured iliac crest bone graft designed to fill the tympanal bone defect (A) and endoscopic view of the graft on the recipient site (B).

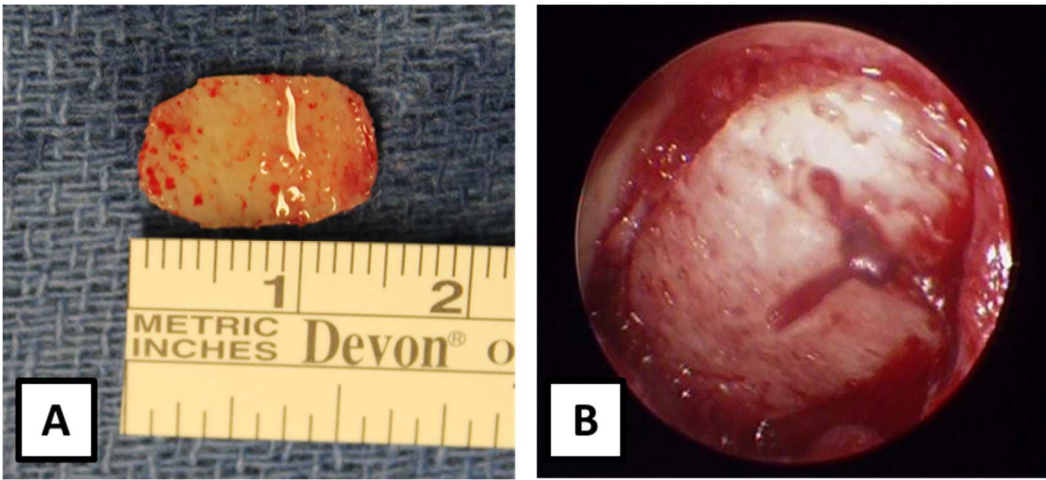
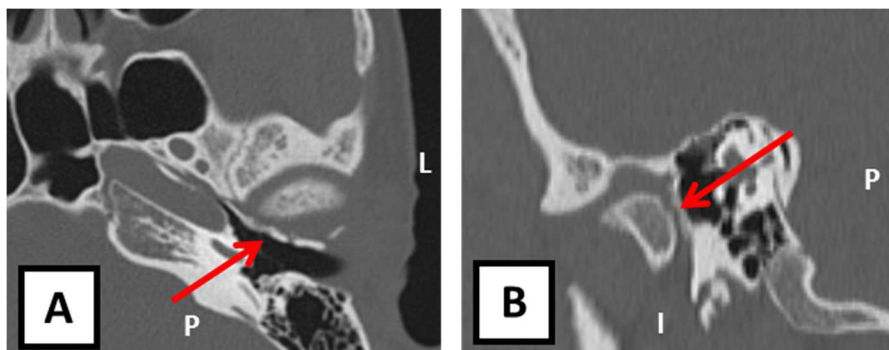


Figure 4. Postoperative CT scan (0.6 mm slice thickness) of the left external auditory canal demonstrating the closure of the foramen tympanicum by the osseointegrated iliac crest bone graft (red arrow). Axial view (A). Sagittal view (B).

P: posterior, L: lateral, I: inferior



References

1. Park YH, Kim HJ, Park M-H. Temporomandibular joint herniation into the external auditory canal. *Laryngoscope* 2010;120(11):2284-8.
2. Van Sickels JE, Nishioka GJ, Hegewald MD, Neal GD. Middle ear injury resulting from temporomandibular joint arthroscopy. *J Oral Maxillofac Surg* 1987;45(11):962-5.
3. Anand VT, Latif MA, Smith WP. Defects of the external auditory canal: a new reconstruction technique. *J Laryngol Otol* 2000;114(4):279-82.
4. Akcam T, Hidir Y, Ilica AT, Kilic E, Sencimen M. Temporomandibular joint herniation into the external ear canal through foramen of Huschke. *Auris Nasus Larynx* 2011;38(5):646-9.
5. Shin JE, Jeong K-H, Ahn SH, Kim C-H. Temporomandibular Joint Herniation Into the External Auditory Canal: Two Cases Involving a Persistent Foramen Tympanicum. *J Craniofac Surg* 2015;26(4):331-3.
6. Humphrey LT, Scheuer L. Age of closure of the foramen of Huschke: an osteological study [Internet]. *International Journal of Osteoarchaeology* 2006;16(1):47-60.
7. Hawke M, Kwok P, Shankar L, Wang RG. Spontaneous temporomandibular joint fistula into the external auditory canal. *J Otolaryngol* 1988;17(1):29-31.
8. Moriyama M, Kodama S, Suzuki M. Spontaneous temporomandibular joint herniation into the external auditory canal: a case report and review of the literature. *Laryngoscope* 2005;115(12):2174-7.
9. Li W, Dai C. Spontaneous temporomandibular joint herniation into the external auditory canal. *Brazilian Journal of Otorhinolaryngology* 2015;81(3):339-41.
10. Lim KH, Jung JY, Rhee J, Choi J. Temporomandibular joint herniation through the foramen of Huschke with clicking tinnitus. *Eur Ann Otorhinolaryngol Head Neck Dis* 2019;136(6):497-9.
11. Ajduk J, Ries M, Vagic D, Batos-Tripalo A. Temporomandibular joint fistula into the external ear canal. *J Laryngol Otol* 2012;126(8):837-9.
12. Bernstein J. Spontaneous Temporomandibular Joint Herniation into the External Auditory Canal through a Persistent Foramen Tympanicum (Huschke): Otologic Features. *J Otolaryngology ENT Res.* 2015;2(4):e00033. <https://doi.org/10.15406/joentr.2015.02.00033>.
13. Rushton VE, Pemberton MN. Salivary otorrhoea: a case report and a review of the literature. *Dentomaxillofac Radiol* 2005;34(6):376-9.
14. Ryu KH, Baek HJ, Hur DG. Spontaneous temporomandibular joint herniation into the external auditory canal through a patent foramen of Huschke: A case report. *Ann Med Surg Lond* 2017;18:33-5.

15. Shapiro MC, Osborn T. Temporoparietal fascia flap and total temporomandibular joint replacement for the management of patent foramen of Huschke. *Int J Oral Maxillofac Surg* 2016;45(8):1023-6.
16. Singh I, Jain A, Prasad P, Rajpurohit P. Spontaneous temporomandibular joint herniation: a rare case. *Oral Maxillofac Surg* 2017;21(1):87-90.
17. Yoo MH, Park JW, Lee HS, Yang CJ, Park HJ. Repair of the foramen of Huschke using an extended endaural approach. *Laryngoscope* 2016;126(9):2137-9.
18. Williams RA, Jackler RK, Corrales CE. Benign Temporomandibular Joint Lesions Presenting as Masses in the External Auditory Canal. *Otol Neurotol* 2017;38(4):563-71.
19. Kaftan H, Hosemann W. Herniation of the soft tissue of the temporomandibular joint into the external auditory canal. *HNO* 2004;52(9):817-9.
20. Burlak K, So TY, Maclaurin WA, Dixon AF. Foramen tympanicum with symptomatic temporomandibular joint herniation. *Radiol Case Rep* 2018;13(4):822-4.
21. Nakasato T, Nakayama T, Kikuchi K, Ehara S, Ohtsuka H, Fukuda K, et al. Spontaneous temporomandibular joint herniation into the external auditory canal through a persistent foramen tympanicum (Huschke): radiographic features. *J Comput Assist Tomogr* 2013;37(1):111-3.
22. Rana K, Rathore PK, Raj A, Meher R, Wadhwa V, Prakash A, et al. Bilateral spontaneous salivary otorrhoea: Case report and a review of the literature. *Int J Pediatr Otorhinolaryngol* 2015;79(10):1774-7.
23. Fusconi M, Benfari G, Franco M, Deriu D, Dambrosio F, Greco A, et al. Foramen of Huschke: case report and experimental procedure for diagnosis of spontaneous salivary fistula. *J Oral Maxillofac Surg* 2009;67(8):1747-51.
24. Pękala JR, Pękala PA, Satapathy B, Henry BM, Skinningsrud B, Paziewski M, et al. Incidence of Foramen Tympanicum (of Huschke): Comparing Cadaveric and Radiologic Studies. *J Craniofac Surg* 2018;29:2348-52.
25. Kim TH, Lee SK, Kim SJ, Byun JY. A Case of Spontaneous Temporomandibular Joint Herniation into the External Auditory Canal with Clicking Sound. *Korean J Audiol* 2013;17(2):90-3.
26. Ertugrul S. Rare Cause of Tinnitus: Spontaneous Temporomandibular Joint Herniation Into the External Auditory Canal. *J Craniofac Surg* 2018;29(5):521-2.
27. Rojas YA, Sinnott C, Colasante C, Samas J, Reish RG. Facial Implants: Controversies and Criticism. A Comprehensive Review of the Current Literature. *Plast Reconstr Surg* 2018;142(4):991-9.
28. Gillies HD: *The Principles and Art of Plastic Surgery*. Boston, Little, Brown and company, 1957.

29. Monteiro JLGC, de Arruda JAA, de Melo ARS, Barbosa RJV, Carneiro SCAS, Vasconcelos BCDE: Updated Review of Traumatic Dislocation of the Mandibular Condyle Into the Middle Cranial Fossa. *J Oral Maxillofac Surg* 2019;77:132.e1-132.e16. Epub 2018 Sep 20.