HAL open science

Facial pressure ulcers in COVID-19 patients undergoing prone positioning: How to prevent an underestimated epidemic?

A. Perrillat, J.-M. Foletti, A.-S. Lacagne, L. Guyot, N. Graillon

▶ **To cite this version:**

A. Perrillat, J.-M. Foletti, A.-S. Lacagne, L. Guyot, N. Graillon. Facial pressure ulcers in COVID-19 patients undergoing prone positioning: How to prevent an underestimated epidemic?. Journal of Stomatology, Oral and Maxillofacial Surgery, 2020, 121 (4), pp.442-444. 10.1016/j.jormas.2020.06.008 . hal-03191399

HAL Id: hal-03191399

https://amu.hal.science/hal-03191399v1

Submitted on 21 Sep 2022

HAL is a multi-disciplinary open access archive for the deposit and dissemination of scientific research documents, whether they are published or not. The documents may come from teaching and research institutions in France or abroad, or from public or private research centers.

L'archive ouverte pluridisciplinaire **HAL**, est destinée au dépôt et à la diffusion de documents scientifiques de niveau recherche, publiés ou non, émanant des établissements d'enseignement et de recherche français ou étrangers, des laboratoires publics ou privés.

Distributed under a Creative Commons Attribution - NonCommercial 4.0 International License

Version of Record: https://www.sciencedirect.com/science/article/pii/S2468785520301543
Manuscript_5faa7c9eca4adb367c7f68005a36f4ef

Facial pressure ulcers in COVID-19 patients undergoing prone positioning: How to prevent an underestimated epidemic?

Ambre Perrillat [a]; Jean-Marc Foletti [a,b]; Anne-Sophie Lacagne [a]; Laurent Guyot [a,c]; Nicolas Graillon [a,b].

a. Department of Oral and Maxillofacial Surgery, CHU Conception, APHM, 147 bd Baille 13005 Marseille, France

b. Aix-Marseille Univ, IFSTTAR, LBA UMR_T24, bd Pierre Dramard 13916 Marseille, France
c. Aix-Marseille Univ, CNRS, EFS, ADES, bd Pierre Dramard 13344 Marseille, France

Declarations of interest: none

Author Contact:

Nicolas Graillon, M.D.
Secrétariat de Chirurgie Maxillo-faciale
CHU Conception
147 boulevard Baille 13005 Marseille
Email: nicolas.graillon@ap-hm.fr
Phone: +33491435520
Fax: +33491435422

© 2020 published by Elsevier. This manuscript is made available under the CC BY NC user license
https://creativecommons.org/licenses/by-nc/4.0/

Facial pressure ulcers in COVID-19 patients undergoing prone positioning: How to prevent an underestimated epidemic?

Abstract

Prone positioning is an adjuvant therapy used to treat COVID-19 pneumonia complicated by acute respiratory distress syndrome. However, prolonged pressure on facial skin at the level of the bony structures may be responsible for facial pressure ulcers. In the context of severe COVID-19 pneumonia, we hypothesized that hypoxemia, microvascular injury and thrombosis can increase the risk of pressure ulcers. We described two cases in order to emphasize the risk of facial pressure ulcers as a result of prone positioning, so as to discuss their physiopathology and highlight the importance of appropriate preventive measures.

Keywords: pressure ulcers; facial; prone positioning; COVID -19

Introduction

In 17% of all COVID-19 cases [1] pneumonia caused by Severe acute respiratory syndrome coronavirus-2 (SARS-CoV-2) may decompensate due to hypoxemic respiratory failure consistent with acute respiratory distress syndrome (ARDS)[2]. Prone positioning is a postural adjuvant therapy, which improves ventilation in patients with ARDS[1,3] and is widely used to treat COVID-19 pneumonia complicated by ARDS [1].

Prone position allows for dorsal lung regions recruitment, end-expiratory lung volume increase, and alveolar shunt decrease [3]. As the prone position must be maintained for 10 to 12h to be effective [3] it may result in prolonged pressure points on the face leading to potential ischemic lesions [4]. Facial pressure ulcers resulting from prone positioning have already been described for treatment of ARDS of various origins before the COVID-19 pandemic[5]. These facial ulcers occur mostly at the level of the bony structures including : the forehead, the cheekbone and the chin [4].

One may hypothesize that during the COVID-19 pandemic, both the massive influx of patients and the involvement of non-specialist nurses in intensive care units led to an increased incidence of severe facial pressure ulcers.

We sought to describe the clinical presentation and specificities of two cases in order to emphasize the risk of face pressure ulcers in the prone position, so as to discuss their physiopathology and highlight the importance of appropriate preventive actions.

Clinical cases

Case 1

A 27-year-old male, was admitted to Intensive Care Unit for treatment by mechanical ventilation due to ARDS with PCR-positive SARS-CoV-2. The patient presented a morbid obesity (BMI = 38, 6 Kg/M^2). He followed a protocol including 6 prone position sessions lasting at least 12 hours each. Throughout each session, the breathing tube was placed on the left side of his mouth, secured by a tape around his neck, and his face rested on a

semilunar silicone positioning cushion. During the protocol, multiple facial pressure ulcers occurred (figure 1) on the right side of his face: on his forehead affecting the eyebrow, the cheekbone, the cheek, next to the masseter (stage 3 of the Revised National Pressure Ulcer Advisory Panel Pressure Injury Staging System (NPUAP)[6]), and the labial commissure under the tape of the breathing tube (stage 2 of the NPUAP). The patient also presented keratitis and a corneal ulcer in his right eye likely due to the absence of full eyelid closure. Following the appearance of a right hemifacial swelling, a CT scan of the face was performed showing masseter myositis next to the posterior cheek pressure ulcer without any abscess or fluid collection through fine needle aspiration (figure 2). The treatment consisted in debridement of necrotic tissue and paraffin gauze dressing application. The right corneal ulcer was treated by vitamin A ointment application and artificial tears associated with a temporary eyelid closure. A feeding tube was placed in order to improve nutritional intake. The intensive care team decided to perform a tracheotomy due to prolonged ventilatory needs.

Case 2

A 50-year-old male was admitted to Intensive Care Unit for treatment by mechanical ventilation and extracorporeal membrane oxygenation in the context of severe lung disease with PCR-positive SARS-CoV-2 complicated by ARDS, multi visceral failure and anemia. The patient was previously healthy and did not smoke. A protocol including 9 prone position sessions lasting at least 12 hours each was set up over a period of 15 days. The patient presented with superficial pressure ulcers on his left cheekbone (NPUAP stage 2) and on the left labial commissure, under the tape used to fix the breathing tube (NPUAP stage 2). The treatment consisted in debridement of necrotic tissue and paraffin gauze dressing application for secondary wound healing.

Discussion

In the context of the COVID-19 pandemic, the use of prone - positioning therapy in the treatment of ARDS may lead to a significant proportion of pressure ulcers.

Physiopathology

Facial pressure ulcers are mainly due to prolonged skin pressure, but in the context of severe COVID-19 pneumonia, we hypothesized that hypoxemia, microvascular injury and thrombosis may also increase the risk of pressure ulcers. Indeed, hypoxemia results in a decrease in peripheral perfusion, including skin perfusion, and promotes the occurrence of these ischemic skin lesions. Anatomopathological analysis of the purpuric skin lesions showed the presence of pauci-inflammatory thrombogenic vasculopathies[7] and highlighted the role of a complement-mediated thrombotic microvascular injury syndrome in the skin [8]

Prevention

In order to avoid this complication, intensive care staff must be warned, and subsequently adequately trained. Prone positioning should be supervised and regularly monitored by a member of the nursing staff familiar with this technique. In both cases, the continuous positioning of the breathing tube on the same side led to continuous pressure on the other side of the face, and the circular attachment of the probe promoted the development of pressure ulcers. In addition, in case 1, the edge of the semi- lunar positioning cushion, used to hold the patient's head, pressed on his cheek next to the masseter, accounting for the atypical location of the posterior pressure ulcer and masseter myositis. A semi- lunar positioning cushion is usually used in the supine position to hold the patient's head however, it was not designed for use in the prone position: it is too hard and the distribution of pressure points is too restricted.

We recommend using a specific softer prone -positioning head cushion , with space for the breathing tube, and a better distribution of pressure points on the whole face or silicone gels or silicone foam dressings[9] (Figure 3) . Head position should be changed 2 or 3 times

during a prone position session and the position of the breathing tube should be changed between each prone position session[5]. The circumferential fixation should be protected with gauzes or replaced by a specific endotracheal tube holder endowed with a silicon shield in contact with the cheek and the labial commissure[9]. In case 1 incomplete eyelid closure led to the occurrence of a corneal ulcer. An occlusive dressing must be applied on each eyelid and checked after prone positioning. Prolonged pressure (superior to 8 hours) on the same points is strongly associated with pressure ulcer risk, [10] and thus regular changes in head position are required during each prone position session. The systemic parameters interfering with wound healing, such as hypoxemia, anemia, or malnutrition should be preventively corrected.

Treatment

Pressure ulcer treatment consists in suppressing the pressure point on the wound, debridement of necrotic tissue, and secondary wound healing with paraffin gauze dressing or alginate in case of abundant wound exudate. Anti-complement therapy and/or anticoagulants may have a role in case of thrombotic microvascular injury syndrome[7].

Over time, facial pressure ulcers can be responsible for unsightly scars, hyperpigmentation or keloid scars, and may require additional procedures[10]. Furthermore, their long- term consequences need to be evaluated.

To conclude, the authors emphasize the risk of surge in facial pressure ulcers during the COVID-19 pandemic due to prone positioning therapy monitored by less experienced staff. In their health care facilities, oral and maxillofacial surgeons have an important role to play in the prevention of facial pressure ulcers.

This study was conducted following the principles of the Declaration of Helsinki (2013). The patients gave their written informed consent.

Disclosure of interest

The authors declare no financial disclosure and no conflict of interest.

This research did not receive any specific grant from funding agencies in the public, commercial, or not-for-profit sectors.

References

[1] Ghelichkhani P, Esmaeili M. Prone Position in Management of COVID-19 Patients; a Commentary. Arch Acad Emerg Med 2020;8:e48.

[2] Archer SL, Sharp WW, Weir EK. Differentiating COVID-19 Pneumonia from Acute Respiratory Distress Syndrome (ARDS) and High Altitude Pulmonary Edema (HAPE): Therapeutic Implications. Circulation 2020. https://doi.org/10.1161/CIRCULATIONAHA.120.047915.

[3] Kallet RH. A Comprehensive Review of Prone Position in ARDS. Respir Care 2015;60:1660–87. https://doi.org/10.4187/respcare.04271.

[4] Kim RS, Mullins K. Preventing Facial Pressure Ulcers in Acute Respiratory Distress Syndrome (ARDS): J Wound Ostomy Continence Nurs 2016;43:427–9. https://doi.org/10.1097/WON.0000000000000247.

[5] Lucchini A, Bambi S, Mattiussi E, Elli S, Villa L, Bondi H, et al. Prone Position in Acute Respiratory Distress Syndrome Patients: A Retrospective Analysis of Complications. Dimens Crit Care Nurs DCCN 2020;39:39–46. https://doi.org/10.1097/DCC.0000000000000393.

[6] Edsberg LE, Black JM, Goldberg M, McNichol L, Moore L, Sieggreen M. Revised National Pressure Ulcer Advisory Panel Pressure Injury Staging System: Revised Pressure Injury Staging System. J Wound Ostomy Cont Nurs Off Publ Wound Ostomy Cont Nurses Soc 2016;43:585–97. https://doi.org/10.1097/WON.0000000000000281.

[7] Magro C, Mulvey JJ, Berlin D, Nuovo G, Salvatore S, Harp J, et al. Complement associated microvascular injury and thrombosis in the pathogenesis of severe COVID-19 infection: a report of five cases. Transl Res 2020:S1931524420300700. https://doi.org/10.1016/j.trsl.2020.04.007.

[8] Helms J, Tacquard C, Severac F, Leonard-Lorant I, Ohana M, Delabranche X, et al. High risk of thrombosis in patients with severe SARS-CoV-2 infection: a multicenter prospective cohort study. Intensive Care Med 2020. https://doi.org/10.1007/s00134-020-06062-x.

[9] Kim RS, Mullins K. Preventing Facial Pressure Ulcers in Acute Respiratory Distress Syndrome (ARDS). J Wound Ostomy Cont Nurs Off Publ Wound Ostomy Cont Nurses Soc 2016;43:427–9. https://doi.org/10.1097/WON.0000000000000247.

[10] Nazerali RS, Song KR, Wong MS. Facial pressure ulcer following prone positioning. J Plast Reconstr Aesthetic Surg JPRAS 2010;63:e413-414. https://doi.org/10.1016/j.bjps.2009.11.001.

Figure legends:

Figure 1: A 27-year-old man with morbid obesity presenting pressure ulcers on the right side of his face: on the forehead affecting the eyebrow, the cheekbone, the cheek next to the masseter (NPUAP stage 3), and the labial commissure (NPUAP stage 2) after prone position sessions (case 1).

Figure 2 CT-scan of the head; an inflammatory edema of the masseter muscle (red arrow), without abscess at the puncture, is observed next to the cheek pressure ulcer (with arrow).
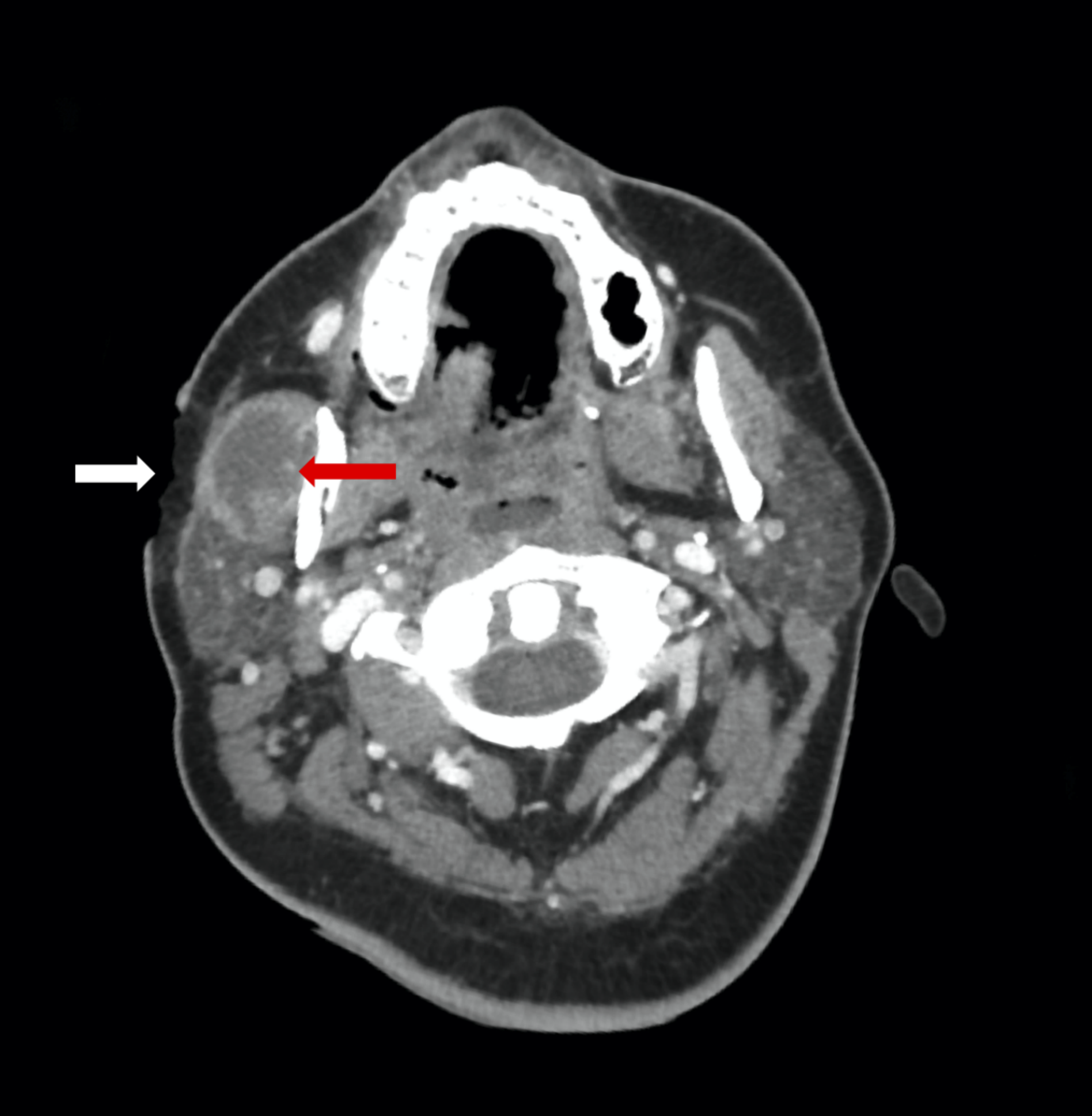
Figure 3: The optimal positioning of the head in prone position lies on a specific designed head cushion; this semi- lunar shaped cushion protects the bone structures with a wide peripheral contact without any pressure on the cheekbone, the probe or the eye (Eyes occlusion and care remain critical) (*). A non-circular device, such as a sticking-plaster, to hold the probe is preferred (**). A block placed under the shoulders prevents cervical over extension (***). Both adequate positioning and nurse cares to prevent maceration from excessive sweating should be performed every 8 hours or less.