HAL open science

Spectrum of Kidney Involvement in Patients with Myelodysplastic Syndromes

Nora Schwotzer, François Provot, Simon Ville, Laurent Daniel, Awena Le Fur, Sébastien Kissling, Noémie Jourde-Chiche, Alexandre Karras, Anne Moreau, Jean-François Augusto, et al.

To cite this version:

Nora Schwotzer, François Provot, Simon Ville, Laurent Daniel, Awena Le Fur, et al.. Spectrum of Kidney Involvement in Patients with Myelodysplastic Syndromes. Kidney International Reports, 2021, 6 (3), pp.746-754. 10.1016/j.ekir.2020.12.030 . hal-03208678

HAL Id: hal-03208678

https://amu.hal.science/hal-03208678v1

Submitted on 20 May 2022

HAL is a multi-disciplinary open access archive for the deposit and dissemination of scientific research documents, whether they are published or not. The documents may come from teaching and research institutions in France or abroad, or from public or private research centers.

L'archive ouverte pluridisciplinaire **HAL**, est destinée au dépôt et à la diffusion de documents scientifiques de niveau recherche, publiés ou non, émanant des établissements d'enseignement et de recherche français ou étrangers, des laboratoires publics ou privés.

Distributed under a Creative Commons Attribution - NonCommercial - NoDerivatives 4.0 International License

KI REPORTS
KIReports.org
CLINICAL RESEARCH

Spectrum of Kidney Involvement in Patients with Myelodysplastic Syndromes

Nora Schwotzer[1], François Provot[2], Simon Ville[3], Laurent Daniel[4], Awena Le Fur[5], Sébastien Kissling[6], Noémie Jourde-Chiche[7], Alexandre Karras[8], Anne Moreau[9], Jean-François Augusto[10], Viviane Gnemmi[11], Hélène Perrochia[12], Stanislas Bataille[13], Moglie Le Quintrec[14], Jean-Michel Goujon[15], Samuel Rotman[16] and Fadi Fakhouri[17]

[1]Transplantation Center, Centre Hospitalier Universitaire Vaudois and University of Lausanne, Switzerland; [2]Department of Nephrology and Renal Transplantation, CHRU de Lille, Lille, France; [3]Department of Nephrology and Immunology, CHU de Nantes, Nantes, France; [4]Pathology Department, CHU La Timone, Marseille, France; [5]Department of Nephrology, CH La Roche-sur-Yon, La Roche-sur-Yon, France; [6]Service of Nephrology and Hypertension, Department of Medicine, Lausanne University Hospital, Lausanne, Switzerland; [7]Department of Nephrology, Aix-Marseille Univ, C2VN, INSERM, INRAE, AP-HM CHU de la Conception, Marseille, France; [8]Department of Nephrology, Hôpital Européen Georges Pompidou, Paris, France; [9]Pathology Department, CHU de Nantes, Nantes, France; [10]Department of Nephrology, CHU d'Angers, Angers, France; [11]Pathology Department, CHRU de Lille, Lille, France; [12]Pathology Department, CHU de Montpellier, Montpellier, France; [13]Institut Phocéen de Néphrologie, Clinique Bouchard, Marseille, France; [14]Department of Nephrology, CHU de Montpellier, Montpellier, France; [15]Department of Pathology, CHU de Poitiers, Poitiers, France; [16]Service of Clinical Pathology, Centre Hospitalier Universitaire Vaudois and University of Lausanne, Switzerland; and [17]Service of Nephrology and Hypertension, Centre Hospitalier Universitaire Vaudois and University of Lausanne, Lausanne, Switzerland

Introduction: Myelodysplastic syndromes (MDS) are characterized by a high prevalence of associated autoimmune manifestations. Kidney involvement has been rarely reported in MDS patients. We report on the spectrum of kidney pathological findings in MDS patients.

Methods: We retrospectively identified MDS patients who had undergone a kidney biopsy between 2001 and 2019 in nine Swiss and French nephrology centres.

Results: Nineteen patients (median age 74 years [63-83]) were included. At the time of kidney biopsy, eleven (58%) patients had extra-renal auto-immune manifestations and sixteen (84%) presented with acute kidney injury. Median serum creatinine at diagnosis was 2.8 mg/dL [0.6-8.3] and median urinary protein to creatinine ratio was 1.2 g/g [0.2-11]. Acute tubulo-interstitial nephritis (TIN) was present in seven (37%) patients. Immunofluorescence study in one patient with acute TIN disclosed intense IgG deposits along the tubular basement membrane and Bowman's capsule. Other kidney pathological features included ANCA-negative pauci-immune necrotizing and crescentic glomerulonephritis (n = 3), membranous nephropathy (n = 2), IgA nephropathy (n = 1), IgA vasculitis (n = 1), immunoglobulin-associated membrano-proliferative glomerulonephritis type I (n=1), crescentic C3 glomerulopathy (n = 1), fibrillary glomerulonephritis (n = 1) and minimal change disease (n = 1). Eleven (58%) patients received immunosuppressive treatments, among whom one developed a severe infectious complication. After a median follow-up of 7 month [1-96], nine (47%) patients had chronic kidney disease stage 3 (n = 6) or 4 (n = 3) and five (26%) progressed to end-stage kidney disease. Three patients died.

Conclusions: MDS are associated to several autoimmune kidney manifestations, predominantly acute TIN. MDS are to be listed among the potential causes of autoimmune TIN.

Kidney Int Rep (2021) **6,** 746–754; https://doi.org/10.1016/j.ekir.2020.12.030
KEYWORDS: acute tubulointerstitial nephritis; autoimmunity; myelodysplastic syndromes
© 2021 International Society of Nephrology. Published by Elsevier Inc. This is an open access article under the CC BY-NC-ND license (http://creativecommons.org/licenses/by-nc-nd/4.0/).

Chronic myeloid neoplasms are clonal myeloid disorders of hematopoietic stem cells that include myelodysplastic syndromes (MDS), myeloproliferative neoplasms (MPN) and MDS/MPN with overlapping features of both entities.

MDS are a heterogeneous group of acquired clonal disorders defined by ineffective haematopoiesis with *dysplasia* in one or several hematopoietic cell lineages leading to cytopenias.[1] MDS carry a high morbidity related mainly to infections, bleeding and leukemic transformation. In contrast, MPN, which include polycythemia vera, essential thrombocythemia, chronic

Correspondence: Fadi Fakhouri, Service of Nephrology and Hypertension, Department of Medicine, Lausanne University Hospital, Lausanne, Switzerland. E-mail: fadi.fakhouri@unil.ch

Received 21 December 2020; accepted 22 December 2020; published online 6 January 2021

myeloid leukemia and primary myelofibrosis, are characterized by predominant peripheral blood cell *proliferation*.[1,2] Chronic myelomonocytic leukaemia, initially considered to be part of the spectrum of MDS, is now placed into a separate category with both myeloproliferative and myelodysplastic features.

MDS are also characterized by a unique high prevalence of associated autoimmune manifestations reported in 10-20% of patients.[3-6] These autoimmune manifestations encompass systemic vasculitis, connective tissue diseases (including incomplete or unclassified forms), immune-mediated haematological abnormalities, isolated autoimmune diseases and asymptomatic serological autoimmune features.[7] Conversely, a history of an autoimmune disease has been associated with an increased risk of developing MDS.[8,9]

Kidney is a major target of autoimmunity. However, kidney involvement has been rarely reported in patients with MDS, mostly in case reports [10,11] and kidney pathological data are particularly scarce in this setting. We aimed to describe the spectrum of kidney pathological findings in patients with MDS.

MATERIALS AND METHODS

We retrospectively identified, using computerized clinical and pathological databases, adult (> 18 years of age) patients with MDS who had undergone a kidney biopsy in nephrology centers in nine university and general hospitals in France and Switzerland. Patients' records were reviewed and relevant clinical and biological data were extracted. Kidney biopsies were locally reviewed in each pathology centre by an expert kidney pathologist. Glomerular filtration rate (eGFR) (ml/min/1.73m2) was estimated using the CKD-EPI equation.[12] Nephrotic syndrome was defined by a proteinuria > 3 g/day and a serum albumin < 30 g/l.

This study was approved by the local research ethics committee (Swissethics, CER-VD, project number 2020-00167). Data are presented as percentages or medians and ranges.

We also performed a search using PubMed, with the following keywords: myelodysplasic syndromes, kidney biopsy, glomerulonephritis, interstitial nephritis, in order to identify previously reported cases of nephropathies documented by kidney biopsy in MDS patients.

RESULTS

Nineteen patients (5 female, 14 male; median age 74 years [63-83 years]) with MDS who had undergone a kidney biopsy between 2001 and 2019 were included. In the three centres that included the highest number of patients, kidney biopsy was performed in less than 1% of MDS patients followed in each institution during the inclusion period. Patients' characteristics are shown in Table 1 and Table 2. Median time between MDS diagnosis and kidney biopsy was 1.5 years [0-7]. The diagnosis of MDS preceded the onset of kidney disease in 13 cases and was made concomitantly to or less than two months after kidney biopsy in six cases. At time of kidney biopsy, 11 (58%) patients had extra-renal manifestations. Median serum creatinine at diagnosis was 2.8 mg/dl [0.6-8.3] and all patients except three (patients 13, 18 and 19) presented with acute kidney injury. Patients 3 and 7 had a pre-existing chronic kidney disease of unknown cause with an eGFR of 40 and 34 ml/min/1.73 m2, respectively. Median urinary protein to creatinine ratio was 1.2 g/g [0.2-11] and two patients had a nephrotic syndrome. Microscopic haematuria was present in fifteen patients (macroscopic haematuria in patient 10). Anti-nuclear factors were detected in patients 5, 10, 11 and 17, anti-DNA antibodies and anti-cardiolipin antibodies (IgM) in patient 10 and anti-myeloperoxidase ANCA in patient 17.

Detailed pathology findings in kidney biopsies are shown in Table 3. The most frequent feature in kidney biopsies was acute tubulo-interstitial nephritis (TIN) present in seven (37%) patients (superimposed on chronic TIN in one patient) (Figure 1a-e). One additional patient had acute TIN associated to a glomerulonephritis. None of the patients with TIN had a new medication (particularly antibiotics and non-steroidal anti-inflammatory drugs) introduced in the last 6 months preceding acute kidney injury or kidney biopsy, except for patient 5 who received corticosteroids for arthritis two months earlier. Two patients (patients 2 and 3) only were on long-term treatment with a proton-pump inhibitor (detailed list of long-term treatment in patients with TIN is shown in Table S1). Patient 4 was on azacitidin at the time of acute kidney injury but was maintained on long-term azacitidin without any recurrence of acute TIN after corticosteroids withdrawal. Immunofluorescence study in patient 5 with acute TIN disclosed intense deposits of polyclonal IgG along the tubular basement membrane and Bowman's capsule. The intensity of staining was similar for the IgG1, 2, 3 and 4 subclasses (Figure 1d).

Other pathological features included ANCA-negative pauci-immune necrotizing and crescentic glomerulonephritis (n = 3), membranous nephropathy (n = 2) (Figure 1f and g), IgA nephropathy (n = 1), IgA vasculitis (n = 1), immunoglobulin-associated membrano-proliferative glomerulonephritis type I (n = 1) (Figure 1h and i), crescentic C3 glomerulopathy (n = 1), fibrillary glomerulonephritis (n = 1) and minimal change disease (n = 1). In one patient, kidney biopsy

Table 1. Characteristic of 19 patients with myelodysplastic syndromes (MDS) who had undergone a kidney biopsy

Pt	Gender Age (y)	MDS type	Treatment at KB	Time between MDS and KB (y)	At time of KB: SCr (mg/dl)	At time of KB: U P/Cr (g/g)	At time of KB: H	At time of KB: CRP (mg/l)	Extra-renal manifestations	Diagnosis/KB	TRT	Outcome
1	M, 74	MDS-MLD	EPO	3	6.2	Anuria	+++	229	Fever, livedo, scleritis, polychondritis, coeliac disease	Acute TIN	Cs	CKD: SCr 1.6-1.8 mg/dl (eGFR 36 ml/min/1.73 m2) at 1 year.
2	M, 76	MDS-RS	EPO,	2	3.2	0.3 g/l	-	29	-	Acute TIN	Cs	SCr 1 mg/dl (eGFR 74 ml/min/1.73m2) and U P/Cr < 0.5 g/g at 5 months.
3	M, 74	MDS with isolated del(5q)	EPO	> 1 y	2.9*	0.47	+	17	Polychondritis	Acute TIN	-	ESKD at 1 month.
4	F, 76	MDS-EB	Azacitidin	1.5	4.5	0.6	+++	115	Fever, arthralgia, buccal ulcerations, skin nodules	Acute TIN	-	CKD: SCr 2.5 mg/dl (eGFR 18 ml/min/1.73m2) at 3 years
5	M, 83	NA	-	Concomitant	1.9	0.8 g/l	-	13	Arthralgia	Acute TIN	Cs	CKD: SCr 1.4 mg/dl (eGFR 46 ml/min/1.73m2) at 3 months.
6	M, 80	MDS-MLD	EPO	1.6	3.6	1.5	++	50	-	Acute TIN IgAN	-	ESKD (patient declined dialysis) and Death 1 year later (AML).
7	M, 79	Not available	EPO, deferoxamin	7	8.3*	0.6	+++	142	-	Subacute TIN.	None	ESKD at 1 month
8	F, 69	MDS-EB	RBC transfusions	1.5	3.7	3.9**	+++	50	Neutrophilic urticaria, sicca syndrome	ANCA-negative PiNCG	Cs+MMF / AZA	ESKD at 6 months.
9	M, 74	MDS-MLD	RBC transfusions, EPO, deferoxamin	MDS diagnosed 2 weeks after KB	4	1.1	+++	319	Fever, pleuritis	ANCA-negative PiNCG	Cs+CYP[a] RTX	CKD: SCr 2.4 mg/dl (eGFR 25 ml/min/1.73m2) at 6 years.
10	M, 73	MDS-MLD	EPO, GM-CSF	7	5.1/HD	2.3g/l	+++M	76	Thrombocytopenia	ANCA-negative PiNCG	Cs+RTX	SCr decreased to 2 mg/dl at 3 weeks but increased again following septic shock and HD was restarted.
11	M, 74	MDS-RS	-	2 months after KB	2.5	9.4***	+	1	Sicca syndrome, peripheral neuropathy	MN.	Cs+MMF RBC Transfusions	Partial remission of the NS at 8 months (Alb, 38 g/l, Puria 1.4 g/24h). Stable CKD: SCr 1.25 mg/dl (eGFR 51 ml/min/1.73m2).
12	F, 72	MDS-MLD	EPO, RBC transfusions	1	1.3	7.9[£]	-	5	-	MN	ACEI	Stable CKD: SCr 1.5 mg/dl (eGFR 35 ml/min/1.73m2) and Puria 2 g/day at 15 months.
13	F, 78	MDS-SLD	EPO	> 3	1	0.8	+++	35	Purpura (leukocytoclasic vasculitis)	IgA vasculitis	-	Stable CKD (SCr 0.9 mg/dl; eGFR 58 ml/min/1.73m^2) and proteinuria (< 1g/24h) at 8 years
14	M, 69	MDS-MLD	-	Concomitant	1.4	1	+++		-	IgAN	None	Stable CKD: SCr 1.4 mg/dl (eGFR 50 ml/min/1.73m2) at 2 years.
15	M, 63	MDS-U	Azacitidin	1	1.6	1 g/l	++	< 5	-	Ig-MPGN type 1	None	Stable CKD: SCr 2 mg/dl (eGFR 33 ml/min/1.73 m2). Death 6 years later (AML)
16	M, 67	MDS-EB	Azacitidin, EPO	Concomitant	2.6	0.5	+	112	Arthralgia, livedo	Crescentic C3G[b] Acute TIN	Cs+RTX Ecu	ESKD at 3 months.
17	F, 75	MDS-MLD	EPO	1 month	4.5	11	+++	32	-	Fibrillary GN	Cs, RTX	CKD: SCr 2.7 mg/dl (eGFR 24 ml/min/1.73m2) at 3 months.
18	M, 80	MDS-RS	RBC transfusion	2	0.6	9.7 g/l	-	< 5	-	MCD	Cs	Partial remission of NS. Death 1 month later (septic shock).
19	M, 80	MDS-U	RBC transfusions, EPO, GM-CSF, deferoxamin	4	0.6	1.24	+++	123	Peripheral neuropathy	Normal	Cs	Stable normal SCr. Normalization of proteinuria (0.3 g/24h)

ACEI, angiotensin converting enzyme inhibitor; AML, acute myeloid leukemia; ANCA, anti-neutrophil cytoplasm antibodies; AZA, azathioprine; Cs, corticosteroids; CKD, chronic kidney disease; CRP, C-reactive protein; CYP, cyclophosphamide; EB, excess of blasts; Ecu, eculizumab; eGFR, estimated glomerular filtration rate;.EPO, erythropoietin; ESKD, end-stage kidney disease; F, female; GM-CSF, Granulocyte Macrophage Colony-Stimulating Factor; H, hematuria; HD, haemodialysis; IgAN, IgA nephropathy; IgG GN, IgG glomerulonephritis; Ig-MPGN, immunolglobulin-mediated membrano-proliferative glomerulonephritis; KB, kidney biopsy; M, male; MCD, minimal change disease; MLD, multiple lineage dysplasia; MMF, mycophenolate mofetil; MN, membranous nephropathy; NS, nephrotic syndrome; PiNCG, pauci-immune necrotizing and crescentic glomerulonephritis; Pt, patient; RBC, red blood cells; RS, ring sideroblasts; RTX, rituximab; SCr, serum creatinine; SLD, single lineage dysplasia; TIN, tubulo-interstitial nephritis; TRT, treatment; U, unclassifiable; U P/Cr, urinary protein to creatinine ratio; Y, years.

*patient with pre-existing CKD

**NS, serum albumin 27 g/l

***NS, serum albumin 25 g/l

[£], absence of NS, serum albumin 42 g/l

[a]The patient developed pancytopenia within two weeks of the start of cyclophosphamide (single infusion) and was switched to rituximab

[b]No monoclonal component was detected in the serum or urine.

Table 2. Characteristics of 19 patients with myelodysplastic syndromes (MDS) and nephropathies documented by kidney biopsy, including seven patients with tubule-interstitial nephritis and twelve with glomerulopathies. Values are medians (range) or percentages

Characteristics	Tubulo-interstitial nephritis (n = 7)	Glomerulopathy (n = 12)	All (n = 19)
Age (years)	76 (74-83)	73.5 (63-80)	74 (63-83)
Female	1 (14%)	4 (33.3%)	5 (26%)
Chemotherapy at the time of kidney biopsy	2 (29%)	1 (8.3%)	3 (16%)
Time between MDS and kidney biopsy (years)	1.6 (0-7)	1 (0-7)	1.5 (0-7)
Serum creatinine (mg/dl)	3.6 (1.9-8.3)	2.1 (0.6-5.1)	2.75 (0.6-8.3)
Urinary Protein/Creatinine (g/g)	1.05 (0.6-4.7)	1.2 (0.2-11)	1.2 (0.2-11)
Haematuria	5 (71%)	10 (83%)	15 (79%)
Extra-renal manifestations	4 (57%)	7 (58%)	11 (58%)
Treatment			
Immunosuppression	3 (43%)	8 (67%)	11 (58%)
Supportive care	4 (57%)	4 (33%)	8 (42%)
Outcome			
Remission	1 (14%)	1 (8%)	2 (11%)
Chronic kidney disease	3 (43%)	6 (50%)	9 (47%)
Dialysis	2 (29%)	3 (25%)	5 (26%)
Death	1 (14%)	2 (17%)	3 (16%)

was normal and the diagnosis of polyarteritis nodosa was made based on the presence of distal arterial microaneurysms on renal arteriography.

Among the two patients with membranous nephropathy, patient 11 had persistently negative anti-phospholipase A2 receptor 1 (PLA2R1) antibodies but a positive PLA2R1 staining in his second kidney biopsy. The status of anti-PLA2R1 antibodies is unknown for patient 12. The two patients with C3 glomerulopathy and immunoglobulin-associated membrano-proliferative glomerulonephritis type I had normal C3 and C4 plasma levels and patient 16 had no detectable C3 nephritic factor, anti-factor H and anti-factor B antibodies.

Three patients had a repeat biopsy that confirmed the diagnosis based on the first biopsy in patient 11 and the resolution of acute kidney lesions following treatment in patients 4 and 9.

Eleven (58%) patients received immunosuppressive treatments, including steroids in all. In patient 9, severe pancytopenia occurred within two weeks after the start of cyclophosphamide and the diagnosis of MDS was made (the patient was subsequently switched to rituximab). One patient had severe infectious complications (pneumonia) related to immunosuppressive treatments. After a median follow-up of 7 months [1-96], nine (47%) patients had CKD stage 3 (n = 6) or 4 (n = 3) and five (26%) had progressed to end-stage kidney disease. Three patients died in the setting of acute myeloid leukemia and septic choc.

The search in the literature retrieved only six cases of kidney biopsies performed in adult patients with MDS (Table 4). Median age at kidney biopsy was 64 years [61-74 years]. Kidney biopsies disclosed a membranous glomerulonephritis (MN) in four cases, an ANCA-associated pauci-immune necrotizing and crescentic glomerulonephritis in one, and an immunoglobulin-associated membrano-proliferative glomerulonephritis in one. In five cases, MDS was diagnosed in the workup of the newly diagnosed nephropathy and in one case, MDS was diagnosed 6 month after kidney biopsy. During follow-up, one progressed to end-stage kidney disease.

DISCUSSION

The present study is the first description of the spectrum of kidney diseases documented by kidney biopsy in patients with MDS. It clearly indicates that the kidney, along with other organs, is a target of autoimmunity in the setting of MDS. The predominant pathological feature in our series was acute TIN present in 37% of cases. Thus, MDS are, most probably, to be listed among the disorders associated to acute TIN. The absence of previous published series has potentially led to the under-recognition (and hence to the under-diagnosis) of the association of acute TIN with MDS. Acute TIN has been reported in patients with chronic myelomonocytic leukemia,[13] a hemopathy which was previously included in the spectrum of MDS. However, TIN in chronic myelomonocytic leukemia patients is either due to lysozyme toxicity[14] or to a specific leukemic infiltrate, in contrast to the non-specific infiltrate composed mostly of lymphocytes and macrophages seen in MDS patients. Finally, no case of TIN associated with MPN has been documented in published series.[15,16]

Based on our findings, the diagnostic workup of an acute TIN should include an assessment for the presence of MDS and both disorders can be concomitantly

Table 3. Features of light microscopy and immunofluorescence (IF) studies of 22 kidney biopsies performed in 19 patients with myelodysplastic syndromes. Three patients underwent a repeat kidney biopsy

	Light microscopy					
Pt	Glomeruli	Tubules	Interstitium	Vessels	IF	Diagnosis
1	9 (4 sclerotic). Normal appearance.	Rare atrophic tubules	Edema and diffuse (++) inflammatory cells infiltrate (mononuclear cells)	Normal	Mesangial IgA deposits (+/++)	Acute TIN
2	22 (1 sclerotic) Normal appearance.	Epithelial cell vacuolization. Exocytosis of inflammatory cells in tubular sections	Oedema and diffuse (+++) inflammatory cells infiltrate (lymphocytes and plasmocytes). Fibrosis < 10%	Mild arteriosclerosis	No significant deposits.	Acute TIN
3	20 (9 sclerotic). Focal segmental lesions. Absence of proliferation.	Several tubular atrophy Focal tubulitis	Inflammatory cell infiltrate (++/+++) (lymphocytes, plasmocytes, macrophages) in 30-40% of cortex area. Fibrosis 70%	Severe intimal fibrosis. Absence of thrombosis.	No significant deposits.	Acute TIN
4	1st KB 20 (0 sclerotic). Normal appearance.	Acute tubular necrosis	Oedema and inflammatory cells infiltrate (++/+++) (neutrophils, lymphocytes, plasmocytes) (including in peritubular capillaries)	Very mild arteriosclerosis	No glomeruli.	Acute TIN
	2nd KB (4 months later) 12 glomeruli (3 sclerotic). Normal appearance.	No significant lesion	Regression of inflammatory cells infiltrate. Fibrosis 10%	Very mild arteriosclerosis	No significant deposits.	
5	13 glomeruli (3 sclerotic). Absence of proliferation. Thickening of Bowman's capsule (5 glomeruli).	Deposits within the tubular basement membrane Acute injury in rare tubules	Inflammatory cell infiltrate (++) (lymphocytes, plasmocytes, eosinophils) Multifocal fibrosis (50-60%)	Moderate to severe arteriosclerosis	Polyclonal IgG (++/+++) deposits in Bowman's capsule and TBM. Similar staining for IgG 1-4 subclasses.	Acute TIN
6	13 /2 (sclerotic). Mild mesangial proliferation (+). Focal segment lesions (2 glomeruli).	Focal tubular atrophy	Inflammatory cell infiltrate (++) (lymphocytes/ plasmocytes) in 30% of the cortical area. Fibrosis 60%	Mild intimal fibrosis	Mesangial IgA and C3 deposits (++).	Acute TIN. IgAN
7	8 (2 sclerotic). Normal appearance.	Mild tubular atrophy	Focal (+/++) inflammatory cell infiltrate (lymphocytes). Fibrosis 30-40%	Mild intimal fibrosis	No significant deposits.	Subacute/ Chronic TIN
8	17 (0 sclerotic). Fibrinoid necrosis (3 glomeruli). Cellular or fibrocellular crescents (3 glomeruli).	Tubular atrophy	Giant-cell granulomas Fibrosis 50%	Normal	No significant deposits	PiNCG
9	1st KB 12 (2 sclerotic). Fibrinoid necrosis (2 glomeruli). Glomerular infiltration by neutrophils.	Rare atrophic tubules	Cortical inflammatory cell infiltrate (+/++) (neutrophils, lymphocytes, plasmocytes) Fibrosis 20%	Mild intimal fibrosis	No significant deposits.	PiNCG
	2nd KB (10 months later). 10 glomeruli (2 sclerotic). Normal appearance.	Mild (+/++) tubular atrophy	Fibrosis 30-40%	Normal	No significant deposits.	
10	11 (1 slerotic). Cellular crescents (3 glomeruli). Intra-glomerular inflammatory cells. Segmental aspects of TMA.	Mild (+) tubular injury	Inflammatory cell infiltrate (+/++) (lymphocytes and plasmocytes)	Severe arteriosclerosis	No significant deposits.	PiNCG
11	1st KB 22 (1 sclerotic). Stiffness of the capillary walls. Absence of proliferation.	Normal	Normal	Mild intimal fibrosis	Granular IgG (+++), C3 (+++) and IgM (+) along the capillary walls. Negative PLA2R1 staining.	MN
	2nd KB (6 months later). 19 (1 sclerotic). Thickening of the capillary walls. Presence of inflammatory cells (lymphocytes, monocytes, neutrophils) in capillaries.	Mild atrophy	Mild to severe fibrosis Moderate (+/++) inflammatory cell infiltrate (lymphocytes)	Mild intimal fibrosis	Granular IgG (+++), C3 (+++) along the capillary walls. Positive PLA2R1staining.	
12	10 (0 sclerotic). Deposits and spikes along the basement membrane.	Mild tubular atrophy	Mild fibrosis	Mild arteriosclerosis	Parietal granular polyclonal IgG (+++) deposits.	MN
13	9 glomeruli (0 sclerotic). Mild mesangial proliferation (+/++).	Normal	Fibrosis < 20%	Mild arteriosclerosis	Mesangial and parietal IgA (++), fibrin (++) and C3 (+) deposits.	IgA vasculitis

(Continued on following page)

Table 3. (Continued) Features of light microscopy and immunofluorescence (IF) studies of 22 kidney biopsies performed in 19 patients with myelodysplastic syndromes. Three patients underwent a repeat kidney biopsy

Pt	Light microscopy				IF	Diagnosis
	Glomeruli	Tubules	Interstitium	Vessels		
14	7 (2 sclerotic). Mild (+) mesangial matrix expansion. Focal segmental lesion (1 glomerulus).	Mild tubular atrophy	Fibrosis < 10%	Mild arteriosclerosis	Parietal IgA (++) deposits.	IgAN.
15	8 glomeruli (1 sclerotic). Mesangial deposits. Absence of proliferation.	Mild acute tubular lesions	Mild (+/++) inflammatory cell infiltrate (lymphocytes, plasmocytes)	Fibrosis < 10%	Mesangial and intra-membranous IgG (+++) and C3 (++) deposits.*	Ig- MPGN
16	20 (3 sclerotic) Focal mesangial cell proliferation (+/++). Cellular crescents (3 glomeruli).	Acute tubular necrosis	Diffuse (++) interstitial inflammatory cell infiltrate (lymphocytes, plasmocytes) Fibrosis 10%	Mild intimal fibrosis	Mesangial and parietal C3 (+++) deposits.	Crescentic C3G. Acute TIN.
17	11 (4 sclerotic). Mesangial matrix expansion and mild hypercellularity (+). Parietal deposits. Cellular crescent (1 glomerulus) and focal segmental lesions (4 glomeruli).	Mild atrophy	Mild fibrosis	Normal	Polyclonal IgG (+++) parietal deposits. IgG1++, IgG2-, IgG3-, IgG4+/++. **	Fibrillary GN.
18	10 (1 sclerotic).	Rare atrophic tubules	Fibrosis < 10%	Intimal fibrosis	No significant deposits	MCD.
19	9 (0 sclerotic).	Normal	Fibrosis < 10%	Normal	No significant deposits.	Normal

C3G, C3 glomerulopathy; IgAN, IgA nephropathy; IgG GN, IgG glomerulonephritis; Ig-MPGN, immunoglobulin-mediated membrano-proliferative glomerulonephritis; KB, kidney biopsy; MCD, minimal change disease; MN, membranous nephropathy; PiNCG, pauci-immune necrotizing and crescentic glomerulonephritis; Pt, patient; TBM, tubular basement membrane; TIN, tubulo-interstitial nephritis.
*Electron microscopy study disclosed the presence of glomerular non-dense deposits
**Congo red staining was negative. Electron microscopy study disclosed the presence of glomerular deposits composed of randomly oriented fibrils of 12 ± 1.2 nm (mean ± standard deviation of 10 random measurements) in external diameter without distinct hollow core. Gold particles labelling anti-DNAJB9 (a specific marker of fibrillary glomerulonephritis) bound the fibrils.

diagnosed, as exemplified by one case from this series. The presence of an intense staining of the tubular basement membrane (and of Bowman's capsule) with polyclonal IgG in one patient reported here is highly intriguing. It suggests that a humoral autoimmune process (along with a cellular one) may be involved in the pathogenesis of TIN in the setting of MDS. Sera from MDS patients with TIN in this series were not available for the detection of potential circulating autoantibodies targeting the tubular sections. However, anti-tubular basement membrane antibodies have been previously reported in patients with acute TIN[17] and are believed to be directed against a 58-kDa non-collagenous protein involved in the regulation of tubulogenesis.

The other kidney pathological findings in MDS patients from this series encompass a wide range of autoimmune glomerulonephritis. Some of these nephropathies have been previously reported in MDS patients in a limited number of case reports, particularly membranous nephropathy (Table 4). However our findings are remarkable for the presence of very rare glomerulopathies: ANCA-negative pauci-immune necrotizing and crescentic glomerulonephritis,[18] crescentic C3 glomerulopathy,[19] fibrillary glomerulonephritis[20,21] and immunoglobulin-associated membranoproliferative glomerulonephritis. The occurrence of these glomerulopathies may result from a MDS-linked autoimmune dysregulation (including complement dysregulation) and abnormal activation of granulocytes in ANCA-negative necrotizing and crescentic glomerulonephritis. Interestingly, ANCA negative[7] and more rarely ANCA positive[10] as well as IgA[22] extra-renal vasculitis have been reported in MDS patients. Besides, C3 glomerulopathy and immunoglobulin-associated membranoproliferative glomerulonephritis have been linked to autoimmune processes.[23] Furthermore, fibrillary glomerulonephritis probably results from glomerular deposition of immune complexes that have the ability to undergo fibrilogenesis[21] and has been reported in the setting of various auto-immune diseases, including systemic lupus erythematous and Sjögren's syndrome.[20] However, the exact mechanisms underlying autoimmune manifestations in MDS patients remain speculative.[24]

The rarity of these autoimmune glomerulonephritis (and the relative rarity of acute unexplained TIN) is the first argument against a fortuitous association between MDS and nephropathies described herein. Furthermore, as already stated, autoimmunity is a well-recognized feature of MDS in extra-renal organs. Half of the patients included in this series had extra-renal manifestations at the time of kidney biopsy and 20% had autoantibodies, even though the latter are not

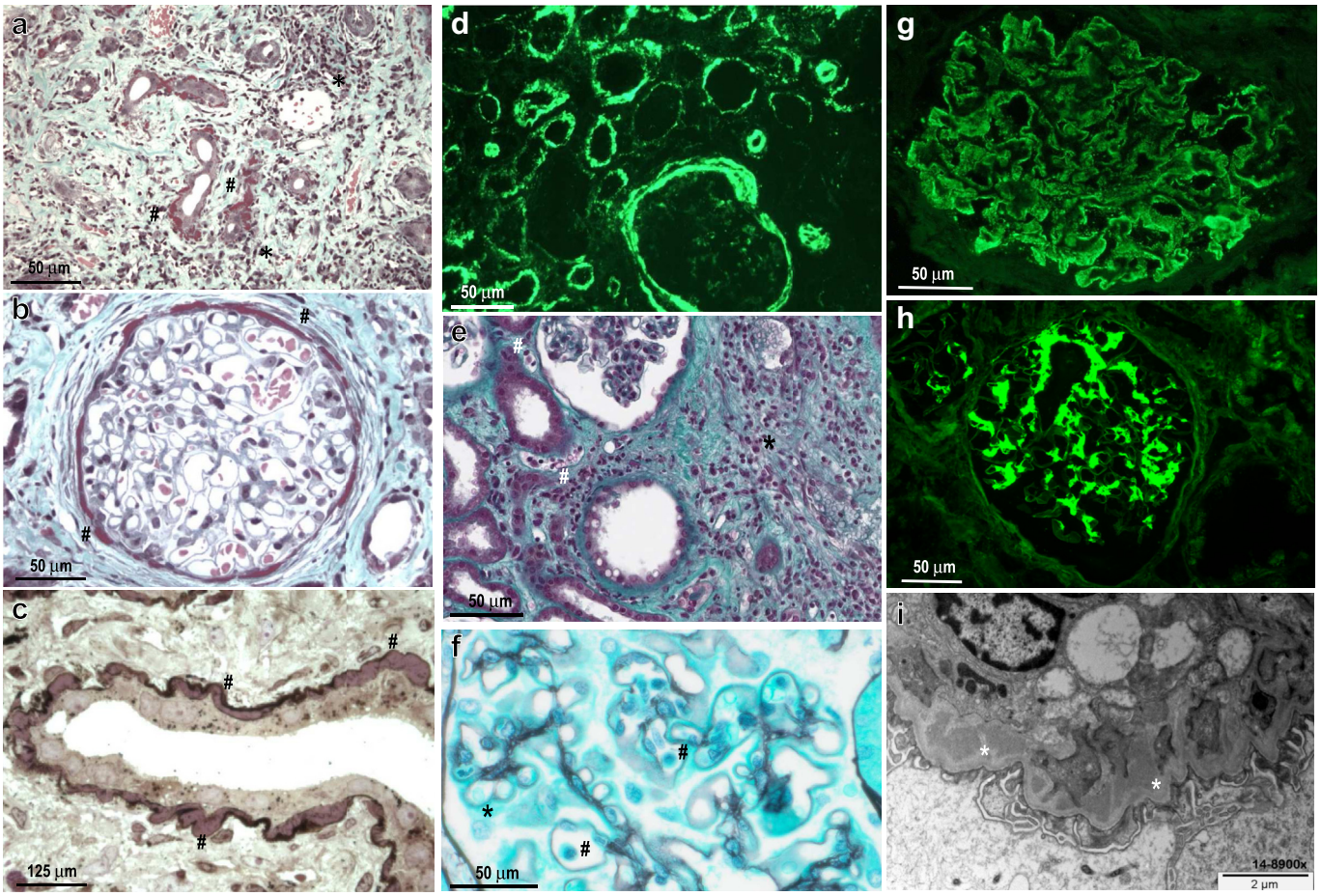

Figure 1. (a-d) Patient 5 (Table 1). A 83-year old male patient with MDS was admitted for acute kidney injury. A kidney biopsy was performed. Light microscopy study: A (Masson's trichrome staining, x200), B (Masson's trichrome staining, x400) and C (Jones staining, x600). An interstitial inflammatory cell infiltrate was present (A, *) and a thickening of the tubular basement membranes and of Bowman's capsules with the presence of deposits was noted (A-C, #). The immunofluorescence study (D, x200) disclosed intense IgG staining of the tubular basement membranes and Bowman's capsules. (e) Patient 4 (Table 1). A 76-year old female patient with MDS was admitted for severe acute kidney injury associated with extra-renal symptoms (fever, arthralgia, buccal ulcerations, skin nodules) A kidney biopsy was performed. Light microscopy study, Masson's trichrome staining, x200. An interstitial inflammatory cell infiltrate was present (*) and inflammatory cells were also noted in the lumen of peritubular capillaries (#). (f-g) Patient 11 (Table 1). A 74-year male patient with MDS was admitted for an acute kidney injury and a nephrotic syndrome. A kidney biopsy was performed. Light microscopy study, (F, Jones staining, x400). Minor alterations of the glomerular capillary walls (*) were noted in the absence of any proliferation. Inflammatory cells were present in the lumen of the glomerular capillaries (#). Immunofluorescence study (G, x 400) disclosed the presence of parietal subepithelial IgG deposits. (h-i) Patient 15 (Table 1). A 63-year male patient with MDS was admitted for acute kidney injury and mild proteinuria. Light microscopy examination revealed mild mesangial expansion and on immunofluorescence study (H, x400) mesangial and parietal IgG deposits were present (along with C3 deposits). Electron microscopy study (I, x8900) disclosed non-electron dense deposits (*) within the basement membrane.

necessarily pathogenic.[24] Besides, in six out of 19 patients, the diagnosis of MDS was made concomitantly or shortly (less than 2 months) after kidney biopsy and acute kidney injury. Nevertheless, the nature of the glomerulopathies associated to MDS in the present study was heterogeneous and a definite link between these glomerular diseases and the underlying hemopathy cannot be formally established. However, extra-renal auto-immune manifestations, frequently reported in MDS patients, are similarly highly heterogeneous in their presentation and severity.[4]

Noteworthy, the glomerular pathological findings in our patients with MDS sharply contrast with those previously documented in MPN, particularly the "MPN-related glomerulopathy" characterized by mesangial sclerosis and hypercellularity, segmental sclerosis, features of chronic thrombotic microangiopathy, and intracapillary hematopoietic cell infiltration.[16]

The treatment of nephropathies associated with MDS relies mostly on immunosuppressive treatments, which carry specific morbidity (mostly infectious) and mortality, as illustrated by several cases from the present series. Moreover, the use of cytotoxic drugs may lead to a worsening of MDS-associated cytopenias or uncover yet undiagnosed MDS as in one patient from this

Table 4. Characteristics of six previously reported patients with myelodysplastic syndromes (MDS) who underwent kidney biopsy

Ref	Gender, Age (y)	MDS type	Treatment**	Time between MDS and KB	At time of KB			Extra-renal manifestations	Diagnosis	TRT	Outcome
					SCr (mg/dl)	Puria (g/l)	H				
11	M, 65	"Hypoplastic"	Aracytin-C	Concomitant	8.7	3.7	-	-	MN	Cs, CYP.	Urea 30 mg/dl, proteinuria <0.3g/24h at 3 months
6	NA	NA	NA	NA	NA	NS	NA	NA	MN	NA	NA
25	M, 61	Refractory anaemia with eosinophilia*	EPO, Cs	Concomitant	2	1-2	-	Skin lesions (cholesterol emboli)	MN	Cs	Stable SCr and proteinuria at 1 year.
26	F, 74	Refractory cytopenia with multilineage dysplasia.	Cs, decitabine, CSA.	Concomitant	0.94	14 NS	+	NA	MN	ARB	NS at 3 months
6	NA	NA	NA	NA	NA	NA	NA	NA	Ig-MPGN?	NA	NA
10	F, 63	Refractory anemia* (trisomy 7)	EPO	6 months after KB	8.2	0.9	+	Probable intra-alveolar haemorrhage	ANCA -associated PiNCG	Cs	ESKD

AKI, acute kidney injury; ANCA, antineutrophil cytoplasm antibodies; ARB, aracytin B; Cs, corticosteroids; CSA, cyclosporin A; CYP, cyclophosphamide; EPO, erythropoietin; ESKD, end-stage kidney disease; F, female; H, haematuria; Ig-MPGN, immunoglobulin-mediated membrano-proliferative glomerulonephritis; KB, kidney biopsy; M, male; MN, membranous nephropathy; NA, not available; NS, nephrotic syndrome; PiNCG, pauci-immune necrotizing and crescentic glomerulonephritis; Puria, proteinuria; Ref, reference; SCr, serum creatinine; TRT, treatment; Y, years.
*According to the French American British classification
**At time of kidney biopsy

series. Rapid tapering of steroids and, when feasible, the use of non-cytotoxic agents (such as rituximab) is recommended in these patients.

In total, the kidney is a new identified target of autoimmunity in MDS patients. MDS are associated to several autoimmune kidney manifestations, predominantly acute TIN, and more rarely various immune glomerulonephritis.

DISCLOSURE

All the authors declared no competing interests.

ACKNOWLEDGMENTS

We would like to thank Prof. Manuel Pascual (Centre de Transplantation d'Organes, CHUV, Lausanne) for his critical reading and comments on the manuscript.

SUPPLEMENTARY MATERIAL

Supplementary File (PDF)

Table S1. Long-term treatment received by the seven patients with MDS and acute/subacute tubulo-interstitial nephritis.

STROBE Statement

REFERENCES

1. Arber DA, Orazi A, Hasserjian R, et al. The 2016 revision to the World Health Organization classification of myeloid neoplasms and acute leukemia. *Blood*. 2016;127(20):2391–2405.
2. Patnaik MM, Tefferi A. Chronic myelomonocytic leukemia: 2018 update on diagnosis, risk stratification and management. *Am J Hematol*. 2018;93(6):824–840.
3. Mekinian A, Grignano E, Braun T, et al. Systemic inflammatory and autoimmune manifestations associated with myelodysplastic syndromes and chronic myelomonocytic leukaemia: a French multicentre retrospective study. *Rheumatology (Oxford)*. 2016;55(2):291–300.
4. de Hollanda A, Beucher A, Henrion D, et al. Systemic and immune manifestations in myelodysplasia: a multicenter retrospective study. *Arthritis Care Res (Hoboken)*. 2011;63(8):1188–1194.
5. Lee SJ, Park JK, Lee EY, et al. Certain Autoimmune Manifestations Are Associated With Distinctive Karyotypes and Outcomes in Patients With Myelodysplastic Syndrome: A Retrospective Cohort Study. *Medicine (Baltimore)*. 2016;95(13):e3091.
6. Enright H, Jacob HS, Vercellotti G, Howe R, Belzer M, Miller W. Paraneoplastic autoimmune phenomena in patients with myelodysplastic syndromes: response to immunosuppressive therapy. *Br J Haematol*. 1995;91(2):403–408.
7. Saif MW, Hopkins JL, Gore SD. Autoimmune phenomena in patients with myelodysplastic syndromes and chronic myelomonocytic leukemia. *Leuk Lymphoma*. 2002;43(11):2083–2092.
8. Montoro J, Gallur L, Merchan B, et al. Autoimmune disorders are common in myelodysplastic syndrome patients and

confer an adverse impact on outcomes. *Ann Hematol*. 2018;97(8):1349–1356.

9. Kristinsson SY, Bjorkholm M, Hultcrantz M, Derolf AR, Landgren O, Goldin LR. Chronic immune stimulation might act as a trigger for the development of acute myeloid leukemia or myelodysplastic syndromes. *J Clin Oncol*. 2011;29(21):2897–2903.
10. Komatsuda A, Miura I, Ohtani H, et al. Crescentic glomerulonephritis accompanied by myeloperoxidase-antineutrophil cytoplasmic antibodies in a patient having myelodysplastic syndrome with trisomy 7. *Am J Kidney Dis*. 1998;31(2):336–340.
11. Paydas S, Paydas S, Tuncer I, Zorludemir S, Gonlusen G. A case with membranous glomerulonephritis and myelodysplastic syndrome. *Nephron*. 1992;62(2):231–232.
12. Levey AS, Stevens LA, Schmid CH, et al. A new equation to estimate glomerular filtration rate. *Ann Intern Med*. 2009;150(9):604–612.
13. Kobayashi K, Yokote T, Tsuji M, Takubo T, Inoue T, Hanafusa T. Renal infiltration associated with chronic myelomonocytic leukaemia. *Br J Haematol*. 2009;147(4):414.
14. Maraj A, MacEneaney O, Doyle B, Quinn J. Lysozyme-induced nephropathy: a rare manifestation of chronic myelomonocytic leukaemia. *Br J Haematol*. 2020;189(3):393.
15. Rahimian S, Johnson T, Herb R. A Case of Essential Thrombocythemia and IgA Nephropathy with Literature Review of the Concurrence. *Case Rep Oncol Med*. 2019;2019:5086963.
16. Said SM, Leung N, Sethi S, et al. Myeloproliferative neoplasms cause glomerulopathy. *Kidney Int*. 2011;80(7):753–759.
17. Lusco MA, Fogo AB, Najafian B, Alpers CE. AJKD Atlas of Renal Pathology: Anti-Tubular Basement Membrane Antibody Disease. *Am J Kidney Dis*. 2017;70(1):e3–e4.
18. Eisenberger U, Fakhouri F, Vanhille P, et al. ANCA-negative pauci-immune renal vasculitis: histology and outcome. *Nephrol Dial Transplant*. 2005;20(7):1392–1399.
19. Le Quintrec M, Lapeyraque AL, Lionet A, et al. Patterns of Clinical Response to Eculizumab in Patients With C3 Glomerulopathy. *Am J Kidney Dis*. 2018;72(1):84–92.
20. Nasr SH, Valeri AM, Cornell LD, et al. Fibrillary glomerulonephritis: a report of 66 cases from a single institution. *Clin J Am Soc Nephrol*. 2011;6(4):775–784.
21. Andeen NK, Troxell ML, Riazy M, et al. Fibrillary Glomerulonephritis: Clinicopathologic Features and Atypical Cases from a Multi-Institutional Cohort. *Clin J Am Soc Nephrol*. 2019;14(12):1741–1750.
22. Pertuiset E, Liote F, Launay-Russ E, Kemiche F, Cerf-Payrastre I, Chesneau AM. Adult Henoch-Schonlein purpura associated with malignancy. *Semin Arthritis Rheum*. 2000;29(6):360–367.
23. Levine AP, Chan MMY, Sadeghi-Alavijeh O, et al. Large-Scale Whole-Genome Sequencing Reveals the Genetic Architecture of Primary Membranoproliferative GN and C3 Glomerulopathy. *J Am Soc Nephrol*. 2020.
24. Grignano E, Jachiet V, Fenaux P, Ades L, Fain O, Mekinian A. Autoimmune manifestations associated with myelodysplastic syndromes. *Ann Hematol*. 2018;97(11):2015–2023.
25. Apostolou T, Sotsiou F, Pappas C, Rontoianni D, Apostolidis J, Nikolopoulou N. Atheroembolic renal disease and membranous nephropathy, in a patient with myelodysplastic syndrome, eosinophilia, and trisomy 8. *Nephrol Dial Transplant*. 2002;17(7):1336–1338.
26. Ko KI, Lee MJ, Doh FM, et al. Membranous glomerulonephritis in a patient with myelodysplastic syndrome-refractory cytopenia with multilineage dysplasia. *Kidney Res Clin Pract*. 2013;32(3):134–137.