



HAL
open science

NUT Is a Specific Immunohistochemical Marker for the Diagnosis of YAP1-NUTM1-rearranged Cutaneous Poroid Neoplasms

Nicolas Macagno, Thibault Kervarrec, Pierre Sohier, Brigitte Poirot, Aurélie Haffner, Agnès Carlotti, Brigitte Balme, Christine Castillo, Marie-Laure Jullie, Amélie Osio, et al.

► **To cite this version:**

Nicolas Macagno, Thibault Kervarrec, Pierre Sohier, Brigitte Poirot, Aurélie Haffner, et al.. NUT Is a Specific Immunohistochemical Marker for the Diagnosis of YAP1-NUTM1-rearranged Cutaneous Poroid Neoplasms. *American Journal of Surgical Pathology*, 2021, 45 (9), pp.1221-1227. 10.1097/PAS.0000000000001693 . hal-03210178

HAL Id: hal-03210178

<https://amu.hal.science/hal-03210178v1>

Submitted on 19 Jul 2021

HAL is a multi-disciplinary open access archive for the deposit and dissemination of scientific research documents, whether they are published or not. The documents may come from teaching and research institutions in France or abroad, or from public or private research centers.

L'archive ouverte pluridisciplinaire **HAL**, est destinée au dépôt et à la diffusion de documents scientifiques de niveau recherche, publiés ou non, émanant des établissements d'enseignement et de recherche français ou étrangers, des laboratoires publics ou privés.



Distributed under a Creative Commons Attribution - NonCommercial 4.0 International License

NUT Is a Specific Immunohistochemical Marker for the Diagnosis of *YAP1-NUTM1*-rearranged Cutaneous Poroid Neoplasms

Nicolas Macagno, MD, PhD, Thibault Kervarrec, MD, PhD, Pierre Sohier, MD, PhD,
Brigitte Poirot, PharmD, PhD, Aurélie Haffner, MD, Agnès Carlotti, MD,
Brigitte Balme, MD, Christine Castillo, MD, Marie-Laure Jullie, MD,
Amélie Osio, MD, Jacqueline Lehmann-Che, PharmD, PhD, Eric Frouin, MD,
and Maxime Battistella, MD, PhD

Abstract: *YAP1-NUTM1* fusion transcripts have been recently reported in poroma and porocarcinoma. *NUTM1* translocation can be screened by nuclear protein in testis (NUT) immunohistochemistry in various malignancies, but its diagnostic performance has not been thoroughly validated on a large cohort of cutaneous epithelial neoplasms. We have evaluated NUT immunohistochemical expression in a large cohort encompassing 835 cases of various cutaneous epidermal or adnexal epithelial neoplasms. NUT expression was specific to eccrine poromas and porocarcinoma, with 32% of cases showing NUT expression. All other cutaneous tumors tested lacked NUT expression, including mimickers such as seborrheic keratosis, Bowen disease, basal cell carcinoma, squamous cell carcinoma, Merkel cell carcinoma, nodular hidradenoma, and all other adnexal tumors tested. Remarkably, NUT expression was more frequent in a distinct morphologic subgroup. Indeed, 93% of poroid hidradenoma (dermal/subcutaneous nodular poroma, 13/14) and 80% of poroid hidradenocarcinoma cases (malignant poroid hidradenoma, 4/5) showed NUT expression, in contrast to 17% and 11% of classic poroma (4/23) and porocarcinoma cases (4/35), respectively. RNA sequencing of 12 NUT-positive neoplasms further confirmed the presence of a *YAP1-NUTM1* fusion transcript in all cases, and also an *EMC7-NUTM1* gene fusion in a single case. In the

Key Words: NUT, *NUTM1*, *YAP1*, poroma, porocarcinoma, squamous cell carcinoma, basal cell carcinoma, adnexal, poroid hidradenoma, poroid hidradenocarcinoma

Poroid tumors are cutaneous adnexal neoplasms harboring differentiation towards the intradermal portion of the sweat apparatus.¹ The poroma family currently includes 4 distinct histopathologic variants (hidradenoma simplex, classic poroma, dermal duct tumor, and poroid hidradenoma) that all share common cytologic features with a combination of so-called poroid and cuticular cells.^{1,2} Although acrosyringial ductal differentiation is the *sine qua non* to diagnose this group, the histopathologic presentation is quite variable, with several reported morphologic variants such as sebaceous, squamous, clear cell, or pigmented poromas.³⁻⁶ Accordingly, a wide range of epidermal and adnexal neoplasms have to be considered in the differential diagnoses. Moreover, the distinction between porocarcinoma, the malignant counterpart of poroma, and poorly differentiated squamous cell carcinoma can be a diagnostic challenge in current practice.⁷

In this context, several immunohistochemical markers have been proposed to distinguish benign and malignant poroid tumors from their differential diagnoses. Indeed, epithelial membrane antigen is expressed in poroma cells, and carcinoembryonic antigen highlights the ductal structures.⁸⁻¹⁰ In addition, several other markers have been described with variable diagnostic performance.¹⁰

Recently, Sekine et al¹¹ have reported recurrent *YAP1-MAML2* and *YAP1-NUTM1* fusion transcripts in poroma and porocarcinoma. Interestingly, *NUTM1* fusion in cutaneous poroid neoplasms was associated with nuclear expression of nuclear protein in testis (NUT), while no positive expression for this protein was observed in the other skin tumors tested.^{11,12} Indeed, apart from testis and ovary germ

cells, NUT expression is lacking in normal adult tissues¹³ suggesting it constitutes a potential specific marker of poroid tumors. In this context, our study aimed to evaluate the performance of NUT immunohistochemistry to distinguish poroma and porocarcinoma from their potential mimics on a large cohort of various cutaneous epithelial neoplasms.

METHODS

Patients and Samples

Cases of various cutaneous epithelial neoplasms were selected from the consultation archives of the authors (T.K., M.B., E.F., N.M., P.S.). Archived slides stained with hematoxylin-eosin, and phloxine (HPS) were reexamined to confirm diagnoses in accordance with the fourth WHO Classification of Skin Tumors.¹ Adnexal neoplasms were reviewed by a group of expert pathologists from the French Rare Skin Cancer Group (CARADERM). The study was conducted according to the Declaration of Helsinki and European RGD (ID RCB2009-A01056-51).

A total of 835 tumors with available histologic material was selected for investigation. Specifically, all 78 poroid tumor cases and 82 other neoplasms were evaluated on whole slide cuts, to demonstrate the homogeneity of NUT expression and allow the use of a tissue microarray (TMA) approach for further analysis. Subsequently, NUT specificity was evaluated in a second independent cohort of 675 neoplasms embedded in TMAs.

Immunohistochemistry

Sections from the paraffin blocks from each case and TMAs were stained using immunohistochemistry detecting the NUT protein encoded by the *NUTM1* gene (anti-NUT, ozyme, clone C52B1, rabbit monoclonal, 1:100 concentration) using the Ventana Benchmark Ultra automated immunostainer (Ventana Medical Systems, Tucson AZ) and revealed with the UltraView Universal DAB Detection kit (Ventana Medical Systems). Appropriate external positive control (NUT-midline carcinoma [NMC] and normal testis) was included on each slide.

Molecular Biology

Gene fusion analysis was performed using next-generation sequencing on 15 samples with available formalin-fixed paraffin-embedded (FFPE). Total RNA was extracted from ten 10 µm thick tissue sections, using the Maxwell RSC RNA FFPE kit on a Maxwell RSC instrument (Promega). The library was prepared using a custom FusionPlex Comprehensive kit (ArcherDx) including 30 targeted genes (*AKT1*, *ALK*, *AXL*, *BRAF*, *CCND1*, *CCND3*, *CIITA*, *DUSP22*, *EWSR1*, *FGFR1*, *FGFR2*, *FGFR3*, *MALT1*, *MAML2*, *MYB*, *NRG1*, *NTRK1*, *NTRK2*, *NTRK3*, *NUTM1*, *PDCD1LG2*, *PLAG1*, *PPARG*, *RAF1*, *RET*, *ROSI*, *SSI8*, *THADA*, *TP63*, *YAPI*) and sequenced on a MiSeq System (Illumina). The obtained data were analyzed using the Archer Analysis Suite, v6.03.2. The AMP (Anchored Multiplex PCR) technology allows the identification of fusion transcripts involving one of the 30 genes of the panel, regardless of the fusion partner.

TABLE 1. NUT Expression in 78 Poroid Tumors

	N	NUT Positivity, n (%)
Poroid tumors	78	25 (32)
Benign	38	17 (44)
Poroma	23	4 (17)
Poroid hidradenoma	14	13 (93)
Dermal duct	1	0 (0)
Malignant	40	8 (20)
Porocarcinoma	35	4 (11)
Malignant poroid hidradenoma	5	4 (80)

RESULTS

NUT Expression Is Restricted to Poroid Tumors

To determine the diagnostic performance of NUT immunohistochemistry for the diagnosis of poroid neoplasms, NUT expression was evaluated in a cohort of 835 skin neoplasms and 15 normal skin samples. Immunohistochemical results are summarized in Tables 1 and 2.

TABLE 2. NUT Expression in 757 Other Cutaneous Epithelial Neoplasms and 15 Normal Skin Samples

Diagnosis	N	NUT Positivity, n (%)
Normal skin	15	0 (0)
Nonporal skin adnexal neoplasms	301	0 (0)
Adenoid cystic carcinoma	5	0 (0)
Adnexal carcinoma, not otherwise specified	4	0 (0)
Adnexal microcystic carcinoma	3	0 (0)
Apocrine carcinoma	1	0 (0)
Chondroid syringoma	4	0 (0)
Digital papillary carcinoma	2	0 (0)
Ductal squamoid carcinoma	2	0 (0)
Hidradenocarcinoma	1	0 (0)
Hidradenoma	16	0 (0)
Histiocytoid carcinoma	1	0 (0)
Malignant mixed tumor	1	0 (0)
Mucinous carcinoma	2	0 (0)
Myoepithelioma	2	0 (0)
Extramammary Paget disease	7	0 (0)
Pilar sheath acanthoma	1	0 (0)
Pilomatricoma	1	0 (0)
Pilomatricoma	21	0 (0)
Primary cutaneous cribriform carcinoma	1	0 (0)
Proliferating tricholemmal tumor	3	0 (0)
Sebaceoma	35	0 (0)
Sebaceous adenoma	96	0 (0)
Sebaceous carcinoma	23	0 (0)
Sebaceous hyperplasia	10	0 (0)
Sebocystoma	4	0 (0)
Secretory carcinoma	1	0 (0)
Spiradenoma/cylindroma	15	0 (0)
Syringocystadenoma papilliferum	1	0 (0)
Trichoblastoma/trichoepithelioma	29	0 (0)
Tricholemmal carcinoma	1	0 (0)
Tricholemmoma	8	0 (0)
Other skin neoplasms	456	0 (0)
Actinic keratosis	10	0 (0)
Basal cell carcinoma	80	0 (0)
Carcinoma in situ and Bowen	50	0 (0)
Clear cell acanthoma	5	0 (0)
Inverted follicular keratosis	2	0 (0)
Neuroendocrine carcinoma (Merkel)	202	0 (0)
Seborrheic keratosis	21	0 (0)
Squamous cell carcinoma	65	0 (0)
Undifferentiated carcinoma	21	0 (0)

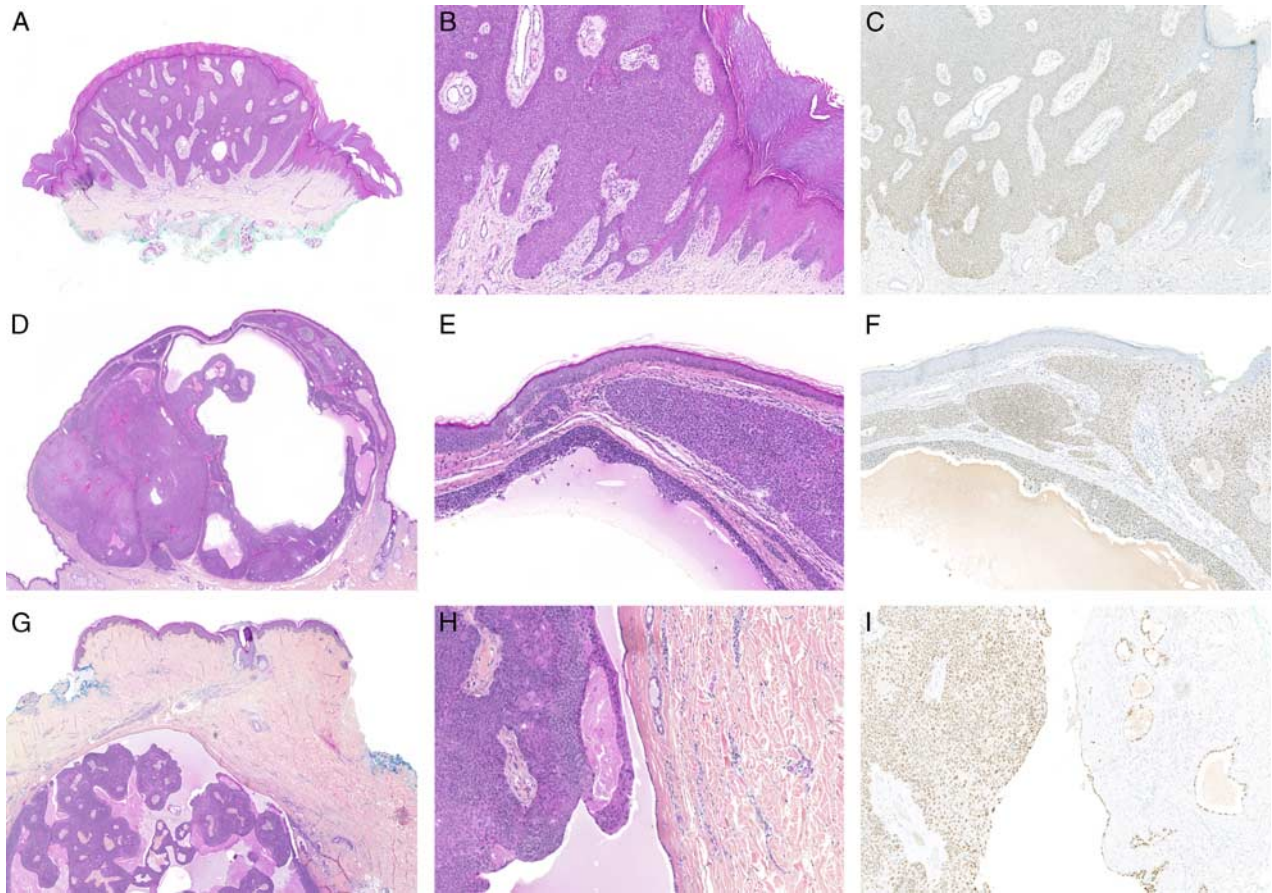


FIGURE 1. Nuclear expression of NUT in poroma and poroid hidradenoma. A–C, Poroma, showing a classic dome-shaped silhouette with vascular stroma, with poroid cytology, diffuse nuclear expression of NUT. D–F, Poroid hidradenoma, composed of dermal nodules with lobulation and cystic changes, NUT stains the majority of the neoplastic nuclei. G–I, Poroid hidradenoma with cuticular cells, note that NUT positivity is expressed by the single layer of cells lining the cystic spaces.

First, we assessed NUT specificity in the skin by evaluating NUT expression in a set of 15 normal skin samples. No expression of NUT was observed in these samples.

Thus, we evaluated NUT expression in poroid tumor samples ($n=78$). In this setting, NUT positivity was observed in 32% of the cases ($n=25/78$). Importantly, most of the poroid hidradenoma cases (93%, $n=13/14$) were positive in contrast to only 17% ($n=4/23$) of the classic poroma cases (Fig. 1).

Accordingly, among malignant poroid tumors, NUT expression was observed in the majority of malignant poroid hidradenoma (poroid hidradenocarcinoma) cases (80%, $n=4/5$) and only in 11% of classic porocarcinoma cases ($n=4/35$) (Fig. 2). Thus, NUT was more frequently expressed in benign and malignant poroid hidradenoma cases within the poroid group of tumors (χ^2 , $P < 0.0001$).

Finally, we investigated NUT expression in nonporoid skin tumors. No expression of NUT was observed among the 757 tumor samples tested (Table 2, Fig. 3), suggesting NUT might constitute a highly specific marker. NUT immunohistochemistry diagnostic performances are

summarized in Table 3. Accordingly, NUT displayed a perfect specificity (100%) to diagnose benign and malignant poroid tumors, albeit its overall sensitivity was 32.1%. NUT sensitivity reached 89.5% for the diagnosis of poroid hidradenoma and its malignant counterpart (poroid hidradenocarcinoma) and dropped to 20.0% to diagnose a malignant poroid tumor (porocarcinoma and poroid hidradenocarcinoma) in general.

Identification of Fusion Partners in NUT-expressing Poroid Tumors

To determine whether *YAPI* (NM_001130145.2) was the preferential fusion partner of *NUTM1* (NM_175741.2), as previously described, RNA sequencing was performed on all NUT-expressing tumors for which an FFPE sample was available (15 cases). Three cases had extracted RNA of insufficient quality for the analysis. Among the 12 contributive analyses, RNA sequencing revealed a *YAPI-NUTM1* fusion transcript in all cases tested (Table 4): exon 3 (5 cases, 41%), exon 4 (5 cases, 41%), exon 7 (1 case, 8%), or intron 8 (1 case, 8%) of *YAPI* were fused with exon 3 (8 cases, 67%), exon 4

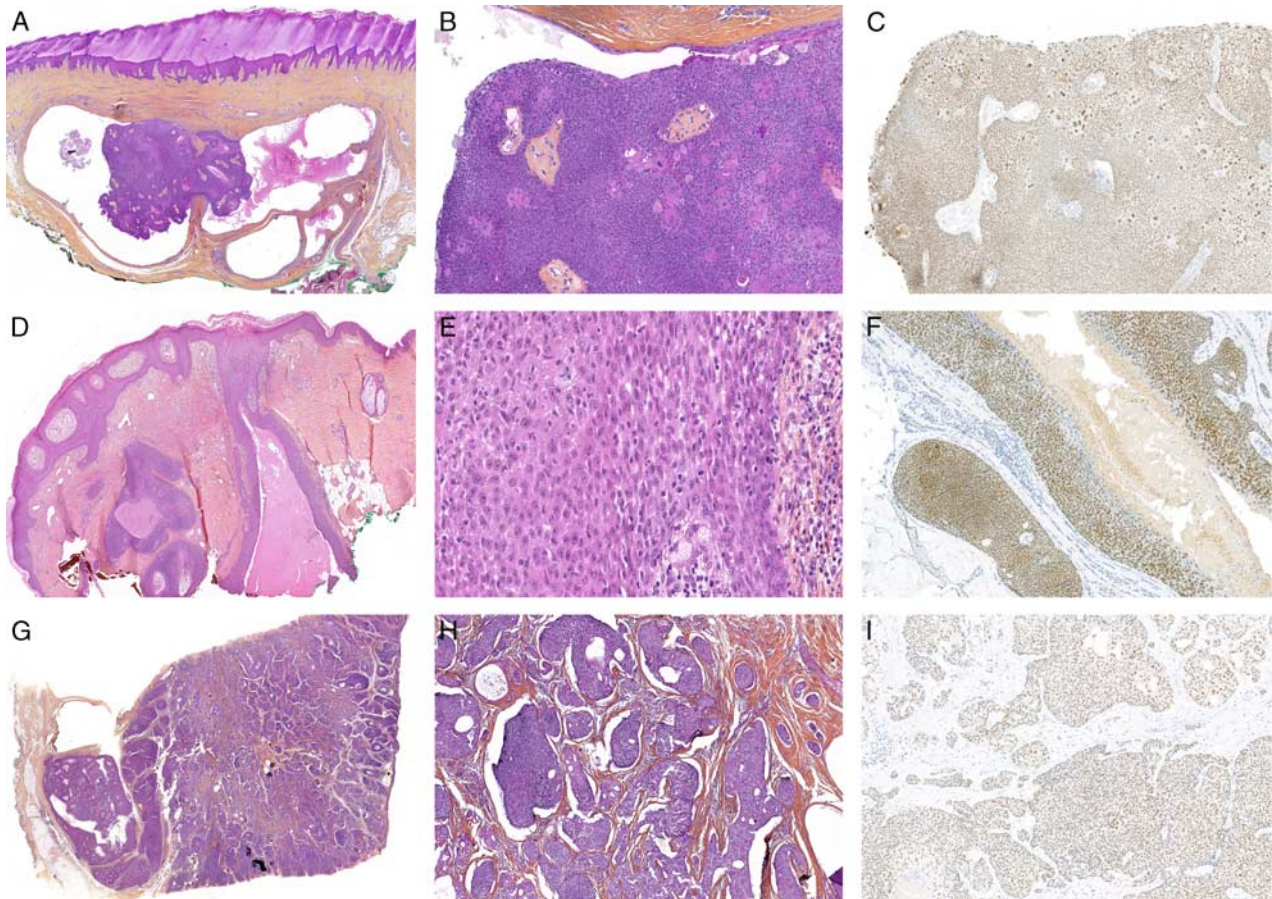


FIGURE 2. Nuclear expression of NUT in malignant poroid neoplasms. A–C, Malignant poroid hidradenoma: cuticular cells show nuclear atypia and pleomorphism, with high mitotic activity and diffuse nuclear expression of NUT. D–F, Porocarcinoma arising from a poroma: cell crowding and nuclei overlap, mild to high nuclear atypia, high mitotic activity with abnormal (tripolar) mitotic figures, juxtaposed to a classic superficial poroma. NUT is expressed by both components. G–I, Invasive aggressive porocarcinoma: invasive carcinoma composed of lobules surrounded by cleft artifacts, variable ductal differentiation, and diffuse expression of NUT.

(2 case, 17%), exon 5 (1 case, 8%) or intron 2 (1 case, 8%) of *NUTM1*. One case of malignant poroid hidradenoma (poroid hidradenocarcinoma) showed 2 different *NUTM1* fusions, namely *YAPI* (exon 7)—*NUTM1* (exon 5), and *EMC7* (exon 1)—*NUTM1* (exon 5).

DISCUSSION

In the present study, we have evaluated the performance of NUT immunohistochemical staining for the diagnosis of poroma and porocarcinoma, among a large cohort of skin epithelial neoplasms. Our results showed that NUT expression was restricted to poroid tumors (specificity = 100%). Moreover, our study further highlighted NUT as a highly sensitive marker of benign and malignant poroid hidradenoma (poroid hidradenocarcinoma), while such positivity was only observed in 14% of classic poroma and porocarcinoma cases (n = 8/58). The strength of our study was to refine NUT specificity by testing it on a large cohort of various cutaneous epithelial neoplasms. We have also confirmed that immunohistochemical expression was highly

correlated with a *YAPI-NUTM1* fusion transcript in all cases investigated. Also, we have highlighted that NUT was frequently associated with a distinct poroid hidradenomatous morphology.

In a physiological context, NUT protein expression is restricted to the testis and appears critical for male fertility.¹⁴ Indeed, NUT enhances histone H4K5 and H4K8 acetylation by interacting with the histone acetyltransferases p300 and/or CBP, therefore contributing to nuclear compaction and morphogenesis of the spermatids.¹⁴ In 2003, French and colleagues brought the first demonstration of the oncogenic abilities of *NUTM1* fusion by identifying recurrent *BRD4-NUTM1* fusions in a subset of poorly differentiated, mostly lethal carcinoma, later called NMC.^{13,15,16} Further in vitro investigation revealed that knock-down of the *BRD4-NUTM1* fusion protein in NMC lead to cell cycle arrest and squamous cell carcinoma differentiation, confirming the oncogenic potential of the fusion protein.¹⁷ Indeed, expression of the fusion product results in histone hyperacetylation that affects chromatin compaction and cell transcription

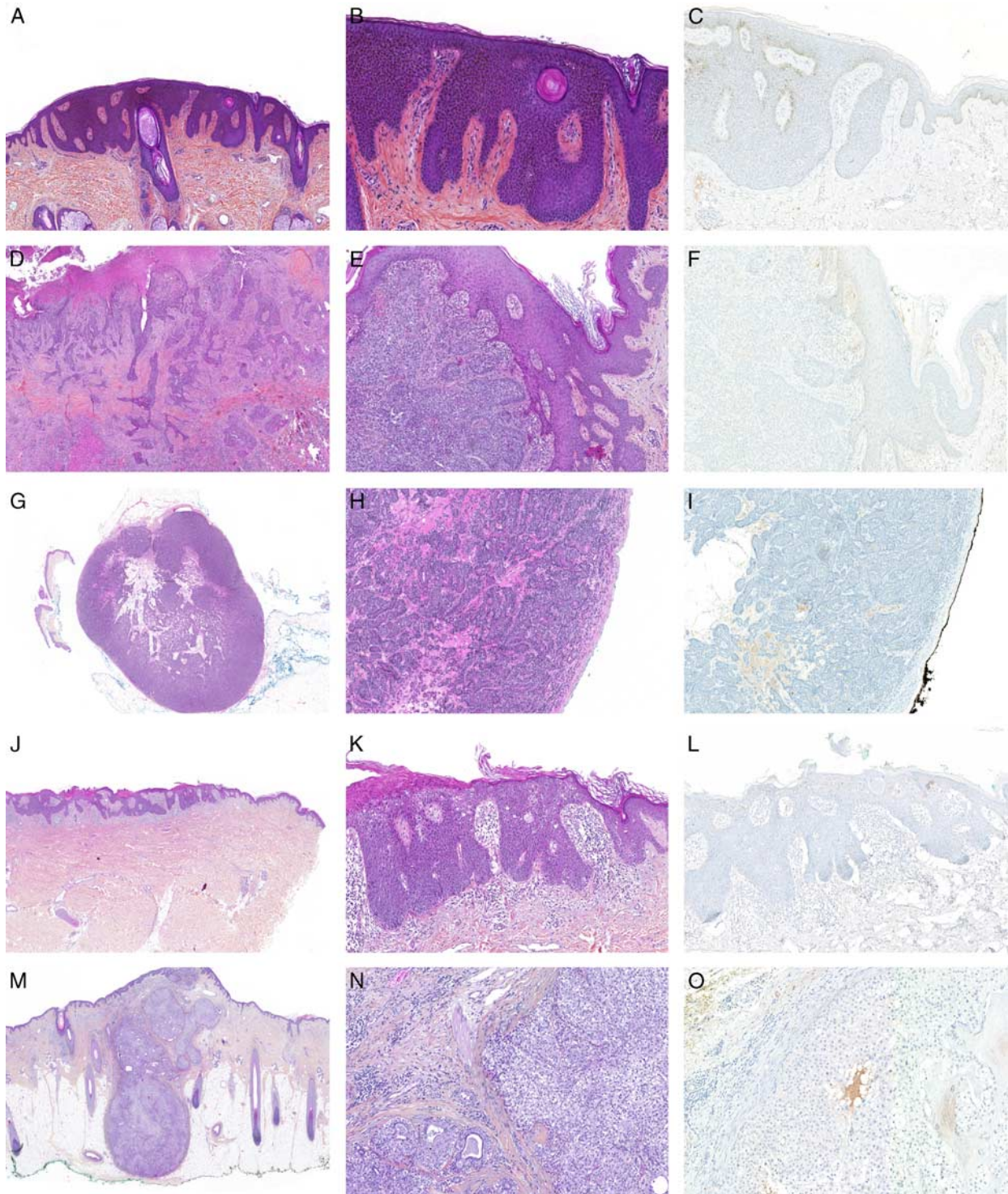


FIGURE 3. Lack of NUT expression in nonporoid epithelial neoplasms. A–C, Seborrheic keratosis: the well-demarcated proliferation of basaloid pigmented keratinocytes arranged in broad adjoining columns. Absence of NUT expression. D–F, Infiltrating basal cell carcinoma: variably sized, reticular or jagged nests of basaloid neoplastic cells with an infiltrative pattern of invasion. Absence of NUT expression. G–I, Spiradenoma: a round nodule of basaloid cells, with edematous stroma, composed of clear and dark cells arranged in ductal structures. Absence of NUT expression. J–L, Bowen disease: full-thickness epidermal dysplasia with parakeratosis, atypical pleomorphic squamous cells with increased mitotic figures. Absence of NUT expression. M–O, Nodular hidradenoma: a dermohypodermal nodular neoplasm composed of solid aggregates of pale and clear cells, with ductal structures at the periphery. Absence of NUT expression.

TABLE 3. NUT Diagnostic Performances to Diagnose Poroid Tumors, Malignant Poroid Tumors, and Benign or Malignant Poroid Hidradenomatous Tumors

	Sensitivity (%)	95% CI (%)	Specificity (%)	95% CI (%)	PPV (%)	NPV (%)
Poroid tumors*	32.1	21.9-43.6	100	99.5-100	100	93.5
Malignant poroid tumors†	20.0	9.1-35.7	100	99.6-100	100	96.0
Benign and malignant poroid hidradenomatous tumors‡	89.5	66.9-98.7	100	99.6-100	100	99.8

*Poroma, dermal duct tumor, poroid hidradenoma, porocarcinoma, and malignant poroid hidradenoma (poroid hidradenocarcinoma).

†Porocarcinoma, malignant poroid hidradenoma (poroid hidradenocarcinoma).

‡Poroid hidradenoma, malignant poroid hidradenoma (poroid hidradenocarcinoma).

CI indicates confidence interval; NPV, negative predictive value; PPV, positive predictive value.

profile.^{17,18} Such dysregulation notably leads to *TP63* and *MYC* expression, which both are genes demonstrated as crucial for NMC proliferation.^{18,19} Of note, additional fusion partners of *NUTM1* were later reported in NMC such as *BRD3* and *BRDT*, all harboring high homology with *BRD4*.¹⁶

In addition to NMC, *NUTM1* rearrangements were recently observed in several nonepithelial malignancies, including sarcoma and leukemia, although the fusion partners vary from one entity to the other (fusion partners in sarcomas: *CIC*, *MGA*, *MXD4*, *ZNF532*; fusion partners in leukemias: *SLC2A6*, *CUX1*, *IKZF1*, *ACIN1*).²⁰⁻²²

In this context, Sekine et al¹¹ reported recurrent *YAP1-NUTM1* rearrangements in benign and malignant poroid tumors (n=27/115), such alterations being mutually exclusive with *YAP1-MAML2* fusion (n=72/115). In addition, a single case of poroma in their study harbored a *WWTRI-NUTM1* fusion (n=1/115).¹¹ Two porocarcinomas of the auditory canal harboring *NUTM1-YAP1* translocation were further reported by Agaimy et al.²³ Although our study confirmed the presence of recurrent *NUTM1* fusion in poroid tumors as previously reported, some subtle differences were observed. Indeed, Sekine and colleagues detected more frequent NUT positivity in porocarcinoma cases than in benign poroid tumors (54% vs. 24%, respectively) suggesting that NUT might constitute a relevant marker for the diagnosis of porocarcinoma. Very recently, Russell-Goldman et al¹² also reported NUT expression in porocarcinomas (41% of cases), but without expression in poroma, squamous cell carcinoma, and hidradenocarcinoma and also suggested an association between NUT expression and porocarcinoma.¹² By contrast, we observed NUT expression both in poroma and porocarcinoma, and in our

study, 16% of the porocarcinoma cases showed NUT positivity, suggesting a lower-than-expected NUT sensitivity for the diagnosis of porocarcinoma, with a comparable frequency to classic poroma (17%). Interestingly, 20% of porocarcinomas are associated with a poroma, suggesting in these cases a malignant transformation of the benign component.²⁴ In this context, the similar frequencies of NUT expression observed in classic poroma and porocarcinoma also suggest that *NUTM1* fusion might constitute one of the primary oncogenic drivers that leads to poroma development, while secondary events such as *KRAS*, *SETD2*, *TP53*, and *RBI* mutations, contribute to progression to malignancy, as previously reported.^{11,25}

In contrast to a lower-than-expected NUT positivity frequency in porocarcinoma, we have found almost constant NUT expression (93% of the cases) in a distinctive dermal nodular morphologic subset, namely poroid hidradenoma, and in 80% of its malignant counterpart. Indeed, poroid hidradenoma harbors the cytologic features of a poroid neoplasm with a combination of poroid and cuticular cells, but with architectural characteristics of hidradenoma, forming dermal nodules, often with cystic changes.²⁶ In this context, poroid hidradenoma can be morphologically confused with nodular hidradenoma, an entity that consistently lacked NUT expression in the present study (n=16). Nodular hidradenoma characteristically harbors *CTRC1-MAML2* or *CRTC3-MAML2* oncogenic fusion, not found in poroid hidradenoma.²⁷ Our data further confirms that poroid hidradenoma is distinct from nodular hidradenoma, and that NUT appears a sensitive and specific immunohistochemical marker in their differential diagnosis.

All poroid neoplasms are expected to derive from basal keratinocytes of the sweat duct ridge and the existence of four morphologic variants has been proposed to be linked to variation in the site of tumor initiation along the sweat duct ridge.² Interestingly, much higher frequency of *NUTM1* fusion is observed in poroid hidradenoma than in any other poroid tumor subtype, suggesting that its morphology might also be driven by specific genetic alterations.

In addition to the 115 poromas and porocarcinomas, Sekine et al¹¹ investigated NUT expression in 97 other cutaneous tumors (24 squamous cell carcinomas, 32 basal cell carcinomas, 5 cutaneous adenocarcinomas, 9 Merkel cell carcinomas, and 27 seborrheic keratoses) and did not identify any NUT expression. These findings were partially confirmed by a recent study that reported NUT

TABLE 4. RNA Sequencing of NUT-positive Cutaneous Poroid Neoplasms (N = 12)

	n (%)
YAP1 exon 3-NUTM1 exon 3*	5 (42)
YAP1 exon 4-NUTM1 exon 3	5 (42)
YAP1 exon 7-NUTM1 exon 5	1 (8)
YAP1 intron 8-NUTM1 intron 2	1 (8)
EMC7 exon 1-NUTM1 exon 5*	1 (8)

*Both fusion transcript types present within the same tumor.

expression in porocarcinomas, but lacking NUT expression in 10 poromas, 10 squamous cell carcinomas, and 6 hidradenocarcinomas.¹²

In the present study, we have further confirmed these results, on the largest cohort to date, by demonstrating the lack of NUT expression in a large panel of cutaneous epithelial and adnexal tumors (n = 757) and in normal skin (n = 15). Therefore, NUT expression in a cutaneous epithelial neoplasm is highly suggestive of a poroid neoplasm, albeit NUT negativity cannot rule out this diagnosis. Of note, NUT positivity in porocarcinoma should not lead the pathologist to misdiagnose it as NMC, a highly aggressive neoplasm occurring in children and young adults with a completely different clinical presentation.

On molecular grounds, we have found a perfect concordance between NUT immunohistochemistry and gene fusion analysis, detecting *YAPI-NUTM1* fusion transcript in all contributive cases (13 cases could not be studied), thus paralleling previous results by Sekine et al.¹¹ Indeed, they also reported a high concordance between immunohistochemistry and molecular biology, albeit 4 cases (12%) showed positive NUT immunohistochemistry but lacked a detectable fusion involving *NUTM1*. Another study investigating NUT immunohistochemistry on poroid neoplasm did not perform molecular biology.¹²

Our study harbors some limitations, such as the lack of rarer variants of poroid tumor and other adnexal neoplasms, notably benign and malignant dermal duct tumor and hidracanthoma simplex. Also, molecular biology could not be performed on all NUT-positive cases, as 10 FFPE samples were not available and 3 samples were not contributive due to RNA quality.

CONCLUSIONS

To conclude, our study provided immunohistochemical data on NUT expression in several cutaneous epithelial neoplasms, revealing a remarkable restriction of its nuclear expression to a subset of poroid neoplasms harboring a frequent poroid hidradenomatous morphology and associated with *YAPI-NUTM1* fusion transcripts. NUT immunohistochemistry is therefore a valuable tool for the diagnosis of this specific group of poroid adnexal neoplasms, and for the differential diagnosis of nodular hidradenoma and poroid hidradenoma.

REFERENCES

1. World Health Organization (WHO). In: Elder DE, Massi D, Scolyer RA, Willemze R, eds. *WHO Classification of Skin Tumours*, 4th ed. Lyon, France: International Agency for Research on Cancer; 2018: 3p164.
2. Battistella M, Langbein L, Peltre B, et al. From hidroacanthoma simplex to poroid hidradenoma: clinicopathologic and immunohistochemical study of poroid neoplasms and reappraisal of their histogenesis. *Am J Dermatopathol*. 2010;32:459–468.
3. Goh SGN, Dayrit JF, Calonje E. Sarcomatoid eccrine porocarcinoma: report of two cases and a review of the literature. *J Cutan Pathol*. 2007;34:55–60.
4. Mahomed F, Blok J, Grayson W. The squamous variant of eccrine porocarcinoma: a clinicopathological study of 21 cases. *J Clin Pathol*. 2008;61:361–365.
5. Kazakov DV, Kutzner H, Spagnolo DV, et al. Sebaceous differentiation in poroid neoplasms: report of 11 cases, including a case of metaplastic carcinoma associated with apocrine poroma (sarcomatoid apocrine porocarcinoma). *Am J Dermatopathol*. 2008;30:21–26.
6. Requena L, Sarasa JL, Piqué E, et al. Clear-cell porocarcinoma: another cutaneous marker of diabetes mellitus. *Am J Dermatopathol*. 1997;19:540–544.
7. Miura K, Akashi T, Namiki T, et al. Engrailed homeobox 1 and cytokeratin 19 are independent diagnostic markers of eccrine porocarcinoma and distinguish it from squamous cell carcinoma. *Am J Clin Pathol*. 2020;154:499–509.
8. Claudy AL, Garcier F, Kanitakis J. Eccrine porocarcinoma. Ultrastructural and immunological study. *J Dermatol*. 1984;11:282–286.
9. Demirkesen C, Tüzüner N, Mat C, et al. Clinicopathologic evaluation of nodular cutaneous lesions of Behçet syndrome. *Am J Clin Pathol*. 2001;116:341–346.
10. Aslan F, Demirkesen C, Çağatay P, et al. Expression of cytokeratin subtypes in intraepidermal malignancies: a guide for differentiation. *J Cutan Pathol*. 2006;33:531–538.
11. Sekine S, Kiyono T, Ryo E, et al. Recurrent *YAPI-MAML2* and *YAPI-NUTM1* fusions in poroma and porocarcinoma. *J Clin Invest*. 2019;129:3827–3832.
12. Russell-Goldman E, Hornick JL, Hanna J. Utility of *YAPI* and *NUT* immunohistochemistry in the diagnosis of porocarcinoma. *J Cutan Pathol*. 2021. [Epub ahead print].
13. Haack H, Johnson LA, Fry CJ, et al. Diagnosis of NUT midline carcinoma using a NUT-specific monoclonal antibody. *Am J Surg Pathol*. 2009;33:984–991.
14. Shiota H, Barral S, Buchou T, et al. Nut directs p300-dependent, genome-wide H4 hyperacetylation in Male germ cells. *Cell Rep*. 2018; 24:3477.e6–3487.e6.
15. French CA, Miyoshi I, Kubonishi I, et al. *BRD4-NUT* fusion oncogene: a novel mechanism in aggressive carcinoma. *Cancer Res*. 2003;63:304–307.
16. Huang QW, He LJ, Zheng S, et al. An overview of molecular mechanism, clinicopathological factors, and treatment in NUT carcinoma. *Biomed Res Int*. 2019;2019:1018439.
17. French CA, Ramirez CL, Kolmakova J, et al. *BRD-NUT* oncoproteins: a family of closely related nuclear proteins that block epithelial differentiation and maintain the growth of carcinoma cells. *Oncogene*. 2008;27:2237–2242.
18. Stelow EB, French CA. Carcinomas of the upper aerodigestive tract with rearrangement of the nuclear protein of the testis (*NUT*) gene (*NUT* midline carcinomas). *Adv Anat Pathol*. 2009;16:92–96.
19. Minato H, Kobayashi E, Nakada S, et al. Sinonasal NUT carcinoma: clinicopathological and cytogenetic analysis with autopsy findings. *Hum Pathol*. 2018;71:157–165.
20. McEvoy CR, Fox SB, Prall OWJ. Emerging entities in *NUTM1*-rearranged neoplasms. *Genes Chromosomes Cancer*. 2020;59:375–385.
21. Stevens TM, Morlote D, Xiu J, et al. *NUTM1*-rearranged neoplasia: a multi-institution experience yields novel fusion partners and expands the histologic spectrum. *Mod Pathol*. 2019;32:764–773.
22. Hormann FM, Hoogkamer AQ, Beverloo HB, et al. *NUTM1* is a recurrent fusion gene partner in B-cell precursor acute lymphoblastic leukemia associated with increased expression of genes on chromosome band 10p12.31-12.2. *Haematologica*. 2019;104:e455–e459.
23. Agaimy A, Tögel L, Haller F, et al. *YAPI-NUTM1* gene fusion in porocarcinoma of the external auditory canal. *Head Neck Pathol*. 2020;14:982–990.
24. Robson A, Greene J, Ansari N, et al. Eccrine porocarcinoma (malignant eccrine poroma): a clinicopathologic study of 69 cases. *Am J Surg Pathol*. 2001;25:710–720.
25. Zahn J, Chan MP, Wang G, et al. Altered Rb, p16, and p53 expression is specific for porocarcinoma relative to poroma. *J Cutan Pathol*. 2019;46:659–664.
26. Requena L, Sánchez M. Poroid hidradenoma: a light microscopic and immunohistochemical study. *Cutis*. 1992;50:43–46.
27. Kuma Y, Yamada Y, Yamamoto H, et al. A novel fusion gene *CRTC3-MAML2* in hidradenoma: histopathological significance. *Hum Pathol*. 2017;70:55–61.