



HAL
open science

In Vivo Corneal Confocal Microscopy in Mucopolipidosis Type IV

Gilles C Martin, Antoinette Bernabe-Gelot, Eric Gabison

► **To cite this version:**

Gilles C Martin, Antoinette Bernabe-Gelot, Eric Gabison. In Vivo Corneal Confocal Microscopy in Mucopolipidosis Type IV. *Ophthalmology: Journal of The American Academy of Ophthalmology*, 2021, 128 (4), pp.521. 10.1016/j.ophtha.2020.11.003 . hal-03242685

HAL Id: hal-03242685

<https://amu.hal.science/hal-03242685>

Submitted on 31 May 2021

HAL is a multi-disciplinary open access archive for the deposit and dissemination of scientific research documents, whether they are published or not. The documents may come from teaching and research institutions in France or abroad, or from public or private research centers.

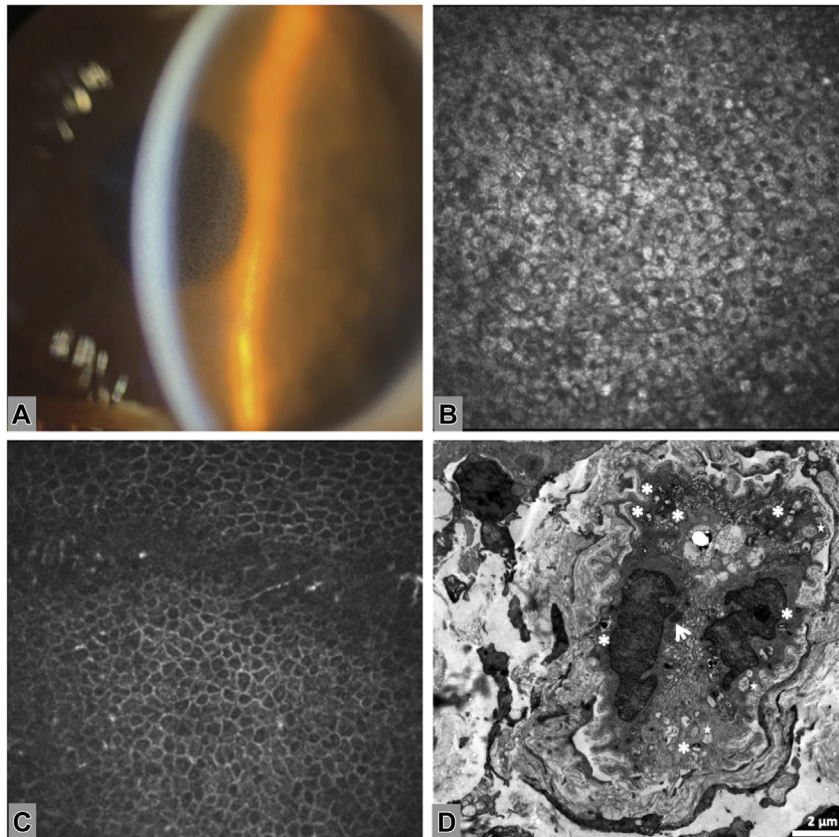
L'archive ouverte pluridisciplinaire **HAL**, est destinée au dépôt et à la diffusion de documents scientifiques de niveau recherche, publiés ou non, émanant des établissements d'enseignement et de recherche français ou étrangers, des laboratoires publics ou privés.



Distributed under a Creative Commons Attribution - NonCommercial - NoDerivatives 4.0 International License

23. United States Census Bureau. Asian alone with one Asian category for selected groups. 2010 Census summary file 1. <https://www.census.gov/history/pdf/2010korean-62017.pdf>, 2017 Accessed 01.07.20.
24. Australian Bureau of Statistics. 2011.0—Census of population and housing: reflecting Australia—stories from the Census, 2016. <https://www.abs.gov.au/ausstats/abs%40.nsf/Lookup/by%20Subject/2071.0~2016~Main%20Features~Cultural%20Diversity%20Article~60>, 2017 Accessed 01.07.20.
25. Ferdi AC, Nguyen V, Samarawickrama C, et al. The impact on work patterns of implementing the Save Sight keratoconus registry in the hospital setting. *Cornea*. 2019;39:451–456.

Pictures & Perspectives



In Vivo Corneal Confocal Microscopy in Mucopolipidosis Type IV

A 7-year-old girl referred for a progressive bilateral visual impairment was found with a diffuse epithelial corneal infiltration appearing as small translucent vesicles (Fig A). Confocal microscopy showed hyperreflectivity of the cytoplasm of the superficial (Fig B) and basal corneal epithelial cells, making the nuclei more visible than in normal eyes (Fig C). This epithelial infiltration in a child of consanguineous union was suspicious for a lysosomal storage disease due to *MCOLN1* mutation: mucopolipidosis type IV. The skin biopsy confirmed this diagnosis, showing heterogeneous inclusions in the endothelial cells cytoplasm on electron microscopy (Fig D): multivesicular bodies (arrow), osmiophilic bodies (asterisks), and electron-empty vesicles (stars) (Magnified version of Fig A–D is available online at www.aaojournal.org).

GILLES C. MARTIN, MD¹

ANTOINETTE BERNABE-GELOT, MD^{2,3}

ERIC GABISON, MD, PhD¹

¹Rothschild Foundation Hospital, Ophthalmology Department, Paris, France; ²Trousseau University Hospital, APHP, Pathology Department, Paris, France; ³INMED, INSERM, Aix-Marseille University, Marseille, France