



Soft-Tissue Management and Neurovascular Protection During Opening-Wedge High Tibial Osteotomy

Kristian Kley, Hamid Rahmatullah Bin Abd Razak, Raghbir S Khakha,
Adrian J Wilson, Ronald van Heerwaarden, Matthieu Ollivier

► To cite this version:

Kristian Kley, Hamid Rahmatullah Bin Abd Razak, Raghbir S Khakha, Adrian J Wilson, Ronald van Heerwaarden, et al.. Soft-Tissue Management and Neurovascular Protection During Opening-Wedge High Tibial Osteotomy. *Arthroscopy Techniques*, 2021, 10, pp.e419 - e422. 10.1016/j.eats.2020.10.020 . hal-03245875

HAL Id: hal-03245875

<https://amu.hal.science/hal-03245875>

Submitted on 2 Jun 2021

HAL is a multi-disciplinary open access archive for the deposit and dissemination of scientific research documents, whether they are published or not. The documents may come from teaching and research institutions in France or abroad, or from public or private research centers.

L'archive ouverte pluridisciplinaire **HAL**, est destinée au dépôt et à la diffusion de documents scientifiques de niveau recherche, publiés ou non, émanant des établissements d'enseignement et de recherche français ou étrangers, des laboratoires publics ou privés.



Distributed under a Creative Commons Attribution - NonCommercial - NoDerivatives 4.0
International License

Soft-Tissue Management and Neurovascular Protection During Opening-Wedge High Tibial Osteotomy



Kristian Kley, M.D.,
Hamid Rahmatullah Bin Abd Razak, M.B.B.S., F.R.C.S.Ed. (Orth), F.A.M.S.,
Raghibir S. Khakha, M.B.B.S., B.Sc., M.Sc., M.R.C.S., F.R.C.S.,
Adrian J. Wilson, M.B.B.S., B.Sc., F.R.C.S. (Tr&Orth),
Ronald van Heerwaarden, M.D., Ph.D., and Matthieu Ollivier, M.D., Ph.D.

Abstract: Medial opening-wedge high tibial osteotomy (OW-HTO) is an excellent surgical option for patients with varus knee osteoarthritis. Medial collateral ligament (MCL) release and posterior neurovascular structure protection during OW-HTO are steps that often induce stress and nervousness during surgery, especially for surgeons in the earlier stages of their learning curve. While it is well-known that the MCL should be released during OW-HTO, the standard retraction techniques pose challenges in visualization and instrument placement in the surgical field. We present our technique, which illustrates an alternative method to manage the MCL and safely protect the neurovascular structures using a second and more posterior surgical window during OW-HTO.

The medial opening-wedge high tibial osteotomy (OW-HTO) is a robust surgical option for treatment of medial compartment osteoarthritis with varus malalignment.¹ Despite good outcomes, complication rates following OW-HTO have been consistently reported to be around 30%.² Although rare (1.7%), neurovascular injury following OW-HTO is devastating when it occurs.² To prevent neurovascular injury, several techniques have been previously described, including the use of a protective cutting system,³ patient-specific cutting guides,⁴ and computer-assisted navigation.⁵ There has been much discussion about the management of the medial collateral ligament

(MCL) following OW-HTO.^{6,7} It is well-known that the MCL has to be released in OW-HTO.⁶ In a standard approach for OW-HTO, the MCL is raised subperiosteally to the posteromedial tibia before a large retractor is placed behind the tibia to protect the neurovascular structures (NVS). However, the surgical assistant often has to fight against the resistance of the intact MCL, and this poses challenges in visualization and instrument placement in the surgical field. The purpose of this article is to present, in detail, a technique to manage the MCL and safely protect the NVS using a second and more posterior surgical window during OW-HTO.

From London Osteotomy Centre, Harley Street Specialist Hospital, London, United Kingdom (K.K., H.R.B.A.R., R.S.K., A.J.W., R.v.H.); Orthoprofis, Hannover, Germany (K.K.); SingHealth Duke-NUS Musculoskeletal Sciences Academic Clinical Programme, Singapore (H.R.B.A.R.); Department of Orthopaedic Surgery, Sengkang General Hospital, Singapore (H.R.B.A.R.); Department of Orthopedics and Traumatology, St. Marguerite Hospital, Aix Marseille Univ, APHM, CNRS, ISM, Institute of Movement and Locomotion, Marseille, France (M.O.); Department of Orthopaedics, Guys & St Thomas's Hospital, London, United Kingdom (R.S.K.); Department of Sports and Exercise, University of Winchester, Winchester, United Kingdom (A.J.W.); and Centre for Deformity Correction and Joint Preserving Surgery, Kliniek Via-Sana, Mill, The Netherlands (R.v.H).

The authors report that they have no conflicts of interest in the authorship and publication of this article. Full ICMJE author disclosure forms are available for this article online, as [supplementary material](#).

Received August 16, 2020; accepted October 17, 2020.

Address correspondence to Dr. Matthieu Ollivier, M.D., Ph.D., Department of Orthopedics and Traumatology, St. Marguerite Hospital, Aix Marseille Univ, APHM, CNRS, ISM, Institute of Movement and Locomotion, 270 Boulevard Sainte Marguerite, BP 29, 13274, Marseille, France. E-mail: matthieu.ollivier@ap-hm.fr

© 2020 by the Arthroscopy Association of North America. Published by Elsevier. This is an open access article under the CC BY-NC-ND license (<http://creativecommons.org/licenses/by-nc-nd/4.0/>).

2212-6287/201414

<https://doi.org/10.1016/j.eats.2020.10.020>

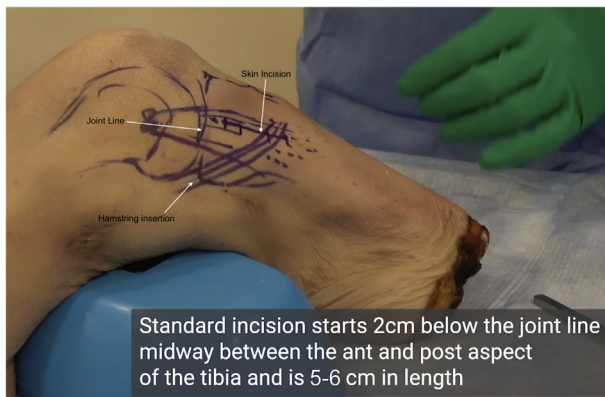


Fig 1. Anatomical landmarks to determine skin incision.

Surgical Technique (With Video Illustration)

Positioning and Draping

After induction of general or spinal anesthesia, the patient is positioned supine. The use of a pneumatic tourniquet is based on surgeon's preference. The leg is prepared and draped in a sterile fashion.

Diagnostic Arthroscopy

A diagnostic arthroscopy is performed to confirm medial compartment disease and exclude significant chondral lesions in the lateral and patellofemoral compartments.

Surgical Procedure

The surgical procedure is presented in [Video 1](#). To summarize, the knee is positioned in a flexed position. A medial approach to the proximal tibia is performed with an oblique skin incision running from the posterosuperior to anteroinferior aspect, starting 2 cm

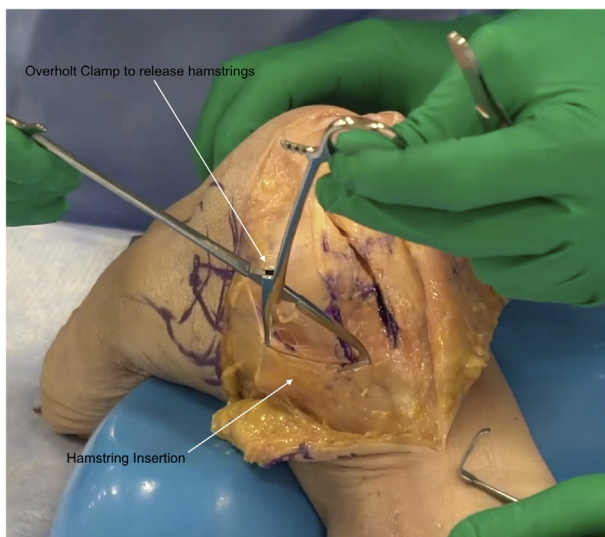


Fig 2. An Overholt clamp is placed underneath the hamstrings and the jaws are opened to release them.

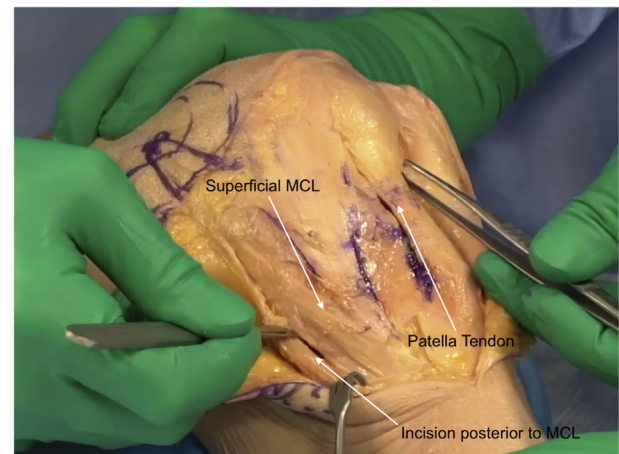

Fig 3. Demonstration of a window being created posterior to the superficial MCL to allow access to the posterior cortex. (MCL, medial collateral ligament.)

below the tibiofemoral joint line and extending 5 to 6 cm toward the distal tibia ([Fig 1](#)). The edge of the patellar tendon is then bluntly dissected and marked in preparation for the biplane osteotomy cut along the tibial tubercle. A subcutaneous soft-tissue dissection exposes the pes anserinus. The pes anserinus is dissected by inserting and spreading the jaws of an Overholt clamp ([Fig 2](#)). After its posterior retraction, the vertical fibers of the MCL are easily identified. Instead of retracting the MCL and placing a posterior retractor from its anterior border, we create a second soft-tissue window at the posterior border of the MCL ([Fig 3](#)). Starting at the posterior border of the MCL, a periosteal elevator is used to dissect the soft tissue until the posterior cortex of the tibia is reached and the popliteus muscle carefully released ([Fig 4](#)). This elevator is then left in place to guide the posterior tissue retractor (Newclip Technics, Nantes, France) between the posterior cortex and popliteus muscle ([Fig 5](#)).

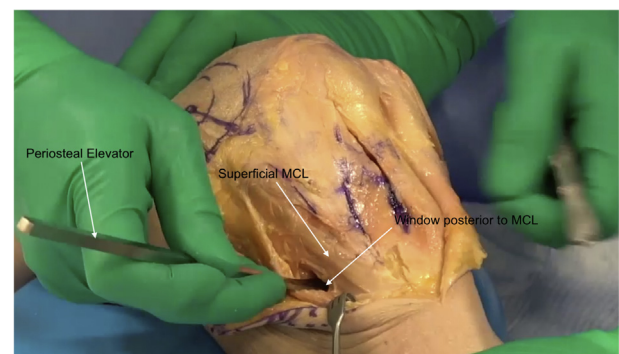


Fig 4. A periosteal elevator is run along the posterior tibial cortex to create a safe passage for the neurovascular protector. (MCL, medial collateral ligament.)

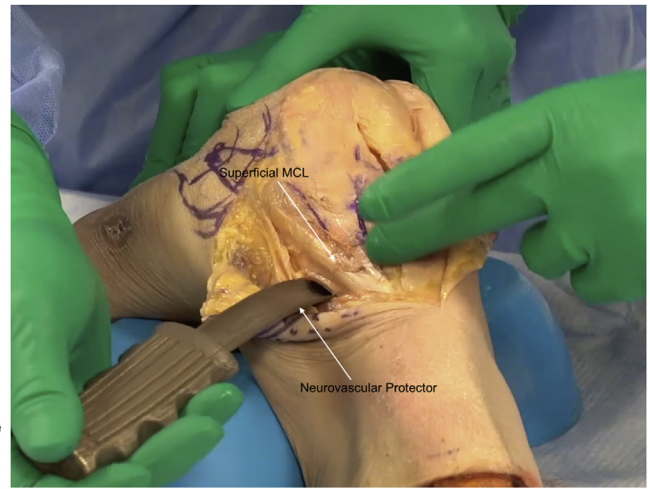
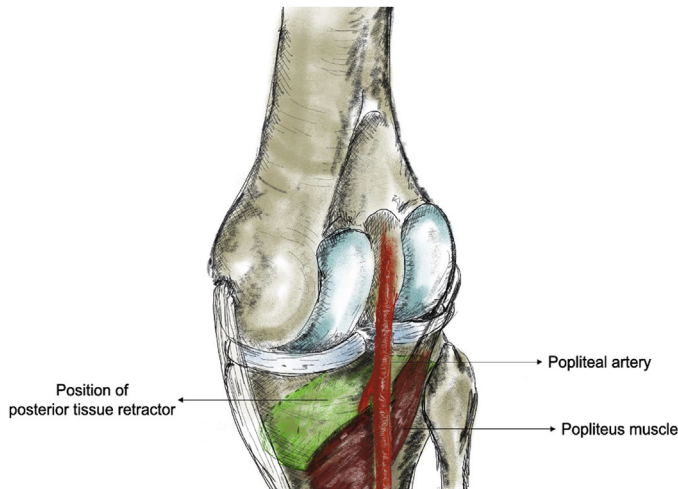


Fig 5. Graphical and anatomical representation of the posterior aspect of the knee showing the neurovascular bundle and popliteus muscle. The green highlighted area shows the position of the posterior tissue retractor (PTR). (MCL, medial collateral ligament.)

This step can be done with the knee in flexion to facilitate insertion. After the posterior tissue retractor (PTR) has been inserted, the periosteal elevator is removed progressively and is used as a “feeler” to palpate the posterior aspect of the tibia and with 180° twists, used to confirm that there is no intervening soft tissue trapped between the posterior aspect of the tibia and the PTR. The deep MCL and proximal tibial attachment of the MCL remain attached. The distal part of the superficial MCL is then released and a small Hohmann retractor is used to retract it, presenting the medial proximal tibial surface for the osteotomy (Fig 3). Following the saw cuts for the osteotomy under fluoroscopic control, a metal ruler or a chisel is used to palpate the PTR through the osteotomy gap to confirm that the posterior tibial cortex has been completely osteotomized. The wedge opening is then performed by

placing a spreader device, posterior to the MCL along the cut posterior cortex. The MCL tension can be assessed and a pie-crusting technique can be used for further fine-tuning. Usually, a small release of the posterior fibers of the MCL allows sufficient lengthening, while maintaining the integrity of the superficial MCL (Fig 6). The rest of the procedure can be undertaken in standard fashion.

Postoperative Protocol

Patients are allowed to weight bear fully if tolerated, with full range of motion and if needed, with the aid of crutches. Chemoprophylaxis against venous thromboembolism is prescribed for 3 weeks.

Discussion

The OW-HTO is an excellent option for younger patients with varus osteoarthritis, given that outcomes following total knee arthroplasty in this patient group are poor.^{8,9} While OW-HTO has been gaining popularity in recent years, it has been shown that the learning curve for OW-HTO ranges from 27 to 42 procedures.¹⁰ Despite good outcomes, complication rates following OW-HTO have been consistently reported to be around 30%.² We believe that our described technique can reduce the complications of tibial plateau fractures as well as neurovascular injuries.

Tibial plateau fractures following OW-HTO has an incidence that ranges from about 1% to 11%.¹¹ This usually occurs from an incomplete osteotomy. With our technique, we can confirm that there is no intervening soft tissue between the PTR and the posterior cortex of the tibia. The surgeon can then confidently complete the planned osteotomy cut, leaving the lateral hinge intact. This should reduce the risk of tibial plateau fractures.

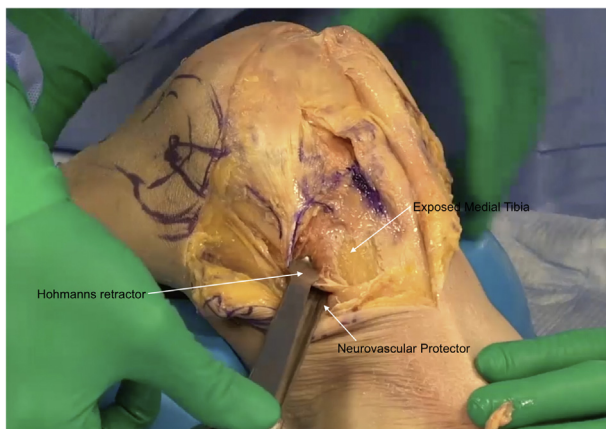


Fig 6. Anatomical representation of the posterior tissue retractor protecting the neurovascular structures and a mini-Hohmann presenting the medial aspect of the tibia for osteotomy.

Table 1. Advantages and Disadvantages of the Second Window Approach

Advantages
Prevention of excessive tension on MCL
Excellent protection of posterior neurovascular structures
Offers opportunity for more controlled release of MCL following osteotomy
Disadvantages
Potential injury to posterior neurovascular structures without appropriate instruments
MCL, medial collateral ligament.

According to the literature, there are anatomical variants in the division of the popliteal artery. An aberrant high branching of the anterior tibial artery running posterior to the popliteus muscle has been previously reported.^{12,13} Therefore, placement of the PTR after releasing of the popliteus off the posterior aspect of the proximal tibia will offer excellent protection of the NVS while the surgeon saws the posterior tibial cortex. Feedback of contact between the saw tip and the PTR confirms that the posterior cortex has been osteotomized. Although rare (1.7%), neurovascular injury following OW-HTO is devastating when it occurs.²

Besides offering complete protection of the NVS, positioning the posterior retractor through a second surgical window along the posterior border of the MCL allows us to perform a controlled and patient-specific release following opening of the osteotomy. We could potentially prevent both excessive pressure (from under-release) on the medial compartment and medial instability (from over-release). Our technique also has some disadvantages. A broad and sharp periosteal elevator is required to dissect the soft tissue until the posterior cortex of the tibia is reached and the popliteus muscle carefully released. Without the appropriate tool, there is danger of injuring the neurovascular structures. The advantages and disadvantages of our technique are presented in Table 1.

To conclude, we are convinced that by creating a secondary window posterior to the MCL allows excellent protection of the posterior neurovascular structures, prevents collision of retractors and the power instruments, and allows us to perform a more controlled release of the MCL following the osteotomy.

References

1. Bonasia DE, Dettoni F, Sito G, et al. Medial opening wedge high tibial osteotomy for medial compartment overload/arthritis in the varus knee: Prognostic factors. *Am J Sports Med* 2014;42:690-698.
2. Kim JH, Kim HJ, Lee DH. Survival of opening versus closing wedge high tibial osteotomy: A meta-analysis. *Sci Rep* 2017;7:7296.
3. Lee YS, Lee MC, Kang SG, Elazab A, Oh WS. Open-wedge high tibial osteotomy using a protective cutting system: Technical advancement for the accuracy of the osteotomy and avoiding intraoperative complications. *Arthrosc Tech* 2016;5:e7-e10.
4. Chaouche S, Jacquet C, Fabre-Aubrespy M, et al. Patient-specific cutting guides for open-wedge high tibial osteotomy: Safety and accuracy analysis of a hundred patients continuous cohort. *Int Orthop* 2019;43:2757-2765.
5. Song SJ, Bae DK. Computer-assisted navigation in high tibial osteotomy. *Clin Orthop Surg* 2016;8:349-357.
6. Malinowski K, Sibilska A, Goralczyk A, LaPrade RF, Hermanowicz K. Superficial medial collateral ligament reattachment during high tibial osteotomy: Regulate tension, preserve stability! *Arthrosc Tech* 2019;8:e1339-e1343.
7. Pape D, Duchow J, Rupp S, Seil R, Kohn D. Partial release of the superficial medial collateral ligament for open-wedge high tibial osteotomy: A human cadaver study evaluating medial joint opening by stress radiography. *Knee Surg Sports Traumatol Arthrosc* 2006;14:141-148.
8. Canovas F, Dagneaux L. Quality of life after total knee arthroplasty. *Orthop Traumatol* 2018;104:S41-S46.
9. Niemeläinen M, Moilanen T, Huhtala H, Eskelinen A. Outcome of knee arthroplasty in patients aged 65 years or less: A prospective study of 232 patients with 2-year follow-up. *Scand J Surg* 2018;108:313-320.
10. Lee DK, Kim KK, Ham CU, Yun ST, Kim BK, Oh KJ. The learning curve for biplane medial open wedge high tibial osteotomy in 100 consecutive cases assessed using the cumulative summation method. *Knee Surg Relat Res* 2018;30:303-310.
11. Yapici F, Aykut US, Coskun M, et al. Complications, additional surgery, and joint survival analysis after medial open-wedge high tibial osteotomy. *Orthopedics* 2020;43:303-314.
12. Klecker RJ, Winalski CS, Aliabadi P, Minas T. The aberrant anterior tibial artery: Magnetic resonance appearance, prevalence, and surgical implications. *Am J Sports Med* 2008;36:720-727.
13. Tindall AJ, Shetty AA, James KD, Middleton A, Fernando KW. Prevalence and surgical significance of a high-origin anterior tibial artery. *J Orthop Surg (Hong Kong)* 2006;14:13-16.