



HAL
open science

Minimally Invasive High Tibial Osteotomy Using a Patient-Specific Cutting Guide

Hamid Rahmatullah Bin Abd Razak, Christophe Jacquet, Adrian J Wilson, Raghbir S Khakha, Kristian Kley, Sébastien Parratte, Matthieu Ollivier

► **To cite this version:**

Hamid Rahmatullah Bin Abd Razak, Christophe Jacquet, Adrian J Wilson, Raghbir S Khakha, Kristian Kley, et al.. Minimally Invasive High Tibial Osteotomy Using a Patient-Specific Cutting Guide. *Arthroscopy Techniques*, 2021, 10, pp.e431 - e435. 10.1016/j.eats.2020.10.029 . hal-03245904

HAL Id: hal-03245904

<https://amu.hal.science/hal-03245904v1>

Submitted on 2 Jun 2021

HAL is a multi-disciplinary open access archive for the deposit and dissemination of scientific research documents, whether they are published or not. The documents may come from teaching and research institutions in France or abroad, or from public or private research centers.

L'archive ouverte pluridisciplinaire **HAL**, est destinée au dépôt et à la diffusion de documents scientifiques de niveau recherche, publiés ou non, émanant des établissements d'enseignement et de recherche français ou étrangers, des laboratoires publics ou privés.



Distributed under a Creative Commons Attribution - NonCommercial - NoDerivatives 4.0 International License

Minimally Invasive High Tibial Osteotomy Using a Patient-Specific Cutting Guide



Hamid Rahmatullah Bin Abd Razak, M.B.B.S., F.R.C.S.Ed. (Orth), F.A.M.S.,
Christophe Jacquet, M.D., Adrian J. Wilson, M.B.B.S., B.Sc., F.R.C.S. (Tr&Orth),
Raghubir S. Khakha, M.B.B.S., B.Sc., M.Sc., M.R.C.S., F.R.C.S., Kristian Kley, M.D.,
Sébastien Parratte, M.D., Ph.D., and Matthieu Ollivier, M.D., Ph.D.

Abstract: Medial opening wedge high tibial osteotomy (OW-HTO) is an excellent surgical option for patients with varus knee osteoarthritis. This article presents a technique of performing a minimally invasive OW-HTO using a patient-specific cutting guide (PSCG). Preoperative 3-dimensional planning with computed tomography imaging is essential. The correction parameters, the final plate position, as well as the 3-dimensional position of the hinge as well as wedge are verified preoperatively before the PSCG is produced. After exposure with an oblique incision over the posteromedial tibia, the hamstring tendons are released for later re-attachment and the medial collateral ligament is released slightly. The PSCG is then used to perform the OW-HTO with protection of the posterior neurovascular structures by a retractor placed posterior to the medial collateral ligament. The final fixation of the osteotomy is achieved with a low-profile locking plate and a femoral head allograft wedge.

High tibial osteotomy (HTO) has been an excellent surgical option for patients with knee osteoarthritis (OA) with good long-term outcomes provided the indications are correct and a precise surgical technique is used.¹ The medial opening wedge HTO (OW-HTO) is the workhorse for treatment of medial compartment OA with varus malalignment.² Compared with lateral closing wedge HTO, the 10-year survival rate in OW-HTO has been found to be significantly greater.³ Despite good outcomes, complication rates following OW-HTO have been consistently reported to be around 30%.^{4,5} The most common complications are undisplaced lateral hinge fracture and wound complications.⁴ Vascular injury is very rare (1.7%) following OW-HTO but devastating when it occurs.⁵ Recently, 3-dimensional patient-specific cutting

guides (PSCGs) have offered benefits of increased precision, faster operative time, and decrease in fluoroscopy exposure.⁶ Performing an OW-HTO with PSCG has been shown to produce precise corrections with good functional outcomes with a potential for lowering the complication rates through a minimally invasive (MIS) approach.⁷ The purpose of this Technical Note is to describe a MIS technique of performing a OW-HTO using a PSCG.

Surgical Technique (With Video Illustration)

Indications and Contraindications

Indications for the procedure are patients <60 years of age with isolated medial knee OA (Ahlbäck ≤ 2 or Kellgren and Lawrence <4) and significant

From SingHealth Duke-NUS Musculoskeletal Sciences Academic Clinical Programme, Singapore (H.R.B.A.R.); Department of Orthopaedic Surgery, Sengkang General Hospital, Singapore (H.R.B.A.R.); London Osteotomy Centre, Harley Street Specialist Hospital, London, United Kingdom (H.R.B.A.R., A.J.W., R.S.K., K.K.); Department of Orthopedics and Traumatology, St. Marguerite Hospital, Aix Marseille University, APHM, CNRS, ISM, Institute of Movement and Locomotion, Marseille, France (C.J., M.O.); Department of Sports and Exercise, University of Winchester, Winchester, United Kingdom (A.J.W.); Department of Orthopaedics, Guys & St Thomas's Hospital, London, United Kingdom (R.S.K.); Orthoprofit Hannover, Hannover, Germany (K.K.); and International Knee and Joint Centre, Abu Dhabi, United Arab Emirates (S.P.).

The authors report the following potential conflicts of interest or sources of funding: A.J.W., K.K., S.P., and M.O. are paid consultants for Newclip Technics, outside the submitted work. S.P. is a consultant for Zimmer Biomet,

outside the submitted work. M.O. is a consultant for Stryker and Arthrex, outside the submitted work. K.K. is a consultant for Stryker, outside the submitted work. Full ICMJE author disclosure forms are available for this article online, as [supplementary material](#).

Received August 10, 2020; accepted October 18, 2020.

Address correspondence to Dr. Matthieu Ollivier, M.D., Ph.D., Department of Orthopedics and Traumatology, St. Marguerite Hospital, Aix Marseille Univ, APHM, CNRS, ISM, Institute of Movement and Locomotion, 270 Boulevard Sainte Marguerite, BP 29, 13274, Marseille, France. E-mail: matthieu.ollivier@ap-hm.fr

© 2020 by the Arthroscopy Association of North America. Published by Elsevier. This is an open access article under the CC BY-NC-ND license (<http://creativecommons.org/licenses/by-nc-nd/4.0/>).

2212-6287/201388

<https://doi.org/10.1016/j.eats.2020.10.029>

metaphyseal tibial vara (medial proximal tibial angle $<85^\circ$). Contraindications are advanced OA (Ahlbäck >2), evidence of symptomatic patellofemoral, or lateral knee OA and previous surgery and hardware or bony abnormalities that would interfere with obtaining high-quality computed tomography (CT) imaging.

Preoperative Planning

A preoperative CT scan is obtained and a virtual OW-HTO is performed. The 3-dimensional planning determines the planes of the osteotomy as well as the dimensions of the wedge to be opened in the proximal tibia for the desired correction. An ACTIVMOTION HTO plate (Newclip Technics, Haute-Goulaine, France) is then virtually placed on the tibia. The PSCG design accommodates the planes of the osteotomy as well as the positions of the screw holes on the plate postcorrection. The aim of the PSCG is to define the optimal plate position after OW-HTO correction and to feedback this anatomical position to the preosteotomy guide position. When the final position of the plate fits the holes drilled using the PSCG following the OW-HTO, we would have achieved our target correction.

Surgical Procedure (Video 1)

The procedure is shown in [Video 1](#). Surgery is performed with the patient placed in a dorsal decubitus position under general anaesthesia with a thigh tourniquet. A 6-cm slightly oblique vertical incision is placed along the posteomedial surface of the tibia, commencing 1 cm below the medial joint line and taken distally to the distal aspect of the tibial tuberosity. The hamstring tendons need to be either detached or released posteriorly to allow for the insertion of the PSCG. In this case, the hamstring tendons were detached and the medial collateral ligament (MCL) was exposed and released slightly using the Cobb elevator ([Fig 1](#)).

The 2 components of the PSCG are then clipped together and applied to the medial surface of the tibia. Care must be taken not to remove any osteophytes, as the PSCG is anatomical. The anterior component is positioned below the patellar tendon and the 2 posterior legs are placed between the posterior surface of the tibia and the MCL. Starting posterior to the MCL, a small periosteal elevator is then used to “scratch” the posterior bony surface of the tibia until it reaches the posterior aspect of the fibular head. A radiolucent

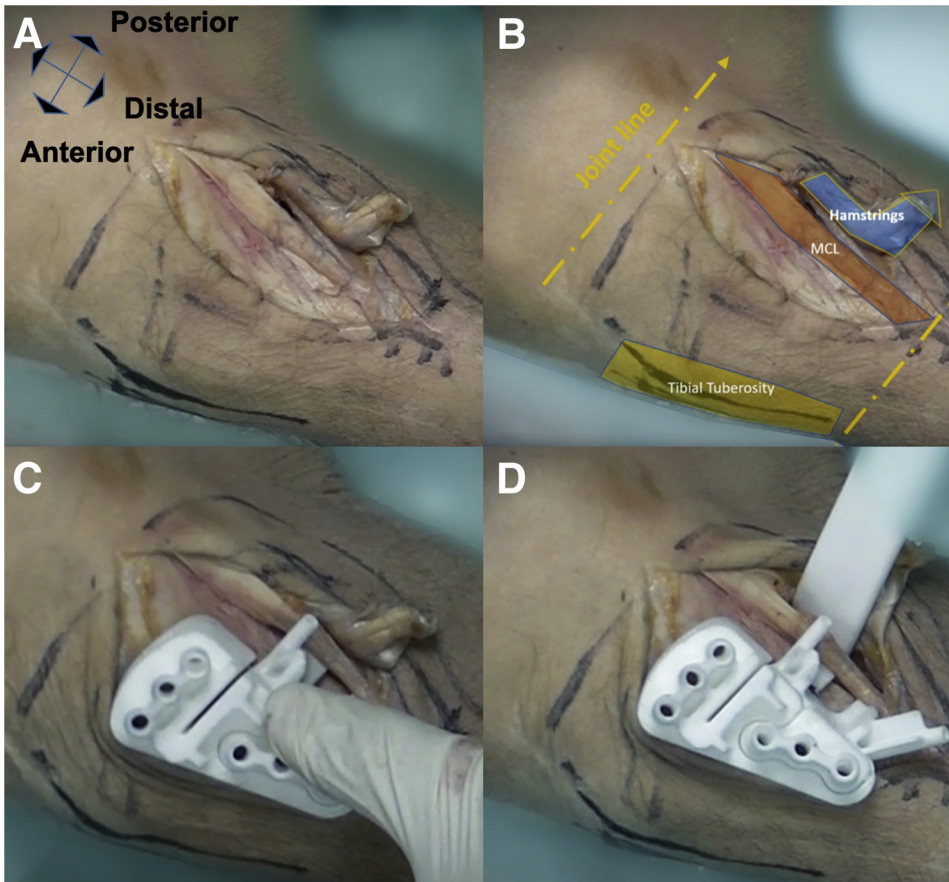


Fig 1. (A) A 6-cm oblique incision is placed along the posteromedial surface of the tibia. (B) An incision is placed 1 cm below the medial joint line and taken distally to the distal aspect of the tibial tuberosity. (C) The PSCG anterior bracket is placed inferior to the patellar tendon and anterior to the posterior oblique ligament. (D) The posterior neurovascular bundle is protected by using a tissue protector that is posterior to the posterior oblique ligament, scratching the posterior surface of the tibia directed toward the fibular head anterior to the popliteus muscle. (PSCG, patient-specific cutting guide.)

Hohmann retractor is then positioned posterior to the MCL, “scratching” the posterior bony surface of the tibia, anterior to the popliteus muscle.

Two 2.2-mm Kirshner wires (K-wires) are then inserted through the PSCG to ensure the trajectory of the osteotomy (horizontal wire) as well as to protect the lateral hinge (oblique wire) (Fig 2). The MCL is protected by an anteriorly placed retractor. The fluoroscopic position of the PSCG is then checked against the position on virtual planning. A 4-mm drill bit is then used through 6 pinholes of the PSCG and secured with adapted. The saw blade is guided by a specific slotted capture of the PSCG. The medial cortex and the first few centimeters of trabecular bone are then cut. To finalize the cut, the proximal pins and the upper part of the guide are then removed. The insertion depth of the saw blade is then marked according to the computed depth to avoid injury to lateral structures. The cut is achieved when the saw blade gets in contact with the hinge pin at the computed depth. An ascending biplane cut is then performed using “free-hand” technique to isolate the tibial tuberosity from the rest of the proximal

tibia. The horizontal K-wire and the PSCG are then removed. The oblique wire is left in situ. The holes drilled through the PSCG are then marked carefully to aid subsequent plate positioning.

An osteotome is then used to ensure that the posterior cortex of the proximal tibia is completely cut. The osteotomy is then progressively opened using osteotomy wedges, with care taken to avoid a lateral hinge fracture (Fig 3). A laminar spreader is then applied to maintain the osteotomy gap posterior to the MCL. A bone wedge, fashioned from cryopreserved femoral head allograft, is then placed in the osteotomy gap. The locking plate is then applied using the predrilled holes and the 4-mm pins are reinserted. Once the plate holes coincide with the predrilled holes, we know that the planned corrected is achieved. The plate is then secured with screws. The hamstrings are then reinserted anteriorly using resorbable sutures.

Postoperative Protocol

Patients are allowed to weight bear fully if tolerated, with full range of motion and if needed, with the aid of

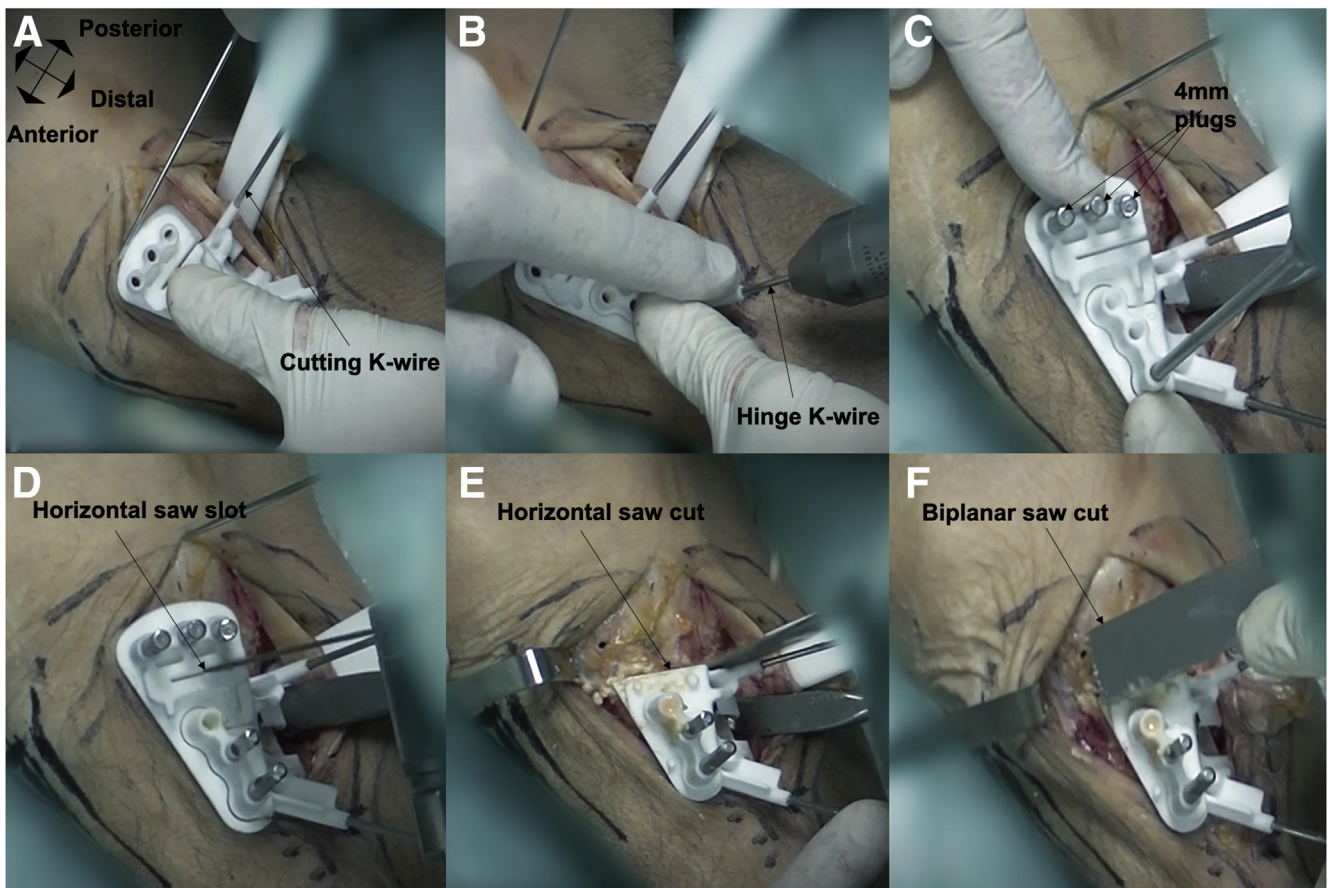


Fig 2. (A) The cutting K-wire that allows control of the saw blade to avoid misdirection is inserted through the PSCG. (B) The hinge K-wire that protects the inadvertent saw penetration of the hinge is inserted through the PSCG. (C) 4-mm plugs are inserted into the proximal tibia holes (which correspond to the plate screw holes) to secure the PSCG. (D) The horizontal saw cut is commenced through the slot in the PSCG. (E) The upper part of the PSCG is removed and the horizontal saw cut is completed. (F) A free-hand biplanar saw cut is performed. (PSCG, patient-specific cutting guide.)

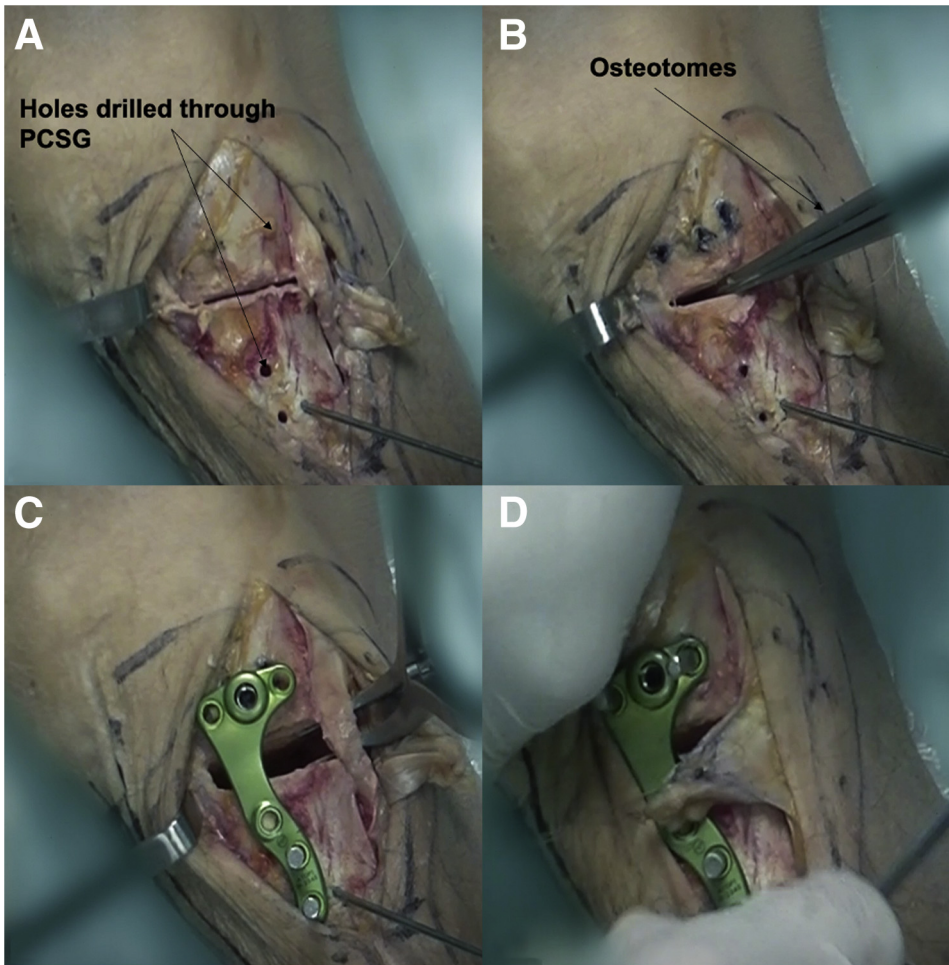


Fig 3. (A) After the saw cuts, the protective K-wire is left in place during the opening to enhance hinge resistance to fracture. (B) The osteotomy is gradually opened using osteotomes. (C) The final opening is made when the plate is secured on the distal tibia using 4-mm plugs with a laminar spreader opening the osteotomy posteriorly until the previously drilled proximal tibial holes match the respective plate holes. (D) The hamstring tendons are reattached onto the anterior tibia using nonresorbable sutures

crutches. Chemoprophylaxis against venous thromboembolism is prescribed for 3 weeks.

Discussion

The OW-HTO is an excellent option for younger patients with varus OA, given that outcomes following TKA in this patient group are poor.^{8,9} Lee et al.¹⁰ reported that incidence of undercorrection, lateral hinge fracture, and excessive posterior slope change following OW-HTO could be reduced by surgical experience and concluded that differences in the incidence of surgical errors in OW-HTO may be due to different learning curves of the surgeons. OW-HTO with PSCG offers accuracy and reliability in achieving the desired corrections.^{11,12} Surgeons are also able to understand in 3 dimensions the effect of their saw cuts and hinge position through the preoperative planning process. These factors may play a part in smoothing the learning curve for OW-HTO. We would like to emphasize that osteophytes and/or other bony irregularities should not be removed before the placement of the PSCG as its position is based on the CT images acquired

preoperatively. This will ensure accurate placement of the PSCG over the proximal tibia, which is essential to prevent complications such as a hinge fracture. Other pearls and pitfalls have been described in [Table 1](#). In the

Table 1. Pearls and Pitfalls

Pearls	Pitfalls
1. Care must be taken not to remove any osteophytes or bony irregularities before placement of the PSCG, as its position is based on the CT acquired bony anatomy.	1. There is risk of neurovascular injury if dissection posterior to the MCL is not performed well
2. The deepest fibers of the patellar tendon should be cleared to create sufficient space for the anterior bracket of the PSCG.	2. 18% risk of benign lateral hinge fractures—Takeuchi type 1 ⁷
3. Marking of the saw blade based on the computed depth minimizes the risk of injury to the lateral structures, and hinge fracture	

CT, computed tomography; MCL, medial collateral ligament; PSCG, patient-specific cutting guide.

Table 2. Advantages and Disadvantages

Advantages	Disadvantages
1. 3-dimensional preplanned correction of deformities are all integrated within the patient-specific cutting guide	1. The correct metaphyseal deformity on the correct bone must be pre-determined by the surgeon beforehand
2. Virtual osteotomy can be performed by the surgeon preoperatively to define the ideal saw cuts, gap creation, screw sizes, and saw depth, so that hinge complications can be avoided	2. Multiple attempts to position the PSCG might be required to achieve the preplanned position
3. The hinge protection wire can be substituted with a 3.5-mm cannulated screw in the event of a hinge fracture	3. Protection of the NVB must be checked and re-checked throughout the surgery, as the PSCG does not offer protection of the NVB on its own

NVB, neurovascular bundle; PSCG, patient-specific cutting guide.

event of an inadvertent hinge fracture, the hinge wire that was inserted through the PSCG can be easily exchanged for a 3.5-mm cannulated screw. This is one of the advantages of using the PSCG (Table 2).

The minimally invasive approach described also allows excellent protection of the posterior neurovascular structures with a Hohmann retractor placed posterior to the MCL as opposed to the traditional subperiosteal dissection of the MCL in an anterior-to-posterior direction. This allows the MCL to be retracted separately with a smaller retractor such as a MacDonald elevator and prevents collision of retractors and the power instruments.

The MIS technique to perform OW-HTO with PSCG described in this Technical Note provides a safe and easy approach to achieve excellent correction in varus knee osteoarthritis.

References

1. Lee DC, Byun SJ. High tibial osteotomy. *Knee Surg Relat Res* 2012;24:61-69.

2. Bonasia DE, Dettoni F, Sito G, et al. Medial opening wedge high tibial osteotomy for medial compartment overload/arthritis in the varus knee: Prognostic factors. *Am J Sports Med* 2014;42:690-698.
3. Kim JH, Kim HJ, Lee DH. Survival of opening versus closing wedge high tibial osteotomy: A meta-analysis. *Sci Rep* 2017;7:7296.
4. Han SB, In Y, Oh KJ, Song KY, Yun ST, Jang KM. Complications associated with medial opening-wedge high tibial osteotomy using a locking plate: A multicenter study. *J Arthroplasty* 2019;34:439-445.
5. Woodacre T, Ricketts M, Evans JT, et al. Complications associated with opening wedge high tibial osteotomy—A review of the literature and of 15 years of experience. *Knee* 2016;23:276-282.
6. Perez-Mananes R, Burro JA, Manaute JR, Rodriguez FC, Martin JV. 3D surgical printing cutting guides for open-wedge high tibial osteotomy: Do it yourself. *J Knee Surg* 2016;29:690-695.
7. Chaouche S, Jacquet C, Fabre-Aubrespy M, et al. Patient-specific cutting guides for open-wedge high tibial osteotomy: Safety and accuracy analysis of a hundred patients continuous cohort. *Int Orthop* 2019;43:2757-2765.
8. Klit J, Jacobsen S, Rosenlund S, Sonne-Holm S, Troelsen A. Total knee arthroplasty in younger patients evaluated by alternative outcome measures. *J Arthroplasty* 2014;29:912-917.
9. Parvizi J, Nunley RM, Berend KR, et al. High level of residual symptoms in young patients after total knee arthroplasty. *Clin Orthop Relat Res* 2014;472:133-137.
10. Lee DK, Kim KK, Ham CU, Yun ST, Kim BK, Oh KJ. The learning curve for biplane medial open wedge high tibial osteotomy in 100 consecutive cases assessed using the cumulative summation method. *Knee Surg Relat Res* 2018;30:303-310.
11. Munier M, Donnez M, Ollivier M, et al. Can three-dimensional patient-specific cutting guides be used to achieve optimal correction for high tibial osteotomy? Pilot study. *Orthop Traumatol Surg Res* 2017;103:245-250.
12. Victor J, Premanathan A. Virtual 3D planning and patient specific surgical guides for osteotomies around the knee: A feasibility and proof-of-concept study. *Bone Joint J* 2013;95-b:153-158.