

Revised version

1 ***Methanobrevibacter smithii* tonsillar phlegmon: A case report.**

2

3 Djemai, K <sup>1,2</sup>, Gouriet, F <sup>1,2</sup>, Michel, J <sup>3</sup>, Radulesco, T <sup>3</sup>, Drancourt, M <sup>1,2</sup>, Grine, G <sup>2,4\*</sup>

4

5 <sup>1</sup> Aix-Marseille Univ, IRD, MEPHI, Marseille, France.

6 <sup>2</sup> IHU Méditerranée Infection, Marseille, France.

7 <sup>3</sup> CHU Hôpital de la Conception, Service ORL et chirurgie cervico-faciale, Marseille,

8 France.

9 <sup>4</sup> Aix-Marseille Université, UFR Odontologie, Marseille, France.

10

11

12 **\*Corresponding author** : Ghiles GRINE, PhD

13 IHU Méditerranée Infection, 19-21 Boulevard Jean Moulin, 13005 Marseille, France.

14 Tel: +33 4 13 73 24 01; Fax: +33 4 13 73 24 02.

15 **Email:** [grineghiles@gmail.com](mailto:grineghiles@gmail.com).

16

17

18 **Word count Abstract = 50**

19 **Word count Text = 1.149**

20 **ABSTRACT**

21 Untreated tonsillar phlegmon is a life-threatening condition commonly caused by  
22 *Streptococcus pyogenes* and *Fusobacterium necrophorum* among other pathogens. Here using  
23 specific laboratory tools, we detected *Methanobrevibacter smithii* in addition to *S. pyogenes*.  
24 This unprecedented observation questions the role of methanogens in phlegmon, and the  
25 optimal treatment of these mixed infection.

26

27 **Keywords:** *Methanobrevibacter smithii*, methanogens, tonsillar phlegmon, *Streptococcus*  
28 *pyogenes*.

29

30 **INTRODUCTION**

31 Tonsillar phlegmon, a retropharyngeal abscess resulting from the infection of the  
32 peritonsillar space and the pharyngeal constrictor muscle through the connective tissue of the  
33 amygdala [1], is a life-threatening situation in the case of cellulitis with extension to the  
34 mediastinum and potential extensive venous thrombosis up to the cavernous sinus [2].

35 Tonsillar phlegmon is affecting particularly adolescent and young adults [3], complicating  
36 acute pharyngitis, recurrent pharyngitis, and chronic tonsillitis [4].

37 Current microbiological documentation, mostly based on direct microscopic  
38 observation and culture of pus specimen, yields a polymicrobial infection of aerobic and  
39 anaerobic bacteria, dominated by *Streptococcus pyogenes* (Group A *Streptococcus*), the only  
40 established pathogen in tonsillar abscess [5-7]. Also, Streptococci (*S. pyogenes*, *Streptococcus*  
41 *milleri*, *Streptococcus viridans*), *Haemophilus spp* and anaerobes including *Fusobacterium*  
42 *necrophorum*, *Fusobacterium nucleatum*, *Prevotella melaninogenica*, *Prevotella intermedia*  
43 and *Peptostreptococcus spp* are isolated from most patients (82% to 90%) [2, 8, 9].

44 In this situation of bacterial tonsillar phlegmon, detection of methanogenic archaea,  
45 mainly represented by *Methanobrevibacter smithii* (*M. smithii*), the most abundant  
46 methanogenic archaea species in the human gut [10] and recently emerging as co-pathogen in  
47 various disease situations [11-14] would requires specific laboratory methods.

48 Accordingly, Here, we have used such specific methods we are mastering, to explore  
49 the presence of methanogens in one case of tonsillar phlegmon.

50 **Case presentation.** A 22-year-old man was admitted to the emergency unit for a two-day  
51 progressively worsening dysphagia with odynophagia and bilateral pharyngeal pain,  
52 associated with sweating without fever. The patient self-treated with paracetamol without  
53 antibiotic nor non-steroidal anti-inflammatory drugs. Clinical examination revealed bilateral

54 inflammatory oropharynx and trismus, no sign of cellulitis, nor palpated cervical  
55 lymphadenopathy. Nasofibroscope disclosed no lesion in the oropharynx with mobile and free  
56 vocal cords. Remarkable laboratory test values included leukocytosis at 17 G/L with  
57 neutrophilic cells 12G/L and C-reactive protein at 132 mg/L. A cervical CT scan showed  
58 bilateral tonsillar hypertrophy with a left tonsillar phlegmon without extension to the  
59 prevertebral space and without anomalies on the internal jugular venous, and bilateral cervical  
60 adenopathies (Figure 1). Intravenous amoxicillin and clavulanic acid 1gr three times a day  
61 and metronidazole 500 mg three times a day was started 24 hours before the patient benefited  
62 from a surgical drainage of the left phlegmon. Per-operative papillomatosis was observed on  
63 the left tonsil, as confirmed by pathology which disclosed inflammatory papilloma without  
64 dysplasia. The pus collected from the phlegmon was immediately inoculated into one aerobic  
65 and one anaerobic blood culture bottles (Virtuo; bioMérieux, La Balme les Grottes, France),  
66 incubated in the BACT/ALERT® VIRTUO® automaton (bioMérieux). Growth was detected  
67 in aerobic and anaerobic bottles after 3.6 and 4.3-hour incubation respectively, and direct  
68 microscopic examination yielded Gram-positive cocci. Broth culture was inoculated on  
69 Chocolate agar PolyViteX medium (bioMérieux) and COLUMBIA ANC medium  
70 (bioMérieux), incubated at 37°C under 5% CO<sub>2</sub> for 5 days to grow aerobic bacteria; and 5%  
71 sheep blood Columbia agar medium (bioMérieux) incubated under strict anaerobiosis at 37°C  
72 for 10 days to grow anaerobic bacteria. After 24-hour incubation, colonies grown on  
73 Columbia and Chocolat PolyViteX media, and then identified as *Streptococcus pyogenes*  
74 using matrix-assisted laser desorption/ionization time-of-flight mass spectrometry (MALDI-  
75 TOF-MS) as previously described [15]. Antibiotic susceptibility testing was done on the  
76 isolated strain as previously described [16] and indicated a wild-type *S. pyogenes* susceptible  
77 to amoxicillin, erythromycin, vancomycin, teicoplanin, clindamycin and pristinamycin; and  
78 exhibiting a low-level susceptibility to gentamicin. The final antibiotherapy was amoxicillin

79 and clavulanic acid 1gr three times a day and metronidazole 500 mg three times a day for 10  
80 days. The patient was cured after 15 days of follow up.

81 For molecular detection of methanogens, DNA was extracted from the pus sample using the  
82 automat extractor EZ1 advanced XL with EZ1 DNA Tissue kit (Qiagen, Courtaboeuf, France)  
83 after 20-minute sonication. Amplification of the archaeal 16S rRNA gene was performed as  
84 previously described [14]. Sequencing the amplicon yielded 100 % sequence similarity with  
85 the reference *M. smithii* ATCC 35061 homologous sequence (GenBank accession number  
86 NC\_009515).

87 Further, to determine whether the pus sample was monomicrobial or polymicrobial, we  
88 completed the routine bacteriological investigations by using the rapid culturomic protocol as  
89 previously described [17]. Seven cultured bacterial species including *Morganella morganii*,  
90 *Klebsiella pneumoniae*, *Klebsiella oxytoca*, *Proteus mirabilis*, *Escherichia coli*, *Enterococcus*  
91 *faecalis* and *Bacteroides vulgatus*, were finally identified by MALDI-TOF-MS [15]. However,  
92 tentative isolation of *M. smithii* failed.

## 93 **DISCUSSION**

94 We are reporting the unprecedented detection of the methanogen *M. smithii* in the pus  
95 sample collected from a tonsillar phlegmon. While this detection was ascertained by the  
96 negativity of the negative controls and the fact that amplicon was sequenced, the very same  
97 pus also yielded a total of eight different bacterial species, in agreement with previous  
98 knowledge regarding the bacterial species reported to be associated with tonsillar phlegmon  
99 [18-20].

100 Until now, the presence of methanogens has never been reported in tonsil infections,  
101 this is due to the fact that methanogens are not systematically searched, and their culture  
102 remains fastidious. Here, the reason for no growth of *M. smithii* may be attributed to the fact

103 that methanogens are extremely sensitive to oxygen and to the fact that phlegmon pus was  
104 collected after the patient received metronidazole, one of few antibiotics shown to be *in vitro*  
105 effective against methanogens [21].

106 Although previously unreported, here detection of *M. smithii* in a tonsillar pus was not  
107 surprising as *M.smithii* is known to colonize the oral fluid microbiota [22], being further  
108 implicated in oral cavity dysbiosis such as periodontitis and peri implantitis [23, 24]. The  
109 presence of methanogens in saliva reinforces the hypothesis of a possible inflammation of the  
110 salivary glands that would cause tonsillar phlegmon [2, 25].

111 In this patient, *M. smithii* was detected in a pus sample also containing eight different  
112 bacterial species and such an association of *M. smithii* with bacteria, chiefly anaerobes, is  
113 constant in all the previous descriptions of *M. smithii* coinfections [11-14]. These bacteria  
114 essentially belong to the enterobacterial and Bacteroidal orders comprising of hydrogen  
115 producers [26, 27]. Here, we suggest the possible involvement of *M. smithii* in this mixed  
116 infection by promoting the growth of aerobic and anaerobic bacteria via syntrophic  
117 interactions which are the real pathogens. The exact mechanism is still poorly understood, but  
118 it would seem that methanogens control the production of essential growth factors for  
119 bacteria, such as short-chain fatty acids, by continuously maintaining a low partial pressure of  
120 H<sub>2</sub> [28, 29] and may also play occasional roles in the development of tonsillar phlegmon as  
121 well as spread of infection.

122 In conclusion, this case report indicates that tonsillar phlegmon should no longer be  
123 regarded as a bacterial infection, but rather an infection mixing anaerobes with methanogens.  
124 When the relative role of these different microorganisms should be reevaluated as  
125 methanogens are producing methane which is a tissue and cell damage [30, 31], potentially  
126 responsible for gas radiologically visible in some cases of tonsillar phlegmon [32, 33], it

127 further questions the importance of prescribing antibiotics active against methanogens, such  
128 as in this patient which medical evolution was favorable.

129

130

131

132

133

134

135

136

137

138

139

140

141

142

143

144

145

146

147

148

149

150

151

152 **Acknowledgments**

153 This work was supported by the French Government under the « Investissements d’avenir »  
154 (Investments for the Future) program managed by the Agence Nationale de la Recherche  
155 (ANR, fr: National Agency for Research) (reference: Méditerranée Infection 10-IAHU-03).

156 **Conflict of interest:**

157 The authors declare no conflicts of interest.

158 **Ethical approval:** Ethical approval was obtained from the IHU Méditerranée Infection Ethic  
159 Committee (No. 2021-010).

160 **Funding:** D.K. benefits from PhD grant by Fondation Méditerranée Infection, Marseille. This  
161 work was supported by the French Government under the «Investissements d’avenir»  
162 (Investments for the Future) program managed by the Agence Nationale de la Recherche  
163 (ANR, fr: National Agency for Research), (reference: Méditerranée Infection 10-IAHU-03).  
164 This work was supported by Region Sud (Provence Alpes Cote d’Azur) and European  
165 funding FEDER PRIMMI.

166 **Author Contributions:** D.K; performed the experiments; data interpretation; manuscript  
167 drafting; G.F; study design and manuscript drafting; M.J and R.T; sample collection and data  
168 interpretation; D.M; study design and implementation, data analysis, results interpretation,  
169 and manuscript writing; G.G; study design and implementation, data analysis, and manuscript  
170 writing. All authors have read and agreed to the published version of the manuscript.

171

172

173

174



175 **REFERENCES**

- 176 1. Klug TE. Peritonsillar abscess: clinical aspects of microbiology, risk factors, and the  
177 association with parapharyngeal abscess. *Dan Med J*. 2017 Mar;64(3): B5333. PMID:  
178 28260599.
- 179 2. Klug TE, Greve T, Hentze M. Complications of peritonsillar abscess. *Ann Clin*  
180 *Microbiol Antimicrob*. 2020 Jul 30;19(1):32.
- 181 3. Risberg S, Engfeldt P, Hugosson S. Incidence of peritonsillar abscess and relationship  
182 to age and gender: retrospective study. *Scand J Infect Dis*. 2008;40(10):792-6.
- 183 4. Powell J, Wilson JA. An evidence-based review of peritonsillar abscess. *Clin*  
184 *Otolaryngol*. 2012 Apr;37(2):136-45.
- 185 5. Galioto NJ. Peritonsillar abscess. *Am Fam Physician*. 2008 Jan 15;77(2):199-202.  
186 PMID: 18246890.
- 187 6. Brook I. The role of anaerobic bacteria in tonsillitis. *Int J Pediatr Otorhinolaryngol*.  
188 2005 Jan;69(1):9-19.
- 189 7. Klug TE, Henriksen JJ, Fuursted K, Ovesen T. Significant pathogens in peritonsillar  
190 abscesses. *Eur J Clin Microbiol Infect Dis*. 2011 May;30(5):619-27.
- 191 8. Jousimies-Somer H, Savolainen S, Mäkitie A, Ylikoski J. Bacteriologic findings in  
192 peritonsillar abscesses in young adults. *Clin Infect Dis*. 1993 Jun;16 Suppl 4: S292-8.
- 193 9. Brook I, Frazier EH, Thompson DH. Aerobic and anaerobic microbiology of  
194 peritonsillar abscess. *Laryngoscope*. 1991 Mar;101(3):289-92.

- 195 10. Dridi B, Henry M, El Khéchine A, Raoult D, Drancourt M. High prevalence of  
196 Methanobrevibacter smithii and Methanosphaera stadtmanae detected in the human gut  
197 using an improved DNA detection protocol. PLoS One. 2009 Sep 17;4(9): e7063.
- 198 11. Nkanga VD, Lotte R, Roger PM, Drancourt M, Ruimy R. Methanobrevibacter smithii  
199 and Bacteroides thetaiotaomicron cultivated from a chronic paravertebral muscle abscess.  
200 Clin Microbiol Infect. 2016 Dec;22(12):1008-1009.
- 201 12. Grine G, Lotte R, Chirio D, Chevalier A, Raoult D, Drancourt M, Ruimy R. Co-  
202 culture of Methanobrevibacter smithii with enterobacteria during urinary infection.  
203 EBioMedicine. 2019 May;43:333-337.
- 204 13. Sogodogo E, Fellag M, Loukil A, Nkanga VD, Michel J, Dessi P, Fournier PE,  
205 Drancourt M. Nine Cases of Methanogenic Archaea in Refractory Sinusitis, an Emerging  
206 Clinical Entity. Front Public Health. 2019 Mar 4; 7:38.
- 207 14. Drancourt M, Djemai K, Gouriet F, Grine G, Loukil A, Bedotto M, Levasseur A,  
208 Lepidi H, Bou-Khalil J, Khelaifia S, Raoult D. Methanobrevibacter smithii archaeemia in  
209 febrile patients with bacteremia, including those with endocarditis. Clin Infect Dis. 2020  
210 Jul 15: ctaa998.
- 211 15. Seng P, Drancourt M, Gouriet F, La Scola B, Fournier PE, Rolain JM, Raoult D.  
212 Ongoing revolution in bacteriology: routine identification of bacteria by matrix-assisted  
213 laser desorption ionization time-of-flight mass spectrometry. Clin Infect Dis. 2009 Aug  
214 15;49(4):543-51.
- 215 16. Haldorsen B, Giske CG, Hansen DS, Helgason KO, Kahlmeter G, Löhr IH,  
216 Matuschek E, Österblad M, Rantakokko-Jalava K, Wang M, Småbrekke L, Samuelsen Ø,  
217 Sundsfjord A; NordicAST CPE Study Group. Performance of the EUCAST disc diffusion

- 218 method and two MIC methods in detection of Enterobacteriaceae with reduced  
219 susceptibility to meropenem: the NordicAST CPE study. *J Antimicrob Chemother.* 2018  
220 Oct 1;73(10):2738-2747.
- 221 17. Naud S, Khelaifia S, Mbogning Fonkou MD, Dione N, Lagier JC, Raoult D. Proof of  
222 Concept of Culturomics Use of Time of Care. *Front Cell Infect Microbiol.* 2020 Nov  
223 23;10:524769.
- 224 18. Gavriel H, Lazarovitch T, Pomortsev A, Eviatar E. Variations in the microbiology of  
225 peritonsillar abscess. *Eur J Clin Microbiol Infect Dis.* 2009 Jan;28(1):27-31.
- 226 19. Johnston J, Stretton M, Mahadevan M, Douglas RG. Peritonsillar abscess: A  
227 retrospective case series of 1773 patients. *Clin Otolaryngol.* 2018 Jun;43(3):940-944.
- 228 20. Slouka D, Hanakova J, Kostlivy T, Skopek P, Kubec V, Babuska V, Pecen L,  
229 Topolcan O, Kucera R. Epidemiological and Microbiological Aspects of the Peritonsillar  
230 Abscess. *Int J Environ Res Public Health.* 2020 Jun 5;17(11):4020.
- 231 21. Khelaifia S, Brunel JM, Raoult D, Drancourt M. Hydrophobicity of imidazole  
232 derivatives correlates with improved activity against human methanogenic archaea. *Int J*  
233 *Antimicrob Agents.* 2013 Jun;41(6):544-7.
- 234 22. Grine G, Terrer E, Boualam MA, Aboudharam G, Chaudet H, Ruimy R, Drancourt M.  
235 Tobacco-smoking-related prevalence of methanogens in the oral fluid microbiota. *Sci*  
236 *Rep.* 2018 Jun 15;8(1):9197.
- 237 23. Efenberger M, Agier J, Pawłowska E, Brzezińska-Błaszczyk E. Archaea prevalence in  
238 inflamed pulp tissues. *Cent Eur J Immunol.* 2015;40(2):194-200.

- 239 24. Sogodogo E, Doumbo O, Aboudharam G, Kouriba B, Diawara O, Koita H, Togora S,  
240 Drancourt M. First characterization of methanogens in oral cavity in Malian patients with  
241 oral cavity pathologies. *BMC Oral Health*. 2019 Oct 30;19(1):232.
- 242 25. Passy V. Pathogenesis of peritonsillar abscess. *Laryngoscope* 1994 ; 104 : 185-90.
- 243 26. Suzuki A, Ito M, Hamaguchi T, Mori H, Takeda Y, Baba R, Watanabe T, Kurokawa  
244 K, Asakawa S, Hirayama M, Ohno K. Quantification of hydrogen production by intestinal  
245 bacteria that are specifically dysregulated in Parkinson's disease. *PLoS One*. 2018 Dec  
246 26;13(12):e0208313.
- 247 27. Smith NW, Shorten PR, Altermann EH, Roy NC, McNabb WC. Hydrogen cross-  
248 feeders of the human gastrointestinal tract. *Gut Microbes*. 2019;10(3):270-288.
- 249 28. Samuel BS, Gordon JI. A humanized gnotobiotic mouse model of host-archaeal-  
250 bacterial mutualism. *Proc Natl Acad Sci U S A*. 2006 Jun 27;103(26):10011-6.
- 251 29. Conway de Macario E, Macario AJ. Methanogenic archaea in health and disease: a  
252 novel paradigm of microbial pathogenesis. *Int J Med Microbiol*. 2009 Feb;299(2):99-108.
- 253 30. Roccarina D, Lauritano EC, Gabrielli M, Franceschi F, Ojetti V, Gasbarrini A. The  
254 role of methane in intestinal diseases. *Am J Gastroenterol*. 2010 Jun;105(6):1250-6.
- 255 31. Piqué JM, Pallarés M, Cusó E, Vilar-Bonet J, Gassull MA. Methane production and  
256 colon cancer. *Gastroenterology*. 1984 Sep;87(3):601-5
- 257 32. Bamgbose BO, Ruprecht A, Hellstein J, Timmons S, Qian F. The prevalence of  
258 tonsilloliths and other soft tissue calcifications in patients attending oral and maxillofacial  
259 radiology clinic of the university of iowa. *ISRN Dent*. 2014 Jan 22; 2014:839635.

260 33. Capps EF, Kinsella JJ, Gupta M, Bhatki AM, Opatowsky MJ. Emergency imaging  
261 assessment of acute, nontraumatic conditions of the head and neck. Radiographics. 2010  
262 Sep;30(5):1335-52.

263

264

265

266

267

268

269

270

271

272

273

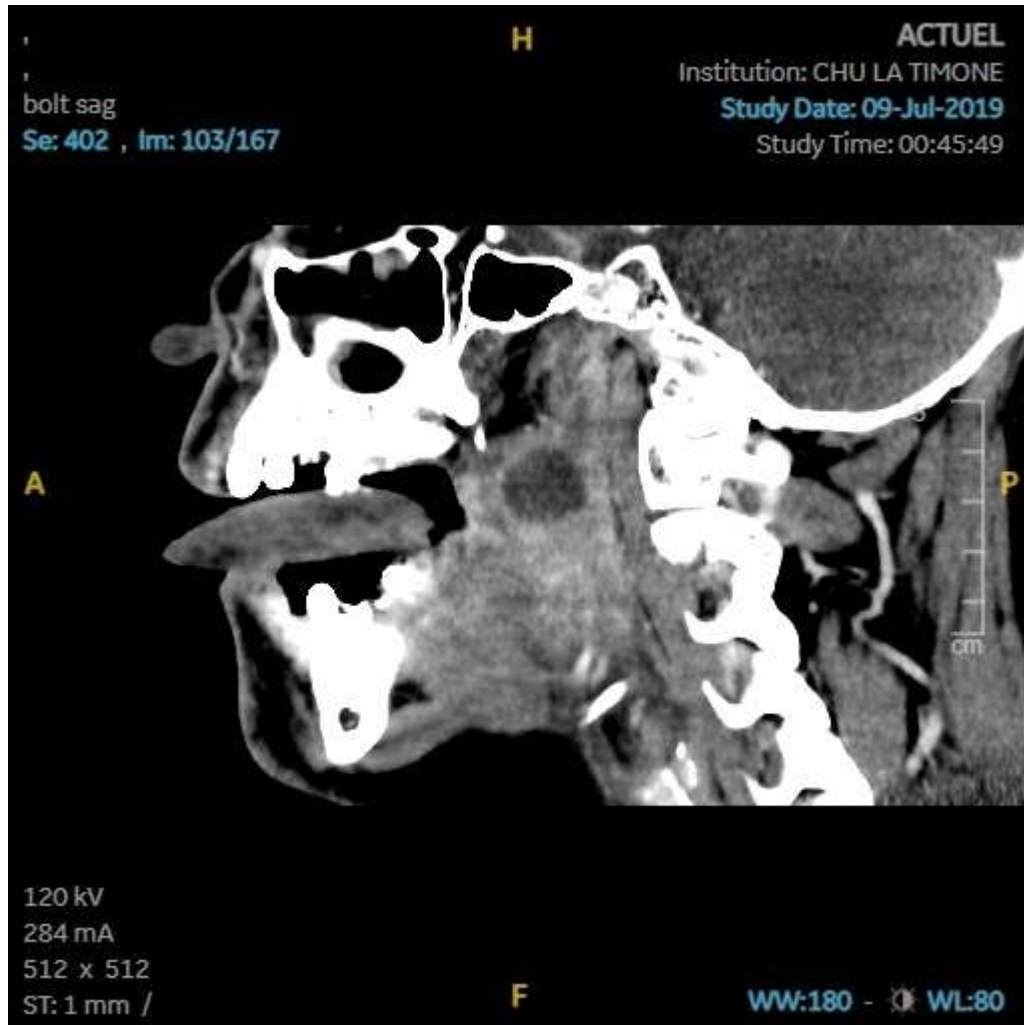
274

275

276

277

278 **Figure 1. head and neck CT-scan sagittal plan showing the tonsillar phlegmon**  
279 **(arrow) in which PCR detected *Methanobrevibacter smithii*, in addition to cultured**  
280 **bacteria.**



281

282

283

284