



**HAL**  
open science

# Robotic Assistance for Minimally Invasive Cervical Pedicle Instrumentation: Report on Feasibility and Safety

Kaissar Farah, Mikael Meyer, Solene Prost, Faisal Albader, Henry Dufour, Benjamin Blondel, Stephane Fuentes

► **To cite this version:**

Kaissar Farah, Mikael Meyer, Solene Prost, Faisal Albader, Henry Dufour, et al.. Robotic Assistance for Minimally Invasive Cervical Pedicle Instrumentation: Report on Feasibility and Safety. World Neurosurgery, 2021, 150, pp.e777-e782. 10.1016/j.wneu.2021.03.150 . hal-03574885

**HAL Id: hal-03574885**

**<https://amu.hal.science/hal-03574885v1>**

Submitted on 4 May 2022

**HAL** is a multi-disciplinary open access archive for the deposit and dissemination of scientific research documents, whether they are published or not. The documents may come from teaching and research institutions in France or abroad, or from public or private research centers.

L'archive ouverte pluridisciplinaire **HAL**, est destinée au dépôt et à la diffusion de documents scientifiques de niveau recherche, publiés ou non, émanant des établissements d'enseignement et de recherche français ou étrangers, des laboratoires publics ou privés.

---

# Robotic Assistance for Minimally Invasive Cervical Pedicle Instrumentation: Report on Feasibility and Safety

Kaissar Farah<sup>1,3</sup>, Mikael Meyer<sup>1,3</sup>, Solene Prost<sup>2,3</sup>, Faisal Albader<sup>1,3</sup>, Henry Dufour<sup>1,3</sup>, Benjamin Blondel<sup>2,3</sup>, Stephane Fuentes<sup>1,3</sup>

■ **BACKGROUND:** Accurate screw placement remains challenging, especially in the cervical spine. We present our first experience of minimally invasive posterior cervical and upper thoracic pedicle screw fixation in the lower cervical spine.

■ **METHODS:** This study reports a case series of patients, undergoing posterior percutaneous pedicle fixation using Cirq robotic assistance coupled to the Airo intraoperative computed tomography scan and Brainlab navigation system. Routine computed tomography was performed on postoperative day 2 to evaluate pedicle screw placement. The effective dose was calculated.

■ **RESULTS:** Between February 2020 and December 2020, 7 patients (4 men and 3 women) were treated. The mean age was 58.8 years (range, 29e75 years). Fixation was performed with a cannulated PASS OCT Reconstruction System (Medicrea). Overall, 28 screws were placed within cervical and upper thoracic pedicles. According to the Neo and Heary classification, 85.7% were rated as acceptable and 14.3% as poor. The radiation dose received by the patient was 9.1 mSv (range, 7.7e10.6 mSv). The radiation dose received by the surgical staff was 0 mSv. The postoperative course was excellent.

■ **CONCLUSIONS:** Posterior miniopen fixation using Cirq robotic assistance coupled with an intraoperative computed tomography navigation system is a major innovation that can improve the accuracy of pedicle screw

positioning, with acceptable patient radiation and reduced surgical team exposure.

---

## INTRODUCTION

**P**osterior cervical spine fixation is a valuable surgical technique commonly performed to treat various degenerative, neoplastic, infectious, and traumatic conditions affecting the cervical spine. Most common screw fixation techniques include lateral mass, pedicle, intralaminar, and transfacet screws.<sup>1,2</sup>

Cervical transpedicular screw fixation (CTSF) offers more biomechanical stability than do other types of internal fixation, including lateral mass screw.<sup>3</sup> However, CTSF placement is technically demanding, and the rate of screw malpositioning was reported as 6.7%e29.1% in conventional fluoroscopy procedures.<sup>4,7</sup> This procedure can be performed through an open or minimally invasive approach.

The fundamental aim of minimally invasive techniques is the reduction of approach-related morbidity secondary to muscle trauma, blood loss, and postoperative neck pain.<sup>8,9</sup>

Navigation techniques can also be used for CTSF. However, no previous reports have described the accuracy of CTSF using Cirq robotic assistance (Brainlab AG, Munich, Germany). in conjunction with intraoperative computed tomography (iCT) scan navigation via a minimally invasive approach.

We present our first experience using this technique for cervical and upper thoracic transpedicular screw fixation.

---

### Key words

- Airo navigation
- Cervical spine
- Cirq robotic
- Minimally invasive
- Pedicle screw

### Abbreviations and Acronyms

- CT: Computed tomography  
CTSF: Cervical transpedicular screw fixation  
DLP: Dose length product  
iCT: Intraoperative computed tomography  
OR: Operating room

From the <sup>1</sup>Departments of Neurosurgery and <sup>2</sup>Orthopedic Surgery, and <sup>3</sup>Spine Unit, La Timone University Hospital, Assistance PubliqueHôpitaux de Marseille, Marseille, France

---

## METHODS

### Patient Selection

We report a retrospective study carried out in our institution. Eligible patients were 18 years old or older, undergoing a complementary second-stage miniopen transpedicular screw instrumentation of the lower cervical and/or upper thoracic spine, for trauma, tumor, spondylodiscitis, or degenerative spinal diseases using intraoperative Airo computed tomography (CT) scan in conjunction with BrainLab curve navigation, Cirq robotic assistance (Brainlab AG, Munich, Germany).

All patients had previously undergone first-stage surgery via an anterior approach to the cervical spine. Anterior cervical discectomy fusion or corpectomy fusion for trauma or oncology or degenerative diseases or anterior debridement fusion for spondylodiscitis was performed.

Patient consent and ethics committee approval were obtained under reference 2019-12-12-007 from the ethics committee of Aix-Marseille University.

### Surgical Management and Technique

Under general anesthesia, the patient was placed prone on the Trupf Medical TruSystem 7500 (Hillrom, Batesville, Indiana, USA), a radiolucent table, with the head maintained in a Mayfield holder. The lower cervical spine was in a neutral position. Required equipment consisted of intraoperative Airo CT in conjunction with BrainLab curve navigation, Cirq robotic assistance (Brainlab) and PASS OCT Reconstruction System (Medicrea, Lyon, France). The posterior neck was shaved, scrubbed, prepared, and draped. The patient reference array was clipped onto the 2-pin fixator, which was attached to the radiolucent Mayfield holder and tightened into position next to the surgical field.

The Cirq was directly mounted to the operating room (OR) table rail on the left side of the patient. The field of the acquisition was determined with a skin marker on the sterile drape and spotted with the laser navigation. Once the scan was completed under

apnea to exclude motion artifacts, images were automatically transferred to the BrainLab curve navigation system. Navigation tools were registered. A navigated probe was used to identify the preferred entry point.

A 3-cm left paramedian skin incision was performed. Exposure of the zygapophyseal joints and laminae was achieved at the index level. The Cirq was then aligned and locked firmly in place within the desired screw trajectory. A 1.5-mm diameter navigated drill with image guidance was used through the cannula on the robotic arm to create a pilot hole on the dorsal cortex of the left lateral mass. A K-wire was inserted in the hole to maintain the trajectory for screw placement. Tapping and screw insertion of the PASS OCT Reconstruction System (Medicrea) through the pedicle were performed. The diameter and length of the screw were chosen perioperatively with image guidance help.

The same procedure was repeated for the right side (Figures 1 and 2). A new iCT scan was performed to assess the position of the implants. Once good positioning was confirmed, 2 rods were inserted and the system locked firmly. The wounds were then closed (Figure 3).

### Radiographic Assessment

Routine postoperative CT scans (slice thickness 1 mm) with axial, coronal, and sagittal reconstructions were obtained on post-operative day 2 or 3. They were interpreted by one of the senior authors (K.F.).

Pedicle screw placement accuracy was evaluated according to the Neo classification system for cervical pedicle screws<sup>7</sup> and to the Heary<sup>10</sup> classification system for thoracic pedicle screws. We also dichotomized clinical grades as acceptable (grade 1 for  $\leq$  Neo classification and II for Heary classification) or poor (grade  $>2/II$ ).

### Quantification of Radiation Exposure

For each iCT-based navigation procedure, we reported:

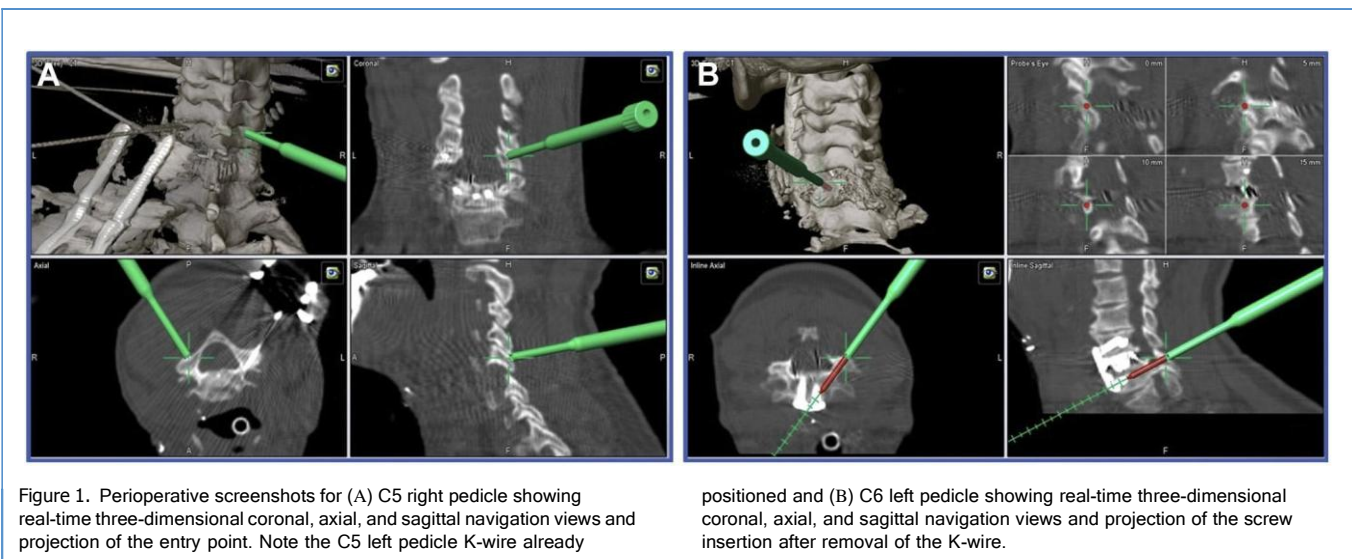




Figure 2. Intraoperative photograph showing the Cirq positioned in a way to use the 1.5-mm-diameter navigated drill with image guidance to create a pilot hole on the dorsal cortex of the right C5 pedicle before introducing the K-wire. Note the other K-wire already positioned within the C5 left pedicle.

- Three-dimensional mode dose length product (DLP) in mGy/cm, defined as the total radiation exposure from iCT
- Effective dose (E) (in mSv) which is a risk-weighted measure of radiation to body organs that can be compared with background radiation levels. It can thus assess a radiologic risk.<sup>11</sup>

Each procedure was calculated using E/DLP ratio as recommended by the European Guidelines for Multislice Computed Tomography<sup>12</sup> ( $E = k \times DLP$ ) ( $k = 0.0059$  for cervical as the region of the body scanned).

All the operative team stayed outside the OR during imaging acquisition.

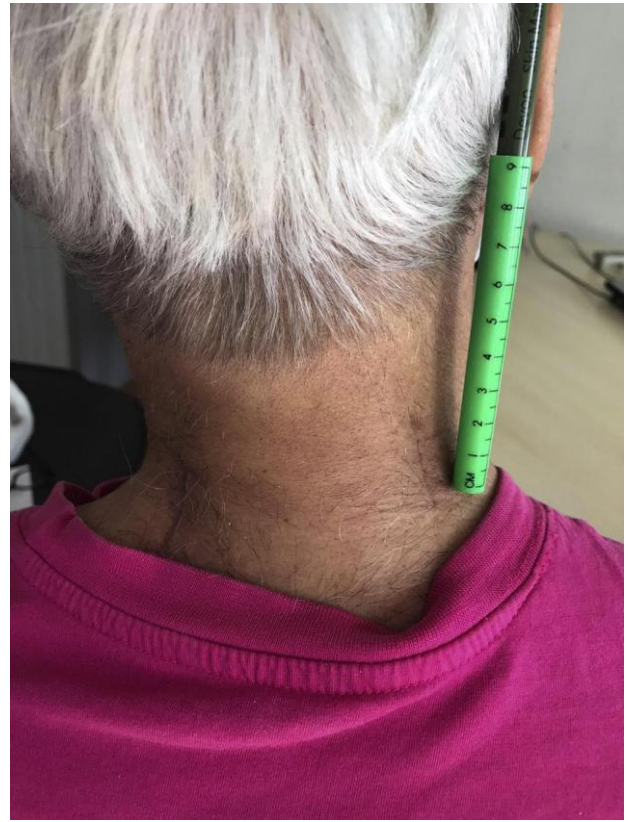

Figure 3. Two 2-cm paramedian vertical wounds.

## RESULTS

### Patient Population

Between February 2020 and December 2020, 7 patients (4 men and 3 women) underwent miniopen transpedicular cervical spine screw instrumentation (Table 1).

The mean age was 58.8 years (range, 29e75 years). The mean body mass index was 24.8 kg/m<sup>2</sup> (range, 17.1e38.05 kg/m<sup>2</sup>).

Five operations were performed for traumatic spine injury (71.4%), 1 for bone metastasis (14.3%), and 1 for infection (14.3%).

The mean surgical time was 115.7 minutes (range, 90e180 minutes). Mean blood loss was 292 mL.

Table 1. Patient Demographics and Surgery Data

	Value
Sex ratio male/female	4:3
Age (years), mean (range)	58.8 (29e75)
Body mass index (kg/m <sup>2</sup> ), mean (range)	24.8 (17.1e38.05)
Surgical time (minutes), mean (range)	115.7 (90e180)
Number of instrumented vertebra	16

### Accuracy of Pedicle Screw Placement

Revision of malpositioned screws was based either on intraoperative judgment by the surgeon or on neurotoxic screw placement (Tables 2 and 3). In this series, no revision for malpositioned screw was needed. Seventeen screws were placed in the pedicles of the lower cervical spine. According to the Neo classification, 11 were grade 0, 3 grade 1, 2 grade 2, and 1 grade 3. For the thoracic spine, according to the Heary classification, 4 were grade I, 1 grade II, 0 grade III, and 0 grade IV. Of these screws, 87.5% were rated as acceptable and 12.5% as poor.

### Radiation Exposure

The mean number of iCT acquisitions for each patient was 3.3 (range, 2-4) (Table 4). Total DLP ranged from 1352.6 to 1803.8 mGy/cm (mean, 1561.2 mGy/cm), which corresponds to 2.77 mSv per single scan. The average total radiation dose for each patient was 9.1mSv (range, 7.7-10.6 mSv). The radiation dose received by the primary surgeon and the rest of the operative team outside the OR, during the imaging acquisition, was considered null.

### Postoperative Course

Patients had minimal postoperative pain, easily controlled by class 1 and/or 2 painkillers. Patients were released home on postoperative day 3-4.

No infection, transfusion, or unplanned return to the OR was reported.

### DISCUSSION

The accuracy and technical advances in CTSF using the Cirq robotic assistance in conjunction with iCT scan navigation were investigated.

CTSF has more advantages than fixation through the spinous process, lamina, and anterior intervertebral plate, but because of

	Number of Patients	Grade			
		0/I	1/II	2/III	3/IV
C1	2	2	0	0	0
C2	0	0	0	0	0
C3	2	1	1	0	0
C4	2	0	1	1	0
C5	2	1	0	1	0
C6	7	6	0	1	0
C7	8	4	1	0	1
T1	2	1	1	0	0
T2	2	2	0	0	0
T3	1	1	3	0	0
Total	28	18	6	3	1

	Neo/Heary (%)
Acceptable	85.7
Poor	14,3

anatomic complexity and possible severe complications, the application of CTSF has been limited.<sup>13</sup>

CTSF is an established technique for spinal stabilization and deformity correction. Its biomechanical advantages include increased bony purchase in the pedicle, and spanning of all 3 columns of the vertebra. It is a more effective technique in restoring segmental lordosis and global cervical lordosis compared with lateral mass fixation.<sup>14-17</sup>

Abumi et al.<sup>18</sup> were the first to introduce this technique in 1994, and there have been many other reports since.<sup>19,20</sup> The most devastating complication associated with this technique is vertebral artery injury and its potentially severe consequences.<sup>21</sup> Other complications such as nerve root injury can also occur.<sup>22</sup>

Recently, intraoperative imaging, navigation systems, and robotic guidance have been developed to assist surgeons in correct screw placement in thoracolumbar<sup>23-27</sup> and upper cervical spine surgery.<sup>28,29</sup> Multiple manufacturers have introduced robotic platforms for use in spine surgery. The current generation of these spinal robots are all designed to assist the surgeon in the placement of screws. In general, these robotic platforms share a similar workflow. In contrast with that of the larger floor-mounted robotic platforms, which are designed to maximize rigidity of the end effector of the robotic arm to minimize motion away from the intended screw trajectory, the Cirq robotic assistance is smaller and lighter (11 kg).<sup>30</sup>

The use of navigation for CTSF was reported with good results; accuracy was up to 95%<sup>31,32</sup> with navigation versus 70%-90% with traditional methods.<sup>33,34</sup> Reports of severe complications were rare. The use of this technique is attractive, especially in traumatology, because in some cases, the articular is fractured and lateral mass instrumentation is more difficult. In this case, performing a 2-level CTSF is less compromising for cervical spine motion (flexion-extension) compared with 3 or 4 levels of lateral mass fixation.

Table 4. Radiation Exposure Data in the Group

	Mean
Number of intraoperative computed tomography acquisitions/patient	3.3
Dose length product (mGy/cm)	1561.2
Radiation dose received by 1 patient (mSv)	9.1
Radiation dose per single scan (mSv)	2.77
Radiation dose received by the primary surgeon performing the imaging acquisition (mSv)	0

---

## Limitations

Some technical limitations are to be noted in our series.

On the one hand, sources of errors were discussed as resulting from the mobility of the lower cervical spine (especially in patients with trauma), registration inaccuracies, and accidental displacement of reference frames. We believe that iCT-based navigation systems should be used when possible when performing posterior fixation in the lower cervical and upper thoracic spine. All sources of potential error of accuracy must be identified and adjusted before the screw placement stage.

On the other hand, we were limited technically, because we could not perform >4 levels per acquisition because of the length and mobility of the robotic arm. Also, we were limited when placing screws on the right side because it was barely possible to reach a higher convergence angle for screw positioning, because of the robotic length and limitation in mobility. In 2 cases, we had to undrape the patient and position the robotic arm on the right side to perform adequate CTSF on the latter side. This situation can explain the less acceptable positioning precision on the right side.

The system that we used for the CTSF seemed adequate because we could easily place the rods within the screw heads. Nevertheless, an adequate system with a cannulated screw should be developed to improve implant placement.

Robotic assistance is a major innovation in spine surgery.<sup>35</sup> In our experience, it reduced muscle trauma and blood loss and allowed an acceptable rate of screw positioning.

Patients undergoing this type of surgery may require shorter hospitalization and encounter fewer medical complications during their stay because of the accurate minimally invasive approach.

We report the first case series of mainly CTSF with Cirq robotic assistance in conjunction with iCT scan navigation. We are at the beginning of the learning curve for this technique.

The overall clinical acceptance rate was good (85.7%). This rate was mainly caused by familiarization with this technology. Nevertheless, no screw repositioning was necessary, specially the one grade 3 in C7.

More cases are needed to assess efficacy, screw placement accuracy, and fusion. Although this technology is designed to assist the surgeon in the placement of screws, a dedicated screw and rod system should be developed to facilitate the surgical workflow.

## CONCLUSIONS

Posterior miniopen fixation using Cirq robotic assistance coupled with iCT navigation system is a major innovation that can improve the accuracy of pedicle screw positioning in the lower cervical and upper thoracic spine. The procedure is associated with acceptable patient radiation and reduced surgical team exposure. Future studies are needed to assess reproducibility, pedicle screw positioning, radiation exposure, and cost-effectiveness.

## CRediT AUTHORSHIP CONTRIBUTION STATEMENT

Kaissar Farah: Conceptualization, Methodology, Writing - original draft, Writing - review & editing. Mikael Meyer: Conceptualization, Writing - original draft, Writing - review & editing. Solene Prost: Writing - original draft, Writing - review & editing. Faisal Albader: Writing - original draft, Writing - review & editing. Henry Dufour: Writing - review & editing. Benjamin Blondel: Writing - review & editing, Supervision. Stephane Fuentes: Conceptualization, Methodology, Writing - review & editing, Supervision.

---

## REFERENCES

1. Joaquim AF, Mudo ML, Tan LA, Riew KD. Posterior subaxial cervical spine screw fixation: a review of techniques. *Global Spine J*. 2018;8:751-760.
  2. Sugimoto Y, Hayashi T, Tokioka T. Minimally invasive cervical pedicle screw fixation via the posterolateral approach for metastatic cervical spinal tumors. *Spine Surg Relat Res*. 2017;1:218-221.
  3. Jones EL, Heller JG, Silcox DH, Hutton WC. Cervical pedicle screws versus lateral mass screws. Anatomic feasibility and biomechanical comparison. *Spine (Phila Pa 1976)*. 1997;22:977-982.
  4. Abumi K, Shono Y, Ito M, Taneichi H, Kotani Y, Kaneda K. Complications of pedicle screw fixation in reconstructive surgery of the cervical spine. *Spine (Phila Pa 1976)*. 2000;25:962-969.
  5. Hojo Y, Ito M, Suda K, Oda I, Yoshimoto H, Abumi K. A multicenter study on accuracy and complications of freehand placement of cervical pedicle screws under lateral fluoroscopy in different pathological conditions: CT-based evaluation of more than 1,000 screws. *Eur Spine J*. 2014;23:2166-2174.
  6. Ishikawa Y, Kanemura T, Yoshida G, Ito Z, Muramoto A, Ohno S. Clinical accuracy of three-dimensional fluoroscopy-based computer-assisted cervical pedicle screw placement: a retrospective comparative study of conventional versus computer-assisted cervical pedicle screw placement. *J Neurosurg Spine*. 2010;13:606-611.
  7. Neo M, Sakamoto T, Fujibayashi S, Nakamura T. The clinical risk of vertebral artery injury from cervical pedicle screws inserted in degenerative vertebrae. *Spine (Phila Pa 1976)*. 2005;30:2800-2805.
  8. Fessler RG, Khoo LT. Minimally invasive cervical microendoscopic foraminotomy: an initial clinical experience. *Neurosurgery*. 2002;51:S37-45.
  9. Ratliff JK, Cooper PR. Cervical laminoplasty: a critical review. *J Neurosurg*. 2003;98:230-238.
  10. Heary RF, Bono CM, Black M. Thoracic pedicle screws: postoperative computerized tomography scanning assessment. *J Neurosurg*. 2004;100:325-331.
  11. The 2007 Recommendations of the International Commission on Radiological Protection. ICRP publication 103. *Ann ICRP*. 2007;37:1-332.
  12. Bongartz G, Golding SJ, Jurik AG, et al. European Guidelines for Multislice Computed Tomography. 2004. Available from: <http://www.dr.s.dk/guidelines/ct/quality/index.htm>. Accessed 2004.
  13. Kandziora F, Pflugmacher R, Scholz M, et al. Posterior stabilization of subaxial cervical spine trauma: indications and techniques. *Injury*. 2005;36(suppl 2):B36-B43.
  14. Dickerman RD, Reynolds AS, Stevens Q, Zigler J. Cervical pedicle screws vs. lateral mass screws: uniplanar fatigue analysis and residual pullout strengths. *Spine J*. 2007;7:384.
  15. Duff J, Hussain MM, Klocke N, et al. Does pedicle screw fixation of the subaxial cervical spine provide adequate stabilization in a multilevel vertebral body fracture model? An in vitro biomechanical study. *Clin Biomech (Bristol, Avon)*. 2018;53:72-78.
  16. Hey HWD, Zhuo WH, Tan YHJ, Tan JH. Accuracy of freehand pedicle screws versus lateral mass screws in the subaxial cervical spine. *Spine Deform*. 2020;8:1049-1058.
  17. Kotani Y, Cunningham BW, Abumi K, McAfee PC. Biomechanical analysis of cervical stabilization systems. An assessment of transpedicular screw fixation in the cervical spine. *Spine (Phila Pa 1976)*. 1994;19:2529-2539.
  18. Abumi K, Kaneda K. Pedicle screw fixation for nontraumatic lesions of the cervical spine. *Spine (Phila Pa 1976)*. 1997;22:1853-1863.
  19. Perna F, Borghi R, Pilla F, Stefanini N, Mazzotti A, Chehrassan M. Pedicle screw insertion techniques: an update and review of the literature. *Musculoskelet Surg*. 2016;100:165-169.
-

- 
20. Yukawa Y, Kato F, Ito K, et al. Placement and complications of cervical pedicle screws in 144 cervical trauma patients using pedicle axis view techniques by fluoroscope. *Eur Spine J.* 2009;18:1293-1299.
  21. Yukawa Y, Kato F, Yoshihara H, Yanase M, Ito K. Cervical pedicle screw fixation in 100 cases of unstable cervical injuries: pedicle axis views obtained using fluoroscopy. *J Neurosurg Spine.* 2006;5:488-493.
  22. Tokioka T, Oda Y. Minimally invasive cervical pedicle screw fixation (MICEPS) via a posterolateral approach. *Clin Spine Surg.* 2019;32:279-284.
  23. Devito DP, Kaplan L, Dietl R, et al. Clinical acceptance and accuracy assessment of spinal implants guided with SpineAssist surgical robot: retrospective study. *Spine (Phila Pa 1976).* 2010;35:2109-2115.
  24. Farah K, Coudert P, Graillon T, et al. Prospective comparative study in spine surgery between O-arm and Airo systems: efficacy and radiation exposure. *World Neurosurg.* 2018;118:e175-e184.
  25. Kantelhardt SR, Martinez R, Baerwinkel S, Burger R, Giese A, Rohde V. Perioperative course and accuracy of screw positioning in conventional, open robotic-guided and percutaneous robotic-guided, pedicle screw placement. *Eur Spine J.* 2011;20:860-868.
  26. Pechlivanis I, Kiriyanthan G, Engelhardt M, et al. Percutaneous placement of pedicle screws in the lumbar spine using a bone mounted miniature robotic system: first experiences and accuracy of screw placement. *Spine (Phila Pa 1976).* 2009;34:392-398.
  27. Tian W. Robot-assisted posterior C1-2 trans-articular screw fixation for atlantoaxial instability: a case report. *Spine (Phila Pa 1976).* 2016;41(suppl 19):B2-B5.
  28. Farah K, Meyer M, Prost S, Dufour H, Blondel B, Fuentes S. Cirq robotic assistance for minimally invasive C1-C2 posterior instrumentation: report on feasibility and safety [e-pub ahead of print]. *Oper Neurosurg (Hagerstown)* <https://doi.org/10.1093/ons/opaa208>, accessed July 25, 2020.
  29. Meyer M, Farah K, Graillon T, Dufour H, Blondel B, Fuentes S. Minimally invasive percutaneous C1-C2 fixation using an intraoperative three-dimensional imaging-based navigation system for management of odontoid fractures. *World Neurosurg.* 2020;137:266-271.
  30. Khalsa SSS, Park P. Commentary: Cirq(R) robotic assistance for minimally invasive C1-C2 posterior instrumentation: report on feasibility and safety[e-pub ahead of print]. *Oper Neurosurg (Hagerstown)* <https://doi.org/10.1093/ons/opaa242>, accessed August 3, 2020.
  31. Ito H, Neo M, Yoshida M, Fujibayashi S, Yoshitomi H, Nakamura T. Efficacy of computer-assisted pedicle screw insertion for cervical instability in RA patients. *Rheumatol Int.* 2007;27:567-574.
  32. Kotani Y, Abumi K, Ito M, Minami A. Improved accuracy of computer-assisted cervical pedicle screw insertion. *J Neurosurg.* 2003;99:257-263.
  33. Reinhold M, Magerl F, Rieger M, Blauth M. Cervical pedicle screw placement: feasibility and accuracy of two new insertion techniques based on morphometric data. *Eur Spine J.* 2007;16:47-56.
  34. Takahata M, Yamada K, Akira I, et al. A novel technique of cervical pedicle screw placement with a pilot screw under the guidance of intraoperative 3D imaging from C-arm cone-beam CT without navigation for safe and accurate insertion. *Eur Spine J.* 2018;27:2754-2762.
  35. Joseph JR, Smith BW, Liu X, Park P. Current applications of robotics in spine surgery: a systematic review of the literature. *Neurosurg Focus.* 2017;42:E2.
-