



**HAL**  
open science

## Fully endoscopic endonasal approach for the treatment of intrasellar arachnoid cysts

Jean D'artigues, Thomas Graillon, Sébastien Boissonneau, Kaissar Farah, Vincent Amodru, Thierry Brue, Stéphane Fuentes, Henry Dufour

► **To cite this version:**

Jean D'artigues, Thomas Graillon, Sébastien Boissonneau, Kaissar Farah, Vincent Amodru, et al.. Fully endoscopic endonasal approach for the treatment of intrasellar arachnoid cysts. Pituitary, 2022, 25 (1), pp.191-200. 10.1007/s11102-021-01187-8 . hal-03574887

**HAL Id: hal-03574887**

**<https://amu.hal.science/hal-03574887v1>**

Submitted on 1 Feb 2023

**HAL** is a multi-disciplinary open access archive for the deposit and dissemination of scientific research documents, whether they are published or not. The documents may come from teaching and research institutions in France or abroad, or from public or private research centers.

L'archive ouverte pluridisciplinaire **HAL**, est destinée au dépôt et à la diffusion de documents scientifiques de niveau recherche, publiés ou non, émanant des établissements d'enseignement et de recherche français ou étrangers, des laboratoires publics ou privés.

# Fully endoscopic endonasal approach for the treatment of intrasellar arachnoid cysts

Jean d'Artigues<sup>1</sup>  · Thomas Graillon<sup>1</sup> · Sébastien Boissonneau<sup>1</sup> · Kaissar Farah<sup>1</sup> · Vincent Amodru<sup>2</sup> · Thierry Brue<sup>2</sup> · Stéphane Fuentes<sup>1</sup> · Henry Dufour<sup>1</sup>

## Abstract

**Purpose** To report our experience of endoscopic endonasal obliteration of symptomatic sellar arachnoid cyst (SAC).

**Methods** From 2002 to 2019, we retrospectively reported the data of 17 cases of SAC operated in Timone University Hospital, Marseille, France. Preoperative clinical findings were collected including main symptoms, visual function and endocrinological assessment. Surgical procedure was homogeneous and consisted in endonasal fully endoscopic surgical obliteration of the cyst cavity with fat graft. Post-operative outcomes, complication and follow-up was reported.

**Results** Visual disorders and/or headaches were the main symptoms. Our technique provided improvement for 83.3% of the patients suffering from visual disturbance and for 87.5% of those suffering from headaches. We reported 2 cases of cerebrospinal fluid (CSF) leakage (11.8%), but no meningitis. One case of definitive diabetes insipidus occurred and one case of postoperative syndrome of inappropriate antidiuretic hormone secretion was temporary. There was one case of recurrence reported. The mean follow-up was 39 months.

**Conclusion** Patients with symptomatic SAC can be treated successfully by endoscopic endonasal obliteration of the cyst. This simple technique offers true benefits for the patients without craniotomy, but the complication rate remains high especially with the risk of CSF leakage. Special attention to skull base opening and closing could reduce this risk.

**Keywords** Intrasellar cyst · Endoscopic surgery · Cyst obliteration · Endonasal approach · Skull base · Arachnoid cysts

## Introduction

Arachnoid cysts are well known in neurosurgical practice and they are traditionally treated by creating a communication with sub arachnoid spaces (SAS), or through shunting systems. Among all locations of arachnoid cyst, those in the sellar region are rare and sparsely described in the literature. Among all intra cranial arachnoid cyst only 3% are sellar arachnoid cyst (SAC) [1]. Relatively to the sellar position, the main presenting symptoms are unusual headaches, visual disturbances, and/or functional disorders due to endocrine deficit.

On brain magnetic resonance imaging (MRI), a liquid cyst without any enhancement of its wall after gadolinium injection, with the same intensity of the cerebrospinal fluid (CSF) [2] can be found. It is sometimes harder to differentiate SAC with other cystic lesions found in the sellar region such as Rathke cleft cyst (RCC), cystic adenoma or craniopharyngioma [3]. The diagnosis is then confirmed by per operative assessment. Meanwhile the continued progress of MRI in recent years helps better characterization of intrasellar cysts [4].

Because of the rarity of the pathology, the treatment of symptomatic arachnoid cyst remains controversial. Major surgical aspects remain concerning: whether the cyst must be fenestrated through SAS or simply obliterated; if the cyst wall must be removed or preserved; finally, if the surgical procedure must be transsphenoidal or transcranial. We hereby present the largest series of fully endoscopic obliteration of symptomatic SAC using the technique previously described by McLaughlin et al. [5].

---

✉ Jean d'Artigues  
Jean.dartigues@hotmail.com

<sup>1</sup> Department of Neurosurgery, Hôpital de La Timone, Marseille, France

<sup>2</sup> Department of Endocrinology, Hôpital de La Conception, Marseille, France

## Method

2430 patients operated on for a sellar pathology were prospectively included in our institutional database between January 2003 and December 2019. Among them: 17 patients had different forms of symptomatic arachnoid cysts that required surgery. The surgical procedure was homogeneous and was performed by the senior author (HD) except two by the second author (TG). This study therefore involved 17 patients.

## Surgical technique

For all patients, we proposed a fully endoscopic transsphenoidal technique. We performed the conventional transsphenoidal endoscopic approach as described by other authors [6, 7]. As much as possible the sphenoid mucosa is respected, and a bipolar coagulation of the sellar floor allows a targeted removal of the mucosa. Drill could be used in case of thick bone found at the sellar floor but in this pathology, the bone is very thinned, and might be opened with a micro spatula. Through cases, the senior author tended to perform smaller sellar floor opening as explained later. The dura mater is then opened in X fashion, and the content of the cyst, which is CSF, immediately flows off. The endoscope is then introduced into the cyst cavity to visualize walls and check the absence of a cystic tumor. No cyst wall removal was performed in order to avoid postoperative CSF leaks. At this point, the sellar diaphragm is prolapsing into the cavity, and the aim of the procedure is to create a “waterproof” barrier at the *diaphragma sellae* stage. Abdominal subcutaneous fat is harvested and set in several pieces to fit in the sella without tension. The fat graft must be placed gently to avoid chiasmal compression or postoperative fat expulsion. To close the sellar floor, collagen patch like Tachosil © or Neuro-Patch © could be used, associated with a rigid biological implant maintaining the fat in its position (Titanium Mesh or Medpore Stryker ©). Surgical glue can also be applied. A Final Valsalva maneuver is made and if CSF is flowing through the floor, additional fat can be placed in the sphenoid sinus with surgical glue keeping it together. No CSF lumbar diversion was used in these cases.

Clinical notes, pre and postoperative radiologic study and hormonal assays were collected. Patients were followed at 3-month, 6-month and then annually with endocrine test, ophthalmologic evaluation, and control MRI-scan.

## Clinical presentation

For each patient, the main symptom that led to medical consultation was mentioned. On postoperative follow up, whether it was visual function disturbance or headaches, we evaluated if it had been improved, worsened or unchanged.

## Visual function

All patients had a preoperative ophthalmologic evaluation comprising a visual acuity test and a visual field examination by Goldman perimetry. Clinical examination was performed daily for the postoperative days. The next evaluation was planned with an ophthalmologist 3 months after the surgery. Thereafter patients had an ophthalmologic examination each year.

## Endocrine assessment

Preoperative and postoperative endocrine status was collected, and it was mentioned if patient's evaluation comprised a corticotropic, gonadotropic, thyretropic or somatotropic deficiency. Hyperprolactinemia due to mass effect in the sellar space was also sought. On postop day 1, we screened all the hypophyseal axes. Similarly, as every sellar region surgery, all patients had a postoperative daily evaluation of hydric balance (urine volume measurement and comparison with all water intakes). Ionic disturbances on blood sample were investigated preoperatively and daily until the patient was discharged from hospital. Between postop day 2 and day 4, if no complication occurred, patients were moved to endocrinology department for further evaluation of pituitary deficiency. Postoperative diabetes insipidus was defined by hypernatremia  $\geq 145$  mmol/L with water intake/outflow balance alteration requiring antidiuretic hormone substitution. The diabetes insipidus was considered transient in case of recovery allowing the discontinuation of antidiuretic hormone substitution.

## Postoperative follow-up

The first postop visit was at the third month with both an endocrinologist and the neurosurgeon that performed the surgery. The next visit was at 6 months and then annually. Headaches and visual disturbance and function evolution were checked. If hormonal deficiency finally recovered, we considered the postoperative hypopituitarism as transient.

## Results

### Preoperative

Among the 17 patients treated 12 were females (sex ratio: 2,4:1). The median age was 46.6 (17; 82) year. The most common presenting symptom was visual disturbance revealed in 11 patients (64.7%), before headaches in 8 patients (47%). Three had both headaches and visual disturbance. For one patient SAC was incidental (transient global amnesia) but the ophthalmologic evaluation revealed a visual field defect. 12 patients (71%) had an objective visual dysfunction which comprised visual field defect (scotoma, bitemporal quadrantanopia or hemianopsia), or loss of visual acuity. The preoperative endocrine assessment showed 3 cases of pituitary hormone deficiency (2 hypothyroidism, one hypogonadism). The radiologic preoperative imaging was available for 15 patients. For 13 patients the largest axis of the cyst was  $\geq 20$  mm (Table 1). Radiologic chiasmatic compression was present in 12 patients.

### Post operative outcome

The median follow-up was 24 months (3–106). Among the 8 patients suffering from headaches, 7 (87.5%) were improved at last follow-up. Visual function was improved in 10 out of the 12 (83.33%) patients with objective visual impairment. For the remained two patients, visual function was worsened. For one of them (an 82-year-old woman) ophthalmologic evaluation attributed the visual degradation to age-related macular degeneration.

Endocrinological outcomes did not show any improvement for the three patients presenting with pituitary deficiency. One patient experienced transient corticotrophic deficiency.

### Complications

Two cases of post-operative CSF leak occurred (11.8%). Both were reoperated. For both, preoperative CT scan and intra operative findings displayed adipose tissue graft expelled into the sphenoid sinus. No meningitis occurred and patient's follow up did not reveal any further complication. At reoperation, new fat graft was introduced in the cyst cavity and sellar floor was strongly reconstructed by titanium MESH©.

Two patients had permanent diabetes insipidus that required daily oral anti diuretic hormone supplementation. In both cases, no operative event could explain this

outcome. One patient suffered from severe hyponatremia attributed to a syndrome of inappropriate anti-diuretic hormone secretion at day 7 postop that recovered after temporary water deprivation and oral salt supplementation.

One 52-year-old woman whose presenting symptom was visual field amputation was operated on. 1 month after surgery and initial recovery she presented an acute spontaneous visual loss. On brain MRI an intrasellar hematoma was seen. Cerebral angiogram did not find vascular abnormality. She was reoperated (by the same technique) and she finally completely recovered. We did not find any explanation for this delayed hematoma. Diabetes insipidus persisted on follow up for this patient.

No case of mortality occurred on postoperative course.

### Recurrence

Recurrence occurred in a 63-year-old woman at three-month follow-up. On iterative post-operative MRI, we assist to reaccumulation of CSF into the cyst (Case 15, Table 1). Radiological and clinical observation were established.

## Discussion

Cystic non neoplastic lesions of the sellar region (excluding cystic craniopharyngiomas and cystic adenomas) arise for 2.8% of the sellar lesions [8]. This category includes RCC and arachnoid cyst which are even less frequent. The diagnosis of SAC is a combination of radiological and per operative findings. On MRI, SACs appear like a cyst filled with CSF: hypointense on T1 weighted and hyperintense on T2 weighted images. The signal of cyst content is typically the same as CSF but can be more intense on T1-weighted sequences [2]. Cyst wall is a thin arachnoid barrier squeezing the normal pituitary gland which is flattened to various positions around the cyst [5]. The diaphragma sellae is seen at the dome of the cyst bending upward to the optochiasmatic structure. Confusion with craniopharyngiomas and RCC may sometimes happen. In these cases, the perioperative aspect of a SAC clears up the doubts (water-like liquid content and non-tissular thin wall). In our experience, histopathological sample is not required when the diagnosis is clear. Furthermore, we believe that the aggression of the cyst wall could lead to pituitary damage, diabetes insipidus and increase the risk of CSF leakage.

### Outcomes

The clinical presentation varies across the consequences of mechanical increase of intrasellar pressure. Headaches is an unspecific typical symptom of sellar mass growth. The physiopathology of headaches in case of sellar compression

**Table 1** Preoperative findings and postoperative outcome

Case number	Age (years)	Sex	Preoperative data			Postoperative data				Follicle up(m)	
			Presenting symptom	Visual fongction	Larger axis size (mm)	Pituitary function	Physical outcome	Visual function	Pituitary function		Complication
1	69	F	Visual disorder	Visual field defect	Missing data	Hypothyroidism	Improved	Improved	Hypothyroidism	None	96
2	57	M	Transient amnesia (incidental finding)	Visual field defect	24	Normal	N	Improved	Normal	None	106
3	27	F	Headaches, visual disorder	Visual field defect	23	Normal	Improved	Improved	Normal	None	67
4	32	M	Headaches, asthenia	Normal	20	Normal	Not improved	Normal	Normal	CSF Leakage	5
5	47	F	Headaches, visual disorder	Visual field defect	17	Hypothyroidism	Improved	Improved	Hypothyroidism	None	91
6	82	F	Visual disorder	Visual field defect + loss of acuity	17	Normal	Not improved	Not improved	Normal	None	24
7	46	F	Headaches, asthenia	Normal	Missing data	Normal	Improved	Normal	Normal	None	73
8	42	M	Visual disorder	Visual field defect + loss of acuity	28	Normal	Improved	Improved	Diabetes insipidus	CSF Leakage	16
9	80	F	Visual disorder	Visual field defect + loss of acuity	19	Normal	Worsened	Worsened	Normal	None	67
10	71	F	Visual disorder	Visual field defect	34	Normal	Improved	Improved	Normal	None	22
11	17	M	Headaches	Visual field defect	26	Normal	Improved	Improved	Normal	None	15
12	38	F	Headaches	Normal	16	Normal	Improved	Normal	Normal	None	3
13	28	F	Headaches	Normal	21	Normal	Improved	Normal	Normal	None	13
14	52	F	Visual disorder	Visual field defect	24	Normal	Improved	Improved	Diabetes insipidus	Delayed Hematoma	24
15	63	F	Visual disorder	Visual field defect	30	Normal	Improved	Improved	Normal	Recurrence	24
16	30	M	Visual disorder	Visual field defect	42	Hypogonadism	Improved	Improved	Not improved	none	3
17	62	F	Headaches, visual disorder	Normal	20	Normal	Improved	Normal	Normal	None	12

is unclear and the causality of the cyst is often questionable. In cases of small cysts only presenting as chronic headaches, the possibility that headaches could be unrelated to the cyst has to be mentioned. The fact that surgery would bring no benefit must be considered and discussed with the patient. In our series, 87.5% of patients were improved after surgery. Similar improvement rate is reported by the other authors [2, 5, 9].

Visual impairment is explained by the compression of the optochiasmatic structures.

Pituitary deficiencies or hyperprolactinemia can occur when the intrasellar pressure reach a critical threshold above which the portal system fails to vascularize the pituitary gland sufficiently [10, 11].

Outcomes on headaches and visual impairment (> 80%) are encouraging. In contrast, pituitary deficiency has not been improved in our experience. Similar results are described for pituitary non-functioning adenoma [12]. And the other series seem to globally agree to this point [2, 5, 9, 13]. Consequently, we would not recommend surgery in the perspective of hormonal recovery in this pathology in case of isolated pituitary deficiency. Hyperprolactinemia must be considered apart and could possibly be improved by surgery, relieving the pressure into the sella [5, 10].

## Pathophysiology and surgical approach

Surgical procedure can be guided by pathophysiology meanwhile the latter is controversial. However, the transsphenoidal approach with cyst obliteration seems to be preferred to cyst fenestration in the previous series [2, 5, 13]. At normal condition, arachnoid space (with both arachnoid and CSF) is absent from the sellar cavity. However authors have demonstrated the presence of arachnoid layers along the pituitary stalk and also surrounding the pituitary body [14]. A trapped intra arachnoid cyst into the sellar space would develop between the arachnoid layers present along the pituitary stalk and gland [13]. On the other hand, a ball-valve mechanism filling the cyst during elevation of intracranial pressure has been proposed to explain the cyst's growth [15]. Therefore, the fenestration of the cyst into SAS or ventricular system has been promoted [16].

Meanwhile, compared to intracranial arachnoid cyst, SAC occur in a normally CSF-free region. We therefore believe that obliteration of the cyst is closer to the anatomy.

## CSF leakage and recurrence

Postoperative CSF leakage can account for 15 to 20% [5]. McLaughlin et al. reported no postoperative leakage in their series of 8 patients compared to 2/17 in this study [5]. This pathology is certainly more at risk of postoperative CSF leakage than pituitary adenomas [17]. Consequently,

the skull base reconstruction must be maximalist even if no CSF leak is observed during the procedure. Intrasellar adipose tissue graft with its hydrophobic properties appears to prevent efficiently postoperative CSF leakage after transsphenoidal surgery [18]. Setting in place enough fat, volume for volume, neither too much, nor too little, ensures the obstruction of the communication between the SAS and the cyst, thus avoiding a post-operative leakage and a recurrence by preventing the cyst from filling up again. We believe that the mechanical action of the graft prevents the diaphragma to collapse and the defect to be enlarged.

As is often the case in surgery, closure should be anticipated at the beginning of the procedure. The sellar floor can be very thin in this pathology and if the aim is only to obliterate the cyst cavity without tissue removal, there is no need for a wide opening. This was precisely demonstrated in the cadaveric work by Catapano et al.: endoscopic transsphenoidal surgery, in comparison with microsurgery performed with a nasal retractor, encourage the surgeon to open the sellar floor significantly wider [19]. Therefore we should resist this temptation in this procedure because the remaining bone helps to keep the fat graft in place. In the two cases of CSF leakage fat graft expulsion was seen intraoperatively at reoperation. A solution could be to pack the fat graft with small pieces, gradually, to fit in a small floor opening. Care must be taken to avoid the overpacking of the sella because it would facilitate the fat expulsion in a Valsalva maneuver in addition to the risk of optic chiasm compression.

We do not use a systematic CSF lumbar diversion because of the potential complications due to this dispositive [20]. We believe that CSF leakage is mainly caused by the expulsion of the sellar packing. CSF lumbar diversion would artificially hide this event and potentially delay the CSF leakage.

The other issue is recurrence by cyst reaccumulation which occurred in one case in our experience. The intrasellar packing remained in the cavity but the cyst had simply refilled at the expense of the fat progressive resorption. Postoperative CT scan attested the complete filling of the entire cyst by the fat, though. We do not have explanation for this recurrence. However larger intrasellar cystic lesions seem to be more at risk of recurrence [21].

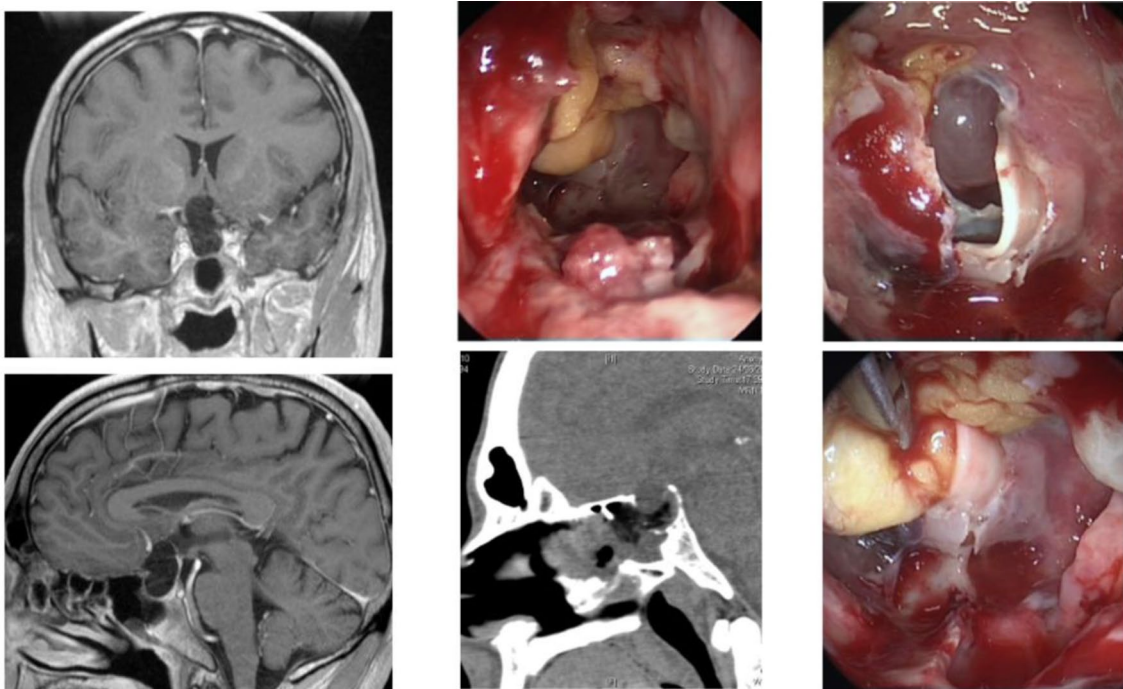
In other words, CSF leakage seems to be secondary to insufficient sellar floor reconstruction whereas cyst reaccumulation could be explained by persistence of communication with SAS. And this latter could probably be prevented by sufficient packing of the cavity.

Complications are mainly consequences of CSF leakage (Table 2). Although, we reported the case of a delayed hematoma found in the cyst cavity 1 month after the surgery leading to a revision surgery. We did not find any etiology for what appears to be a rare complication for this pathology.

The disorders of the salt balance can occur in both sides. Hyponatremia by a syndrome of inappropriate secretion of

**Table 2** Series with more than 3 cases of intrasellar arachnoid cyst

Authors	Number of cases	Surgical technique	Complications	Recurrence
Baskin et al. 1984 [9]	8	Microscopic Transsphenoidal	2 CSF leaks 1 meningitis	None
Meyer et al. 1987 [13]	13	Microscopic Transsphenoidal	1 death by meningitis	None
Shin et al. 1999 [21]	5	Microscopic Transsphenoidal	None	1
Dubuisson et al. 2007 [2]	9	Microscopic Transsphenoidal	2 CSF leaks	None
Cavallo et al. 2008 [26]	10	Endonasal endoscopic/ Microscopic	2 CSF leaks, one meningitis	None
McLaughlin et al. 2012 [5]	8	Microscopic and endonasal endoscopic	None	None
Shim et al. 2013 [16]	6	Transventricular Endoscopic	None	None
Oyama et al. 2014 [22]	6	Endoscopic Transtubercular	None	None

**Fig. 1** On the left part: Preop MRI T1 with gadolinium coronal and sagittal, on the right: fat graft expulsion at postop day 1 visible on CT scanner (sagittal) with reintervention (peroperative endoscopic view)

anti-diuretic hormone has been noticed in our experience but finally returned to normal. Diabetes insipidus, in contrary, was unfortunately definitive in two cases.

The other option to treat an SAC would be the fenestration of the cyst to the supra-sellar arachnoid spaces. The objective in this configuration is to release the CSF trapped in the sellar space. Shim et al. proposed a transventricular endoscopic approach. In this case no CSF leakage occurred due to the absence of skull base opening [16]. But all the cyst treated exceeded 25 mm with important suprasellar expansion. We consider that such procedure would be at risk

of pituitary damage in smaller cysts. Other authors reported fenestration to the SAS by transtuberculum endonasal endoscopic [22], or retrosellar [23], or even transsphenoidal with the fenestration through the diaphragma [24]. But CSF leakage and recurrence rate are higher.

The transcranial fenestration is still performed by some authors with good result [25]. But no recent series assessed the risk of cyst recurrence with this technique. For larger cysts with suprasellar expansion and visual function loss, it would be acceptable to fenestrate it with a minimal invasive craniotomy but for smaller cysts, the morbidity and the

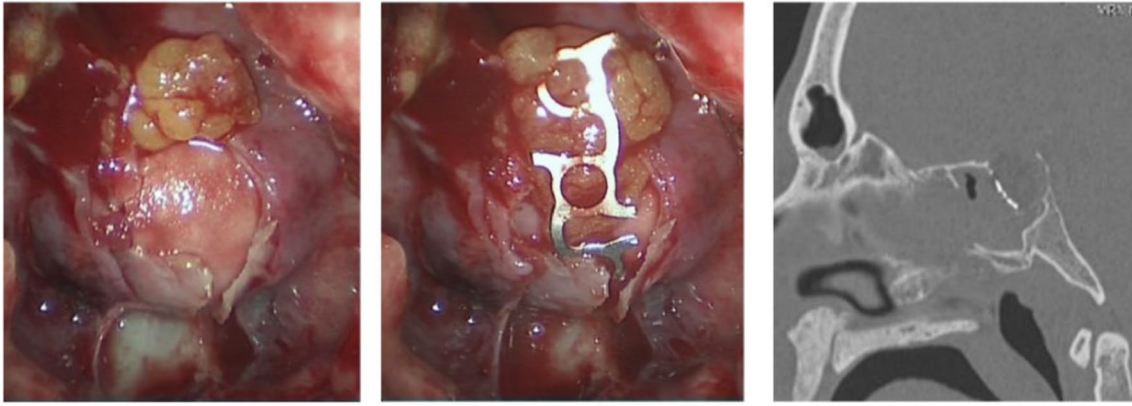


Fig. 2 Surgical reintervention and treatment for fat expulsion

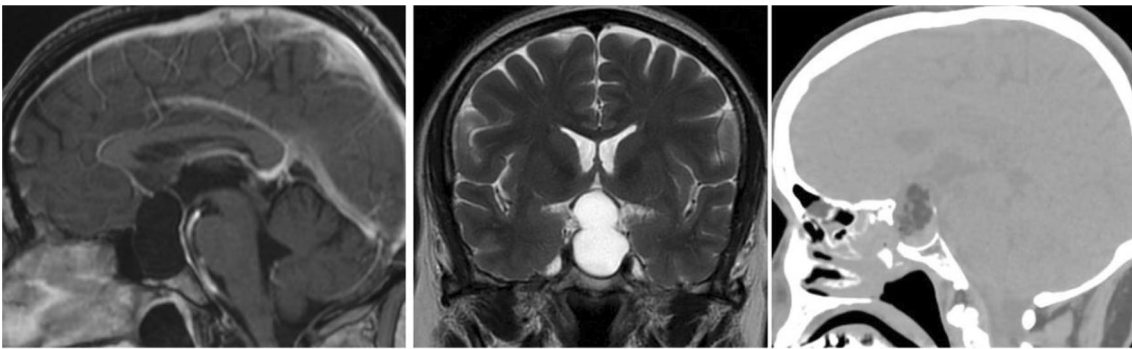


Fig. 3 Preoperative MRI scan and Day one postoperative CT scan

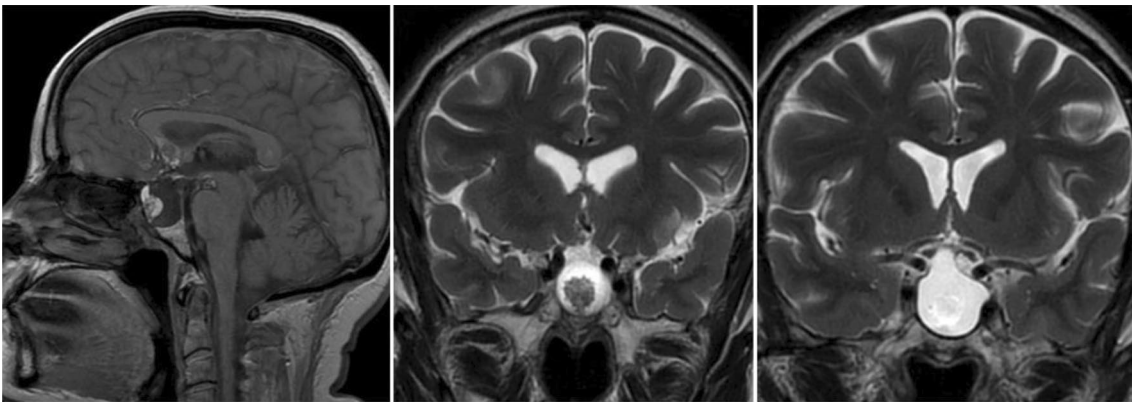


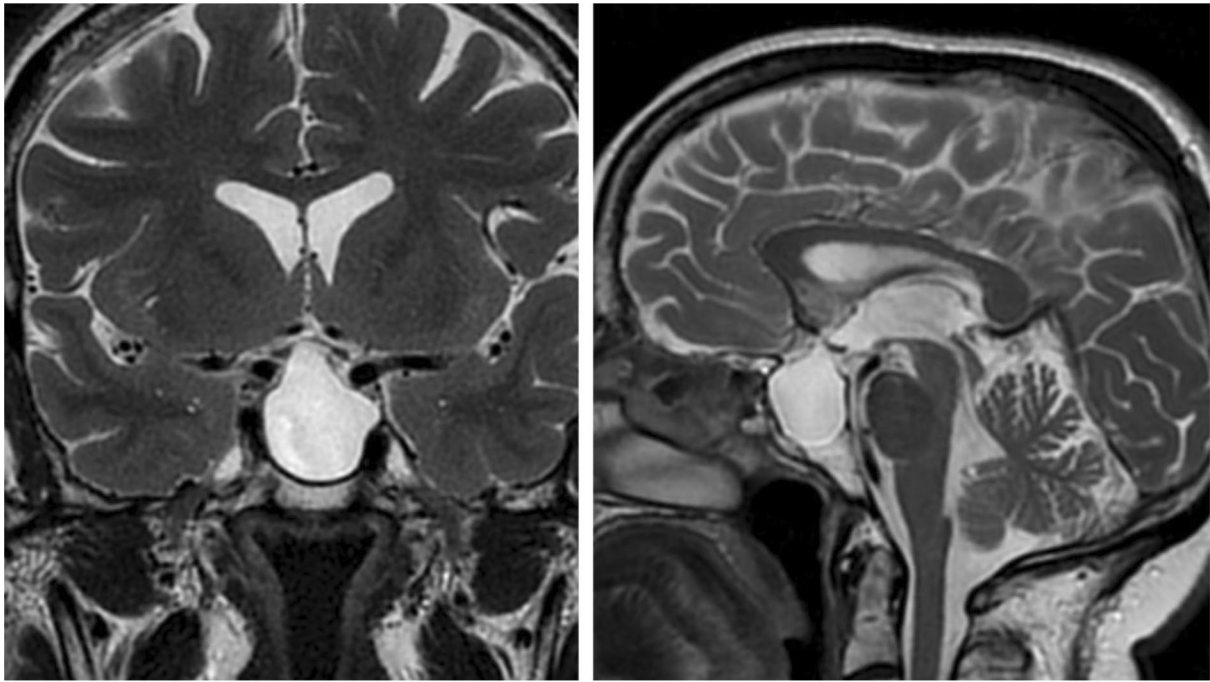
Fig. 4 3-month postop MRI-scan with cyst reacumulation and fat graft shrinkage

scarring remains problematic with the transcranial approach in comparison with an endoscopic endonasal approach.

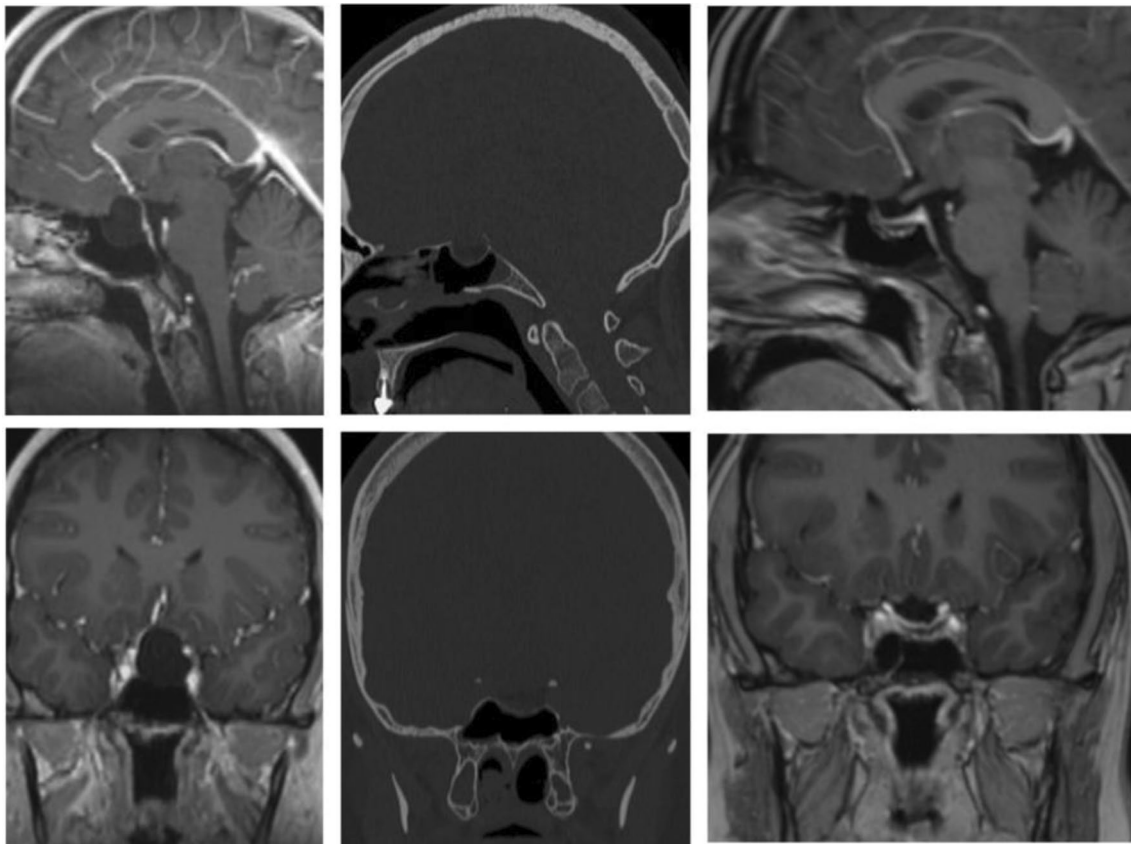
## Conclusion

The treatment of SAC is challenging because it is a non-neoplastic lesion and complication rate is higher than with pituitary adenoma surgery, for example. Our surgical approach which consists in recreating a waterproof barrier





**Fig. 5** 2-years postop MRI-scan, complete resorption of the fat graft and cyst recurrence



**Fig. 6** Preoperative MRI T1 with gadolinium, cystic intrasellar lesion, CT scan at day 1 showing fat graft in the sellar space and integrity of the sellar floor, Postop MRI with gadolinium at 1 year; absence of recurrence

at the *diaphragma sellae* with obliteration of the cyst with adipose tissue and reconstruction of skull base seems to be a simple solution with a low complication rate. We consider that a craniotomy can be avoided in most cases of this pathology. Cyst recurrence and CSF postoperative leakage are the two main complications. These are not limitations of this surgical technique, but in contrary, a way to improve the packing of the sellar space and the skull base opening and reconstruction (Tables 1 and 2).

### Illustrative cases

A 42-years-old man (case number 8) presented with visual disorder on the left eye, perimetry displayed scotoma and visual acuity loss. On MRI scan a cystic intrasellar mass was visible and evoked the diagnosis of SAC. Surgery was performed by transsphenoidal endoscopic technique, simple cyst obliteration with fat graft. Neuro-Patch © was used for sellar floor reconstruction with additional surgical glue. Despite this precautions, cerebrospinal leakage occurred on postop day 1. CT -scan revealed the expulsion of the fat graft in the sphenoid sinus. Surgical reintervention was performed, and a titanium mesh has been positioned on the sellar floor. No further leakage happened, and the visual function was improved on postop visit. (Figs. 1 and 2).

A 63 years-old women (case number 15) had bitemporal hemianopsia and the diagnosis of cystic non-tissular lesion of the sellar region. She was operated, sufficient fat graft obliteration was seen on postop CT-scan, but on follow up MRI-scan revealed a progressive cyst reaccumulation and resorption of the fat graft. The visual disorder completely recovered so she has not been reoperated for the moment. (Figs. 3, 4 and 5).

A 28 years-old women (case number 13) presented with unusual and persistent headaches. MRI (Fig. 6) led to the diagnostic of an intrasellar arachnoid cyst measuring 21 mm. Endoscopic transsphenoidal obliteration with fat graft was performed. Surgery improved the headaches and after 13 months of follow up, no complication occurred. Postoperative MRI showed the absence of residual cystic lesion in the sella (Fig. 6).

**Funding** No funding was received for conducting this study.

### Declarations

**Conflict of interest** The authors declare no conflict of interest.

**Ethical approval** All procedures performed in studies involving human participants were in accordance with the ethical standards of the institutional and/or national research committee and with the 1964 Helsinki Declaration and its later amendments. The Human Investigation Com-

mittee (IRB) of College de Neurochirurgie approved this study. No. IRB00011687 Collège de neurochirurgie IRB #1: 2021/19.

**Informed consent** Informed consent was obtained from the patients included in this study.

### References

1. Al-Holou WN, Terman S, Kilburg C, Garton HJL, Muraszko KM, Maher CO (2013) Prevalence and natural history of arachnoid cysts in adults. *J Neurosurg* 118(2):222–231. <https://doi.org/10.3171/2012.10.JNS12548>
2. Dubuisson AS, Stevenaert A, Martin DH, Flandroy PP (2007) Intrasellar arachnoid cysts. *Neurosurgery* 61(3):505–513. <https://doi.org/10.1227/01.NEU.0000290896.69825.40>
3. Chen B, Miao Y, Hu Y et al (2019) Rare intrasellar arachnoid cyst distinguishing from other benign cystic lesions and its surgical strategies. *J Craniofac Surg* 30(5):e400–e402. <https://doi.org/10.1097/SCS.0000000000005315>
4. Liu H, Lu X, Hang W, Liu G (2019) Magnetic resonance imaging characteristics and differential diagnosis of common sellar cystic lesions. *Zhonghua Er Bi Yan Hou Tou Jing Wai Ke Za Zhi* 54(11):819–825. <https://doi.org/10.3760/cma.j.issn.1673-0860.2019.11.004>
5. McLaughlin N, Vandergrift A, Ditzel Filho LF et al (2012) Endonasal management of sellar arachnoid cysts: simple cyst obliteration technique. *J Neurosurg* 116(4):728–740. <https://doi.org/10.3171/2011.12.JNS11399>
6. Cappabianca P, de Divitiis E (2004) Endoscopy and transsphenoidal surgery. *Neurosurgery* 54(5):1043–1048. <https://doi.org/10.1227/01.neu.0000119325.14116.9c>
7. Kassam A, Snyderman CH, Mintz A, Gardner P, Carrau RL (2005) Expanded endonasal approach: the rostrocaudal axis. Part I. Crista galli to the sella turcica. *Neurosurg Focus* 19(1):1–12. <https://doi.org/10.3171/foc.2005.19.1.4>
8. Saeger W, Lüdecke DK, Buchfelder M, Fahlbusch R, Quabbe H-J, Petersenn S (2007) Pathohistological classification of pituitary tumors: 10 years of experience with the German Pituitary Tumor Registry. *Eur J Endocrinol* 156(2):203–216. <https://doi.org/10.1530/eje.1.02326>
9. Baskin DS, Wilson CB (1984) Transsphenoidal treatment of non-neoplastic intrasellar cysts: a report of 38 cases. *J Neurosurg* 60(1):8–13. <https://doi.org/10.3171/jns.1984.60.1.0008>
10. Zayour DH, Selman WR, Arafah BM (2004) Extreme elevation of intrasellar pressure in patients with pituitary tumor apoplexy: relation to pituitary function. *J Clin Endocrinol Metab* 89(11):5649–5654. <https://doi.org/10.1210/jc.2004-0884>
11. Arafah BM, Prunty D, Ybarra J, Hlavin ML, Selman WR (2000) The dominant role of increased intrasellar pressure in the pathogenesis of hypopituitarism, hyperprolactinemia, and headaches in patients with pituitary adenomas. *J Clin Endocrinol Metab* 85(5):1789–1793. <https://doi.org/10.1210/jcem.85.5.6611>
12. Chanson P, Raverot G, Castinetti F et al (2015) Management of clinically non-functioning pituitary adenoma. *Ann Endocrinol* 76(3):239–247. <https://doi.org/10.1016/j.ando.2015.04.002>
13. Meyer FB, Carpenter SM, Laws ER (1987) Intrasellar arachnoid cysts. *Surg Neurol* 28(2):105–110. [https://doi.org/10.1016/0090-3019\(87\)90081-4](https://doi.org/10.1016/0090-3019(87)90081-4)
14. Campero A, Tróccoli G, Martins C, Fernandez-Miranda JC, Yasuda A, Rhoton AL (2006) Microsurgical approaches to the medial temporal region: an anatomical study. *Neurosurgery* 59(4

- Suppl 2):ONS-279-ONS-307. <https://doi.org/10.1227/01.NEU.0000223509.21474.2E>
15. Hornig GW, Zervas NT (1992) Slit defect of the diaphragma sellae with valve effect: observation of a “slit valve.” *Neurosurgery* 30(2):265–267. <https://doi.org/10.1227/00006123-199202000-00022>
  16. Shim K-W, Park E-K, Lee Y-H, Kim S-H, Kim D-S (2013) Transventricular endoscopic fenestration of intrasellar arachnoid cyst. *Neurosurgery* 72(4):520–528. <https://doi.org/10.1227/NEU.0b013e318282a6e3>
  17. Magro E, Graillon T, Lassave J et al (2016) Complications related to the endoscopic endonasal transsphenoidal approach for non-functioning pituitary macroadenomas in 300 consecutive patients. *World Neurosurg* 89:442–453. <https://doi.org/10.1016/j.wneu.2016.02.059>
  18. Roca E, Penn DL, Safain MG, Burke WT, Castlen JP, Laws ER (2019) Abdominal fat graft for sellar reconstruction: retrospective outcomes review and technical note. *Oper Neurosurg Hagerstown Md* 16(6):667–674. <https://doi.org/10.1093/ons/opy219>
  19. Catapano D, Sloffer CA, Frank G, Pasquini E, D’Angelo VA, Lanzino G (2006) Comparison between the microscope and endoscope in the direct endonasal extended transsphenoidal approach: anatomical study. *J Neurosurg* 104(3):419–425. <https://doi.org/10.3171/jns.2006.104.3.419>
  20. Bakhshi SK, Suhail N, Mitha R, Moazzam M, Zahid N, Shamim MS (2020) Lumbar drain for temporary cerebrospinal fluid diversion: factors related to the risks of complications at a University Hospital. *World Neurosurg* 143:e193–e198. <https://doi.org/10.1016/j.wneu.2020.07.120>
  21. Shin JL, Asa SL, Woodhouse LJ, Smyth HS, Ezzat S (1999) Cystic lesions of the pituitary: clinicopathological features distinguishing craniopharyngioma, Rathke’s cleft cyst, and arachnoid cyst. *J Clin Endocrinol Metab* 84(11):3972–3982. <https://doi.org/10.1210/jcem.84.11.6114>
  22. Oyama K, Fukuhara N, Taguchi M, Takeshita A, Takeuchi Y, Yamada S (2014) Transsphenoidal cyst cisternostomy with a keyhole dural opening for sellar arachnoid cysts: technical note. *Neurosurg Rev* 37(2):261–267. <https://doi.org/10.1007/s10143-013-0496-4>
  23. Su Y, Ishii Y, Lin C-M, Tahara S, Teramoto A, Morita A (2015) Endoscopic transsphenoidal cisternostomy for nonneoplastic sellar cysts. *BioMed Res Int* 2015:389474. <https://doi.org/10.1155/2015/389474>
  24. Castle-Kirsbaum MD, Uren B, King J, Wang YY, Goldschlager T (2018) Glimpse into pathophysiology of sellar arachnoid cysts. *World Neurosurg* 119:381–383. <https://doi.org/10.1016/j.wneu.2018.08.111>
  25. Aljuboori Z, Burke W, Yeo H, McCallum A, Clark J, Williams B (2020) Orbitofrontal approach for the fenestration of a symptomatic sellar arachnoid cyst. *Surg Neurol Int* 11:10. [https://doi.org/10.25259/SNI\\_541\\_2019](https://doi.org/10.25259/SNI_541_2019)
  26. Cavallo LM, Prevedello D, Esposito F et al (2008) The role of the endoscope in the transsphenoidal management of cystic lesions of the sellar region. *Neurosurg Rev* 31(1):55–64. <https://doi.org/10.1007/s10143-007-0098-0>