



HAL
open science

Ultrasound arterial anomalies in patients exposed to nilotinib therapy for chronic myeloid leukemia

G. Sarlon-Bartoli, Q. Michel, E. Sarlon, M. Carcopino-Tusoli, P. Suchon, R. Soler, M.A. Bartoli, D. Brunet, P. Morange, A. Charbonnier

► **To cite this version:**

G. Sarlon-Bartoli, Q. Michel, E. Sarlon, M. Carcopino-Tusoli, P. Suchon, et al.. Ultrasound arterial anomalies in patients exposed to nilotinib therapy for chronic myeloid leukemia. *JMV-Journal de Médecine Vasculaire*, 2021, 46 (2), pp.66-71. 10.1016/j.jdmv.2021.02.002 . hal-03588889

HAL Id: hal-03588889

<https://amu.hal.science/hal-03588889>

Submitted on 22 Mar 2023

HAL is a multi-disciplinary open access archive for the deposit and dissemination of scientific research documents, whether they are published or not. The documents may come from teaching and research institutions in France or abroad, or from public or private research centers.

L'archive ouverte pluridisciplinaire **HAL**, est destinée au dépôt et à la diffusion de documents scientifiques de niveau recherche, publiés ou non, émanant des établissements d'enseignement et de recherche français ou étrangers, des laboratoires publics ou privés.



Distributed under a Creative Commons Attribution - NonCommercial 4.0 International License

ORIGINAL ARTICLE

Ultrasound arterial anomalies in patients exposed to nilotinib therapy for chronic myeloid leukemia

Short title: Vascular ultrasound after nilotinib exposure

Gabrielle Sarlon-Bartoli (1), Quentin Michel (1), Emmanuelle Sarlon (2), Magali Carcopino-Tusoli (1), Pierre Suchon (3), Raphael Soler (4), Michel Alain Bartoli (4), Dominique Brunet (1, 3), Pierre Morange (3), Aude Charbonnier (1)

(1) Unité d'Exploration et de médecine vasculaires, Faculté de Médecine de Marseille, Aix-Marseille Université, Assistance Publique Hôpitaux de Marseille - Hôpital de la Timone, Marseille, France.

(2) Unité de Santé publique, Centre Hospitalier Intercommunal Gap, 1 place Auguste Muret, 05000 Gap, France.

(3) Service d'hématologie, Faculté de Médecine de Marseille, Aix-Marseille Université, Assistance Publique Hôpitaux de Marseille - Hôpital de la Timone, Marseille, France.

(4) Service de Chirurgie Vasculaire, Faculté de Médecine de Marseille, Aix-Marseille Université, Assistance Publique Hôpitaux de Marseille - Hôpital de la Timone, Marseille, France.

(5) Institut Paoli-Calmettes, département d'Onco-hématologie, 232, boulevard Sainte-Marguerite, BP 156, 13273 Marseille cedex 9, France.

Corresponding author: Dr Sarlon-Bartoli Gabrielle, MD, PhD

Unité d'Exploration et de médecine vasculaires, Hôpital de la Timone, 264 rue saint pierre, 13385 Marseille cedex 05, France

Phone : +33491387023, Fax: +33491384370, mail: gabrielle.sarlon@ap-hm.fr

SUMMARY

Introduction: Patients exposed to nilotinib for chronic myeloid leukemia (CML) appear to be at risk of arterial complication. The prevalence and aspect of ultrasound asymptomatic arterial lesions are unknown.

Objective: To describe prevalence and characteristics of ultrasound arterial anomalies in patients treated with nilotinib for CML.

Methods: Patients treated with nilotinib from 2006 to 2015 in the department of the Paoli-Calmettes Institute, Marseille, were included retrospectively. A vascular ultrasound screening was carried out from 2010. The arterial lesions at the first examination were described: plaque and its echogenicity, stenosis or occlusion. A vascular arterial anomaly (VAA) was defined by the presence of a clinical and/or ultrasound anomaly. Patients with or without VAA at initial vascular examination were compared using bivariate and multivariate analysis.

Results: 74 patients were included (51.4% men, mean age 54.5 years); 25 patients had ultrasound arterial anomalies (33.8%). Carotid bulb was the most involved territory (44%). Arterial anomalies were: 88% plaques, 44% >50% stenosis and 12% occlusion. 72.7% plaques were echolucent or hypoechogenic. A VAA was present in 25 patients with initial vascular evaluation (33.8%). Patients with VAA at baseline were significantly older (64.9 vs 49.3, $p < 0.001$), older at nilotinib initiation (60.8 vs 46.5, $p < 0.001$), with more arterial hypertension (40% vs 12.2%, $p = 0.01$), with more cardiovascular risk factors ($p = 0.03$). In patient with no cardiovascular risk factor 12.5% had VAA ($n = 24$).

CONCLUSION: Nilotinib seems to be associated to arterial lesions of unstable lipid-like appearance. The most involved arterial territory was the carotid bulb and the most common lesion was echolucent or hypoechogenic plaque. VAA can occur in patients without cardiovascular risk factors. This result encourages us to systematically screen and follow all patients exposed to nilotinib even those without cardiovascular risk factors.

Key words: ultrasound arterial anomalies, nilotinib, chronic myeloid leukemia

INTRODUCTION

Chronic myeloid leukemia (CML) is defined by expansion of uncontrolled myeloid cells with BCR/ABL1 oncogene (1). The “gold standard” therapy is the BCR/ABL1 tyrosine kinase inhibitor (TKI) imatinib. However more effective second generation TKI nilotinib (and dasatinib in some countries) may be used at diagnosis. Second and third generation TKIs including nilotinib, dasatinib, bosutinib, and ponatinib, have been validated in case of resistance or intolerance in clinical trials and daily practice (2).

No significant vascular adverse events (VAE) have been reported in initial clinical trials testing nilotinib (<1%) (3,4). However, during the past few years several works suggest a higher prevalence of about 30% of arterial diseases during nilotinib therapy like peripheral arterial disease (PAD), renal artery stenosis, cerebral ischemia and myocardial infarction (5-11). This prevalence is higher than that expected in general population: for example PAD prevalence based on ankle brachial index measurement (ABI) has been evaluated in several epidemiologic studies with a range of 3% to 10% before 65 years, increasing maximum to 15% to 20% in persons over 65 years (12).

Predisposing factors seemed to be: high doses of nilotinib (13), long exposure to nilotinib around 3 years exposure and pre-existing cardiovascular risk factors (11). However sometimes PAD occurred also in younger patients without risk factors (14).

In 2016 the France Intergroupe des Leucémies Myéloïdes Chroniques provided an overview of nilotinib efficacy and cardiovascular safety profile and proposed practical recommendations with the goal to minimize the risk and severity of cardiovascular events in nilotinib-treated patients (15). An initial evaluation with calculation of the Systematic COronary Risk Evaluation (SCORE) from ESC 2012 guidelines is strongly recommended (16). A low cardiovascular risk is not associated with systematic vascular imaging. A moderate risk encourages screening coronary artery with electrocardiogram and

echocardiogram, carotid and leg arteries with duplex ultrasound. Patient with high or very high risk should benefit of a multidisciplinary discussion before nilotinib prescription.

Few months later, European recommendations for the management and avoidance of adverse events of treatment in CML were published and strongly suggested performing either the ankle-brachial index (ABI) or duplex ultrasonography to assess asymptomatic PAD in all newly diagnosed patients with CML aged over 65 years and in younger patients in the presence of cardiovascular risk factors or claudication symptoms (17).

Ultrasound screening was thus recently widely recommended in patients treated with nilotinib for CML but prevalence of asymptomatic ultrasound lesions and their characteristics are unknown.

Our objective was to describe prevalence and characteristics of ultrasound anomalies during the screening of patients exposed to nilotinib for CML.

METHOD

Patients

Seventy-four patients treated with nilotinib for CML and followed up in oncohematology department of the Paoli-Calmettes Institute, Marseille, from 2006 to 2015 were retrospectively included. From 2010, patients already treated by nilotinib had an arterial duplex ultrasonography. The newly nilotinib treated patients had this exam three months after nilotinib initiation. Demographic, hematologic and cardiovascular parameters were collected after informed consent was obtained and procedures approved by the local human ethics committee.

Hematologic evaluation

All patients had a three months onco-hematologic survey. Nilotinib indications were: first line therapy or resistance to others therapies or side effects. Nilotinib dose were: 300mg twice a day or 400mg twice day for resistant patients.

Vascular examination

Patients had clinical, biological and arterial duplex ultrasonography first evaluation with experimented vascular doctors. Clinical examination consisted with cardiovascular risk evaluation, BP measurement, cardiovascular auscultation and palpation, ABI measurement. Biological parameters were: fasting glucose, HbA1c, lipids (cholesterol, low- and high-density lipoprotein (LDL and HDL) and triglycerides), and creatinine. Vascular duplex ultrasonography evaluation was exhaustive: extracranial carotid arteries, extracranial vertebral arteries and their ostia, subclavian arteries, abdominal aorta, digestive and renal arteries, legs arteries including hypogastric arteries with their ostia. Ultrasound aspect of arterial lesion was described: presence of plaque and its echogenicity, presence of stenosis and its degree, occlusion or not. Description of plaque echolucency was qualitative: no echo pattern = echolucent plaque, less echogenicity than media-adventice interface =

hypoechoic plaque, same echogenicity than adjacent bone = hyperechoic plaque. A specific follow-up was determinate after the first vascular exam.

Definition of arterial anomaly

Vascular arterial anomaly was defined by: clinical and/or ultrasound anomalies. Clinical symptoms were: PAD, stroke, myocardial infarction, renovascular hypertension. Ultrasound anomalies were: arterial plaque, stenosis or occlusion, without symptoms.

Statistical analyses

Population characteristics were described and compared at baseline according to the presence of VAA. Results were expressed as mean \pm SD or median [min-max] with interquartile range (IQR). Bivariate analyses were conducted with all appropriate continuous variables using Student's t-test or a Mann–Whitney test. Categorical variables were analyzed by the chi-squared or Fisher's exact test. The statistical analysis was considered to be significant for $p < 0.05$. Multivariate analysis was carried out by elaborating a logistic regression model to estimate the probability of a VAA according to the relevant parameters. The selection of variables was made according to literature data and the results of bivariate analyses (variables associated with $p < 0.05$): age at nilotinib introduction, pre-existent hypertension, and arterial stenosis. Analysis was performed using R for Windows, version 2.11.1.

RESULTS

Hematological characteristics

A total of 74 patients (38 men and 36 women) were included with a mean age of 54.5 ± 16.2 years. Seventy-one patients were in chronic phase, two in acute phase and one in blastic transformation. Two patients were allografted: one for blastic transformation and one because diagnosis was made before 2000. Seventeen patients were at first line therapy, 17 had side effects of others TKI, 25 patients had resistant to others TKI and 12 had lack of molecular response level 3 or 4 (3 missing data). Median exposure time to nilotinib was 22 months [1-84].

Arterial duplex ultrasonography

Arterial ultrasound anomalies were screened at the first exam for 25 patients (33.8%; n=74). 18 patients had more than one arterial territory involved (72%, n=25). Involved arterial territories were (n=25): carotid bulb (44%), iliac (28%), superficial femoral artery (28%), common femoral artery (20%), renal artery (12%), vertebral ostium (12%), legs artery (12%), mediocalcosis (12%) abdominal aorta (4%) and popliteal artery (4%). First arterial ultrasound showed 22 patients with plaques (88%, n=25): 16 were echolucent or hypoechoic (72.7%) (**Figure 1**) and 6 (27.3%) were hyperechoic. Eleven patients had arterial stenosis >50% (44%; n=25). Three patients (12%) had arterial occlusion (one superficial femoral artery and two patients with occlusion of legs arteries).

Cardiovascular characteristics

They were resumed in **Table I**. VAA was present at the first vascular examination for 25 patients (33.8%, n=74). In <65 years patients, 20 had VAE (n=55; 36.3%), in ≥ 65 years 13 patients had VAE (n=19; 68.4%). In patient with no cardiovascular risk factor, 3 had VAE (n=24; 12.5%). Fifteen patients were symptomatic (n=74; 20.3%): 9 PAD, 2 strokes, 2 myocardial infarctions and 2 renal artery stenosis. Twelve patients had statins, 14 had

antiplatelet agent, 4 had previous lower limb revascularization, 2 had previous coronary stenting, 2 had previous renal artery stenting. Five patients from VAA- group had antiplatelets for primary prevention. Baseline characteristics were compared for patients with and without VAA and have been reported in **Table I**. Patients with VAA were significantly older (64.9 vs 49.3; $p<0.001$) and older at nilotinib initiation (60.8 vs 46.5; $p<0.001$). Patients with VAA had significantly more hypertension (10 vs 6; $p=0.01$) and more cardiovascular risk factors ($p=0.03$). In multivariate analysis age at nilotinib initiation appeared to be an independent factor to VAA ($p=0.03$).

DISCUSSION

We described for the first-time the aspect of arterial ultrasound lesion of CML patients during nilotinib therapy. CML patients with nilotinib presented mostly with echolucent or hypoechogenic plaques (22%, n=74). In literature, these plaques were associated with instable atheroma: the carotid plaques with low grayscale median were associated with a twofold increase in stroke (18, 19). Echolucent plaque reflects lipid core of atheroma and it is associated to unstable plaque (20). No prior data are available in literature but figures of Mirault et al. showed ever clearly hypodense stenosis and occlusion on CT angiography (10). Hypodense lesion on CT correspond to hypoechogenic lesion on ultrasonography. We also emphasize that these echolucent lesions are sometimes difficult to detect during ultrasonography because echogenicity is similar to the circulating blood. Rea et al. studied plasma lipid profile from 27 patients treated by nilotinib: data from a minimum 1-year follow up showed that nilotinib significantly increased total, low- and high-density lipoprotein cholesterol within three months (21). The mechanisms of action of nilotinib on various non-hematopoietic cells that could explain this potential adverse effect are poorly understood. Nilotinib binds to a limited number of key kinase targets. One of the more interesting kinase-targets in terms of vascular cells and events is the discoidin domain receptor 1 (DDR1). This receptor has recently been implicated in plaque formation in atherosclerosis (22).

Our study shows that adding ultrasound anomalies to define VAA, ranges arterial anomaly prevalence from 20% (symptomatic patients) to 34% (symptomatic and asymptomatic patients). Screening asymptomatic patients may lead to prevent events and adapt hematological treatment. VAA defined by clinical symptoms and/or ultrasound anomalies is significantly and independently associated to nilotinib exposure time. Le Coutre *et al.* (6) first described PAD during nilotinib therapy for 179 patients and relation with exposure time: the mean time from initiation of nilotinib to the first PAD event was 26 months. This relation between VAA and exposure time was also suggested by Levato *et al.* (9): VAA appeared after a median time of exposition to nilotinib of 24 months. European leukemia

recommendations consider that the vast majority of documented cases of PAD occurred within the first 48 months of therapy, but some have been reported after only 4 months, or as late as 5 years (17). We choose to take also into account ultrasound asymptomatic anomalies because patients had instable-like lesion with echolucent plaques. These data are in line with literature that shows high prevalence of VAA: after 2 years, the numbers of CML patients developing VAE during nilotinib ranged between 1% and 29% (23).

We find that 36% patients without or with only one cardiovascular risk factor had VAA, suggesting the importance for ultrasound follow-up in all patients treated by nilotinib. These results do not totally agree with Breccia et al. that used a systematic coronary risk evaluation chart (SCORE) to identify chronic myeloid leukemia patients at risk of cardiovascular diseases during nilotinib treatment (24). They obtained low cumulative incidence of atherosclerotic events at 48 months (8.5%) but highlighted a correlation between incident events and cardiovascular risk factors: none of the low-risk patients according to the SCORE chart experienced atherosclerotic events compared to 10 % in the moderate-risk category and 29 % in the high-risk. We obtained higher prevalence of cardiovascular anomalies in patients probably because we used ultrasound anomalies and clinical anomalies in our definition. We show also that hypertension is significantly associated to VAA; it was also the predominant cardiovascular risk factor (63.6%) for Le Coutre *et al.* (6) and 35% for Breccia *et al.* (24).

Study limitations are firstly that vascular examination is nonsystematic at nilotinib initiation. It is explained by the absence of knowledge of VAA during nilotinib therapy at the beginning of the drug use. It may explain why some patients were symptomatic at the initial vascular evaluation. Secondly, we chose VAA definition with clinical or ultrasound anomalies which can increase the prevalence of VAA but we think that echolucent lesions are instable-like lesions and of poor prognosis. We think that detection of asymptomatic lesions should be taken into account for cardiovascular prevention and may sometimes adapt hematologic treatment.

CONCLUSION

Treatment with nilotinib seems to be associated to atherosclerosis. The prevalence of ultrasound VAA is high, especially with nilotinib exposure, in older patients and in the presence of several cardiovascular risk factors. Of note, VAA may be present in patients without cardiovascular risk factors. Ultrasound characteristics are high frequency of echolucent plaques which reflect instable lesion. We believe that the initiation of nilotinib therapy should systematically be associated with a cardiovascular evaluation in all patients, even in the absence of cardiovascular risk factors. We also believe in the importance of close vascular follow-up in these patients.

Disclosure of interest The authors declare that they have no competing interest.

REFERENCES

- 1 Faderl S, Talpaz M, Estrov Z, O'Brien S, Kurzrock R, Kantarjian HM. The biology of chronic myeloid leukemia. *N Engl J Med.* 1999;341(3):164-172.
- 2 Jabbour EJ, Cortes JE, Kantarjian HM. Resistance to tyrosine kinase inhibition therapy for chronic myelogenous leukemia: a clinical perspective and emerging treatment options. *Clin Lymphoma Myeloma Leuk.* 2013;13(5):515-529.
3. Kantarjian H.M., Giles F.J., Bhalla K.N, Pinilla-Ibarz J, Larson RA, Gattermann N, et al. Nilotinib is effective in patients with chronic myeloid leukemia in chronic phase after imatinib resistance or intolerance: 24-month follow-up results. *Blood* 2011; 117: 1141–1145.
4. EMA. Tasigna: Annex I. Summary of Product Characteristics.
http://www.ema.europa.eu/docs/en_GB/document_library/EPAR_-_Product_Information/human/000798/WC500034394.pdf2007 [cited 2014 March 20th].
5. Aichberger KJ, Herndlhofer S, Schernthaner GH, Schillinger M, Mitterbauer-Hohendanner G, Sillaber C, et al. Progressive peripheral arterial occlusive disease and other vascular events during nilotinib therapy in CML. *Am J Hematol.* 2011;86(7): 533-539.
6. Le Coutre P, Rea D, Abruzzese E, Dombret H, Trawinska MM, Herndlhofer S, et al. Severe peripheral arterial disease during nilotinib therapy. *J Natl Cancer Inst.* 2011;103(17):1347-1348.
7. Kim TD, Rea D, Schwarz M, Grille P, Nicolini FE, Rosti G, et al. Peripheral occlusive disease in chronic phase chronic myeloid leukemia patients treated with nilotinib or imatinib. *Leukemia.* 2013;27(6):1316-1321.
8. Giles FJ, Mauro MJ, Hong F, Ortmann CE, McNeill C, Woodman RC, et al. Rates of peripheral arterial occlusive disease in patients with chronic myeloid leukemia in the chronic phase treated with imatinib, nilotinib, or nontyrosine kinase therapy: a retrospective cohort analysis. *Leukemia.* 2013;27(6):1310-1315.
9. Levato L, Cantaffa R, Kropp MG, Magro D, Piro E, Molica S. Progressive peripheral arterial occlusive disease and other vascular events during nilotinib therapy in chronic myeloid leukemia: a single institution study. *Eur J Haematol.* 2013;90(6):531-532.
10. Mirault T, Rea D, Azarine A, Messas E. Rapid onset of peripheral artery disease in a chronic myeloid leukemia patient without prior arterial disorder: direct relationship with nilotinib exposure and clinical outcome. *Eur J Haematol.*2015;94(4):363-367.

11. Bondon-Guitton E, Combret S, Pérault-Pochat MC, Stève-Dumont M, Bagheri H, Huguet F, et al. Cardiovascular risk profile of patients with peripheral arterial occlusive disease during nilotinib therapy. *Target Oncol.* 2016;11(4):549-52.
12. Norgren L, Hiatt WR, Dormandy JA, Nehler MR, Harris KA, Fowkes FG; TASC II Working Group. Inter-Society Consensus for the Management of Peripheral Arterial Disease (TASC II). *J Vasc Surg.* 2007;45 Suppl S:S5-67.
13. Hochhaus A, Saglio G, Hughes TP, Larson RA, Kim DW, Issaragrisil S, et al. Long-term benefits and risks of frontline nilotinib vs imatinib for chronic myeloid leukemia in chronic phase: 5-year update of the randomized ENESTnd trial. *Leukemia.* 2016;30(5):1044-54.
14. Stève-Dumont M, Baldin B, Legros L, Thyss A, Re D, Rocher F, et al. Are nilotinib-associated vascular adverse events an under-estimated problem? *Fundam Clin Pharmacol.* 2015;29(2):204-8.
15. Rea D, Ame S, Charbonnier A, Coiteux V, Cony-Makhoul P, Escoffre-Barbe M, et al. Management of the cardiovascular disease risk during nilotinib treatment in chronic myeloid leukemia: 2015 recommendations from the [France Intergroupe des Leucémies Myéloïdes Chroniques]. *Bull Cancer.* 2016;103(2):180-9.
16. Perk J, De Backer G, Gohlke H, Graham I, Reiner Z, Verschuren M et al. European Guidelines on cardiovascular disease prevention in clinical practice (version 2012). The Fifth Joint Task Force of the European Society of Cardiology and Other Societies on Cardiovascular Disease Prevention in Clinical Practice. *Eur Heart J* 2012;33(13): 1635–701.
17. Steegmann JL, Baccarani M, Breccia M, Casado LF, García-Gutiérrez V, Hochhaus A, et al. European LeukemiaNet recommendations for the management and avoidance of adverse events of treatment in chronic myeloid leukaemia. *Leukemia.* 2016;30(8):1648-71
18. Mathiesen EB, Børnaa KH, Joakimsen O. Echolucent plaques are associated with high risk of ischemic cerebrovascular events in carotid stenosis. The Tromsø Study. *Circulation* 2001;103:2171-5.
19. Gupta A, Kesavabhotla K, Baradaran H, Kamel H, Pandya A, Giambrone AE, et al. Plaque echolucency and stroke risk in asymptomatic carotid stenosis: a systematic review and meta-analysis. *Stroke.* 2015;46(1):91-7.
20. Stary HC, Chandler AB, Dinsmore RE, Fuster V, Glagov S, Insull W Jr, et al. A definition of advanced types of atherosclerotic lesions and a histological classification of

atherosclerosis. A report from the Committee on Vascular Lesions of the Council on Arteriosclerosis, American Heart Association. *Circulation* 1995; 92:1355-74.

21. Rea D, Mirault T, Cluzeau T, Gautier JF, Guilhot F, Dombret H, et al. Early onset hypercholesterolemia induced by the 2nd-generation tyrosine kinase inhibitor nilotinib in patients with chronic phase-chronic myeloid leukemia. *Haematologica*. 2014;99(7):1197-203.

22. Franco C, Britto K, Wong E, Hou G, Zhu SN, Chen M, et al. Discoidin domain receptor 1 on bone marrow-derived cells promotes macrophage accumulation during atherogenesis. *Circ Res* 2009;105:1141–1148.

23. Valent P, Hadzijusufovic E, Scherthaner GH, Wolf D, Rea D, le Coutre P. Vascular safety issues in CML patients treated with BCR/ABL1 kinase inhibitors. *Blood*. 2015;5;125(6):901-6.

24. Breccia M, Molica M, Zacheo I, Serrao A, Alimena G. Application of systematic coronary risk evaluation chart to identify chronic myeloid leukemia patients at risk of cardiovascular diseases during nilotinib treatment. *Ann Hematol*. 2015;94(3):393-7.

Figure 1: Ultrasound picture of carotid bulb with hypoechoic plaque in a 40-year-old patient without cardiovascular risk factors

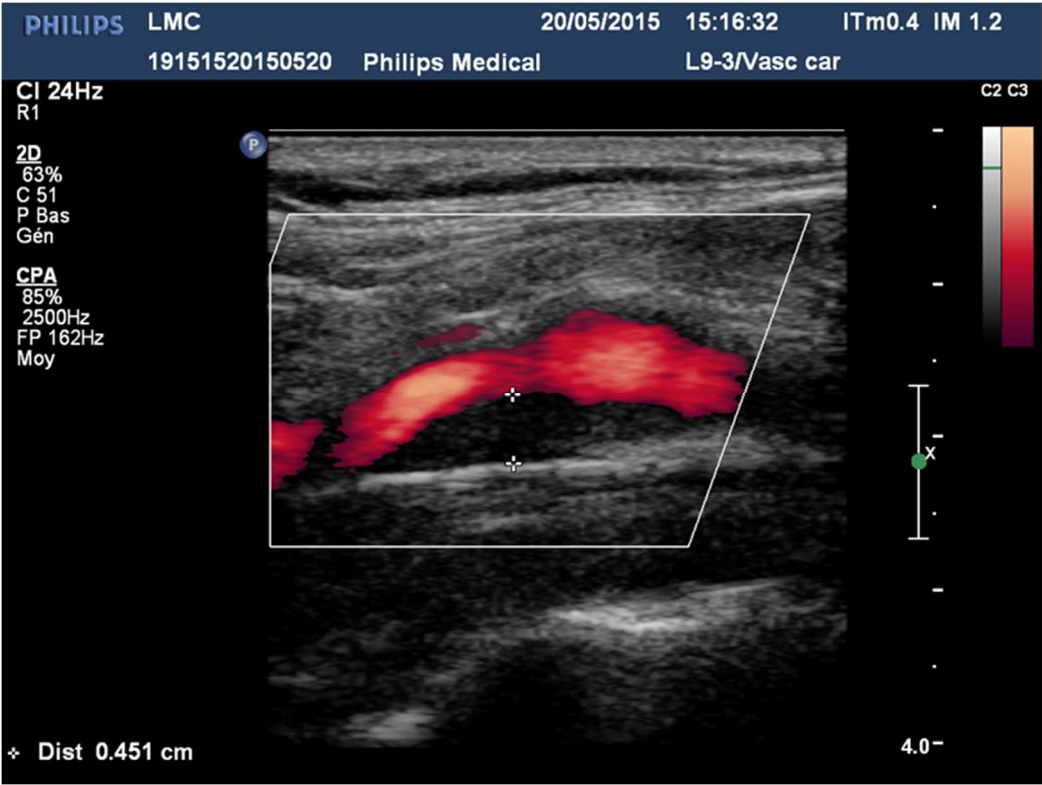


Table I: Baseline characteristics of the study population

	Population n=74 (%)	Age <65 years n=51 (%)	VAA + n=25 (%)	VAA - n=49 (%)	p (bivariate)	p (multivariate)
Sex M	38 (51.4)	28 (54.9)	10 (40)	26 (53)	0.41	
Age (mean)	54.5	46.0	64.9	49.3	<0.001	
Age at nilotinib initiation	51.3	43.2	60.8	46.5	<0.001	0.03
Dyslipidemia	10 (14)		5 (20)	5 (10)	0.42	
Hypertension	16 (22)		10 (40)	6 (12)	0.01	0.77
Tabacco	27 (36)		9 (36)	18 (37)	0.41	
Diabete	4 (5)		3 (12)	1 (2)		
Heredity	11 (15)		7 (28)	4 (8)	0.05	
CV score					0.03	
0 CV factor	24 (32)		3 (12)	21 (43)		
1 CV factor	19 (26)		6 (24)	13 (27)		
2 CV factor	18 (24)		8 (32)	10 (20)		
3 CV factor	9 (12)		6 (24)	3 (6)		
4 CV factor	4 (5)		2 (8)	2 (4)		
VAE	25 (34)					
Statin	12 (16)		7 (28)	5 (10)	0.08	
Antiplatelets	14 (19)		9 (36)	5 (10)	0.01	
Symptoms	15 (20)		15 (60)	0 (0)	<0.01	
Echolucent or hypoechoic plaque	24 (32)		16 (64)	6 (12)	<0.01	
Stenosis	11 (15)		11 (44)	0 (0)	<0.01	0.99

CV: Cardiovascular; VAA: Vascular Arterial Anomaly