



HAL
open science

CRYODESMO-O1: A prospective, open phase II study of cryoablation in desmoid tumour patients progressing after medical treatment

Jean-Emmanuel Kurtz, Xavier Buy, Frédéric Deschamps, Erik Sauleau, Amine Bouhamama, Maud Toulmonde, Charles Honoré, F. Bertucci, Mehdi Brahmi, Christine Chevreau, et al.

► To cite this version:

Jean-Emmanuel Kurtz, Xavier Buy, Frédéric Deschamps, Erik Sauleau, Amine Bouhamama, et al. CRYODESMO-O1: A prospective, open phase II study of cryoablation in desmoid tumour patients progressing after medical treatment. *European Journal of Cancer*, 2021, 143, pp.78-87. 10.1016/j.ejca.2020.10.035 . hal-03623642

HAL Id: hal-03623642

<https://amu.hal.science/hal-03623642v1>

Submitted on 29 Nov 2024

HAL is a multi-disciplinary open access archive for the deposit and dissemination of scientific research documents, whether they are published or not. The documents may come from teaching and research institutions in France or abroad, or from public or private research centers.

L'archive ouverte pluridisciplinaire **HAL**, est destinée au dépôt et à la diffusion de documents scientifiques de niveau recherche, publiés ou non, émanant des établissements d'enseignement et de recherche français ou étrangers, des laboratoires publics ou privés.



Distributed under a Creative Commons Attribution - NonCommercial 4.0 International License

CRYODESMO-O1: a prospective, open phase II study of cryoablation in desmoid tumor patients progressing after medical treatment

Jean-Emmanuel Kurtz¹, Xavier Buy², Frédéric Deschamps³, Erik Sauleau⁴, Amine Bouhamama⁵, Maud Toulmonde⁶, Charles Honoré⁷, François Bertucci, MD⁸, Mehdi Brahmi⁹, Christine Chevreau¹⁰, Florence Duffaud¹¹, Justine Gantzer¹, Julien Garnon¹², Jean-Yves Blay⁹, Afshin Gangi¹²

1 Service d'Oncologie Médicale, Hôpitaux Universitaires de Strasbourg, Strasbourg, France

2 Département de radiodiagnostic, Institut Bergonié, Bordeaux France

3 Département de radiologie interventionnelle, Institut Gustave Roussy, Villejuif, France

4 Service de Santé publique, Groupe Méthode en recherche clinique, Hôpitaux Universitaires de Strasbourg, Strasbourg, France

5 Service de radiologie interventionnelle oncologique, Centre Léon Bérard, Lyon, France

6 Département de Médecine Oncologique, Institut Bergonié, Bordeaux France

7 Service de chirurgie viscérale oncologique et sarcomes, Institut Gustave Roussy, Villejuif, France

8 Département d'Oncologie médicale, Institut Paoli-Calmettes, Marseille, France

9 Département de médecine oncologique, Centre Léon Bérard, France

10 Département d'oncologie médicale, IUCT Oncopole, Toulouse, France

11 Service d'Oncologie médicale, CHU de Marseille et Aix-Marseille Université (AMU) Marseille, France

12 Service de radiologie interventionnelle, Hôpitaux Universitaires de Strasbourg, France

Summary

Background: Desmoid tumors (DT) are rare tumors originating from musculoaponeurotic structures. Although benign, they may be locally aggressive, leading to pain and disability. ESMO guidelines recommend frontline watchful waiting and medical treatment in progressing tumors. Cryoablation is an interventional radiology technique that is suitable for DT patients (pts) based on repeated cycles of freezing, leading to cell death.

Methods: CRYODESMO-01 (ClinicalTrials.gov Identifier: NCT02476305) is a prospective, open-label, non-randomized, non-comparative, multicenter study assessing cryoablation in non-abdominopelvic progressing DT. Inclusion criteria were: pts ≥ 18 y.o., confirmed DT accessible to cryoablation ($\geq 90\%$ destruction), measurable lesion (mRECIST), progressive disease after ≥ 2 lines of medical therapy or with functional symptoms/pain, adequate biological parameters, informed consent, and affiliation to a medical insurance scheme. The primary endpoint was the non-progression rate at 12 months; secondary endpoints included safety, quality of life (QoL), assessment of pain and functional status.

Findings: 50 pts were enrolled (78% female) from four French centers and all were treated. The mean age was 41 y.o (19-73). The median number of prior treatments was 2.00 [1-4] including NSAIDs, hormone therapy, chemotherapy, and antiangiogenics. Tumor location included limbs (36%), trunk (60%), and cervical area (4%). The median tumor largest diameter was 89 mm. The rate of non-progressing disease at +12 months was 86% (CI95% 73%-94%). Median PFS was not reached at a median follow-up of 31 months. Grade 1 and 2 toxicity occurred in 32.8 and 44.5% of patients, grade 3-4 in 22% and no Grade 5 toxicity was observed. Cryoablation significantly improved functional status and pain scores.

Interpretation: Cryoablation demonstrated feasibility in progressive DT pts. The study met its primary endpoint with 86% of non-progressive disease at +12 months, with reduced pain, better functional status, and encouraging long-term disease control.

Funding: CRYODESMO-01 was funded by the French PHRC-K program.

Key words: desmoid tumor, cryoablation

Introduction

Desmoid tumor (DT), or aggressive fibromatosis, is a rare tumor (2-4 cases/million/year) that originates from musculoaponeurotic structures (1). Although DT origins is still a consider matter of debate, it is well recognized that beta-catenin plays a critical role in the pathogeny of the disease. DT can arise in the setting of familial polyposis through an *APC* (adenomatous polyposis coli) gene mutation, or in the “sporadic” setting, where mutations in *CTNNB1* (encoding beta-catenin) are commonly found (2, 3). The rarity of the tumor is still responsible for a considerable lack of unawareness of the disease, leading to large and sometimes disabling tumors at diagnosis. In some patients, DTs may be locally aggressive, leading to pain and disability, and exceptionally death, especially in the setting of intra-abdominal location. The natural history of the disease is still incompletely deciphered, with outcomes varying from asymptomatic small tumors that will eventually spontaneously disappear to continuously growing masses requiring multiple therapy lines. A number of candidate prognostic factors have been considered to apprehend the disease, including molecular (*CTNNB1* genotype) and hormonal markers (estrogen dependence) and many more (4).

Indeed, the therapeutic approach to DT has recently evolved from a front-line surgical approach that was jeopardized by a high local relapse rate, to a more conservative attitude such as the wait-and-see attitude, which is currently supported by several position papers (5, 6).

In progressing tumors, medical treatment includes NSAIDs, anti-estrogens, or cytotoxic chemotherapy as front-line therapy (7-10). From second-line therapy, a number of trials have been conducted from which the most recent advances include anti-angiogenics such as sorafenib and pazopanib (11, 12), leading to objective tumor responses in 37 and 33% of evaluable patients and clinical benefit since the median PFS was not reached in both trials. All of these trials including the most recent suffer from with the pitfalls of drugs side effects and uncertainty towards long-term benefit.

In some patients, progressive tumors lead to uncontrolled pain or progressive disability, and limited options are available including radiation therapy (13). Recent advances in interventional radiology techniques include cryoablation which is based on repeated cycles of freezing/passive thawing of the tumor, leading to cell death. Given the first encouraging reports of cryoablation in DT patients (14), this phase II study aimed to prospectively assess cryoablation in patients with extra-abdominal disease progressing under medical therapy.

Patients and methods

CRYODESMO-01 was a prospective, open-label, non-randomized multicenter phase II study exploring cryoablation in non-abdominopelvic DT patients progressing under medical therapy. The primary study endpoint was the non-progression rate at +12 months. Secondary endpoints included non-progression rates at +6 and +12 months according to mRECIST and MRI contrast product uptake, safety (according to NCI CTC V4.0 criteria), functional status and pain according to a semi-quantitative scale and Brief Pain Inventory (BPI), respectively. Quality of life (QoL) was assessed using the EQ 5D-3L scale. The study was conducted in accordance with the principles of the Declaration of Helsinki and the Guidelines for Good Clinical Practice and was approved by the Independent ethics committee East IV and by Competent Authority (ANSM). CRYODESMO-01 was funded by the French PHRC-K program and registered under the clinicaltrials.gov identification number NCT02476305.

Inclusion criteria

Inclusion criteria were: pathologically confirmed extra-abdominal DT; progressive disease after at least two lines of adequate medical therapy (including tamoxifen, NSAID or chemotherapy), with functional symptoms and/or pain; unresectable tumor or tumour amenable only to mutilating surgery deemed inappropriate in a NETSARC tumor board. Patients with modified (m) RECIST 1.1 criteria stable disease, but with persistent functional disability or tumor-induced pain not controlled by adequate pain medication including narcotics patients were also eligible. Other inclusion criteria were: age ≥ 18 years old; tumor deemed accessible for cryoablation procedure by the radiologist operator of the investigator center (with 90% of destruction of the tumor achievable in one procedure of cryoablation and with a possible second cryoablation procedure if necessary and if scheduled at study entry); measurable lesion (mRECIST 1.1) using MRI (gadolinium injection mandatory); ECOG performance status (PS) 0-2; adequate biological and hematological parameters; affiliation to a medical insurance scheme for health costs coverage, and signed written informed consent.

Exclusion criteria

Exclusion criteria were: contra-indication for the procedure as stated by the interventional radiologist in terms of tumor size, proximity to neural/vascular structures making the procedure at unacceptable risk; impaired hemostasis, concomitant participation in other experimental studies that could affect endpoints of this study, contra-indication to any form of sedation; contraindication to MRI or gadolinium injection (proven allergy, glomerular filtration rate < 30 ml/min by MDRD formula); psychiatric disorders and adults under guardianship, pregnancy or breastfeeding, or under judicial protection.

Cryoablation procedure

The cryoablation procedure was performed with a Visual Ice machine (if performed under CT guidance) or a MRI-Seednet machine (if performed under MRI guidance), available in participating centers. Four types of sterile, disposable 17-gauge cryoablation probes were used with the Visual-Ice or MRI-Seednet machine:

Icesphere[®], Iceseed[®], IceRod[®] and IceRod[®] PLUS, characterized by different sizes and shapes of iceball, their number and type being planned in advance upon the size and shape of the tumor. All these devices are CE marked Galil Medical devices (Yokneam, Israel) and used according to the CE mark.

Cryoablation was performed percutaneously under general anesthesia, under CT or MRI guidance with cryoprobes placed at a distance of 1.5 cm between each other, in all planes as recommended by the manufacturer.

Tumor ablation was carried out through two 10 minutes freezing cycles, separated by a passive 10 minutes thawing period under repeated imaging controls to monitor the iceball volume, which had to exceed the tumor limits by 10 to 30 mm in all planes at the end of the second freezing cycle (when reaching its maximum volume). At the end of the procedure, an active cryoprobes thawing was performed to ensure their rapid removal. After the procedure, patients were hospitalized for two days to monitor and prevent pain and or side effects and discharged at day 3 whenever possible.

Follow-up

Clinical and MRI evaluation was planned at months (M) 1, 3, 6, 9 and 12 with an additional visit at M2. Clinical data including vital signs and safety data were recorded. Pain and QoL assessments were performed at study entry and at each visit. No follow-up was scheduled after M12.

Endpoints

The primary endpoint of the study was the rate of non-progressing disease at +12 months, failure/progression being defined by either a necrotic volume <90% in the treated zone, a tumor recurrence in the treated zone, or a tumor progression in the treated volume size at M12 compared to M1.

In parallel to the mRECIST criteria, we assessed response using the tumor MRI Contrast product Uptake (MCU) as previously reported in kidney cancers undergoing cryoablation (15). Criteria for MCU response included the combination of i) no suspicious contrast enhancement in the treated zone, and ii) the lack of progressing disease at M12 as compared to M1 (first post-procedure MRI). Similarly, failure of the procedure was defined as i) a necrosis volume <90% of the treated zone, ii) a tumor recurrence (area of nodular or crescent-shaped or irregular enhancement in the ablation zone, observed after injection of gadolinium) at any assessment, and iii) an increase in the treated zone size at M12 compared to M1.

Secondary endpoints included safety, analysis of factors influencing tumor response, quality of life and pain scores. Progression-free was a non-prespecified exploratory endpoint, calculated from the date of the cryoablation procedure to the date of tumor progression or relapse or last follow-up.

Statistical considerations

Descriptive statistics were performed with mean, median and range for continuous variables, and effective and frequencies for categorical variables. Bayesian inference methods were performed using Markov chains-Monte Carlo technics (McMC, with 12 000 final iterations for estimates) using vague priors and convergence diagnosis. For example, we based our calculations on a neutral prior hypothesis of 50% of non-progressing patients at 12

months. Mixed models (“random” subject effect) included linear analysis for continuous variables (e.g. tumor volume), gamma regression in case of skewed data, logistic analysis for dichotomous variables (MCU), polychotomous for ordinal variables (EQ5D-3L scores) or Beta for bounded scales (VAS). Significance was considered as reached whether the parameter probability to be more than 0 is more than 0.95. For example decrease in tumor volume would be “significant” if the probability that the difference in volume between 12 months and inclusion was negative is more than 95%.

Analyses were carried out with intention to treat but completed by per protocol selection of subjects.

Role of the funding source

This work was funded by the French academic PHRC-K program. The funding source had no role in study design, data collection, data analysis, data interpretation, or writing of the report. The corresponding author had full access to all the data and had final responsibility to submit for publication.

Results

Patients and treatment

Between May 2015 and November 2017, 50 patients were included in the study. Their clinical characteristics are summarized in Table 1. Among these, 45 were treated in a single procedure, whereas 5 had a planned two-steps cryoablation. The median duration of hospitalization for the procedure was 4 days until patients were discharged. Among the whole study population, one patient faced a major protocol deviation (procedure performed under ultrasonography).

Primary endpoint:

Rate of non-progressing disease at 12 months

Although non-progression rates are generally assessed by RECIST, these criteria do not apply when tumor shrinkage incompletely surrogates treatment efficacy. Indeed, after cryoablation, tumor necrosis (characterized by decreased tumor density and loss of contrast uptake) does not translate rapidly into tumor response as assessed by mRECIST1.1, yet symptoms relief may be already observed. MRI contrast uptake (MCU) was also performed besides mRECIST 1.1 to take into account post-procedure tissular changes (tumor necrosis) that cannot be assessed using the usual mRECIST criteria.

The observed non-progression rate at 12 months was 85.8% (36/42) [72.9%; 93.8%] (Complete response=CR 28.6%; Partial response=PR 26.2%; Stabilization=SD 31%, with an ORR of 54.8%) according to mRECIST 1.1 and according to MCU (Figure 1). The respective inferred *a posteriori* rates were very similar: 85.2 and 84.8%.

Secondary endpoints

Safety

Cryoablation was well tolerated. No grade 5 toxicity was observed, and the majority (79%) of side-effects was of mild to moderate severity, as 42 pts experienced grade 1 or 2 side effects (31 and 29, respectively) whereas 15 had grade 3 or 4 (11 and , respectively) (Table 2). The median delay to the onset of grade 2-4 side effects was 2 days. Among these, transient pain, peripheral nerve impairment (paresthesia, peripheral nerve palsy), edema, musculo-skeletal impairment, rhabdomyolysis and skin burn were predominant and expected from previous cryoablation experience. Overall, 15 patients experienced 24 grade 3-4 side effects, most of them resulting from cryoablation of large tumors (median: 123 vs 110 cm³ in the total population) and having a favorable outcome over time. Acute toxicity (pain, increase in CPK, edema) was managed during hospitalization owing to sufficient hydration, IV analgesics and careful monitoring until patients' discharge.

Symptoms and quality of life

Among symptoms related to DTs, pain is a major issue. Owing to the brief pain inventory, we showed that pain significantly decreased over time, both in severity (Figure 2A) and interference (Figure 2B), the latter describing

the consequences of pain on general activity *i.e.* walking, work, mood, enjoyment of life, relations with others, and sleep. Of note, a transient increase in pain was observed at days 1 and 2, reflecting the post-procedure period, where IV analgesics were administered. Indeed, pain scores were significantly decreased from month 2 (M2) evaluation, a finding that is consistent with a parallel decrease in analgesic drugs intake over time (Figure 2C). Pain scores (brief pain inventory in interference and in severity) were analyzed in both completely (100% DT destruction) and incompletely treated DT patients, showing that the differences in pain were not different from 0 between groups (0,187 [-0.992; 1.376] in severity and -0.365 [-1.618; 0.899] in interference).

Quality of life was analyzed globally through a calculated utility score (Figure 3A) that takes into account reported outcomes in the five dimensions of EQ5D-3L and a visual analogic scale (VAS) (Figure 3B). More in depth analysis of EQ5D-3L data showed that in two dimensions (anxiety and depression, and daily activities), scores consistently improved over time (Figure 3C and 3D, respectively)

Progression-free survival after month 12

After the last trial visit (Month 12), patients were followed according to the standard practice with clinical and radiological assessments. Post-trial progression-free survival (PFS) data were retrieved from investigators as a hypothesis-generating endpoint. In prior SD or PR patients, alongside RECIST criteria, a tumor residue with increased symptoms also defined progression. With a median follow-up of 31 months after cryoablation, the median PFS was not reached (Figure 4)

Factors influencing outcomes

In order to identify factors that might influence the outcomes of the cryoablation procedure, we performed univariate and multivariate analyses including the following baseline measures: gender, age, CTNNB1 mutation, localization (trunk vs limbs vs neck), EQ5D score, BPI score, BMI and tumor largest diameter. Among these, only tumor largest diameter was significantly and inversely correlated to the likelihood of treatment efficacy. Accordingly, the probability of success was multiplied by 1.035 (with a 95% credible interval [1.001, 1.079]) each time this diameter decreases by 1 mm. The probability that this odds-ratio is more than 1 was 0.978. Moreover, we found that recurrences never occurred in the treated zone, but rather in its periphery, suggesting that treating smaller tumors earlier in the course of the disease would procure even more efficacy.

Discussion

Local treatment, surgery and radiation therapy are active in DT but associated with long term side effects, and a frequent risk of relapse. Although DTs are benign tumors, their local development is characterized by invasion and tissue destruction leading to functional and aesthetic outcomes that can be disastrous. Considering the variability of tumor evolution and the potential morbidity following surgery, a wait-and-see period after diagnosis is currently a standard to allow a more appropriate care according to tumor aggressiveness (5, 6).

Alternative therapies to DT surgery for front-line or recurrence include radiation therapy (ORR 39%) (13), NSAIDs (7, 8, 16), anti-estrogens (ORR 3%) (17-19) alone or in combination, chemotherapy (45% of non-progression at 6 months) (9, 10), targeted therapies with imatinib (20, 21), sorafenib (ORR 33%) (11), pazopanib (83.7% of non-progression at 6 months) (12) and more recently gamma-secretase inhibitors (ORR 29%) (22). Of note, among these therapies, NSAIDs and hormone therapy may be less effective than antiangiogenics or chemotherapy, with some likelihood of spontaneous regression in progressing patients. All of these medical approaches however may fail to achieve long-term disease control and a number of patients suffer from irreducible pain, and disability related to tumor volume. In such circumstances, we must explore innovative techniques that are minimally harmful and may provide disease control and symptoms relief. Indeed, surgery (at least for abdominal wall tumors) may be considered as a second-line treatment, but in all of our patients a multidisciplinary tumor board ruled out surgery prior to enrollment (23). From the first case series reported by Kujak et al. (14), a few authors have reported retrospective data supporting the potential benefits of cryoablation in DTs (24-31).

We here report the first prospective trial of cryoablation in DT patients progressing under medical therapy. Our study met its primary endpoint with 86% of non-progression at 12 months, as assessed by either RECIST1.1 or MRI contrast uptake. Indeed, in such a technique, where solid tumors like DT are turned into gelatinous necrosis (with a slow resorption rate) through the freezing procedure, mRECIST criteria may not be optimal to assess efficacy. Nonetheless, using mRECIST criteria we were able to show a high non-progression rate confirmed by MRI contrast uptake evaluation. Despite it was an exploratory analysis, median PFS was not reached at a median follow-up of 31 months, suggesting that even in the setting of large progressive, heavily pretreated tumors, cryoablation may procure a valuable long-term relief to patients. We acknowledge that some patients were enrolled with mRECIST stable tumor, though having uncontrolled symptoms such as pain or disability. Those might harbor a more favorable profile in terms of outcomes that has to be taken into account when analyzing the non-progression rate at 12 months.

Secondary endpoints were also met in terms of safety, pain scores, analgesics consumption, and quality of life assessment. After thorough patients' selection for feasibility and in the hands of trained interventional radiologists, the procedure was safe, despite we treated large tumors, which volume distribution was right-skewed due to some very large masses. To accurately monitor the target volume is critical to spare critical organs such as skin and nerves. This can be achieved through skin heating, carbo (CO₂) or hydro-dissection during the procedure that should be ideally performed under real-time MRI to closely monitor the iceball

volume. When MRI is not available, CT-scanner is an option. Together with CT, ultrasonography may be helpful in positioning the probes and monitor the skin to avoid skin burn; however, cryoablation should not be undertaken without MRI or CT monitoring. Most side effects were mild and moderate, and easily managed. Most grade 3-4 side effects were found in patients with large tumors, a finding that supports the use of cryoablation earlier in the course of the disease. Given our data, mid/long-term side effects are infrequent and include nerve palsy in some cases (with a favorable outcome), together with pain. It is however very unlikely that cryoablation would induce mid/long term pain that is equal/worse than tumor symptoms.

Cryoablation is probably not feasible in all DT cases. Indeed, some localisations such as cranio-facial, intra-abdominal (mesenteric) DTs are at unacceptable risk given the vicinity of organs such as bowel (even with carbodissection), and nerves. Post-procedure edema must also be taken into account to avoid compartment syndrome.

We found that cryoablation was highly effective in relieving symptoms, among which pain is a very frequent complain in DT patients. After a very transient post-procedure increase in pain scores, these consistently decreased over time, in parallel with a decrease of analgesic intake. Of note, DT patients progressing after medical therapy may have tumor not accessible to complete cryoablation due to the vicinity of “at risk” organs such as skin, nerves or viscera. Hence, inclusion criteria aimed to have at least 90% of DT cryoablation. Quality of life was also significantly improved by cryoablation, both globally owing to the utility and visual/anologic scores of EQ5D, but also in some of its dimensions. Indeed, patients reported a significant improvement in daily activities, and a decrease of anxiety/depression after cryoablation. Such a favorable effect is of importance in a disease that has such an unpredictable outcome particularly in the setting of the failure of medical therapy. Some other dimensions of EQ5D were not so conclusive, perhaps due to insufficient patient number, but also to non-relevant dimensions (self-care and mobility impairment highly depending on the tumor sites). Cryoablation series that appear in the literature have also suggested similar results in terms of efficacy and safety, though suffering from their retrospective nature, and variability regarding the size of tumors (29-31). Indeed other techniques such as radiofrequency ablation (RFA) might be considered in DT. However, cryoablation has the advantages of a better accuracy in visualizing the treated zone with MRI (RFA is not routinely applicable under MRI) , induces a liquid tumor necrosis (solid necrosis with RFA).

In conclusion, CRYODESMO-01 was the first prospective trial assessing cryoablation in DTs progressing under medical treatment. The study met its primary endpoints, was safe, and improved pain scores and quality of life. Cryoablation benefits to the patients in terms of disease control, pain and quality of life. As compared to a surgical, possibly mutilating approach, cryoablation is also able to spare healthy tissues and maintain as much function as possible. Based on our results, cryoablation will be evaluated *versus* standard medical care in patients progressing after the wait-and-see period in the CRYODESMO-02 trial. The trial, funded by the French National Cancer Institute, will start recruitment by 2021, in order to make another breakthrough in the care of this problematic disease.

We think that cryoablation should be discussed and offered to progressing patients, provided they cannot be enrolled into a clinical trial, and have a comprehensive assessment by an expert doublet of medical oncologist and interventional radiologist trained in cryoablation.

Acknowledgements

CRYODESMO-01 was funded by the French PHRC-K program.

Conflict of interest statement

Dr Buy received consulting fees from Galil-BTG; Dr Deschamps received grants from Boston Scientific; Dr Garnon received consulting fees from Boston-Galil, Johnson & Johnson, Canon Medical, Medtronic; Pr Gangi received consulting fees from BTG and has a patent from Apriomed.

References

- 1) Reitamo JJ, Hayry P, Nykyri E, Saxen E: The desmoid tumor. I. Incidence, sex-, age- and anatomical distribution in the Finnish population. *Am J Clin Pathol* 1982, 77(6):665-673.
- 2) Tejpar S, Nollet F, Li C, Wunder JS, Michils G, dal Cin P, Van Cutsem E, Bapat B, van Roy F, Cassiman JJ, Alman BA. Predominance of beta-catenin mutations and beta-catenin dysregulation in sporadic aggressive fibromatosis (desmoid tumor). *Oncogene* 1999, 18(47):6615-6620.
- 3) Li C, Bapat B, Alman BA: Adenomatous polyposis coli gene mutation alters proliferation through its beta-catenin-regulatory function in aggressive fibromatosis (desmoid tumor). *Am J Pathol* 1998, 153(3):709-714.
- 4) Salas S, Dufresne A, Bui B, Blay JY, Terrier P, Ranchere-Vince D, Bonvalot S, Stoeckle E, Guillou L, Le Cesne A, Oberlin O, Brouste V, Coindre JM. Prognostic factors influencing progression-free survival determined from a series of sporadic desmoid tumors: a wait-and-see policy according to tumor presentation. *J Clin Oncol* 2011, 29(26):3553-3558.
- 5) Kasper B, Baumgarten C, Garcia J, Bonvalot S, Haas R, Haller F, Hohenberger P, Penel N, Messiou C, van der Graaf WT, Gronchi A; Desmoid Working Group. An update on the management of sporadic desmoid-type fibromatosis: a European Consensus Initiative between Sarcoma Patients EuroNet (SPAEN) and European Organization for Research and Treatment of Cancer (EORTC)/Soft Tissue and Bone Sarcoma Group (STBSG). *Ann Oncol*. 2017 Oct 1;28(10):2399-2408.
- 6) Gronchi A, Colombo C, Le Péchoux C, Dei Tos AP, Le Cesne A, Marrari A, Penel N, Grignani G, Blay JY, Casali PG, Stoeckle E, Gherlinzoni F, Meeus P, Mussi C, Gouin F, Duffaud F, Fiore M, Bonvalot S; ISG and FSG. Sporadic desmoid-type fibromatosis: a stepwise approach to a non-metastasising neoplasm-- a position paper from the Italian and the French Sarcoma Group. *Ann Oncol*. 2014 Mar;25(3):578-83.
- 7) Teshima M, Iwae S, Hirayama Y, Furukawa T: Nonsteroidal anti-inflammatory drug treatment for desmoid tumor recurrence after surgery. *Otolaryngol Head Neck Surg* 2012, 147(5):978-979.
- 8) Skapek SX, Anderson JR, Hill DA, Henry D, Spunt SL, Meyer W, Kao S, Hoffer FA, Grier HE, Hawkins DS, Raney RB. Safety and efficacy of high-dose tamoxifen and sulindac for desmoid tumor in children: results of a Children's Oncology Group (COG) phase II study. *Pediatr blood cancer* 2013, 60(7):1108-1112.
- 9) Kono T, Tomita I, Chisato N, Matsuda M, Kakisaka A, Kasai S. Successful low-dose chemotherapy using vinblastine and methotrexate for the treatment of an ileoanal pouch mesenteric desmoid tumor: report of a case. *Dis colon rectum* 2004, 47(2):246-249.
- 10) Skapek SX, Hawk BJ, Hoffer FA, Dahl GV, Granowetter L, Gebhardt MC, Ferguson WS, Grier HE: Combination chemotherapy using vinblastine and methotrexate for the treatment of progressive desmoid tumor in children. *J Clin Oncol* 1998, 16(9):3021-3027.
- 11) Gounder MM, Mahoney MR, Van Tine BA, Ravi V, Attia S, Deshpande HA, Gupta AA, Milhem MM, Conry RM, Movva S, Pishvaian MJ, Riedel RF, Sabagh T, Tap WD, Horvat N, Basch E, Schwartz LH, Maki

- RG, Agaram NP, Lefkowitz RA, Mazaheri Y, Yamashita R, Wright JJ, Dueck AC, Schwartz GK. Sorafenib for Advanced and Refractory Desmoid Tumors. *N Engl J Med*. 2018 Dec 20;379(25):2417-2428.
- 12) Toulmonde M, Pulido M, Ray-Coquard I, Andre T, Isambert N, Chevreau C, Penel N, Bompas E, Saada E, Bertucci F, Lebbe C, Le Cesne A, Soulie P, Piperno-Neumann S, Sweet S, Cecchi F, Hembrough T, Bellera C, Kind M, Crombe A, Lucchesi C, Le Loarer F, Blay JY, Italiano A. Pazopanib or methotrexate-vinblastine combination chemotherapy in adult patients with progressive desmoid tumours (DESMOPAZ): a non-comparative, randomised, open-label, multicentre, phase 2 study. *Lancet Oncol*. 2019 Sep;20(9):1263-1272.
 - 13) Ray ME, Lawrence TS: Radiation therapy for aggressive fibromatosis (desmoid tumor). *J Clin Oncol* 2006, 24(22):3714-3715; author reply 3715.
 - 14) Kujak JL, Liu PT, Johnson GB, Callstrom MR. Early experience with percutaneous cryoablation of extra-abdominal desmoid tumors. *Skeletal Radiol*. 2010 Feb;39(2):175-82.
 - 15) Ho VB, Allen SF, Hood MN, Choyke PL: Renal masses: quantitative assessment of enhancement with dynamic MR imaging. *Radiology* 2002, 224(3):695-700.
 - 16) Belliveau P, Graham AM: Mesenteric desmoid tumor in Gardner's syndrome treated by sulindac. *Dis colon rectum* 1984, 27(1):53-54.
 - 17) Ohashi T, Shigematsu N, Kameyama K, Kubo A: Tamoxifen for recurrent desmoid tumor of the chest wall. *Int J Clin Oncol* 2006, 11(2):150-152.
 - 18) Maseelall P, Robins JC, Williams DB, Thomas MA: Stabilization and regression of a recurrent desmoid tumor with the antiestrogen toremifene. *Fertility and sterility* 2005, 84(2):509.
 - 19) Libertini M, Mitra I, van der Graaf WTA, Miah AB, Judson I, Jones RL, Thomas K, Moskvic E, Szucs Z, Benson C, Messiou C. Aggressive fibromatosis response to tamoxifen: lack of correlation between MRI and symptomatic response. *Clin Sarcoma Res*. 2018 May 14;8:13.
 - 20) Heinrich MC, McArthur GA, Demetri GD, Joensuu H, Bono P, Herrmann R, Hirte H, Cresta S, Koslin DB, Corless CL, Dirnhofer S, van Oosterom AT, Nikolova Z, Dimitrijevic S, Fletcher JA. Clinical and molecular studies of the effect of imatinib on advanced aggressive fibromatosis (desmoid tumor). *J Clin Oncol* 2006, 24(7):1195-1203.
 - 21) Kurtz JE, Asmane I, Voegeli AC, Neuville A, Dufresne A, Litique V, Chevreau C, Bergerat JP. A V530I Mutation in c-KIT Exon 10 Is Associated to Imatinib Response in Extraabdominal Aggressive Fibromatosis. *Sarcoma* 2010, 2010:458156.
 - 22) Kummar S, O'Sullivan Coyne G, Do KT, Turkbey B, Meltzer PS, Polley E, Choyke PL, Meehan R, Vilimas R, Horneffer Y, Juwara L, Lih A, Choudhary A, Mitchell SA, Helman LJ, Doroshow JH, Chen AP. Clinical Activity of the γ -Secretase Inhibitor PF-03084014 in Adults With Desmoid Tumors (Aggressive Fibromatosis). *J Clin Oncol*. 2017 May 10;35(14):1561-1569.
 - 23) Desmoid Tumor Working Group. The management of desmoid tumours: A joint global consensus-based guideline approach for adult and paediatric patients. *Eur J Cancer*. 2020 Mar;127:96-107.

- 24) Cornelis F, Italiano A, Al-Ammari S, Kind M, Stoeckle E, Gangi A, Palussière J, Bui BN. Successful iterative percutaneous cryoablation of multiple extraabdominal desmoid tumors in a patient with Gardner syndrome. *J Vasc Interv Radiol*. 2012 Aug;23(8):1101-3.
- 25) Havez M, Lippa N, Al-Ammari S, Kind M, Stoeckle E, Italiano A, Gangi A, Hauger O, Cornelis F. Percutaneous image-guided cryoablation in inoperable extra-abdominal desmoid tumors: a study of tolerability and efficacy. *Cardiovasc Intervent Radiol*. 2014 Dec;37(6):1500-6.
- 26) Schmitz JJ, Schmit GD, Atwell TD, Callstrom MR, Kurup AN, Weisbrod AJ, Morris JM. Percutaneous Cryoablation of Extraabdominal Desmoid Tumors: A 10-Year Experience. *AJR Am J Roentgenol*. 2016 Jul;207(1):190-5.
- 27) Cazzato RL, Garnon J, Ramamurthy N, Koch G, Tsoumakidou G, Caudrelier J, Arrigoni F, Zugaro L, Barile A, Masciocchi C, Gangi A. Percutaneous image-guided cryoablation: current applications and results in the oncologic field. *Med Oncol*. 2016 Dec;33(12):140.
- 28) Colangeli S, Parchi P, Andreani L, Beltrami G, Scoccianti G, Sacchetti F, Ceccoli M, Totti F, Campanacci DA, Capanna R. Cryotherapy efficacy and safety as local therapy in surgical treatment of musculoskeletal tumours. A retrospective case series of 143 patients. *J Biol Regul Homeost Agents*. 2018; 32(6 Suppl. 1):65-70.
- 29) Haroun RR, Quencer KB, Erinjeri JP, O'Hara RG, Fine GC. Percutaneous Cryoablation of an Extra-Abdominal Desmoid Tumor Abutting the Skin Surface and Peritoneum. *J Vasc Interv Radiol*. 2019; 30(3):426-427.
- 30) Bouhamama A, Lame F, Mastier C, Cuiet M, Thibaut A, Beji H, Ricoeur A, Blay JY, Pilleul F. Local Control and Analgesic Efficacy of Percutaneous Cryoablation for Desmoid Tumors. *Cardiovasc Intervent Radiol*. 2019. doi:10.1007/s00270-019-02323-5. [Epub ahead of print]
- 31) Redifer Tremblay K, Lea WB, Neilson JC, King DM, Tutton SM. Percutaneous cryoablation for the treatment of extra-abdominal desmoid tumors. *J Surg Oncol*. 2019;120(3):366-375.

Tables

Table 1: Patient's characteristics at study entry.

	Observed in sample	Estimated in population	Missing
Age, median (range)	41.0 yrs	41.0 yrs [37.2; 44.7]	
Sex (% , n)			
Male	0.22 (11)	0.22 [0.123; 0.348]	
Female	0.78 (39)	0.78 [0.652; 0.877]	
Sex ratio M/F	0.282	0.29 [0.139; 0.555]	
Tumor location (% , n)			
Limbs	0.36 (18)	0.35 [0.230; 0.485]	
Thorax	0.30 (15)	0.29 [0.181; 0.424]	
Abdominal wall	0.30 (15)	0.29 [0.181; 0.424]	
Neck	0.04 (2)	0.04 [0.0082; 0.119]	
Tumor size			
Volume (cm3)	209 (257)	448 [389; 511]	6
Largest diameter (cm)	10.0 (4.13)	10.0 [8.83; 11.2]	2
Brief Pain Inventory (BPI) score			
Severity	3.83 (1.81)	3.83 [3.30; 4.35]	
Interference	3.78 (2.02)	3.78 [3.20; 4.35]	
Utility (EQ5D)	0.480 (0.285)	0.479 [0.398; 0.562]	1
<i>CTNNB1</i> wild-type	6		
<i>CTNNB1</i> mutated (% , n)	44		
Mutation Type	0.854 (35)	0.851 [0.723; 0.937]	
T41 A	0.684 (13)	0.664 [0.446; 0.842]	
T45 F	0.211 (4)	0.210 [0.0735; 0.417]	
T45 P	0.105 (2)	0.110 [0.0219; 0.290]	
N/A	16		
Number of prior treatment lines	2 [1-4]*		
Performance status (ECOG) (% , n)			4
0	0.717 (33)	0.71 [0.570 ; 0.825]	
1	0.261 (12)	0.26 [0.150 ; 0.396]	
2	0.0217 (1)	0.03 [0.0023 ; 0.0961]	

Observed column corresponds with frequencies (effectives) for modalities of qualitative variables or mean (sd) for quantitative

Estimated column corresponds with median and 95% credible interval of posterior distribution of frequencies or mean

*One patient was enrolled with 1 prior medical treatment line (major deviation to the protocol)

Table 2: Safety

Side effect	All grades (N, %)		Grade 1-2 (n, %)		Grade 3-4 (n, %)	
Pain	30	21,6	28	20,9	2	1,4
Paresthesia/Dyesthesia/neural impairment	22	15,8	20	14,4	2	1,4
Edema	21	15,1	20	14,4	1	0,7
Musculo-skeletal impairment	11	7,9	11	7,9	0	0
Skin burn	8	5,8	7	5,0	1	0,7
Rhabdomyolysis (CPK increase)	8	5,8	1	0,7	7	5,0
Bleeding	4	2,9	2	1,4	2	1,4
Asthenia/fatigue	6	4,3	5	3,6	1	0,7
Elevation of liver transaminases	3	2,2	2	1,4	1	0,7
Cutaneous fistula	3	2,2	2	1,4	0	0
Anemia	2	1,4	2	1,4	0	0
Pleural effusion	2	1,4	2	1,4	0	0
Hyperleucocytosis	2	1,4	0	0,0	2	1,4
Malaise	2	1,4	1	0,7	1	0,7
Nausea	2	1,4	2	1,4	0	0
Pruritus	2	1,4	1	0,7	0	0
Stroke	1	0,7	0	0	1	0,7
Erythema	1	0,7	1	0,7	0	0
Fever	1	0,7	1	0,7	0	0
Hypokaliemia	1	0,7	1	0,7	0	0
Acute renal failure	1	0,7	0	0	1	0,7
Bowel stoppage	1	0,7	0	0	1	0,7
Ocular dryness	1	0,7	1	0,7	0	0
Heart rhythm disorder	1	0,7	0	0	1	0,7

Figures

Figure 1: Non-progression rate at 12 months according to RECIST 1.1 (Fig 1A) and MRI Contrast Uptake (Fig 1B).

CR: complete response; PR: partial response; SD: stable disease; PD: progressing disease

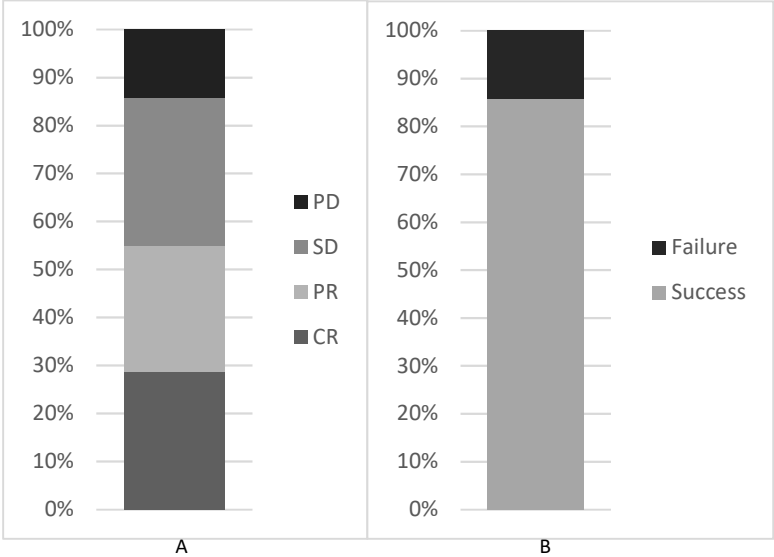


Figure 2: Pain scores over time. Higher scores refer to more intense pain in the Brief Pain Inventory Score. A significant improvement in pain is observed for both severity (Fig 2A) and interference (Fig 2B). A decrease in the frequency of analgesics intake is also observed (Fig 2C).

Figure 2A

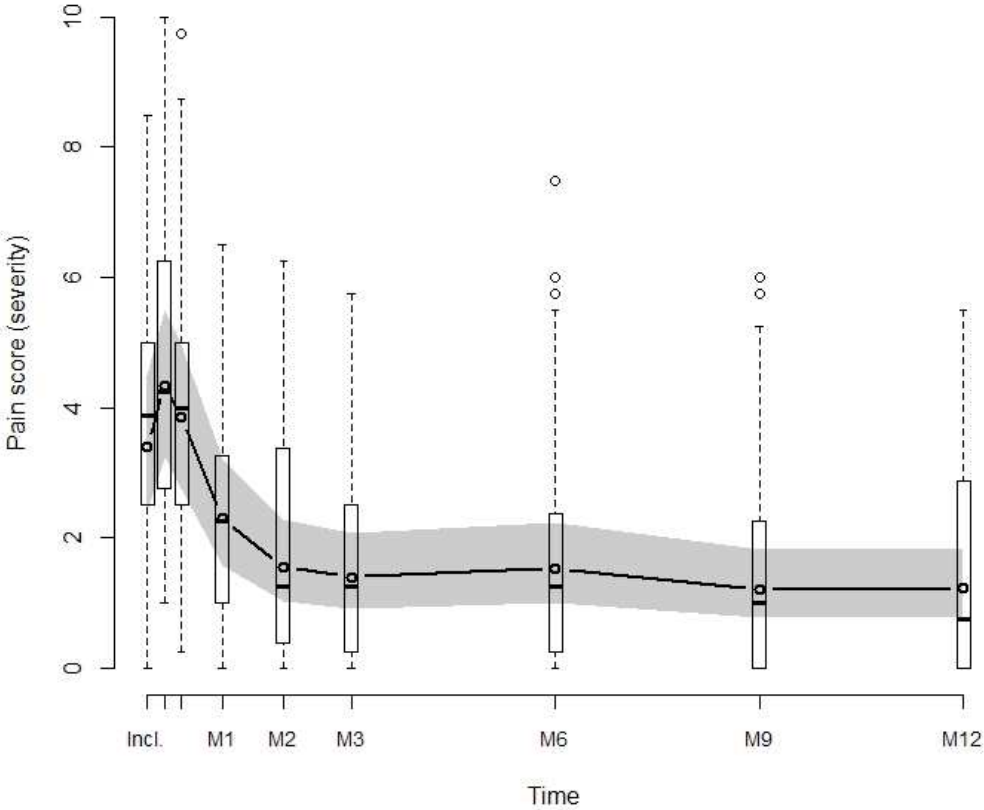


Figure 2B

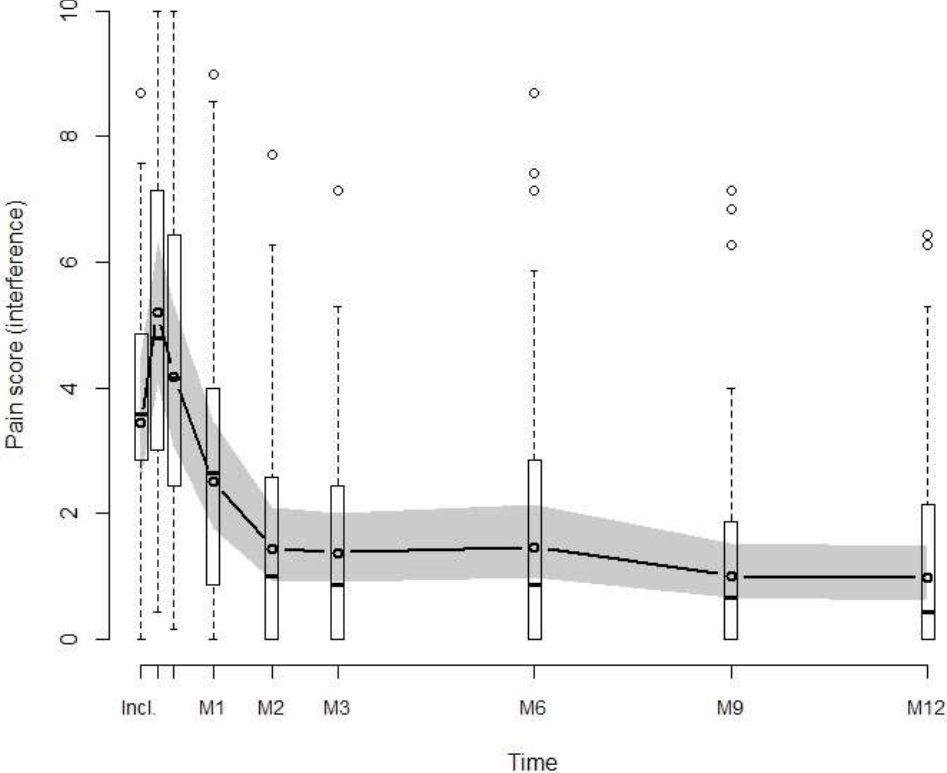


Figure 2C

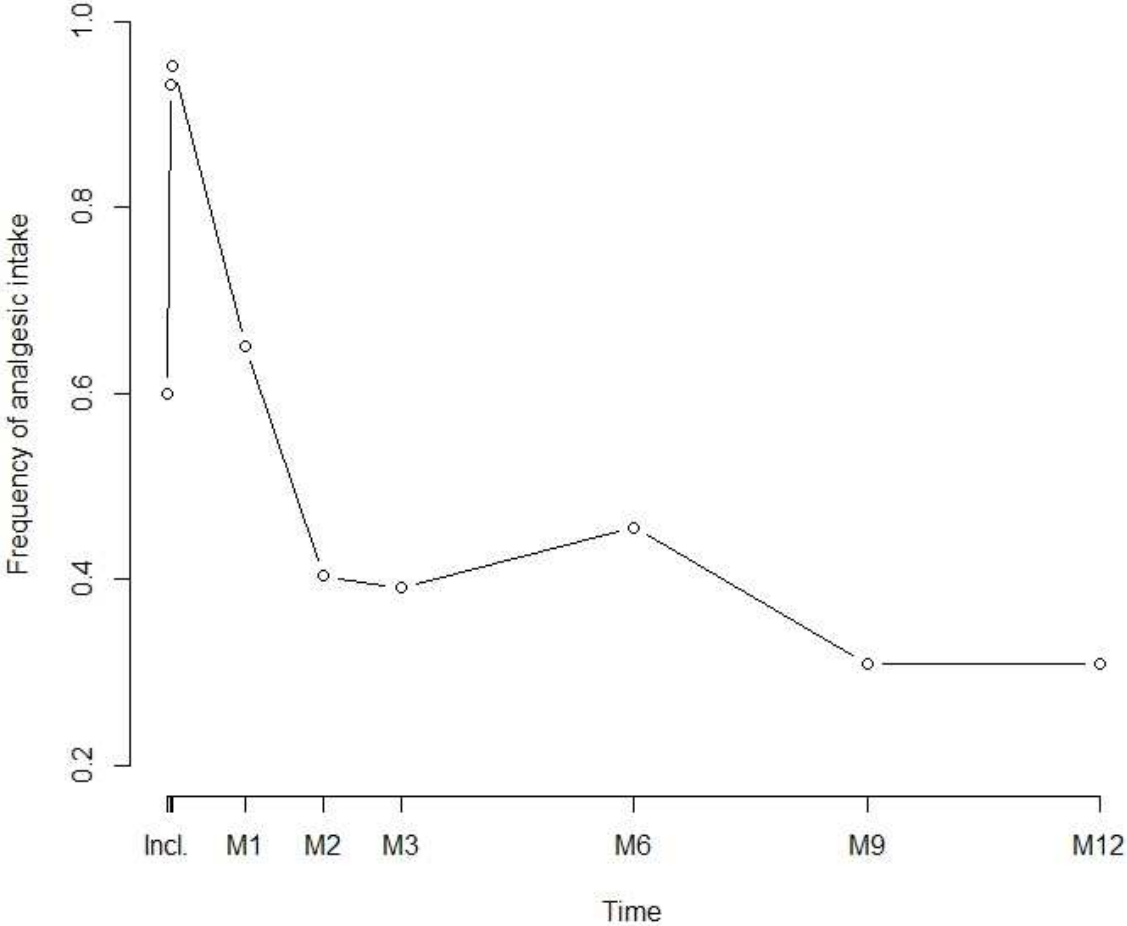
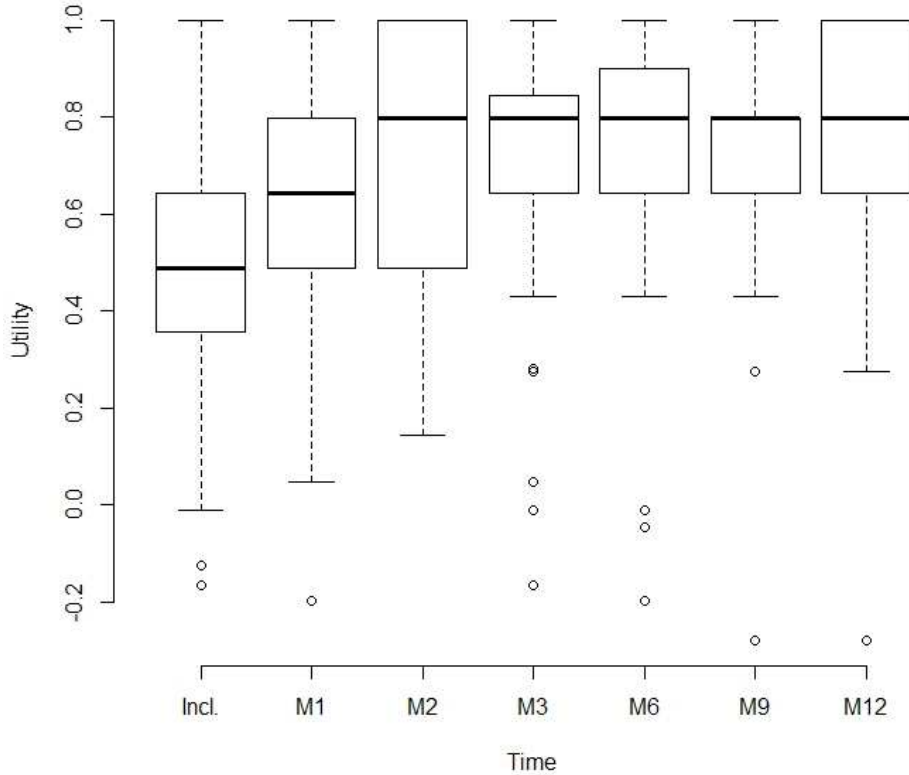


Figure 3: Assessment of quality of life according to the utility score of EQ5D-3L (3A) and the visual analogic scale (3B).

In both cases a significant increase (higher scores refer to a better quality of life) is observed from M2 visit. In the anxiety/depression (3C) and daily activities dimensions (3D) of EQ5D, a favorable outcome was also observed. In daily activities, score 1, 2 and 3 correspond to “no problems”, “some problems” and “unable to perform my usual activities”, respectively. Similarly, for anxiety/depression, score 1, 2 and 3 correspond to “not anxious/depressed”, “moderately depressed” and “extremely depressed”, respectively.

Figure 3 A and 3B



3B:

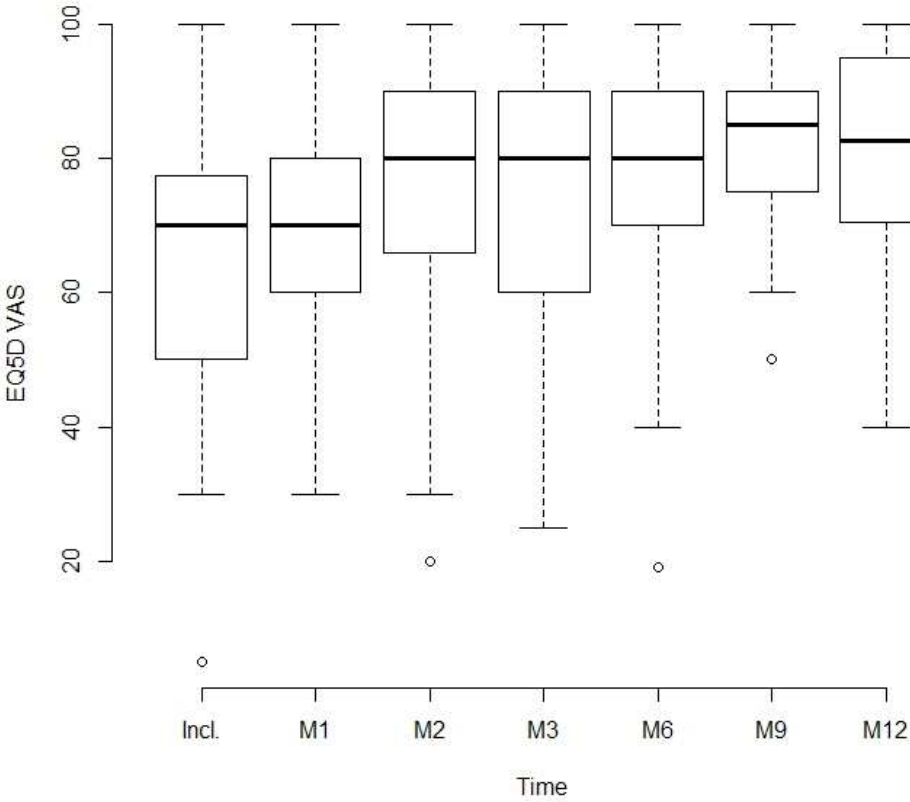


Figure 3C

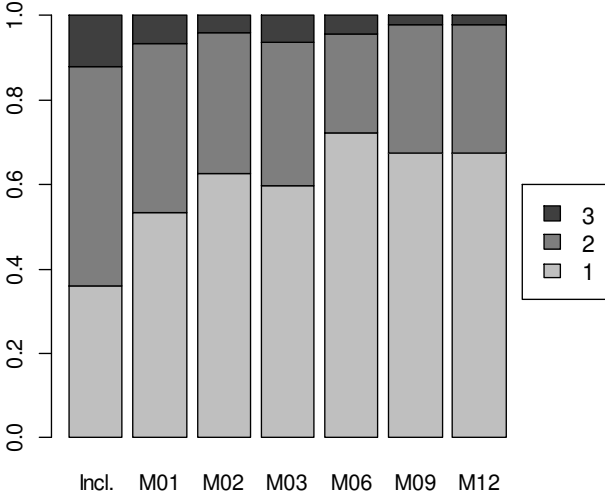


Figure 3D

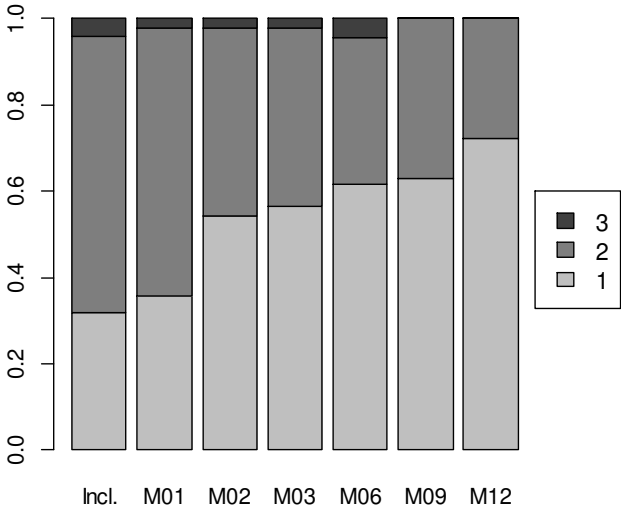


Figure 4: Progression-free survival

