



Schistosoma haematobium infection with pulmonary involvement in a traveller returning from Congo: A case report and systematic review of literature on nodular pulmonary schistosomiasis

Coline Mortier, Camille Aubry, Coralie L'Ollivier, Philippe Gautret,
Jean-Christophe Lagier, Philippe Parola

► To cite this version:

Coline Mortier, Camille Aubry, Coralie L'Ollivier, Philippe Gautret, Jean-Christophe Lagier, et al.. Schistosoma haematobium infection with pulmonary involvement in a traveller returning from Congo: A case report and systematic review of literature on nodular pulmonary schistosomiasis. Travel Medicine and Infectious Disease, 2021, 44, pp.102182. 10.1016/j.tmaid.2021.102182 . hal-03636860

HAL Id: hal-03636860

<https://amu.hal.science/hal-03636860>

Submitted on 5 Jan 2024

HAL is a multi-disciplinary open access archive for the deposit and dissemination of scientific research documents, whether they are published or not. The documents may come from teaching and research institutions in France or abroad, or from public or private research centers.

L'archive ouverte pluridisciplinaire **HAL**, est destinée au dépôt et à la diffusion de documents scientifiques de niveau recherche, publiés ou non, émanant des établissements d'enseignement et de recherche français ou étrangers, des laboratoires publics ou privés.



Distributed under a Creative Commons Attribution - NonCommercial 4.0 International License

***Schistosoma haematobium* infection with pulmonary involvement in a traveller returning
from Congo: a case report and systematic review of literature on nodular pulmonary
schistosomiasis**

Coline Mortier¹, Camille Aubry¹, Coralie L'Ollivier¹, Philippe Gautret¹, Jean-Christophe
Lagier^{1,3}, Philippe Parola^{1,2}

¹ IHU-Méditerranée Infection, Marseille, France.

² Aix Marseille Univ, IRD, AP-HM, SSA, VITROME, Marseille, France.

³ Aix Marseille Univ, IRD, AP-HM, MEPHI, Marseille, France.

*** Corresponding author:** Prof. Philippe Parola. VITROME, Institut Hospitalo-Universitaire
Méditerranée Infection, 19-21 Boulevard Jean Moulin 13385 Marseille Cedex 05, France
Phone: +33 (0) 4 13 73 24 01. Fax: + 33 (0) 4 13 73 24 02
Email:

24 **Keywords:** travellers, pulmonary schistosomiasis, *schistosoma haematobium*, schistosomiasis
25 and thrombosis, nodular pulmonary schistosomiasis

Abstract

Background. Schistosomiasis is highly prevalent in sub-Saharan Africa and diagnosis is difficult for travel medicine practitioners, because it can affect different organs with atypical manifestations. *S. haematobium* is mostly associated with urinary involvement and rarely with pulmonary lesions. This review aims to summarise the pulmonary forms associated with schistosomiasis, especially with *S. haematobium*.

Method. Based on a case report of both pulmonary and urogenital schistosomiasis, we performed a systematic literature review of schistosomiasis occurring in migrants and travellers, with a specific focus on pulmonary schistosomiasis.

Results. Pulmonary schistosomiasis can present two different clinical patterns. On the one hand, there is an acute pattern, which more frequently affects non-immune young travellers within three to eight weeks of their return and, on the other hand, there is a chronic pattern, which has been evolving in recent years and which mostly affects people living in endemic areas or migrating from these countries. Nodular pulmonary lesions are described in both patterns. Genus identification should not focus only on known patterns, and identification of *S. haematobium* should not be associated exclusively with urinary schistosomiasis.

Conclusions. Pulmonary schistosomiasis, even when resulting from *S. haematobium*, is a rare but existing infection that appears to be spreading with increasing travel and global migration. Physicians need to be more aware of non-specific symptoms that may reveal an atypical presentation of a tropical disease, in order to avoid the chronic complications which can result from parasitic diseases.

Introduction

Schistosomiasis is one of the most prevalent parasitic diseases in the world and is a threat to human health (1) (2) . It affects more than 200 million people in the world and transmission has been reported in 78 countries according to the WHO. The main endemic area remains Africa, where there is a mean prevalence of 37.3% and where the prevalence in some areas can reach 60% (measured using parasitological diagnostic tests) (2). The main focal point is in sub-Saharan countries where schistosomiasis has been neglected for many years. Lake Malawi in eastern Africa is the area with the highest prevalence of symptomatic patients, where rates can reach up to 94.9% in some communities (based on parasitological tests on symptomatic people) (3). Asia and South America are endemic areas with a lower parasitic prevalence (4).

Schistosomiasis is also an issue which affects travellers and migrants (5). One systematic Canadian review established that schistosomiasis seroprevalence was the highest in migrants originating from countries in sub-Saharan Africa. It found that seroprevalence was 24.1% in sub-Saharan migrants arriving in host countries where schistosomiasis is not endemic (USA, Canada, Australia, New Zealand, Israel and 23 western European countries), in comparison with a pooled seroprevalence of 18.4% in these same countries (6). Among travellers, the GeoSentinel network reported 410 cases of travel-associated schistosomiasis over a decade (1997 to 2008), with a total of 83% cases acquired in Africa (5) (7), when individuals born in endemic areas were excluded. Schistosomiasis was shown to be one of the ten leading causes of morbidity among returning travellers, accounting for 2% of ill travellers returning from sub-Saharan Africa (7). Schistosomiasis is endemic in certain provinces of the Democratic Republic of the Congo (DRC) and is spreading to formerly non-endemic regions (8). Three species of *Schistosoma* have been found in the DRC: *S. mansoni*, *S. haematobium*

and *S. intercalatum*. The prevalence of confirmed schistosomiasis varied between regions and between villages, with high values of up to 95% observed in some communities (8).

The prevalence of schistosomiasis varies according to the distribution of freshwater snails, the intermediate hosts, and to the different behavioural patterns of human activities in different areas. The clinical spectrum of schistosomiasis varies widely in humans (1), but the most frequent clinical presentations are urogenital schistosomiasis (*S. haematobium*, which is endemic in Africa, the Middle East and, more recently, Corsica in France (9) (10)), intestinal schistosomiasis (*S. mansoni*, which is endemic in Africa, the Middle East, Brazil, Venezuela, and the Caribbean), and the intestinal and hepatosplenic forms (*S. japonicum*, which is endemic only in China, the Philippines and Indonesia (4) (11)).

Individuals who have contracted schistosomiasis may remain asymptomatic or may present with non-specific complaints. Several complications can appear at a later stage and can include severe organic lesions and even cancer. For *S. haematobium*, the most severe complication is bladder cancer following urinary schistosomiasis. Pulmonary lesions due to schistosomiasis are described less often, and genus identification for *S. haematobium* has only been related to pulmonary symptoms in acute pulmonary patterns.

In this study, we report a case of schistosomiasis due to *S. haematobium*, occurring in a French traveller returning from DRC, presenting a spontaneous thrombosis leading to the diagnosis of both pulmonary and bladder schistosomal lesions. The specificity of our case report is that *S. haematobium* eggs were found on the bladder biopsy, and at the same time PCR (targeting the *DraI* gene (12)) was positive on the lung biopsy. This contrasts with other situations where genus identification is rare and is almost never positive for *S. haematobium* in lung biopsies. In addition, nodular pulmonary lesions were reported as appearing in this non-immune traveller one year after exposure, in contrast to the usual time of a few weeks between first exposure and the development of pulmonary lesions.

Material and results

We present a case report highlighting an atypical pattern of schistosomiasis. We performed a systematic review of the medical literature relating to nodular pulmonary lesions and schistosomiasis, with a focus on *S. haematobium*. Articles were identified through a literature search using the PubMed database (until December 2020), in accordance with the Preferred Reporting Items for Systematic Reviews and Meta-Analyses (PRISMA) guidelines. We searched all articles listed in PubMed and indexed for Medline, using the combination of terms “nodular pulmonary schistosomiasis”, “*Schistosoma haematobium*” and “pulmonary”, and “pulmonary” and “bladder schistosomiasis”. The selection of articles is presented in Figure 1.

Only publications of nodular pulmonary cases or reviews of these cases were included, and genus identification was not a criteria for exclusion. Articles which were written in neither English nor Spanish were excluded. We included 24 publications reporting on 43 published case reports, which we classified into acute and chronic pulmonary disease.

A systematic review of the association between schistosomiasis and thrombosis was also performed using the PubMed database and the keywords “hypercoagulability”, “schistosomiasis” and “thrombosis”.

Case report

A 63-year-old male French traveller, with no significant medical history, who had stopped smoking 35 years previously, was diagnosed in August 2017 with a spontaneous deep vein thrombosis in his right leg. Computerised tomographic scans of his chest (CT-scan), abdomen and pelvis were performed to detect malignancies. Three pulmonary nodules were found, ranging in size from 5 to 10 mm (Figure 2). In addition, the CT-scan found a

thickening of the bladder anterior wall. Suspecting a malignancy, a transurethral resection of the bladder tumour was performed. Subsequently, a right middle lobe wedge resection was performed. In the histopathology department, a cystic wall examination revealed a granulomatous inflammation with epithelioid macrophages, giant cells and numerous *Schistosoma* spp. eggs with no malignancy (Figures 3 and 4) (12). The pulmonary nodule histopathology analysis showed non-caseating granulomatous lesions and the PCR was positive (targeting Dra1 gene (12)) for *S. haematobium* on the pulmonary biopsy.

When interviewed, the patient reported having taken one month off work every year for ten years, which he spent in DRC, in central Africa. His last trip was a year ago. During his travels, he reported walking in rivers and stagnant water (exposed to a slow-flowing river). The results of his clinical examinations were normal. Laboratory tests revealed leucocytosis ($6 \times 10^9/l$: normal range $4-10 \times 10^9/l$) without eosinophilia ($0.37 \times 10^9/l$: normal range $0.1-0.7 \times 10^9/l$). The C-reactive protein (CRP), liver enzymes and electrolytes were within normal ranges. The total IgE was elevated (265 kUI/L : normal range $1-100 \text{ kUI/L}$). Serology (ELISA, Novagnost, NovaTec, Western blot LD-Bio France) for schistosomiasis was positive for total Ig (ratio 58, positive >10) and no eggs were found in his urine or stool samples. The patient was treated with oral Praziquantel, 60 mg/kg/day in one intake, and the same dose was repeated after two weeks. Two months after treatment, his serology was stable and remained so over the course of several checks in 2018. Pulmonary nodular lesions remained stable on several CT chest examinations.

Figure 2. Multiple pulmonary nodules caused by schistosomiasis in a patient returning from Congo, PET Scan

Figure 3. Granulomatous lesion and *S.haematobium* eggs in a pulmonary biopsy (image with 100x magnification, hematoxylin-eosin stain)

Figure 4. *S. haematobium* eggs in a pulmonary biopsy (image with 500x magnification, hematoxylin-eosin stain)

Systematic review

Schistosomiasis and pulmonary nodular lesions

Two different patterns are described in the literature with regard to pulmonary lesions in schistosomiasis infections (13)(14). The first exposure to *Schistosoma* spp. may create an immunological reaction around three to eight weeks after exposure. One common feature of the so-called Katayama syndrome may be a dry cough with, usually, normal imaging, although some nodular, non-specific lesions may sometimes be seen. We found 31 published case reports that reported nodular lesions on CT in this context. (Table 1). The clinical symptoms were mostly a dry cough and fever. The mean age was 25.3 years old (14–50), and a predominance for males was observed (67%, 20M, 10F). All but one of the cases were in travellers returning from Africa (one case was in a traveller returning from Saudi Arabia), where *S. mansoni* and *S. haematobium* are endemic, although the genus was not always identified. The diagnosis was reached using positive serology, but the PCR was almost never positive at this early stage. Associated indicative biological features were eosinophilia, elevated IgE, and hepatic cytolysis (15)(16)(17)(18)(19)(20)(21)(22)(23)(24)(25)(26). Recently, one bifocal case with bladder and pulmonary involvement due to *S. haematobium* was reported in the UK in a traveller who had recently returned from Ghana (26).

In contrast, chronic schistosomiasis has been described as affecting people living in endemic areas who are permanently exposed to the parasite. It has also been described in migrants arriving in non-endemic host countries (27)(28). The mean age of these migrants was 22.3 years (18–28). Such a pattern is more common and causes fibrosis and granuloma due to inflammation. Chronic pulmonary schistosomiasis appears many years after exposure,

and can lead to irreversible lesions (13)(22). We found 12 published case reports describing pulmonary nodules associated with chronic schistosomiasis, but this pattern is likely to be under-reported in the literature (Table 2). Genus identification was more frequently available in these reports, and *S. mansoni* infections were the most likely to be documented. No *S. haematobium* eggs were found in lung biopsies in these patients. The clinical features were non-specific, including dyspnoea, chest pain, asthenia, and a cough. More severe complications associated with these lesions were heart failure, pulmonary arterial hypertension, and obstructive syndrome, which were not directly due to schistosomiasis.

Discussion and conclusion

Consequences for clinicians and travellers

Schistosomiasis can be revealed by varied symptoms that can be non-specific and should be investigated by clinicians whenever they examine travellers or migrants with an atypical presentation, especially when returning from Africa. Similarly, past exposure to schistosomiasis in patients presenting with unexplained chronic symptoms should also be investigated, alongside more recent exposure. During pre-travel consultations, travellers should be made aware of and provided with advice on this major risk (one which is often overlooked in comparison with malaria or diarrhoea), as there is no treatment to prevent schistosomiasis. In recent years, with the rise in eco-tourism and the globalisation of tourism, an increasing number of travellers returning from endemic areas have contracted schistosomiasis. The most frequent pattern reported is acute schistosomiasis after recent exposure, although patients occasionally present with the chronic consequences of an untreated schistosomiasis infection. Cercarial shedding is mostly diurnal when travellers may take part in several freshwater activities (3)(1). Contact with infected water can occur while bathing, swimming, scuba diving, rafting or water skiing, which are frequent tourist activities

199 in such endemic areas. Weather conditions such as rain, wind, water levels and waves in
200 lakes, temperature and rainfall have a strong influence on intermediate hosts and can therefore
201 influence the density of infected people and transmission (3). Preventative advice about not
202 swimming in freshwater lakes should be given rather than promoting rafting or water-based
203 tourist activities in those endemic areas. Itching and pruritic papules on the skin following
204 exposure to fresh water should be the first sign alerting to larvae penetration (1).

205 Pulmonary schistosomiasis is a rare and a hard to diagnose disease, as it presents with
206 very non-specific symptoms and inconclusive results from laboratory testing and imaging
207 (21)(12). It mimics other infections such as tuberculosis (28). Pulmonary manifestations are
208 rarely seen with *S. haematobium*. When genus identification is made in pulmonary
209 schistosomiasis, it is more commonly associated with *S. mansoni*, and represents chronic
210 patterns with exposure occurring years before any clinical manifestations.

211 Interestingly, our case report begins with a venous thrombosis without any triggering
212 factor. Thrombotic complications have been associated with other *Schistosoma* spp. (in
213 *S. mansoni* infection, portal vein thrombosis with a hepatic form (29)(30) and mesenteric
214 thrombosis with gastro-intestinal schistosomiasis damage (31)(32)). To our knowledge,
215 however, this is the first case describing thrombosis due to a *S. haematobium* infection.
216 Several explanations should be explored in the future (chronic inflammatory thrombogenesis
217 and hypercoagulability with enhanced fibrinolysis has been found in *S. mansoni*-infected mice
218 (29)), but this case should lead clinicians to recall this aetiology when presented with a
219 traveller with unexplained deep thrombosis.

220 Schistosomiasis remains a global issue and needs to be more effectively controlled and
221 prevented. With increasing migration, many travellers are exposed to potentially
222 contaminated water and should be aware of potential symptoms of infection if we want to
223 reduce severe manifestations of acute schistosomiasis and prevent complications of chronic

224 disease in the future. Due to the different patterns we described this should encourage travel
225 medicine clinicians to look for schistosomiasis when treating patients returning from endemic
226 areas, even if they do not present typical urinary or gastrointestinal symptoms.

227

228 **Declaration of patient consent: YES**

229 **Conflict of interest: There are no conflicts of interest**

230

Figure 1 PRISMA flow diagram

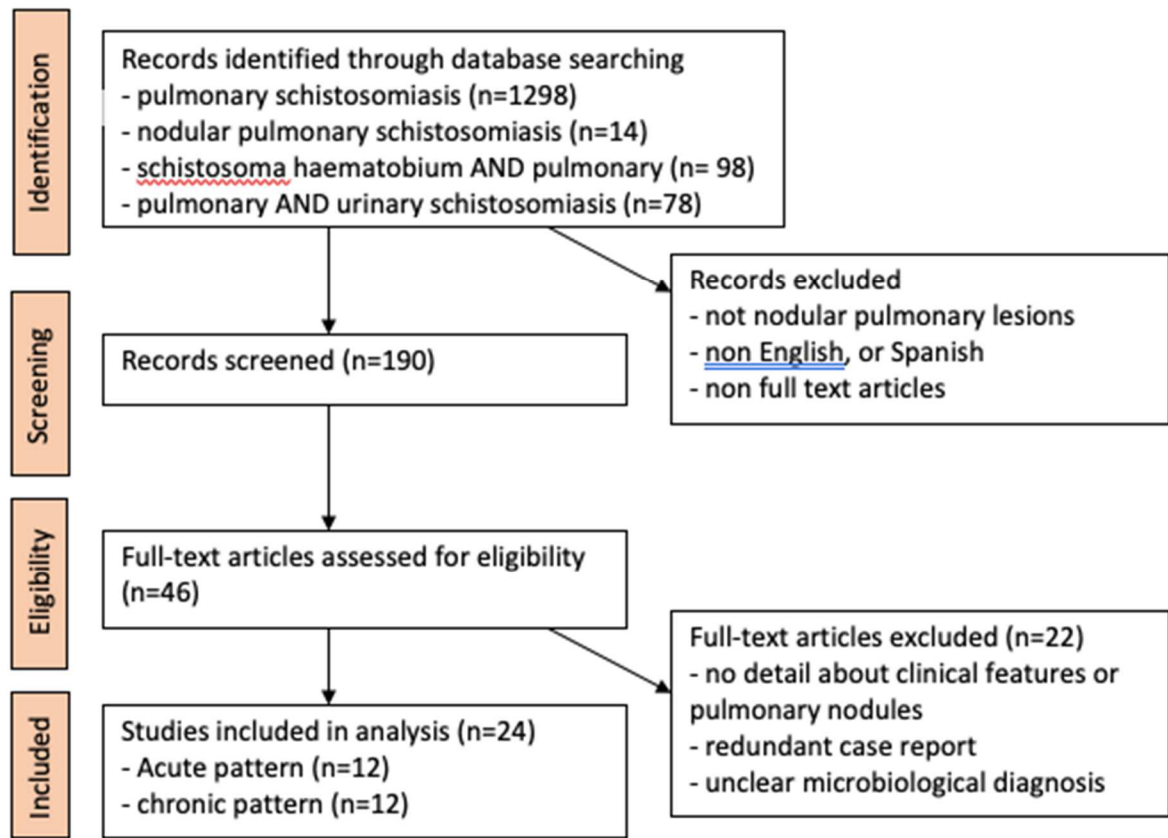


Figure 2. Multiple pulmonary nodules caused by schistosomiasis in a patient returning from Congo, PET Scan

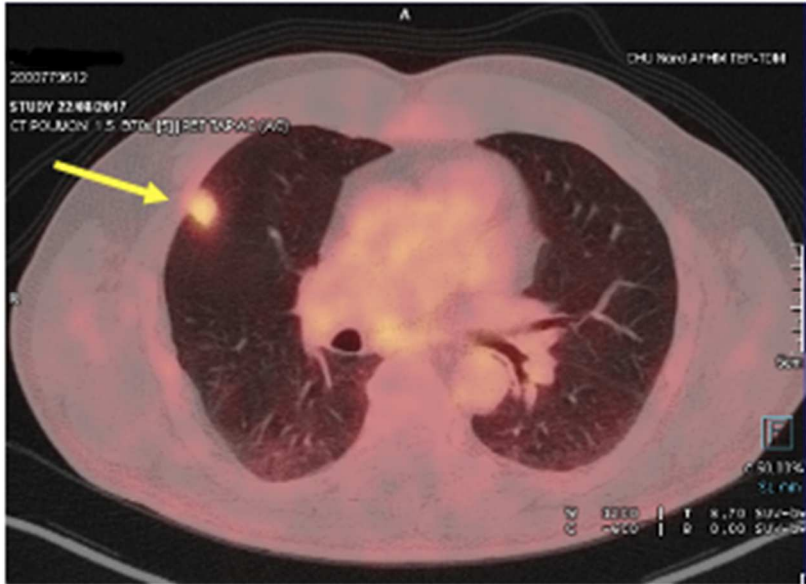
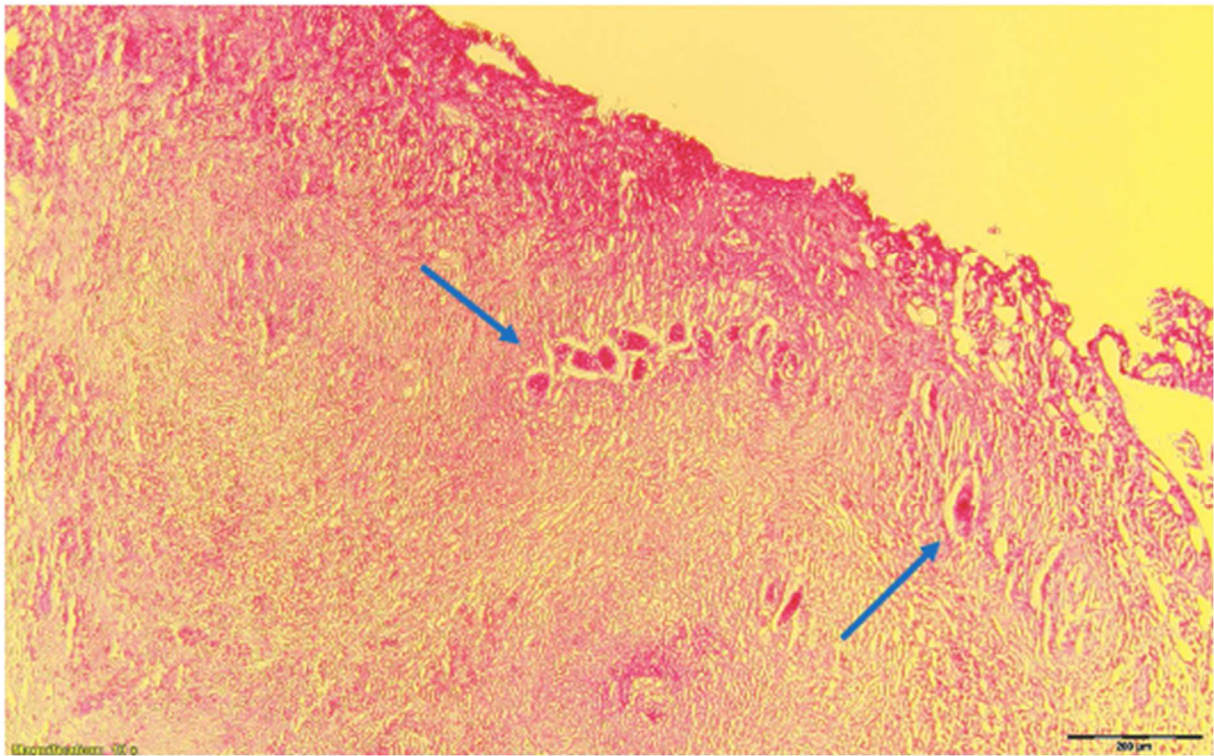
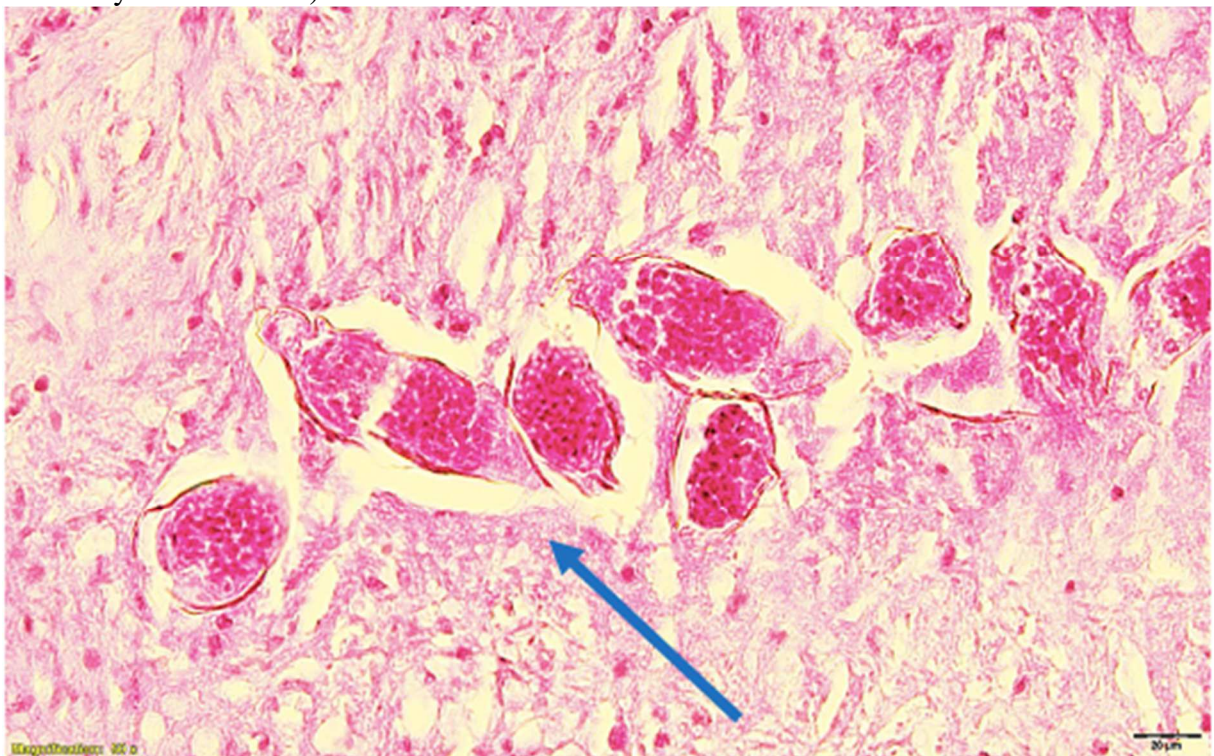


Figure 3. Granulomatous lesion and *S.haematobium* eggs in a bladder biopsy (image with 100x magnification, hematoxylin-eosin stain)



241

242 **Figure 4** *S. haematobium* eggs in a bladder biopsy (image with 500x magnification,
243 hematoxylin-eosin stain)



244

245 **Table 1 : Acute pattern of pulmonary schistosomiasis: review of pulmonary nodule cases. *S.haematobium* was found in eight cases, all in patients**
246 **exposed fewer than eight weeks previously**
247
248

Area of exposure	Gender, age (year)	Time from exposure (weeks)	Clinical presentation	Eosinophilia in G/L (%)	Genus identification	Year of publication (Reference)
Angola	M, 35	8	Dry cough, night sweats	1.45	<i>S. mansoni</i> positive serology negative urinary detection Biopsy : eosinophils, <i>S. mansoni</i> eggs +	1991 (25)
Lake Malawi	4 cases F, 20 M, 22 F, 20 M, 20	4 3 2 8	- Fever, cough, cutaneous rash - Fever, headache, sweats - Fever, dysuria, rash - Rash, dry cough, pruritus	33 (ND) 2 (ND) 8.4 (ND) 4 (ND)	Ø, Positive serology, negative skin and rectal biopsy Ø, positive serology only week 14, negative skin and rectal biopsy Ø, positive serology only week 10, negative stool examination <i>S. haematobium</i> positive serology week 10 , positive stool	1999 (19)
Malawi S. Africa Malawi Ghana Malawi Malawi Malawi Malawi	M, 24 M, 30 M, 24 M, 44 M, 24 M, 25 F, 24 F, 23	4-5 3-4 3-4 4 3-6 3-4 3-4 4	Pulmonary symptoms (unspecified)	3.65 (39) 2.9 (30) 4.8 (44) 4.2 (34) 5.4 (48) 3.6 (48) 6.2 (36) 1.4 (20)	<i>S. haematobium</i> positive serology, eggs - <i>S. haematobium</i> positive serology, eggs + <i>S. mansoni</i> positive serology, eggs + <i>S. mansoni</i> positive serology, eggs - <i>S. haematobium</i> positive serology, eggs + <i>S. haematobium</i> positive serology, eggs + <i>S. haematobium</i> positive serology, eggs - <i>S. haematobium</i> positive serology, eggs +	2000 (24)
East Africa and Lake Malawi (Nkbata Bay)	M, 25	6	Cough, loss of 10 Kg	ND	Ø Positive serology (I 32) negative urinary detection	2002 (18)
Tanzania	10 cases M, 19 M, 23 F, 20	8	Dry cough, shortness of breath Dry cough None	6 (42) 2.3 (44) 1 (18)	<i>S. mansoni</i> (Serology and immunoblot)* <i>S. mansoni</i> (Serology and immunoblot)*	2006 (17)

	F, 19 F, 19 M, 50 M, 19 F, 22 F, 20 F, 47		Mild dry cough Mild dry cough Intermittent, mild shortness of breath Mild dry cough None None None	1.5 (24) 6.7 2.0 (13) 3.9 (35) 0.4 0.6 (5) 0.4 (35)	<i>S. mansoni</i> (Serology and immunoblot)* <i>S. mansoni</i> (Serology and immunoblot)* <i>S. mansoni</i> (Serology and immunoblot)* <i>S. mansoni</i> (Serology and immunoblot)* <i>S. mansoni</i> (Serology and immunoblot)* <i>S. mansoni</i> (Serology and immunoblot)* <i>S. mansoni</i> (Serology and immunoblot)*	
Central Africa	M, 28	2,5	Dry cough, night sweats, fever	6.9 (57)	NR	2010 (21)
Saudi Arabia	M, 14	5	Fever, cough, discomfort	2.43 (30)	Ø video-assisted thoracoscopic lung biopsy: Schistosomal ovum positive serology (genus NR) Negative stool sample, BAL fluid analysis: eosinophils (7%), negative culture	2011 (16)
Madagascar	M, 30	4	Fever, myalgia, cough	3.58 (43)	positive <i>S. mansoni</i> FAST-ELISA test negative <i>S. mansoni</i> immunoblot	2012 (20)
Nile valley	M, 24	7	Cough, discomfort, diarrhoea, cutaneous rash with papules	3	Positive serology, eggs -	2016 (15)
Benign	M, 21	8	Fever, cough, chest pain	1.3	Ø Pulmonary biopsy: schistosoma eggs <i>S. haematobium</i> suspected but no confirmation	2016 (22)
Yemen	M, 23	1	Cough, haemoptysis, chest pain	ND (elevated WBC 13 with eosinophil predominant)	thoracoscopy and excision of abscess: <i>S. mansoni</i> eggs BAL: negative	2018 (23)

Ghana	M, 25	“recent”	Chronic cough, wheezing	ND	<i>S. haematobium</i> found in bladder biopsy	2019 (26)
-------	-------	----------	-------------------------	----	---	-----------

249

250

251 **Table 2 : Chronic pattern of pulmonary schistosomiasis: review of pulmonary nodule cases.**

252

Area of exposure	Gender, age (year)	Time from exposure (years)	Clinical features and pulmonary lesions (size in mm)	Eosinophila in G/L (%)	Genus identification	Year of publication (Reference)
Mali Guinea Ivory Coast Senegal Mali Mali Nigeria	7 cases M, 27 M, 25 M, 28 M, 19 M, 21 M, 18 M, 18	5 1 1 5 1 1 1	multiple nodules	0.75 (13,9) 0,44 (9,6) 0,79 (12,9) 2,04 (31) 2,29 (36,4) 1,96 (22) 0,4 (6,6)	<i>S. mansoni</i> eggs in lung biopsy and stool <i>Schistosoma</i> spp eggs in lung biopsy <i>Schistosoma</i> spp eggs in lung biopsy, <i>S haematobium</i> eggs in urine, <i>S. mansoni</i> eggs in stool <i>Schistosoma</i> spp eggs in lung biopsy, <i>S haematobium</i> eggs in urine <i>Schistosoma</i> spp eggs in lung biopsy, <i>S haematobium</i> eggs in urine no lung biopsy, <i>S haematobium</i> eggs in urine, <i>S. mansoni</i> eggs in stool no lung biopsy, <i>S haematobium</i> eggs in urine	2017 (28)
Egypt	M, 47	Living in area	Pulmonary mass (60mm)	1 (12)	<i>Schistosoma</i> spp eggs in lung biopsy (surgical resection)	1953 (33)
Cameroon	F, NR	Living in area	Chest pain Abscess in the left lung	1	<i>S.mansoni</i> eggs in lobectomy, <i>S haematobium</i> eggs in stool	1982 (34)
Martinique	F, NR	Living in area		NR	<i>S. mansoni</i> in lung biopsy, stool was negative	1988 (35)
Saudi Arabia	F, 13	Living in area	Fever, sweat, weight loss, haematuria Pulmonary lymph node and left pulmonary nodule	NR	<i>Schistosoma</i> spp eggs in lung biopsy	1990 (36)
Brazil	F, 33	Living in	Nodule in right lobe of the	NR	<i>S. mansoni</i> eggs in lung biopsy	2003 (37)

		area	lung			
Gabon	F, 47	Living in area	Fever, chest pain, pneumonia, haemoptysis	NR	<i>Schistosoma</i> spp eggs in lung biopsy	2005 (38)
Brazil	M, NR	Living in area	Dry cough, weight loss, chest pain Pulmonary mass in left lobe	NR	<i>S. mansoni</i> eggs in lung biopsy	2009 (39)
Mali	F, NR	1,3	Pulmonary nodule	1,5	Serology <i>Schistosoma</i> spp positive	2009 (40)
Brazil	M, 25	Living in area	Pulmonary mass Died after surgery	NR	<i>Schistosoma mansoni</i> eggs in lung biopsy	2009 (41)
China	M, 93	Living in area	Lung mass	NR	<i>Schistosoma japonicum</i> eggs in aspiration of the lung mass	2014 (42)
Saudi Arabia	M, 60	26	Asymptomatic solitary pulmonary nodule 20 mm	NR	<i>Schistosoma</i> spp eggs in lung biopsy	2014 (43)

253

254

255 **REFERENCES**

- 256 1. Gryseels B, Polman K, Clerinx J, Kestens L. Human schistosomiasis. *The Lancet*. sept 2006;368(9541):1106–18.
- 257 2. Schur N, Vounatsou P, Utzinger J. Determining Treatment Needs at Different Spatial Scales Using Geostatistical Model-Based Risk Estimates of
258 Schistosomiasis. *Brooker S, éditeur. PLoS Negl Trop Dis*. 13 sept 2012;6(9):e1773.
- 259 3. Makaula P, Sadalaki JR, Muula AS, Kayuni S, Jemu S, Bloch P. Schistosomiasis in Malawi: a systematic review. *Parasites Vectors*. déc 2014;7(1):570.
- 260 4. Chen Y-Y, Liu J-B, Jiang Y, Li G, Shan X-W, Zhang J, et al. Dynamics of spatiotemporal distribution of schistosomiasis in Hubei Province, China. *Acta
261 Tropica*. avr 2018;180:88–96.
- 262 5. Schwartz E, von Sonnenburg F, Reed C, Weld LH, Nicolls DJ, Kozarsky PE, et al. Characteristics of Schistosomiasis in Travelers Reported to the
263 GeoSentinel Surveillance Network 1997–2008. *The American Journal of Tropical Medicine and Hygiene*. 1 nov 2008;79(5):729–34.
- 264 6. Asundi A, Beliavsky A, Liu XJ, Akaberi A, Schwarzer G, Bisoffi Z, et al. Prevalence of strongyloidiasis and schistosomiasis among migrants: a systematic
265 review and meta-analysis. *The Lancet Global Health*. févr 2019;7(2):e236–48.
- 266 7. Cetron MS, Chitsulo L, Sullivan JJ, Pilcher J, Wilson M, Noh J, et al. Schistosomiasis in Lake Malawi. *The Lancet*. nov 1996;348(9037):1274–8.
- 267 8. Madinga J, Linsuke S, Mpabanzi L, Meurs L, Kanobana K, Speybroeck N, et al. Schistosomiasis in the Democratic Republic of Congo: a literature
268 review. *Parasites Vectors*. déc 2015;8(1):601.
- 269 9. Gautret P, Mockenhaupt FP, von Sonnenburg F, Rothe C, Libman M, Van De Winkel K, et al. Local and International Implications of Schistosomiasis
270 Acquired in Corsica, France. *Emerg Infect Dis*. oct 2015;21(10):1865–8.
- 271 10. Beltrame A, Zammarchi L, Zuglian G, Gobbi F, Angheben A, Marchese V, et al. Schistosomiasis Screening of Travelers from Italy with Possible
272 Exposure in Corsica, France. *Emerg Infect Dis*. oct 2015;21(10):1887–9.
- 273 11. Lei Z, Zhang L, Xu Z, Dang H, Xu J, Lv S, et al. [Endemic status of schistosomiasis in People’s Republic of China in 2014]. *Zhongguo Xue Xi Chong Bing
274 Fang Zhi Za Zhi*. déc 2015;27(6):563–9.
- 275 12. Cnops L, Soentjens P, Clerinx J, Van Esbroeck M. A *Schistosoma haematobium*-Specific Real-Time PCR for Diagnosis of Urogenital Schistosomiasis in
276 Serum Samples of International Travelers and Migrants. *Lammie PJ, éditeur. PLoS Negl Trop Dis*. 29 août 2013;7(8):e2413.
- 277 13. Schwartz E. Pulmonary schistosomiasis. *Clinics in Chest Medicine*. juin 2002;23(2):433–43.

278 14. Sami A-A. Pulmonary Manifestations of Schistosomiasis. Diseases of the Chest. juin 1951;19(6):698-705.

279 15. Puylaert CAJ, van Thiel P-P. Katayama Fever. N Engl J Med. 4 févr 2016;374(5):469-469.

280 16. Al-Jahdali H, Bamefleh H, Elkeir A, Yamani N, Baharoon S. Acute pulmonary schistosomiasis. J Global Infect Dis. 2011;3(3):303.

281 17. Nguyen L-Q, Estrella J, Jett EA, Grunvald EL, Nicholson L, Levin DL. Acute Schistosomiasis in Nonimmune Travelers: Chest CT Findings in 10 Patients.
282 American Journal of Roentgenology. mai 2006;186(5):1300-3.

283 18. Salanitri J, Stanley P, Hennessy O. Acute pulmonary schistosomiasis. Australas Radiol. déc 2002;46(4):435-7.

284 19. Cooke GS, Lalvani A, Gleeson FV, Conlon CP. Acute Pulmonary Schistosomiasis in Travelers Returning from Lake Malawi, Sub-Saharan Africa. CLIN
285 INFECT DIS. oct 1999;29(4):836-9.

286 20. Pavlin BI, Kozarsky P, Cetron MS. Acute pulmonary schistosomiasis in travelers: Case report and review of the literature. Travel Medicine and
287 Infectious Disease. sept 2012;10(5-6):209-19.

288 21. Niemann T, Marti HP, Duhnsen SH, Bongartz G. Pulmonary Schistosomiasis – Imaging Features. Radiology Case. 10 sept 2010;4(9):37-43.

289 22. Coron N, Chabasse D, Kettani S, Le Govic Y, Hemery S, Pihet M, et al. Early Detection of Schistosoma Egg–Induced Pulmonary Granulomas in a
290 Returning Traveler. The American Journal of Tropical Medicine and Hygiene. 2 mars 2016;94(3):611-4.

291 23. Hajjar W, Alsheikh A, Alhumaid A, Alkredees N, Abdulwahed N, Hajjar A. Pulmonary schistosomiasis in a young male: A case report and review of
292 the literature. Ann Thorac Med. 2018;13(3):190.

293 24. Schwartz E, Rozenman J, Perelman M. Pulmonary manifestations of early schistosome infection among nonimmune travelers. The American Journal
294 of Medicine. déc 2000;109(9):718-22.

295 25. Schaberg T, Rahn W, Racz P, Lode H. Pulmonary schistosomiasis resembling acute pulmonary tuberculosis. Eur Respir J. sept 1991;4(8):1023-6.

296 26. Massie J, Howling S. *Schistosoma haematobium* causing pulmonary schistosomiasis in a returning traveller. BMJ Case Rep. mars 2019;12(3):e227347.

297 27. Gobbi F, Martelli G, Attard L, Buonfrate D, Angheben A, Marchese V, et al. Schistosoma mansoni Eggs in Spleen and Lungs, Mimicking Other
298 Diseases. Zhou X-N, éditeur. PLoS Negl Trop Dis. 23 juill 2015;9(7):e0003860.

299 28. Gobbi F, Buonfrate D, Angheben A, Beltrame A, Bassetti M, Bertolaccini L, et al. Pulmonary nodules in African migrants caused by chronic
300 schistosomiasis. The Lancet Infectious Diseases. mai 2017;17(5):e159-65.

301 29. Lambertucci JR, Resende V, Voietá I. Portal vein thrombosis in a patient with hepatosplenic schistosomiasis mansoni. *Rev Soc Bras Med Trop.* avr
302 2009;42(2):235-6.

303 30. Olveda DU, Olveda RM, Montes CJ, Chy D, Abellera JMB, Cuajunco D, et al. Clinical management of advanced schistosomiasis: a case of portal vein
304 thrombosis-induced splenomegaly requiring surgery. *Case Reports.* 17 juin 2014;2014(jun17 1):bcr2014203897-bcr2014203897.

305 31. Mosli MH, Chan WW, Morava-Protzner I, Kuhn SM. Schistosomiasis Presenting as a Case of Acute Appendicitis with Chronic Mesenteric Thrombosis.
306 *Canadian Journal of Infectious Diseases and Medical Microbiology.* 2016;2016:1-3.

307 32. Anayi S, Al-Nasiri N. Acute mesenteric ischaemia caused by *Schistosoma mansoni* infection. *BMJ.* 9 mai 1987;294(6581):1197-1197.

308 33. El Mallah SH, Hashem M. Localized Bilharzial Granuloma of the Lung Simulating a Tumour. *Thorax.* 1 juin 1953;8(2):148-51.

309 34. Besson A, Stahel E, Anani P, Djevahirdjian L, Leimgruber A, Cavallo-Serra RJ, et al. [Multifocal pulmonary bilharzioma due to *Schistosoma mansoni*].
310 *Schweiz Med Wochenschr.* 27 mars 1982;112(13):454-7.

311 35. Grunstein P, Broquie G, Gayet AM, Bazelly B, Fouret P. [Pulmonary bilharziasis due to *Schistosoma mansoni* simulating Carrington's disease]. *Rev*
312 *Pneumol Clin.* 1988;44(1):36-8.

313 36. Al-Fawaz IM, Al-Rasheed SA, Al-Majed SA, Ashour M. Schistosomiasis associated with a mediastinal mass: case report and review of the literature.
314 *Annals of Tropical Paediatrics.* janv 1990;10(3):293-7.

315 37. Fatureto MC, Correia D, Silva MB de O, Barra MFC, Silva AV da, Tarquinio DC, et al. Nódulo pulmonar esquistossomótico simulando neoplasia: relato
316 de caso. *Rev Soc Bras Med Trop.* déc 2003;36(6):735-7.

317 38. N'Dong FO, Mbamendame S, Assapi MN, Mbourou JB, Roy E, Kombila M, et al. [Pulmonary bilharziosis due to *Schistosoma haematobium*: pitfalls of
318 species diagnosis. A case report from Libreville, Gabon]. *Med Trop (Mars).* 2005;65(2):163-6.

319 39. Rodrigues GC, Lacerda DC, Gusmão E da S, Colares FA, Mota VT. Forma pseudoneoplásica de esquistossomose pulmonar crônica sem hipertensão
320 pulmonar. *J bras pneumol.* mai 2009;35(5):484-8.

321 40. de Górgolas M, Casado V, Renedo G, Alen JF, Fernández Guerrero ML. Nodular lung schistosomal lesions after chemotherapy for dysgerminoma.
322 *Am J Trop Med Hyg.* sept 2009;81(3):424-7.

323 41. Oliveira CD de, Nangino G de O, Correia PC, Salomão CV, Resende MA, Peixoto L da C, et al. Tumoral pulmonary mass secondary to *Schistosoma*
324 *mansoni* infection resembling neoplasia: case report. *Rev Bras Ter Intensiva.* déc 2009;21(4):461-4.

- 325 42. Tang THC, Wong SSY, Lam W, Cheuk W, Lai CKC, Wu TC. A 93-Year-Old Man With a Left Lung Mass and Exudative Pleural Effusion. *Clinical Infectious*
326 *Diseases*. 15 janv 2014;58(2):300-1.
- 327 43. Chaudhry IU, Manah W, Alghamdi M, Mutairi H. A rare cause of asymptomatic solitary pulmonary nodule: adult *Schistosoma* worm. *Case Reports*.
328 10 mars 2014;2014(mar10 1):bcr2013202840-bcr2013202840.
- 329