



**HAL**  
open science

# Schistosoma haematobium infection with pulmonary involvement in a traveller returning from Congo: A case report and systematic review of literature on nodular pulmonary schistosomiasis

Coline Mortier, Camille Aubry, Coralie L'Ollivier, Philippe Gautret,  
Jean-Christophe Lagier, Philippe Parola

## ► To cite this version:

Coline Mortier, Camille Aubry, Coralie L'Ollivier, Philippe Gautret, Jean-Christophe Lagier, et al.. Schistosoma haematobium infection with pulmonary involvement in a traveller returning from Congo: A case report and systematic review of literature on nodular pulmonary schistosomiasis. Travel Medicine and Infectious Disease, 2021, 44, pp.102182. 10.1016/j.tmaid.2021.102182 . hal-03636860

**HAL Id: hal-03636860**

**<https://amu.hal.science/hal-03636860>**

Submitted on 5 Jan 2024

**HAL** is a multi-disciplinary open access archive for the deposit and dissemination of scientific research documents, whether they are published or not. The documents may come from teaching and research institutions in France or abroad, or from public or private research centers.

L'archive ouverte pluridisciplinaire **HAL**, est destinée au dépôt et à la diffusion de documents scientifiques de niveau recherche, publiés ou non, émanant des établissements d'enseignement et de recherche français ou étrangers, des laboratoires publics ou privés.



Distributed under a Creative Commons Attribution - NonCommercial 4.0 International License

1 ***Schistosoma haematobium* infection with pulmonary involvement in a traveller returning**  
2 **from Congo: a case report and systematic review of literature on nodular pulmonary**  
3 **schistosomiasis**

4  
5 Coline Mortier<sup>1</sup>, Camille Aubry<sup>1</sup>, Coralie L'Ollivier<sup>1</sup>, Philippe Gautret<sup>1</sup>, Jean-Christophe  
6 Lagier<sup>1,3</sup>, Philippe Parola<sup>1,2</sup>

7  
8  
9  
10  
11  
12  
13 <sup>1</sup> IHU-Méditerranée Infection, Marseille, France.

14 <sup>2</sup> Aix Marseille Univ, IRD, AP-HM, SSA, VITROME, Marseille, France.

15 <sup>3</sup> Aix Marseille Univ, IRD, AP-HM, MEPHI, Marseille, France.

16

17

18 \* **Corresponding author:** Prof. Philippe Parola. VITROME, Institut Hospitalo-Universitaire  
19 Méditerranée Infection, 19-21 Boulevard Jean Moulin 13385 Marseille Cedex 05, France

20 Phone: +33 (0) 4 13 73 24 01. Fax: + 33 (0) 4 13 73 24 02

21 Email:

22

23

24 **Keywords:** travellers, pulmonary schistosomiasis, *schistosoma haematobium*, schistosomiasis  
25 and thrombosis, nodular pulmonary schistosomiasis

26 **Abstract**

27

28 **Background.** Schistosomiasis is highly prevalent in sub-Saharan Africa and diagnosis is  
29 difficult for travel medicine practitioners, because it can affect different organs with atypical  
30 manifestations. *S. haematobium* is mostly associated with urinary involvement and rarely with  
31 pulmonary lesions. This review aims to summarise the pulmonary forms associated with  
32 schistosomiasis, especially with *S. haematobium*.

33 **Method.** Based on a case report of both pulmonary and urogenital schistosomiasis, we  
34 performed a systematic literature review of schistosomiasis occurring in migrants and  
35 travellers, with a specific focus on pulmonary schistosomiasis.

36 **Results.** Pulmonary schistosomiasis can present two different clinical patterns. On the one  
37 hand, there is an acute pattern, which more frequently affects non-immune young travellers  
38 within three to eight weeks of their return and, on the other hand, there is a chronic pattern,  
39 which has been evolving in recent years and which mostly affects people living in endemic  
40 areas or migrating from these countries. Nodular pulmonary lesions are described in both  
41 patterns. Genus identification should not focus only on known patterns, and identification of  
42 *S. haematobium* should not be associated exclusively with urinary schistosomiasis.

43 **Conclusions.** Pulmonary schistosomiasis, even when resulting from *S. haematobium*, is a  
44 rare but existing infection that appears to be spreading with increasing travel and global  
45 migration. Physicians need to be more aware of non-specific symptoms that may reveal an  
46 atypical presentation of a tropical disease, in order to avoid the chronic complications which  
47 can result from parasitic diseases.

48

49

## 50 **Introduction**

51 Schistosomiasis is one of the most prevalent parasitic diseases in the world and is a  
52 threat to human health (1) (2) . It affects more than 200 million people in the world and  
53 transmission has been reported in 78 countries according to the WHO. The main endemic area  
54 remains Africa, where there is a mean prevalence of 37.3% and where the prevalence in some  
55 areas can reach 60% (measured using parasitological diagnostic tests) (2). The main focal  
56 point is in sub-Saharan countries where schistosomiasis has been neglected for many years.  
57 Lake Malawi in eastern Africa is the area with the highest prevalence of symptomatic  
58 patients, where rates can reach up to 94.9% in some communities (based on parasitological  
59 tests on symptomatic people) (3). Asia and South America are endemic areas with a lower  
60 parasitic prevalence (4).

61 Schistosomiasis is also an issue which affects travellers and migrants (5). One  
62 systematic Canadian review established that schistosomiasis seroprevalence was the highest  
63 in migrants originating from countries in sub-Saharan Africa. It found that seroprevalence was  
64 24.1% in sub-Saharan migrants arriving in host countries where schistosomiasis is not  
65 endemic (USA, Canada, Australia, New Zealand, Israel and 23 western European countries),  
66 in comparison with a pooled seroprevalence of 18.4% in these same countries (6). Among  
67 travellers, the GeoSentinel network reported 410 cases of travel-associated schistosomiasis  
68 over a decade (1997 to 2008), with a total of 83% cases acquired in Africa (5) (7), when  
69 individuals born in endemic areas were excluded. Schistosomiasis was shown to be one of the  
70 ten leading causes of morbidity among returning travellers, accounting for 2% of ill travellers  
71 returning from sub-Saharan Africa (7). Schistosomiasis is endemic in certain provinces of the  
72 Democratic Republic of the Congo (DRC) and is spreading to formerly non-endemic regions  
73 (8). Three species of *Schistosoma* have been found in the DRC: *S. mansoni*, *S. haematobium*

74 and *S. intercalatum*. The prevalence of confirmed schistosomiasis varied between regions and  
75 between villages, with high values of up to 95% observed in some communities (8).

76 The prevalence of schistosomiasis varies according to the distribution of freshwater  
77 snails, the intermediate hosts, and to the different behavioural patterns of human activities in  
78 different areas. The clinical spectrum of schistosomiasis varies widely in humans (1), but the  
79 most frequent clinical presentations are urogenital schistosomiasis (*S. haematobium*, which is  
80 endemic in Africa, the Middle East and, more recently, Corsica in France (9) (10)), intestinal  
81 schistosomiasis (*S. mansoni*, which is endemic in Africa, the Middle East, Brazil, Venezuela,  
82 and the Caribbean), and the intestinal and hepatosplenic forms (*S. japonicum*, which is  
83 endemic only in China, the Philippines and Indonesia (4) (11)).

84 Individuals who have contracted schistosomiasis may remain asymptomatic or may  
85 present with non-specific complaints. Several complications can appear at a later stage and  
86 can include severe organic lesions and even cancer. For *S. haematobium*, the most severe  
87 complication is bladder cancer following urinary schistosomiasis. Pulmonary lesions due to  
88 schistosomiasis are described less often, and genus identification for *S. haematobium* has only  
89 been related to pulmonary symptoms in acute pulmonary patterns.

90 In this study, we report a case of schistosomiasis due to *S. haematobium*, occurring in  
91 a French traveller returning from DRC, presenting a spontaneous thrombosis leading to the  
92 diagnosis of both pulmonary and bladder schistosomal lesions. The specificity of our case  
93 report is that *S. haematobium* eggs were found on the bladder biopsy, and at the same time  
94 PCR (targeting the *Dra1* gene (12)) was positive on the lung biopsy. This contrasts with other  
95 situations where genus identification is rare and is almost never positive for *S. haematobium*  
96 in lung biopsies. In addition, nodular pulmonary lesions were reported as appearing in this  
97 non-immune traveller one year after exposure, in contrast to the usual time of a few weeks  
98 between first exposure and the development of pulmonary lesions.

## 100 **Material and results**

101           We present a case report highlighting an atypical pattern of schistosomiasis.  
102 We performed a systematic review of the medical literature relating to nodular pulmonary  
103 lesions and schistosomiasis, with a focus on *S. haematobium*. Articles were identified through  
104 a literature search using the PubMed database (until December 2020), in accordance with the  
105 Preferred Reporting Items for Systematic Reviews and Meta-Analyses (PRISMA) guidelines.  
106 We searched all articles listed in PubMed and indexed for Medline, using the combination of  
107 terms “nodular pulmonary schistosomiasis”, “*Schistosoma haematobium*” and “pulmonary”,  
108 and “pulmonary” and “bladder schistosomiasis”. The selection of articles is presented in  
109 Figure 1.

110 Only publications of nodular pulmonary cases or reviews of these cases were included, and  
111 genus identification was not a criteria for exclusion. Articles which were written in neither  
112 English nor Spanish were excluded. We included 24 publications reporting on 43 published  
113 case reports, which we classified into acute and chronic pulmonary disease.

114           A systematic review of the association between schistosomiasis and thrombosis was  
115 also performed using the PubMed database and the keywords “hypercoagulability”,  
116 “schistosomiasis” and “thrombosis”.

117

## 118 **Case report**

119           A 63-year-old male French traveller, with no significant medical history, who had  
120 stopped smoking 35 years previously, was diagnosed in August 2017 with a spontaneous deep  
121 vein thrombosis in his right leg. Computerised tomographic scans of his chest (CT-scan),  
122 abdomen and pelvis were performed to detect malignancies. Three pulmonary nodules were  
123 found, ranging in size from 5 to 10 mm (Figure 2). In addition, the CT-scan found a

124 thickening of the bladder anterior wall. Suspecting a malignancy, a transurethral resection of  
125 the bladder tumour was performed. Subsequently, a right middle lobe wedge resection was  
126 performed. In the histopathology department, a cystic wall examination revealed a  
127 granulomatous inflammation with epithelioid macrophages, giant cells and numerous  
128 *Schistosoma* spp. eggs with no malignancy (Figures 3 and 4) (12). The pulmonary nodule  
129 histopathology analysis showed non-caseating granulomatous lesions and the PCR was  
130 positive (targeting Dra1 gene (12)) for *S. haematobium* on the pulmonary biopsy.

131           When interviewed, the patient reported having taken one month off work every year  
132 for ten years, which he spent in DRC, in central Africa. His last trip was a year ago. During  
133 his travels, he reported walking in rivers and stagnant water (exposed to a slow-flowing river).  
134 The results of his clinical examinations were normal. Laboratory tests revealed leucocytosis  
135 ( $6 \times 10^9/l$ : normal range  $4-10 \times 10^9/l$ ) without eosinophilia ( $0.37 \times 10^9/l$ : normal range  $0.1-0.7 \times 10^9/l$ ).  
136 The C-reactive protein (CRP), liver enzymes and electrolytes were within normal  
137 ranges. The total IgE was elevated ( $265 \text{ kUI/L}$ : normal range  $1-100 \text{ kUI/L}$ ). Serology (ELISA,  
138 Novagnost, NovaTec, Western blot LD-Bio France) for schistosomiasis was positive for total  
139 Ig (ratio 58, positive  $>10$ ) and no eggs were found in his urine or stool samples. The patient  
140 was treated with oral Praziquantel,  $60 \text{ mg/kg/day}$  in one intake, and the same dose was  
141 repeated after two weeks. Two months after treatment, his serology was stable and remained  
142 so over the course of several checks in 2018. Pulmonary nodular lesions remained stable on  
143 several CT chest examinations.

144

145 [Figure 2. Multiple pulmonary nodules caused by schistosomiasis in a patient returning from](#)  
146 [Congo, PET Scan](#)

147 [Figure 3. Granulomatous lesion and \*S.haematobium\* eggs in a pulmonary biopsy \(image with](#)  
148 [100x magnification, hematoxylin-eosin stain\)](#)



149 Figure 4. *S.haematobium* eggs in a pulmonary biopsy (image with 500x magnification,  
150 hematoxylin-eosin stain)

151

## 152 **Systematic review**

### 153 *Schistosomiasis and pulmonary nodular lesions*

154 Two different patterns are described in the literature with regard to pulmonary lesions  
155 in schistosomiasis infections (13)(14). The first exposure to *Schistosoma* spp. may create an  
156 immunological reaction around three to eight weeks after exposure. One common feature of  
157 the so-called Katayama syndrome may be a dry cough with, usually, normal imaging,  
158 although some nodular, non-specific lesions may sometimes be seen. We found 31 published  
159 case reports that reported nodular lesions on CT in this context. (Table 1). The clinical  
160 symptoms were mostly a dry cough and fever. The mean age was 25.3 years old (14–50), and  
161 a predominance for males was observed (67%, 20M, 10F). All but one of the cases were in  
162 travellers returning from Africa (one case was in a traveller returning from Saudi Arabia),  
163 where *S. mansoni* and *S. haematobium* are endemic, although the genus was not always  
164 identified. The diagnosis was reached using positive serology, but the PCR was almost never  
165 positive at this early stage. Associated indicative biological features were eosinophilia,  
166 elevated IgE, and hepatic cytolysis (15)(16)(17)(18)(19)(20)(21)(22)(23)(24)(25)(26).  
167 Recently, one bifocal case with bladder and pulmonary involvement due to *S. haematobium*  
168 was reported in the UK in a traveller who had recently returned from Ghana (26).

169 In contrast, chronic schistosomiasis has been described as affecting people living in  
170 endemic areas who are permanently exposed to the parasite. It has also been described in  
171 migrants arriving in non-endemic host countries (27)(28). The mean age of these migrants  
172 was 22.3 years (18–28). Such a pattern is more common and causes fibrosis and granuloma  
173 due to inflammation. Chronic pulmonary schistosomiasis appears many years after exposure,

174 and can lead to irreversible lesions (13)(22). We found 12 published case reports describing  
175 pulmonary nodules associated with chronic schistosomiasis, but this pattern is likely to be  
176 under-reported in the literature (Table 2). Genus identification was more frequently available  
177 in these reports, and *S. mansoni* infections were the most likely to be documented. No *S.*  
178 *haematobium* eggs were found in lung biopsies in these patients. The clinical features were  
179 non-specific, including dyspnoea, chest pain, asthenia, and a cough. More severe  
180 complications associated with these lesions were heart failure, pulmonary arterial  
181 hypertension, and obstructive syndrome, which were not directly due to schistosomiasis.

182

## 183 **Discussion and conclusion**

### 184 *Consequences for clinicians and travellers*

185 Schistosomiasis can be revealed by varied symptoms that can be non-specific and  
186 should be investigated by clinicians whenever they examine travellers or migrants with an  
187 atypical presentation, especially when returning from Africa. Similarly, past exposure to  
188 schistosomiasis in patients presenting with unexplained chronic symptoms should also be  
189 investigated, alongside more recent exposure. During pre-travel consultations, travellers  
190 should be made aware of and provided with advice on this major risk (one which is often  
191 overlooked in comparison with malaria or diarrhoea), as there is no treatment to prevent  
192 schistosomiasis. In recent years, with the rise in eco-tourism and the globalisation of tourism,  
193 an increasing number of travellers returning from endemic areas have contracted  
194 schistosomiasis. The most frequent pattern reported is acute schistosomiasis after recent  
195 exposure, although patients occasionally present with the chronic consequences of an  
196 untreated schistosomiasis infection. Cercarial shedding is mostly diurnal when travellers may  
197 take part in several freshwater activities (3)(1). Contact with infected water can occur while  
198 bathing, swimming, scuba diving, rafting or water skiing, which are frequent tourist activities

199 in such endemic areas. Weather conditions such as rain, wind, water levels and waves in  
200 lakes, temperature and rainfall have a strong influence on intermediate hosts and can therefore  
201 influence the density of infected people and transmission (3). Preventative advice about not  
202 swimming in freshwater lakes should be given rather than promoting rafting or water-based  
203 tourist activities in those endemic areas. Itching and pruritic papules on the skin following  
204 exposure to fresh water should be the first sign alerting to larvae penetration (1).

205 Pulmonary schistosomiasis is a rare and a hard to diagnose disease, as it presents with  
206 very non-specific symptoms and inconclusive results from laboratory testing and imaging  
207 (21)(12). It mimics other infections such as tuberculosis (28). Pulmonary manifestations are  
208 rarely seen with *S. haematobium*. When genus identification is made in pulmonary  
209 schistosomiasis, it is more commonly associated with *S. mansoni*, and represents chronic  
210 patterns with exposure occurring years before any clinical manifestations.

211 Interestingly, our case report begins with a venous thrombosis without any triggering  
212 factor. Thrombotic complications have been associated with other *Schistosoma* spp. (in  
213 *S. mansoni* infection, portal vein thrombosis with a hepatic form (29)(30) and mesenteric  
214 thrombosis with gastro-intestinal schistosomiasis damage (31)(32)). To our knowledge,  
215 however, this is the first case describing thrombosis due to a *S. haematobium* infection.  
216 Several explanations should be explored in the future (chronic inflammatory thrombogenesis  
217 and hypercoagulability with enhanced fibrinolysis has been found in *S. mansoni*-infected mice  
218 (29)), but this case should lead clinicians to recall this aetiology when presented with a  
219 traveller with unexplained deep thrombosis.

220 Schistosomiasis remains a global issue and needs to be more effectively controlled and  
221 prevented. With increasing migration, many travellers are exposed to potentially  
222 contaminated water and should be aware of potential symptoms of infection if we want to  
223 reduce severe manifestations of acute schistosomiasis and prevent complications of chronic

224 disease in the future. Due to the different patterns we described this should encourage travel  
225 medicine clinicians to look for schistosomiasis when treating patients returning from endemic  
226 areas, even if they do not present typical urinary or gastrointestinal symptoms.

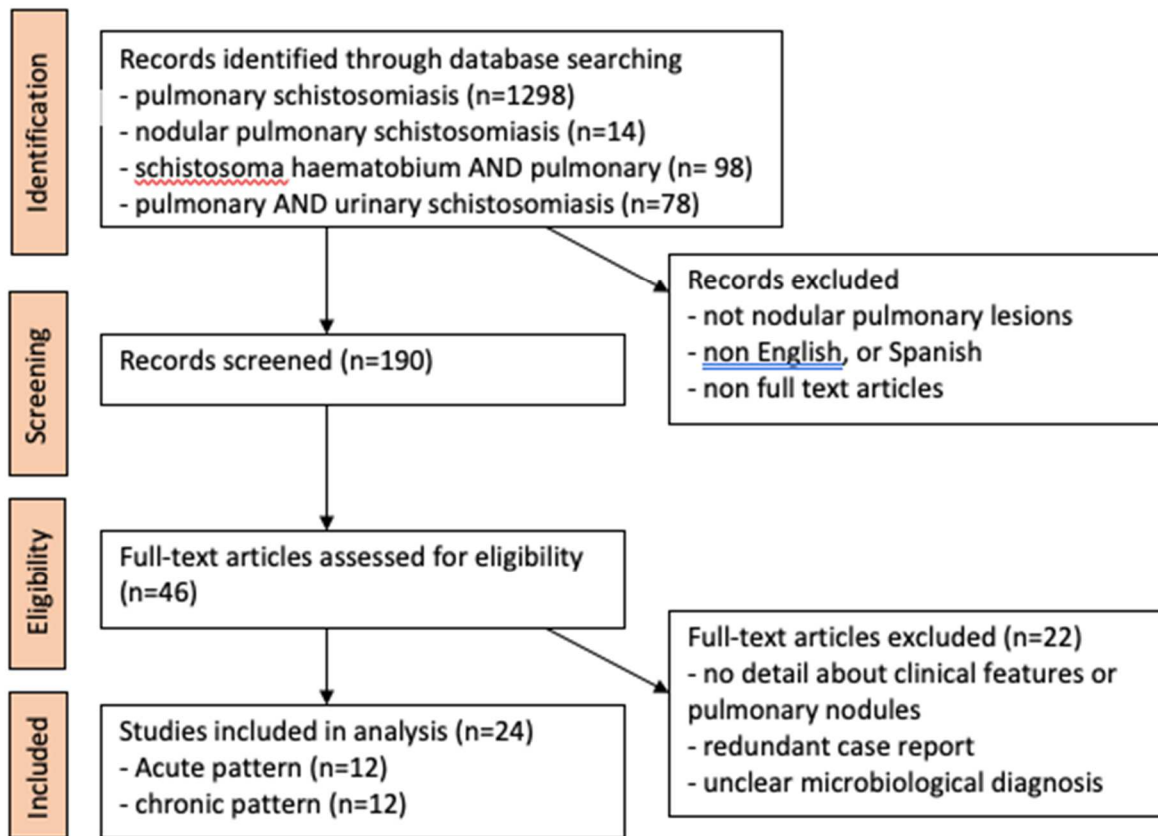
227

228 **Declaration of patient consent: YES**

229 **Conflict of interest: There are no conflicts of interest**

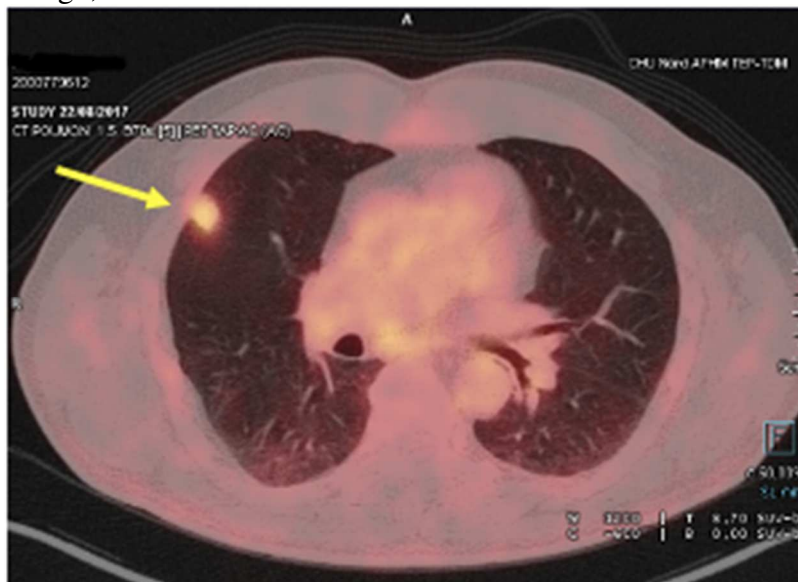
230

231 **Figure 1** PRISMA flow diagram



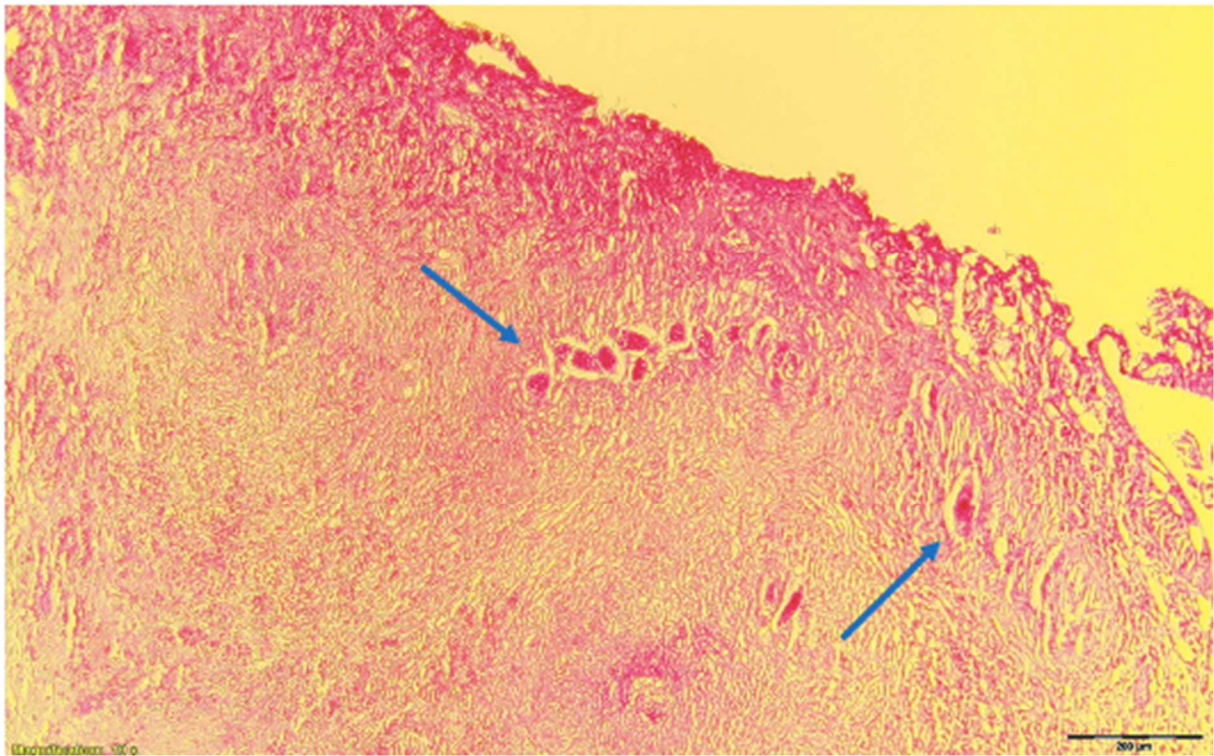
232  
233  
234  
235  
236

**Figure 2.** Multiple pulmonary nodules caused by schistosomiasis in a patient returning from Congo, PET Scan



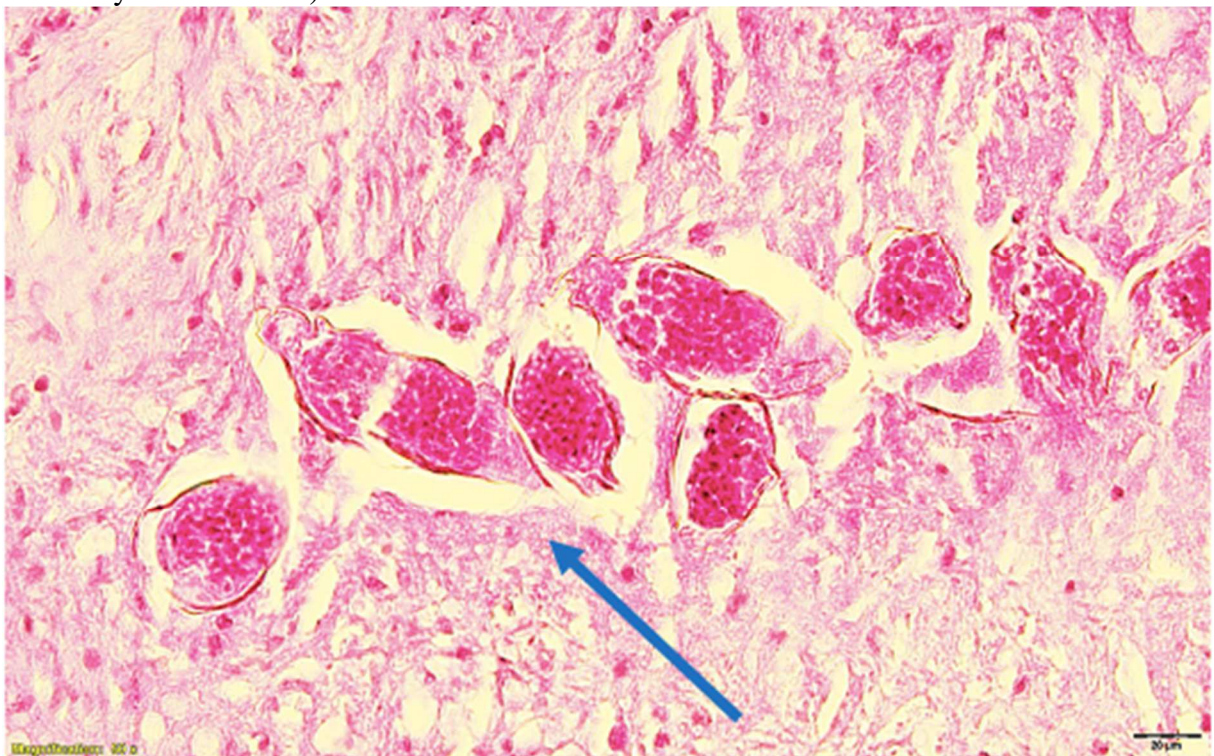
237

238 **Figure 3.** Granulomatous lesion and *S.haematobium* eggs in a bladder biopsy (image with  
239 100x magnification, hematoxylin-eosin stain)



241

242 **Figure 4** *S. haematobium* eggs in a bladder biopsy (image with 500x magnification,  
243 hematoxylin-eosin stain)



244

245 **Table 1 : Acute pattern of pulmonary schistosomiasis: review of pulmonary nodule cases. *S.haematobium* was found in eight cases, all in patients**  
 246 **exposed fewer than eight weeks previously**  
 247  
 248

Area of exposure	Gender, age (year)	Time from exposure (weeks)	Clinical presentation	Eosinophilia in G/L (%)	Genus identification	Year of publication (Reference)
Angola	M, 35	8	Dry cough, night sweats	1.45	<i>S. mansoni</i> positive serology negative urinary detection Biopsy : eosinophils, <i>S. mansoni</i> eggs +	1991 (25)
Lake Malawi	4 cases F, 20 M, 22 F, 20 M, 20	4 3 2 8	- Fever, cough, cutaneous rash - Fever, headache, sweats - Fever, dysuria, rash - Rash, dry cough, pruritus	33 (ND) 2 (ND) 8.4 (ND) 4 (ND)	∅, Positive serology, negative skin and rectal biopsy ∅, positive serology only week 14, negative skin and rectal biopsy ∅, positive serology only week 10, negative stool examination  <i>S. haematobium</i> positive serology week 10 , positive stool	1999 (19)
Malawi S. Africa Malawi Ghana Malawi Malawi Malawi Malawi	M, 24 M, 30 M, 24 M, 44 M, 24 M, 25 F, 24 F, 23	4-5 3-4 3-4 4 3-6 3-4 3-4 4	Pulmonary symptoms (unspecified)	3.65 (39) 2.9 (30) 4.8 (44) 4.2 (34) 5.4 (48) 3.6 (48) 6.2 (36) 1.4 (20)	<i>S. haematobium</i> positive serology, eggs - <i>S. haematobium</i> positive serology, eggs + <i>S. mansoni</i> positive serology, eggs + <i>S. mansoni</i> positive serology, eggs - <i>S. haematobium</i> positive serology, eggs + <i>S. haematobium</i> positive serology, eggs + <i>S. haematobium</i> positive serology, eggs - <i>S. haematobium</i> positive serology, eggs +	2000 (24)
East Africa and Lake Malawi (Nkbata Bay)	M, 25	6	Cough, loss of 10 Kg	ND	∅ <b>Positive serology (I 32)</b> negative urinary detection	2002 (18)
Tanzania	10 cases M, 19 M, 23 F, 20	8	Dry cough, shortness of breath Dry cough None	6 (42) 2.3 (44) 1 (18)	<i>S. mansoni</i> (Serology and immunoblot)*  <i>S. mansoni</i> (Serology and immunoblot)*	2006 (17)

	F, 19 F, 19  M, 50  M, 19 F, 22 F, 20 F, 47		Mild dry cough Mild dry cough Intermittent, mild shortness of breath Mild dry cough None None None	1.5 (24) 6.7 2.0 (13) 3.9 (35) 0.4 0.6 (5) 0.4 (35)	<i>S. mansoni</i> (Serology and immunoblot)*  <i>S. mansoni</i> (Serology and immunoblot)*  <i>S. mansoni</i> (Serology and immunoblot)*  <i>S. mansoni</i> (Serology and immunoblot)*  <i>S. mansoni</i> (Serology and immunoblot)*  <i>S. mansoni</i> (Serology and immunoblot)*  <i>S. mansoni</i> (Serology and immunoblot)*	
Central Africa	M, 28	2,5	Dry cough, night sweats, fever	6.9 (57)	NR	2010 (21)
Saudi Arabia	M, 14	5	Fever, cough, discomfort	2.43 (30)	∅ video-assisted thoracoscopic lung biopsy: Schistosomal ovum <b>positive serology (genus NR)</b> Negative stool sample, BAL fluid analysis: eosinophils (7%), negative culture	2011 (16)
Madagascar	M, 30	4	Fever, myalgia, cough	3.58 (43)	positive <i>S. mansoni</i> FAST-ELISA test negative <i>S. mansoni</i> immunoblot	2012 (20)
Nile valley	M, 24	7	Cough, discomfort, diarrhoea, cutaneous rash with papules	3	Positive serology, eggs -	2016 (15)
Benign	M, 21	8	Fever, cough, chest pain	1.3	∅ Pulmonary biopsy: schistosoma eggs <i>S. haematobium</i> suspected but no confirmation	2016 (22)
Yemen	M, 23	1	Cough, haemoptysis, chest pain	ND (elevated WBC 13 with eosinophil predominant)	thoracoscopy and excision of abscess: <i>S. mansoni</i> eggs BAL: negative	2018 (23)



Ghana	M, 25	“recent”	Chronic cough, wheezing	ND	<i>S. haematobium</i> found in bladder biopsy	2019 (26)
-------	-------	----------	-------------------------	----	---	-----------

249

250

251 **Table 2 : Chronic pattern of pulmonary schistosomiasis: review of pulmonary nodule cases.**

252

Area of exposure	Gender, age (year)	Time from exposure (years)	Clinical features and pulmonary lesions (size in mm)	Eosinophila in G/L (%)	Genus identification	Year of publication (Reference)
Mali Guinea Ivory Coast Senegal Mali Mali Nigeria	7 cases M, 27 M, 25 M, 28 M, 19 M, 21 M, 18 M, 18	5 1 1 5 1 1 1	multiple nodules	0,75 (13,9) 0,44 (9,6) 0,79 (12,9) 2,04 (31) 2,29 (36,4) 1,96 (22) 0,4 (6,6)	<i>S. mansoni</i> eggs in lung biopsy and stool <i>Schistosoma</i> spp eggs in lung biopsy <i>Schistosoma</i> spp eggs in lung biopsy, <i>S haematobium</i> eggs in urine, <i>S. mansoni</i> eggs in stool <i>Schistosoma</i> spp eggs in lung biopsy, <i>S haematobium</i> eggs in urine <i>Schistosoma</i> spp eggs in lung biopsy, <i>S haematobium</i> eggs in urine no lung biopsy, <i>S haematobium</i> eggs in urine, <i>S. mansoni</i> eggs in stool no lung biopsy, <i>S haematobium</i> eggs in urine	2017 (28)
Egypt	M, 47	Living in area	Pulmonary mass (60mm)	1 (12)	<i>Schistosoma</i> spp eggs in lung biopsy (surgical resection)	1953 (33)
Cameroon	F, NR	Living in area	Chest pain Abscess in the left lung	1	<i>S.mansoni</i> eggs in lobectomy, <i>S haematobium</i> eggs in stool	1982 (34)
Martinique	F, NR	Living in area		NR	<i>S. mansoni</i> in lung biopsy, stool was negative	1988 (35)
Saudi Arabia	F, 13	Living in area	Fever, sweat, weight loss, haematuria Pulmonary lymph node and left pulmonary nodule	NR	<i>Schistosoma</i> spp eggs in lung biopsy	1990 (36)
Brazil	F, 33	Living in	Nodule in right lobe of the	NR	<i>S. mansoni</i> eggs in lung biopsy	2003 (37)

		area	lung			
Gabon	F, 47	Living in area	Fever, chest pain, pneumonia, haemoptysis	NR	<i>Schistosoma</i> spp eggs in lung biopsy	2005 (38)
Brazil	M, NR	Living in area	Dry cough, weight loss, chest pain Pulmonary mass in left lobe	NR	<i>S. mansoni</i> eggs in lung biopsy	2009 (39)
Mali	F, NR	1,3	Pulmonary nodule	1,5	Serology <i>Schistosoma</i> spp positive	2009 (40)
Brazil	M, 25	Living in area	Pulmonary mass Died after surgery	NR	<i>Schistosoma mansoni</i> eggs in lung biopsy	2009 (41)
China	M, 93	Living in area	Lung mass	NR	<i>Schistosoma japonicum</i> eggs in aspiration of the lung mass	2014 (42)
Saudi Arabia	M, 60	26	Asymptomatic solitary pulmonary nodule 20 mm	NR	<i>Schistosoma</i> spp eggs in lung biopsy	2014 (43)

253

254

255 **REFERENCES**

- 256 1. Gryseels B, Polman K, Clerinx J, Kestens L. Human schistosomiasis. *The Lancet*. sept 2006;368(9541):1106-1118.
- 257 2. Schur N, Vounatsou P, Utzinger J. Determining Treatment Needs at Different Spatial Scales Using Geostatistical Model-Based Risk Estimates of  
258 Schistosomiasis. *Brooker S, éditeur. PLoS Negl Trop Dis*. 13 sept 2012;6(9):e1773.
- 259 3. Makaula P, Sadalaki JR, Muula AS, Kayuni S, Jemu S, Bloch P. Schistosomiasis in Malawi: a systematic review. *Parasites Vectors*. déc 2014;7(1):570.
- 260 4. Chen Y-Y, Liu J-B, Jiang Y, Li G, Shan X-W, Zhang J, et al. Dynamics of spatiotemporal distribution of schistosomiasis in Hubei Province, China. *Acta  
261 Tropica*. avr 2018;180:88-96.
- 262 5. Schwartz E, von Sonnenburg F, Reed C, Weld LH, Nicolls DJ, Kozarsky PE, et al. Characteristics of Schistosomiasis in Travelers Reported to the  
263 GeoSentinel Surveillance Network 1997–2008. *The American Journal of Tropical Medicine and Hygiene*. 1 nov 2008;79(5):729-734.
- 264 6. Asundi A, Beliavsky A, Liu XJ, Akaberi A, Schwarzer G, Bisoffi Z, et al. Prevalence of strongyloidiasis and schistosomiasis among migrants: a systematic  
265 review and meta-analysis. *The Lancet Global Health*. févr 2019;7(2):e236-248.
- 266 7. Cetron MS, Chitsulo L, Sullivan JJ, Pilcher J, Wilson M, Noh J, et al. Schistosomiasis in Lake Malawi. *The Lancet*. nov 1996;348(9037):1274-1278.
- 267 8. Madinga J, Linsuke S, Mpabanzi L, Meurs L, Kanobana K, Speybroeck N, et al. Schistosomiasis in the Democratic Republic of Congo: a literature  
268 review. *Parasites Vectors*. déc 2015;8(1):601.
- 269 9. Gautret P, Mockenhaupt FP, von Sonnenburg F, Rothe C, Libman M, Van De Winkel K, et al. Local and International Implications of Schistosomiasis  
270 Acquired in Corsica, France. *Emerg Infect Dis*. oct 2015;21(10):1865-1868.
- 271 10. Beltrame A, Zammarchi L, Zuglian G, Gobbi F, Angheben A, Marchese V, et al. Schistosomiasis Screening of Travelers from Italy with Possible  
272 Exposure in Corsica, France. *Emerg Infect Dis*. oct 2015;21(10):1887-1889.
- 273 11. Lei Z, Zhang L, Xu Z, Dang H, Xu J, Lv S, et al. [Endemic status of schistosomiasis in People's Republic of China in 2014]. *Zhongguo Xue Xi Chong Bing  
274 Fang Zhi Za Zhi*. déc 2015;27(6):563-569.
- 275 12. Cnops L, Soentjens P, Clerinx J, Van Esbroeck M. A *Schistosoma haematobium*-Specific Real-Time PCR for Diagnosis of Urogenital Schistosomiasis in  
276 Serum Samples of International Travelers and Migrants. *Lammie PJ, éditeur. PLoS Negl Trop Dis*. 29 août 2013;7(8):e2413.
- 277 13. Schwartz E. Pulmonary schistosomiasis. *Clinics in Chest Medicine*. juin 2002;23(2):433-443.

- 278 14. Sami A-A. Pulmonary Manifestations of Schistosomiasis. *Diseases of the Chest*. juin 1951;19(6):698-705.
- 279 15. Puylaert CAJ, van Thiel P-P. Katayama Fever. *N Engl J Med*. 4 févr 2016;374(5):469-469.
- 280 16. Al-Jahdali H, Bamefleh H, Elkeir A, Yamani N, Baharoon S. Acute pulmonary schistosomiasis. *J Global Infect Dis*. 2011;3(3):303.
- 281 17. Nguyen L-Q, Estrella J, Jett EA, Grunvald EL, Nicholson L, Levin DL. Acute Schistosomiasis in Nonimmune Travelers: Chest CT Findings in 10 Patients.  
282 *American Journal of Roentgenology*. mai 2006;186(5):1300-3.
- 283 18. Salanitri J, Stanley P, Hennessy O. Acute pulmonary schistosomiasis. *Australas Radiol*. déc 2002;46(4):435-7.
- 284 19. Cooke GS, Lalvani A, Gleeson FV, Conlon CP. Acute Pulmonary Schistosomiasis in Travelers Returning from Lake Malawi, Sub-Saharan Africa. *CLIN  
285 INFECT DIS*. oct 1999;29(4):836-9.
- 286 20. Pavlin BI, Kozarsky P, Cetron MS. Acute pulmonary schistosomiasis in travelers: Case report and review of the literature. *Travel Medicine and  
287 Infectious Disease*. sept 2012;10(5-6):209-19.
- 288 21. Niemann T, Marti HP, Duhnsen SH, Bongartz G. Pulmonary Schistosomiasis – Imaging Features. *Radiology Case*. 10 sept 2010;4(9):37-43.
- 289 22. Coron N, Chabasse D, Kettani S, Le Govic Y, Hemery S, Pihet M, et al. Early Detection of Schistosoma Egg–Induced Pulmonary Granulomas in a  
290 Returning Traveler. *The American Journal of Tropical Medicine and Hygiene*. 2 mars 2016;94(3):611-4.
- 291 23. Hajjar W, Alsheikh A, Alhumaid A, Alkreedees N, Abdulwahed N, Hajjar A. Pulmonary schistosomiasis in a young male: A case report and review of  
292 the literature. *Ann Thorac Med*. 2018;13(3):190.
- 293 24. Schwartz E, Rozenman J, Perelman M. Pulmonary manifestations of early schistosome infection among nonimmune travelers. *The American Journal  
294 of Medicine*. déc 2000;109(9):718-22.
- 295 25. Schaberg T, Rahn W, Racz P, Lode H. Pulmonary schistosomiasis resembling acute pulmonary tuberculosis. *Eur Respir J*. sept 1991;4(8):1023-6.
- 296 26. Massie J, Howling S. *Schistosoma haematobium* causing pulmonary schistosomiasis in a returning traveller. *BMJ Case Rep*. mars 2019;12(3):e227347.
- 297 27. Gobbi F, Martelli G, Attard L, Buonfrate D, Angheben A, Marchese V, et al. Schistosoma mansoni Eggs in Spleen and Lungs, Mimicking Other  
298 Diseases. Zhou X-N, éditeur. *PLoS Negl Trop Dis*. 23 juill 2015;9(7):e0003860.
- 299 28. Gobbi F, Buonfrate D, Angheben A, Beltrame A, Bassetti M, Bertolaccini L, et al. Pulmonary nodules in African migrants caused by chronic  
300 schistosomiasis. *The Lancet Infectious Diseases*. mai 2017;17(5):e159-65.

- 301 29. Lambertucci JR, Resende V, Voietá I. Portal vein thrombosis in a patient with hepatosplenic schistosomiasis mansoni. *Rev Soc Bras Med Trop.* avr  
302 2009;42(2):235-6.
- 303 30. Olveda DU, Olveda RM, Montes CJ, Chy D, Abellera JMB, Cuajunco D, et al. Clinical management of advanced schistosomiasis: a case of portal vein  
304 thrombosis-induced splenomegaly requiring surgery. *Case Reports.* 17 juin 2014;2014(jun17 1):bcr2014203897-bcr2014203897.
- 305 31. Mosli MH, Chan WW, Morava-Protzner I, Kuhn SM. Schistosomiasis Presenting as a Case of Acute Appendicitis with Chronic Mesenteric Thrombosis.  
306 *Canadian Journal of Infectious Diseases and Medical Microbiology.* 2016;2016:1-3.
- 307 32. Anayi S, Al-Nasiri N. Acute mesenteric ischaemia caused by *Schistosoma mansoni* infection. *BMJ.* 9 mai 1987;294(6581):1197-1197.
- 308 33. El Mallah SH, Hashem M. Localized Bilharzial Granuloma of the Lung Simulating a Tumour. *Thorax.* 1 juin 1953;8(2):148-51.
- 309 34. Besson A, Stahel E, Anani P, Djevahirdjian L, Leimgruber A, Cavallo-Serra RJ, et al. [Multifocal pulmonary bilharzioma due to *Schistosoma mansoni*].  
310 *Schweiz Med Wochenschr.* 27 mars 1982;112(13):454-7.
- 311 35. Grunstein P, Broquie G, Gayet AM, Bazelly B, Fouret P. [Pulmonary bilharziasis due to *Schistosoma mansoni* simulating Carrington's disease]. *Rev*  
312 *Pneumol Clin.* 1988;44(1):36-8.
- 313 36. Al-Fawaz IM, Al-Rasheed SA, Al-Majed SA, Ashour M. Schistosomiasis associated with a mediastinal mass: case report and review of the literature.  
314 *Annals of Tropical Paediatrics.* janv 1990;10(3):293-7.
- 315 37. Fatureto MC, Correia D, Silva MB de O, Barra MFC, Silva AV da, Tarquinio DC, et al. Nódulo pulmonar esquistossomótico simulando neoplasia: relato  
316 de caso. *Rev Soc Bras Med Trop.* déc 2003;36(6):735-7.
- 317 38. N'Dong FO, Mbamendame S, Assapi MN, Mbourou JB, Roy E, Kombila M, et al. [Pulmonary bilharziosis due to *Schistosoma haematobium*: pitfalls of  
318 species diagnosis. A case report from Libreville, Gabon]. *Med Trop (Mars).* 2005;65(2):163-6.
- 319 39. Rodrigues GC, Lacerda DC, Gusmão E da S, Colares FA, Mota VT. Forma pseudoneoplásica de esquistossomose pulmonar crônica sem hipertensão  
320 pulmonar. *J bras pneumol.* mai 2009;35(5):484-8.
- 321 40. de Górgolas M, Casado V, Renedo G, Alen JF, Fernández Guerrero ML. Nodular lung schistosomal lesions after chemotherapy for dysgerminoma.  
322 *Am J Trop Med Hyg.* sept 2009;81(3):424-7.
- 323 41. Oliveira CD de, Nangino G de O, Correia PC, Salomão CV, Resende MA, Peixoto L da C, et al. Tumoral pulmonary mass secondary to *Schistosoma*  
324 *mansoni* infection resembling neoplasia: case report. *Rev Bras Ter Intensiva.* déc 2009;21(4):461-4.

- 325 42. Tang THC, Wong SSY, Lam W, Cheuk W, Lai CKC, Wu TC. A 93-Year-Old Man With a Left Lung Mass and Exudative Pleural Effusion. *Clinical Infectious*  
326 *Diseases*. 15 janv 2014;58(2):300-1.
- 327 43. Chaudhry IU, Manah W, Alghamdi M, Mutairi H. A rare cause of asymptomatic solitary pulmonary nodule: adult *Schistosoma* worm. *Case Reports*.  
328 10 mars 2014;2014(mar10 1):bcr2013202840-bcr2013202840.
- 329