



Detection of methanogens in peri-appendicular abscesses: Report of four cases

K. Djemai, F. Gourié, I. Sielezneff, D. Mege, M. Drancourt, G. Grine

► To cite this version:

K. Djemai, F. Gourié, I. Sielezneff, D. Mege, M. Drancourt, et al.. Detection of methanogens in peri-appendicular abscesses: Report of four cases. *Anaerobe*, 2021, 72, pp.102470. 10.1016/j.anaerobe.2021.102470 . hal-03662575

HAL Id: hal-03662575

<https://amu.hal.science/hal-03662575>

Submitted on 5 Jan 2024

HAL is a multi-disciplinary open access archive for the deposit and dissemination of scientific research documents, whether they are published or not. The documents may come from teaching and research institutions in France or abroad, or from public or private research centers.

L'archive ouverte pluridisciplinaire **HAL**, est destinée au dépôt et à la diffusion de documents scientifiques de niveau recherche, publiés ou non, émanant des établissements d'enseignement et de recherche français ou étrangers, des laboratoires publics ou privés.



Distributed under a Creative Commons Attribution - NonCommercial 4.0 International License

1 **REVISED VERSION**

2 **Detection of methanogens in peri-appendicular abscesses: Report of four cases**

3 Djemai, K.^{1,2}, Gouriet, F.^{1,2}, Sielezneff, I.⁴, Mege, D.⁴, Drancourt, M.^{1,2}, Grine, G.^{2,3*}

4

5 ¹ Aix-Marseille Univ, IRD, MEPHI, Marseille, France.

6 ² IHU Méditerranée Infection, Marseille, France.

7 ³ Aix-Marseille Université, UFR Odontologie, Marseille, France.

8 ⁴ Department of Digestive Surgery, Aix Marseille Univ, APHM, Timone University Hospital,
9 Marseille, France.

10

11 ***Corresponding author:** Ghiles GRINE, PhD

12 IHU Méditerranée Infection, 19-21 Boulevard Jean Moulin, 13005 Marseille, France.

13 Tel: +33 4 13 73 24 01; Fax: +33 4 13 73 24 02.

14 **Email:** grineghiles@gmail.com.

15

16

17 **Word count Abstract = 86**

18 **Word count Text = 2, 283**

19 **Abstract**

20 The etiology of appendicular abscess is predominantly microbial with aerobic and anaerobic
21 bacteria from gut flora origin. In this study, using specific laboratory tools, we co-detected
22 *Methanobrevibacter oralis* and *Methanobrevibacter smithii* among a mixture of
23 enterobacteria including *Escherichia coli*, *Enterococcus faecium* and *Enterococcus avium* in
24 four unrelated cases of postoperative appendiceal abscesses. These unprecedented
25 observations raise a question on the role of methanogens in peri-appendicular abscesses,
26 supporting antibiotics as an alternative therapeutic option for appendicitis, including
27 antibiotics active against methanogens such as metronidazole or fusidic acid.

28 **Keywords:** *Methanobrevibacter smithii*, *Methanobrevibacter oralis*, methanogens, bacteria,
29 appendicular abscesses.

1. Introduction

Methanogens are strictly aero-intolerant archaea with a specific metabolism characterised by the production of methane [1]. They are part of the stable human intestinal microbiota as early as the first weeks of life [2-4]. To date, the most cultured species from the intestinal tract are *Methanobrevibacter smithii*, *Methanobrevibacter stadtmanae* and *Methanomassiliicoccus luminyensis* with respective prevalences of 95%, 30% and 4% [5-7]. Furthermore, methanogens have been associated with gastrointestinal dysbiosis in pathologies such as inflammatory bowel disease (IBD), colorectal cancer and diverticulosis [8-10]. More recently, methanogens have been described as opportunistic pathogens after their co-detection with bacteria in infectious samples such as the blood of febrile patients, as well as in pus samples from musculoskeletal and brain abscesses [11-13]. These studies open a new field in clinical microbiology and contribute to a better knowledge of these microorganisms. Nevertheless, methanogens remain neglected in human infections and it would be interesting to determine their potential role as pathogens in other infectious settings.

Appendicitis is an acute inflammation of the appendix and considered as the most common abdominal surgical emergency [14]. It is classified into two categories: uncomplicated and complicated forms [15]. The complicated appendicitis occurs in 15% and 30% of cases and characterised by the occurrence of intra-abdominal abscesses requiring surgical drainage associated with antibiotic treatment and/or an appendectomy [16, 17].

Moreover, luminal obstruction is a frequent cause of appendicitis and the most isolated microbes in ruptured appendices are *Bacteroides fragilis*, *Escherichia coli*, *Pseudomonas aeruginosa* as well as *Peptostreptococcus* species and *Fusobacterium* species [18]. Additionally, the etiological spectrum of inflamed appendices include fungi, viruses, and parasites [19-24]. Since methanogens are ubiquitous in the gut microbiota, they could also

play an unsuspected role in the pathogenesis of appendicitis. To our knowledge, no studies have been conducted on the possible implication of methanogens in this pathological situation.

Here, we used methanogen-targeted methods, including molecular and microscopic methods to investigate the presence of methanogens in four cases of appendicular abscesses.

2. Material and methods

2.1. Sample collection

As a part of the routine analyses of the diagnostic laboratory of IHU Méditerranée Infection, four drained appendicular abscess samples were directly inoculated into anaerobic blood culture bottles (BacT/ALERT FN Plus, bioMérieux, Lyon, France) and incubated inside the BACT/ALERT VIRTUO apparatus (bioMérieux) for bacterial growth monitoring. These four samples were subsequently investigated **retrospectively** for the presence of methanogens as a part of a study aiming at investigating the occurrence of methanogens in infectious samples. This work was approved by the IHU Méditerranée Infection Ethics Committee (No. 2021-010) and no sample were taken specifically for this study.

2.2. Methanogen detection

2.2.1. PCR based detection

Total DNA was extracted using the automat extractor EZ1 advanced XL with EZ1 DNA Tissue kit (Qiagen, Courtaboeuf, France), after sonication for 20 minutes with the Branson 2510 ultrasound sonicator (Branson, Rungis, France) as previously described [13]. These samples were then screened using standard polymerase-chain-reaction (PCR) targeting 16S rRNA **archaeal** gene with the primers SDArch0333aS15 (5'-TCCAGGCCCTACGGG-3') and SDArch0958aA19 (5'-YCCGGCGTTGAMTCCAATT-3') (Eurogentec, Seraing,

Belgium) as previously described [25]. PCR products were purified and sequenced using a Big Dye Terminator v1.1 Cycle Sequencing kit (Applied Biosystems, Foster City, CA, USA). The resulting sequences were assembled using the ChromasPro 1.34 software (Technelysium Pty. Ltd., South Brisbane, Australia). The sequences were then blasted against sequences available in GenBank database using the online NCBI BLAST program (<https://blast.ncbi.nlm.nih.gov/Blast.cgi>).

Real-time PCR assays specifically targeting the 16S rRNA **methanogens** gene were also performed as confirmatory tests using the primers and probes Metha_16S_2_MBF (5'-CGAACCGGATTAGATACCCG - 3'); Metha_16S_2_MBR (5'-CCCGCCAATTCCTTTAAGTT- 3'); Metha_16S_2_MBP 6FAM-CCTGGGAAGTACGGTCGCAAG. Master mix and RNase-free water were used as negative control. **Real-time PCR was considered positive for any cycle threshold (Ct) value \leq 38, and the results were validated by the PCR detection of human β -actin gene as an internal control in each sample. To estimate the methanogens inoculum in each sample by extrapolation of the Ct values, a calibration curve was generated from an *M. smithii* and *M. oralis* DNA sample calibrated at 10^9 colony-forming units (CFU)/mL, followed by 10-fold cascade dilutions up to 10^1 CFU/mL.**

2.2.2. Microscopic examination

PCR- positive samples were observed for the presence of methanogens using scanning electron microscopy. Briefly, 100 μ L of the sample were fixed with 2.5% glutaraldehyde, spotted onto a glass slide by cytocentrifugation (Shandon cytospin4, Thermo Scientific, Waltham, MA, USA), stained using 1% phosphotungstic acid (Sigma Aldrich, Saint-Louis, MO, USA) for 2 minutes at room temperature and observed using a TM4000 Plus scanning electron microscope (Hitachi, Tokyo, Japan).

3. Case presentation

Case 1.

A 63-year-old Caucasian man with a medical history of psychosis treated by lithium and risperidone. He presented with a left iliac pain and fever and was diagnosed with appendicitis and peritonitis confirmed by the CT-scan which disclosed a mixed aeric left iliac collection without lymph nodes and without thrombosis. Percutaneous drainage of abscess was performed and was directly collected into an anaerobic blood culture bottle (bioMérieux). Microbiological investigations of this abscess pus yielded amoxicillin-susceptible *E. coli* in culture along with *M. oralis* detected by specific PCR-based methods. The patient was administered intravenous piperacillin/tazobactam 4 gr three times a day plus ciprofloxacin 500 mg twice a day. On day one, the evolution was unfavourable with septic shock. The biological profile revealed an inflammatory syndrome with a hyperleukocytosis of 18 G/L and a CRP of 84 mg/L. The patient underwent an appendectomy with peritoneal debridement. To limit perfusion time and prevent the risks of infection, antibiotic treatment was switched for oral administration of ciprofloxacin 500 mg three times a day plus metronidazole 500 mg three times a day for one week. The patient was discharged on day 21 and the one-month follow-up examination confirmed that the patient was completely cured.

Case 2.

A 39-year-old woman underwent laparoscopic surgery with an appendectomy and caecum repair, for peritonitis with perforation of the caecum. The patient was treated with amoxicillin-clavulanate 1gr three times a day plus gentamicin 160 mg one time a day for 24 hours, which was then replaced by Piperacillin/tazobactam 4 gr three times a day for nine days and finally switched for oral administration of amoxicillin-clavulanate 1gr three times a day for additional week. On day 2 post-surgery, the patient was febrile (38.5°C) and had abdominal pain. The biological profile revealed an inflammatory syndrome with a hyperleukocytosis of 11 G/L and a CRP of 350 mg/L. A CT-scan diagnosed

a right iliac abscess treated on day 4 post-surgery by radiological drainage. Microbiological investigations of this abscess pus yielded *E. coli* in culture along with *M. smithii* detected by specific PCR-based methods. The evolution was favourable at the six-week postoperative medical consultation.

Case 3.

A 14-year-old boy presented with acute appendicitis with peritonitis and peritoneal abscess, which was treated medically with multiple antibiotic therapy consisting of Cefotaxime 2 gr three times daily for three days plus metronidazole 500 mg three times daily for 20 days, gentamicin 160 mg once daily for 6 days and piperacillin/tazobactam 2 gr three times daily for 10 days as well as by percutaneous puncture of the abscess. Microbiological examinations of this abscess pus revealed the presence of *E. coli* and *E. faecium* in culture as well as *M. smithii* detected by specific PCR-based methods. Six month later, the patient was febrile (38.8°C) and the biological profile revealed an inflammatory syndrome with a hyperleukocytosis of 14 G/L and a CRP of 268 mg/L. A laparoscopic appendectomy was performed. Final antibiotic therapy consisted of a combination of ciprofloxacin 500 mg three times daily and metronidazole 500 mg three times daily for one week. The evolution was favourable one month after surgery.

Case 4.

A 19-year-old male with a medical history of autism, treated with Valproic acid and Amitriptyline, underwent a laparoscopic appendectomy. Histological examination of specimen confirmed the diagnosis of acute and suppurative appendicitis and peritonitis. On Day 6 post-surgery, the patient presented with a fever of 38.1°C and abdominal pain. The biological profile revealed an inflammatory syndrome with a hyperleukocytosis of 14 G/L and a CRP of 177 mg/L. A 25-mm pericaecal abscess was diagnosed by CT-scan and treated by percutaneous drainage and medically using ceftriaxone 2 gr/day plus metronidazole 500

mg/day for 24H, which was then replaced by piperacillin/tazobactam 2 gr three times a day for 12 days, followed by amoxicillin-clavulanate 1gr three times a day for one week. Microbiological investigations of this drained abscess pus yielded *E. coli* plus *E. avium* in culture along with *M. smithii* detected by specific PCR-based methods. The evolution was favourable at the five-week postoperative medical consultation.

4. Results

4.1. Molecular detection of methanogens

A total of four intra-abdominal peri-appendicular abscess samples were positive for methanogens. Sequencing of archaea 16S rRNA PCR products yielded, for one sample, 100% sequence similarity with the 16S rRNA gene of *Methanobrevibacter oralis* strain VD9^T (accession number LN898260) and, for three samples, 100% sequence similarity with the 16S rRNA gene of *Methanobrevibacter smithii* strain ATCC 35061^T (accession number GCA_000016525.1). Quantitative PCR analyses targeting the methanogens 16S rRNA gene confirmed the results of PCR sequencing with a median Ct of 30.98 (Interquartile range, IQR, 32.94-23.87), indicative of a methanogens load between of 4.16×10^4 /mL and 2.48×10^8 /mL (Table 1).

All four samples were also positive for *Escherichia coli*. Additionally, *Enterococcus faecium* and *Enterococcus avium* were found associated with both methanogens' species in two samples (Table 1).

4.2. Microscopic observation

Scanning electron microscopy revealed two morphological forms in the samples collected from Case No. 1 and Case No. 2. In each case, one of the observed morphologies matched that of a methanogen, a diplococcoid morphology with a diameter ranging from 0.5 to 1 μ m similar to that of *M. smithii* as well as a bacilli shape with a diameter ranging from 0.7 to 1.2 μ m characteristic of *M. oralis*. The other shape observed in the samples, - bacilli

with lengths of 0.5 to 4 μm with a diameter of 0.5-1.2 μm , similar to that of the co-detected *E. coli* (Figure 1)

4. Discussion

Here, we are reporting the first detection of the methanogenic archaeal species, *M. smithii* and *M. oralis*, in four patients suffering from appendicular abscesses using molecular-based and electron microscopic-based observations. Despite the depth bias associated to molecular methods, these methanogens were detected using two PCR-based methods, quantitative PCR and standard PCR. The latter was further validated by sanger sequencing of the PCR product leading to a definite identification of the detected methanogen. Moreover, using electron microscopy, cells with methanogen-like shaped were observed in each culture. Bacteriological analysis of the abscess samples led the isolation of facultative anaerobic bacteria including *E. coli*, *E. avium* and *E. faecium*, consistently with prior analyses of appendicular abscesses [26, 27].

To our knowledge, this is the first study reporting the detection of methanogens in appendicular abscesses. To date, the presence of methanogens in such a clinical situation has remained unknown because they are not easily detected in clinical microbiology using routine analysis methods such as microscopic observation after Gram staining, culture-based and PCR-based methods. In fact, microscopic examination after Gram staining of methanogens is unreliable and non-specific. Furthermore, the culture of methanogens requires an unusual atmosphere consisting of hydrogen and carbone dioxide whereas and PCR-based detection requires specific DNA extraction including sonication as a method of mechanical lysis [28]. Routine diagnostic laboratory is based on timely result report to quickly provide a diagnosis and therapeutic plan for the patient. Therefore, slow growing organisms such as methanogens, can easily escape routine detection. Although this is a first report, the detection of methanogens is not surprising, given the anatomical location of the appendix in the

gastrointestinal tract. In fact, *M. smithii* is ubiquitous in healthy adult and is stable over the life course with a prevalence increasing with age [29, 30]. Additionally, methanogens are hydrogens-consuming microorganisms that interact preferentially with hydrogens-producing bacteria through syntrophic process to reduce CO₂ into methane [31]. Here, all methanogens-positive samples were co-detected with *E. coli* which is a known hydrogen producer [32].

The relationship between bacteria and methanogens are paramount for intestinal homeostasis. Thus, any fluctuation in the level of methanogens could be involved in the physiopathology of some diseases [33-38]. In the context of appendicular abscess, we suggest two plausible mechanisms by which methanogenesis could be involved in the occurrence of this situation or their implication as potential risk factor, either through the promotion of the growth of pathogenic bacteria such as enterobacteria by maintaining a low partial pressure of hydrogen, which is a very important condition for the fermentation process [39, 40], or by increasing methane excretion due to high methanogens concentrations, leading to a toxic atmosphere. The possible implication of methanogens in appendicitis is corroborated by the recent study reporting an association between appendectomy and decreased methanogen levels, suggesting that the appendix may serve as a reservoir for the intestinal microbiome, including methanogens [41].

To date, the gold standard treatment of complicated appendicitis is based on invasive and costly methods, including percutaneous drainage of appendicular abscesses or laparoscopic appendectomy [16]. In some cases, a nonoperative management of complicated appendicitis is adopted, but this is associated with a risk of recurrence [42, 43].

Methanogens are naturally resistant to beta-lactams which are the most used antibiotics in appendicular abscess. It would be interesting to prescribe antibiotics active against

225 methanogens such as metronidazole or fusidic acid [44], as was done for three patients
226 reported ins this study.

227 Based on these preliminary results, largest cohort studies are needed for investigating
228 specifically the prevalence of methanogens and confirm their possible implication in the
229 occurrence of appendicular abscesses. In fact, if the implication of methanogens is
230 demonstrated, they should be taken into consideration in the diagnosis of this infection to
231 adapt medical treatment.

Funding

D.K. receives a PhD grant from the Fondation Méditerranée Infection, Marseille. This work was supported by the French Government under the “Investissements d’avenir” (Investments for the Future) programme managed by the Agence Nationale de la Recherche (ANR, fr: National Agency for Research), (reference: Méditerranée Infection 10-IAHU-03). This work was supported by Region Sud (Provence Alpes Cote d’Azur) and European funding ERDF PRIMMI.

Conflict of interest:

The authors declare no conflicts of interest.

References.

1. Thauer RK, Kaster AK, Seedorf H, Buckel W, Hedderich R. Methanogenic archaea: ecologically relevant differences in energy conservation. *Nat Rev Microbiol.* 2008 Aug;6(8):579-91. doi: 10.1038/nrmicro1931.
2. Miller TL, Wolin MJ. Enumeration of *Methanobrevibacter smithii* in human feces. *Arch Microbiol.* 1982 Feb;131(1):14-8.
3. Mihajlovski A, Doré J, Levenez F, Alric M, Brugère JF. Molecular evaluation of the human gut methanogenic archaeal microbiota reveals an age-associated increase of the diversity. *Environ Microbiol Rep.* 2010 Apr;2(2):272-80.
4. Grine G, Boualam MA, Drancourt M. *Methanobrevibacter smithii*, a methanogen consistently colonising the newborn stomach. *Eur J Clin Microbiol Infect Dis.* 2017 Dec;36(12):2449-2455.
5. Dridi B, Henry M, El Khéchine A, Raoult D, Drancourt M. High prevalence of *Methanobrevibacter smithii* and *Methanosphaera stadtmanae* detected in the human gut using an improved DNA detection protocol. *PLoS One.* 2009 Sep 17;4(9):e7063
6. Mihajlovski A, Alric M, Brugère JF. A putative new order of methanogenic Archaea inhabiting the human gut, as revealed by molecular analyses of the *mcrA* gene. *Res Microbiol.* 2008 Sep-Oct;159(7-8):516-21.
7. Dridi B, Fardeau ML, Ollivier B, Raoult D, Drancourt M. *Methanomassiliicoccus luminyensis* gen. nov., sp. nov., a methanogenic archaeon isolated from human faeces. *Int J Syst Evol Microbiol.* 2012 Aug;62(Pt 8):1902-1907.

8. Blais Lecours P, Marsolais D, Cormier Y, Berberi M, Haché C, Bourdages R, Duchaine C. Increased prevalence of *Methanosphaera stadtmanae* in inflammatory bowel diseases. *PLoS One*. 2014 Feb 3;9(2):e87734
9. Piqué JM, Pallarés M, Cusó E, Vilar-Bonet J, Gassull MA. Methane production and colon cancer. *Gastroenterology*. 1984 Sep;87(3):601-5
10. Yazici C, Arslan DC, Abraham R, Cushing K, Keshavarzian A, Mutlu EA. Breath Methane Levels Are Increased Among Patients with Diverticulosis. *Dig Dis Sci*. 2016 Sep;61(9):2648-54.
11. Nkanga VD, Lotte R, Roger PM, Drancourt M, Ruimy R. *Methanobrevibacter smithii* and *Bacteroides thetaiotaomicron* cultivated from a chronic paravertebral muscle abscess. *Clin Microbiol Infect*. 2016 Dec;22(12):1008-1009.
12. Drancourt M, Nkanga VD, Lakhe NA, Régis JM, Dufour H, Fournier PE, Bechah Y, Scheld WM, Raoult D. Evidence of Archaeal Methanogens in Brain Abscess. *Clin Infect Dis*. 2017 Jul 1;65(1):1-5.
13. Drancourt M, Djemai K, Gouriet F, Grine G, Loukil A, Bedotto M, Levasseur A, Lepidi H, Bou-Khalil J, Khelaifia S, Raoult D. *Methanobrevibacter smithii* archaeemia in febrile patients with bacteremia, including those with endocarditis. *Clin Infect Dis*. 2020 Jul 15:ciaa998. doi: 10.1093/cid/ciaa998.
14. Humes DJ, Simpson J. Acute appendicitis. *BMJ*. 2006 Sep 9;333(7567):530-4. doi: 10.1136/bmj.38940.664363.AE.
15. Perez KS, Allen SR. Complicated appendicitis and considerations for interval appendectomy. *JAAPA*. 2018 Sep;31(9):35-41. doi: 10.1097/01.JAA.0000544304.30954.40.

16. Li Z, Zhao L, Cheng Y, Cheng N, Deng Y. Abdominal drainage to prevent intra-peritoneal abscess after open appendectomy for complicated appendicitis. *Cochrane Database Syst Rev*. 2018 May 9;5(5):CD010168. doi: 10.1002/14651858.CD010168.pub3.
17. D'Souza N, Nugent K. Appendicitis. *BMJ Clin Evid*. 2014 Dec 8;2014:0408. PMID: 25486014; PMCID: PMC4259213.
18. Jones MW, Lopez RA, Deppen JG. Appendicitis. 2020 Dec 7. In: StatPearls [Internet]. Treasure Island (FL): StatPearls Publishing; 2020 Jan-. PMID: 29630245.
19. Larbcharoensub N, Boonsakan P, Kanoksil W, Wattanatrano D, Phongkitkarun S, Molagool S, Watcharananan SP. Fungal appendicitis: a case series and review of the literature. *Southeast Asian J Trop Med Public Health*. 2013 Jul 4;44(4):681-9.
20. Yiğiter M, Kiyici H, Arda IS, Hiçsönmez A. Actinomycosis: a differential diagnosis for appendicitis. A case report and review of the literature. *J Pediatr Surg*. 2007 Jun;42(6):E23-6. doi: 10.1016/j.jpedsurg.2007.03.057.
21. Plataras C, Tsangouri S, Bourikas D, Christianakis E. Acute appendicitis in a child with swine influenza (H1N1). *BMJ Case Rep*. 2015 Mar 26;2015:bcr2014208219. doi: 10.1136/bcr-2014-208219. PMID: 25814027.
22. Katzoli P, Sakellaris G, Ergazaki M, Charissis G, Spandidos DA, Sourvinos G. Detection of herpes viruses in children with acute appendicitis. *J Clin Virol*. 2009 Apr;44(4):282-6. doi: 10.1016/j.jcv.2009.01.013.
23. Habashi R, Lisi MP. Acute appendicitis and *Enterobius vermicularis* infestation. *CMAJ*. 2019 Apr 29;191(17):E477. doi: 10.1503/cmaj.181194.

24. Altun E, Avci V, Azatcam M. Parasitic infestation in appendicitis. A retrospective analysis of 660 patients and brief literature review. *Saudi Med J*. 2017 Mar;38(3):314-318. doi: 10.15537/smj.2017.3.18061.
25. Lepp PW, Brinig MM, Ouverney CC, Palm K, Armitage GC, Relman DA. Methanogenic Archaea and human periodontal disease. *Proc Natl Acad Sci U S A*. 2004 Apr 20;101(16):6176-81. doi: 10.1073/pnas.0308766101.
26. Chen CY, Chen YC, Pu HN, Tsai CH, Chen WT, Lin CH. Bacteriology of acute appendicitis and its implication for the use of prophylactic antibiotics. *Surg Infect (Larchmt)*. 2012 Dec;13(6):383-90. doi: 10.1089/sur.2011.135.
27. Montuori M, Santurro L, Gianotti L, Fattori L. Uselessness of microbiological samples in acute appendicitis with frank pus: to collect or not to collect? *Eur J Trauma Emerg Surg*. 2020 Aug;46(4):835-839. doi: 10.1007/s00068-018-1031-7.
28. Bang C, Schmitz RA. Archaea: forgotten players in the microbiome. *Emerg Top Life Sci*. 2018 Dec 14;2(4):459-468. doi: 10.1042/ETLS20180035.
29. Miller, T. L. & Wolin, M. J. Stability of *Methanobrevibacter smithii* populations in the microbial flora excreted from the human large bowel. *Appl Environ Microbiol* 45, 317-318 (1983).
30. Stewart JA, Chadwick VS, Murray A. Carriage, quantification, and predominance of methanogens and sulfate-reducing bacteria in faecal samples. *Lett Appl Microbiol*. 2006;43:58–63.
31. Robert C, Del'Homme C, Bernalier-Donadille A. Interspecies H₂ transfer in cellulose degradation between fibrolytic bacteria and H₂-utilizing microorganisms from the human colon. *FEMS Microbiol Lett*. 2001;205:209–14.

32. 31 Trchounian K, Trchounian A. Hydrogen production from glycerol by *Escherichia coli* and other bacteria: An overview and perspectives. *Appl Energy*. 2015; 156:174-84.
33. 32Scanlan PD, Shanahan F, Marchesi JR. Human methanogen diversity and incidence in healthy and diseased colonic groups using *mcrA* gene analysis. *BMC Microbiol*. 2008; 8:79.
34. 33Ghavami SB, Rostami E, Sephay AA, Shahrokh S, Balaii H, Aghdaei HA, et al. Alterations of the human gut *Methanobrevibacter smithii* as a biomarker for inflammatory bowel diseases. *Microb Pathog*. 2018; 117:285–9.
35. 34Ghoshal U, Shukla R, Srivastava D, Ghoshal UC. Irritable Bowel Syndrome, Particularly the Constipation-Predominant Form, Involves an Increase in *Methanobrevibacter smithii*, Which Is Associated with Higher Methane Production. *Gut Liver*. 2016; 10:932–8.
36. 35Wilder-Smith CH, Olesen SS, Materna A, Drewes AM. Breath methane concentrations and markers of obesity in patients with functional gastrointestinal disorders. *United Eur Gastroenterol J*. 2018; 6:595–603
37. 36Wilder-Smith CH, Olesen SS, Materna A, Drewes AM. Breath methane concentrations and markers of obesity in patients with functional gastrointestinal disorders. *United Eur Gastroenterol J*. 2018; 6:595–603
38. 37Camara A, Konate S, Tidjani Alou M, Kodio A, Togo AH, Cortaredona S, Henrissat B, Thera MA, Doumbo OK, Raoult D, Million M. Clinical evidence of the role of *Methanobrevibacter smithii* in severe acute malnutrition. *Sci Rep*. 2021; 11:5426.

39. 38Stams AJM, Plugge CM. Electron transfer in syntrophic communities of anaerobic bacteria and archaea. *Nat Rev Microbiol*. 2009;7:568–77.
40. 39Conway de Macario E, Macario AJ. Methanogenic archaea in health and disease: a novel paradigm of microbial pathogenesis. *Int J Med Microbiol*. 2009 Feb;299(2):99-108. doi: 10.1016/j.ijmm.2008.06.011. Epub 2008 Aug 30. PMID: 18757236.
41. 40Takakura W, Oh SJ, Singer-Englar T, Mirocha J, Leite G, Fridman A, Pimentel M, Mathur R, Pichetshote N, Rezaie A. Comparing the rates of methane production in patients with and without appendectomy: results from a large-scale cohort. *Sci Rep*. 2020 Jan 21;10(1):867. doi: 10.1038/s41598-020-57662-y.
42. Andersson RE, Petzold MG. Nonsurgical treatment of appendiceal abscess or phlegmon: a systematic review and meta-analysis. *Ann Surg*. 2007 Nov;246(5):741-8. doi: 10.1097/SLA.0b013e31811f3f9f.
43. Maxfield MW, Schuster KM, Bokhari J, McGillicuddy EA, Davis KA. Predictive factors for failure of nonoperative management in perforated appendicitis. *J Trauma Acute Care Surg*. 2014 Apr;76(4):976-81. doi: 10.1097/TA.0000000000000187.
44. Dridi B, Fardeau ML, Ollivier B, Raoult D, Drancourt M. The antimicrobial resistance pattern of cultured human methanogens reflects the unique phylogenetic position of archaea. *J Antimicrob Chemother*. 2011 Sep;66(9):2038-44. doi: 10.1093/jac/dkr251.

388 **Table 1.** Patient information along with PCR sequencing, RT-PCR and bacterial culture
 389 results.

Case	Sex	Age	PCR-Sequencing	RT-PCR targeting β -actin	RT-PCR targeting methanogens 16S gene	Methanogens load	Bacterial culture
1	M	63	<i>M. oralis</i>	24,82	23.87	2.48×10^8 / mL	<i>E. coli</i>
2	F	39	<i>M. smithii</i>	26,08	32.94	4.16×10^4 / mL	<i>E. coli</i>
3	M	14	<i>M. smithii</i>	25,24	30.25	5.48×10^5 / mL	<i>E. coli</i> + <i>E. faecium</i>
4	M	19	<i>M. smithii</i>	24,73	31.71	1.35×10^5 / mL	<i>E. coli</i> + <i>E. avium</i>

390

391

392

393

394

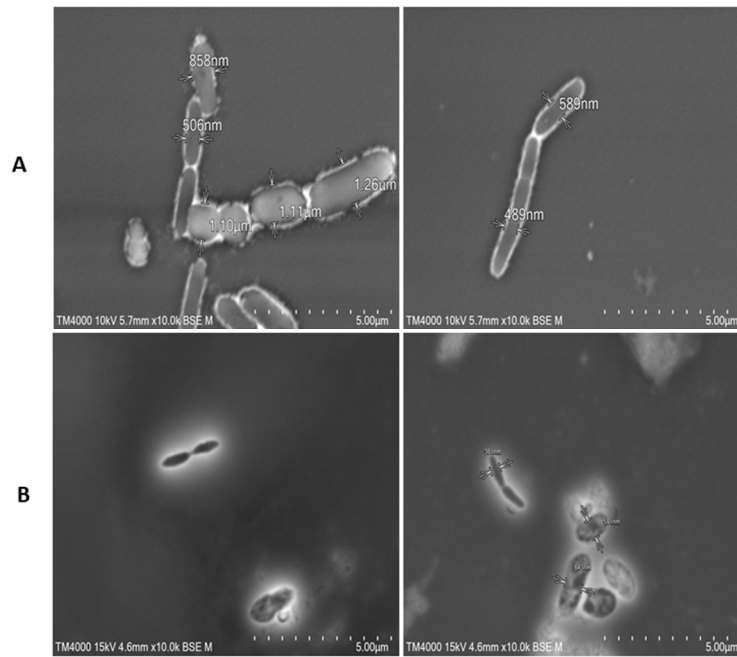
395

396

397

398

399



400

401 **Figure 1.** Scanning electron microscopy imaging of peri-appendicular abscess pus sample in
 402 one patient diagnosed with mixed *M. oralis* and *E. coli* infection (Panel A) and in one patient
 403 diagnosed with mixed *M. smithii* and *E. coli* infection (Panel B). The scale bars indicate 5 μm.