



**HAL**  
open science

## **Nocardia farcinica cerebral abscess: A systematic review of treatment strategies**

N. Beucler, K. Farah, A. Choucha, M. Meyer, S. Fuentes, P. Seng, Henry Dufour

### ► **To cite this version:**

N. Beucler, K. Farah, A. Choucha, M. Meyer, S. Fuentes, et al.. Nocardia farcinica cerebral abscess: A systematic review of treatment strategies. Neurochirurgie, 2022, 68 (1), pp.94-101. 10.1016/j.neuchi.2021.04.022 . hal-03663623

**HAL Id: hal-03663623**

**<https://amu.hal.science/hal-03663623v1>**

Submitted on 5 Apr 2023

**HAL** is a multi-disciplinary open access archive for the deposit and dissemination of scientific research documents, whether they are published or not. The documents may come from teaching and research institutions in France or abroad, or from public or private research centers.

L'archive ouverte pluridisciplinaire **HAL**, est destinée au dépôt et à la diffusion de documents scientifiques de niveau recherche, publiés ou non, émanant des établissements d'enseignement et de recherche français ou étrangers, des laboratoires publics ou privés.

# *Nocardia farcinica* cerebral abscess: A systematic review of treatment strategies

N. Beucler<sup>a,b,\*</sup>, K. Farah<sup>c</sup>, A. Choucha<sup>c</sup>, M. Meyer<sup>c</sup>, S. Fuentes<sup>c</sup>, P. Seng<sup>d</sup>, H. Dufour<sup>c,e</sup>

<sup>a</sup> Neurosurgery department, Sainte-Anne Military teaching Hospital, 2, boulevard Sainte-Anne, 83800 Toulon cedex 9, France

<sup>b</sup> École du Val-de-Grâce, French Military Health Service Academy, 1, place Alphonse-Laveran, 75230 Paris cedex 5, France

<sup>c</sup> Neurosurgery department, Timone University Hospital, APHM, 264, rue Saint-Pierre, 13005 Marseille, France

<sup>d</sup> Unité microbes, évolution, phylogénie et infection (MEPHI), IHU – méditerranée infection, Service de maladies infectieuses tropicales et infections chroniques (MITIC), Aix-Marseille Université, APHM, 19–21, boulevard Jean-Moulin, 13005 Marseille, France

<sup>e</sup> Inserm, MMG, Aix-Marseille Université, Marseille, France

## ARTICLE INFO

### Keywords:

*Nocardia farcinica*

Cerebral abscess

Disseminated nocardiosis

Surgical excision

Needle aspiration

## ABSTRACT

**Purpose.** – *Nocardia farcinica* is an opportunistic pathogen causing mainly pneumonia in immunocompromised patients, complicated in almost one-third of the cases by a thick-walled multiloculated cerebral abscess which induces significant morbidity and mortality. This review aims to assess the optimal treatment strategy for *N. farcinica* cerebral abscess.

**Methods.** – Report of a case. Medline database was used to conduct a systematic review from inception to January 2020 looking for English-language articles focused on *N. farcinica* cerebral abscess, in accordance with the PRISMA guidelines.

**Results.** – The research yielded 54 articles for a total of 58 patients. *N. farcinica* cerebral abscess displayed three different neuroimaging patterns: a single multiloculated abscess in half of the cases, multiple cerebral abscesses, or a small paraventricular abscess with meningitis. The patients who benefited from surgical excision of the abscess showed a trend towards a lower risk of surgical revision (8% versus 31%,  $P = 0.06$ ) and a lower mortality rate (8% versus 23%,  $P = 0.18$ ) than patients who benefited from needle aspiration. Twenty-two percent of the patients benefited from microbiological documentation from another site with a mortality rate of 23%.

**Conclusion.** – Urgent multimodal MRI is necessary in face with clinical suspicion of cerebral nocardiosis. In case of single or multiple small cerebral abscesses, microbiological documentation can be obtained with puncture of pseudotumoral visceral lesions. In case of large or symptomatic cerebral abscess, an aggressive surgical excision seems a reliable option and can be preferred over needle aspiration. Long-term antibiotic therapy with cotrimoxazole is necessary thereafter.

## 1. Introduction

Firstly described by Edmond Nocard in 1888, *Nocardia farcinica* is a soil-born Gram positive filamentous bacteria [1]. It firstly causes pneumonia in immunocompromised patients [2]. Sometimes, the infection spreads hematogenously from an infected pulmonary site, leading to “disseminated nocardiosis” if at least two non-contiguous organs are affected (Fig. 1) [3,4]. The preferred dissemination sites are the central nervous system in one-third of the cases and then the skin [4,5]. Pseudo-tumoral visceral lesions are also possible in the abdomen, as well as in the eyes and the joints.

The prognosis of disseminated nocardiosis with cerebral involvement depends on the size, the number and the location of cerebral abscesses in oftentimes fragile and immunosuppressed patients. The neurosurgeon has to be solicited for diagnostic purpose or for symptomatic relief in face with a large multiloculated abscess. The expertise of the infectious disease specialist becomes mandatory thereafter.

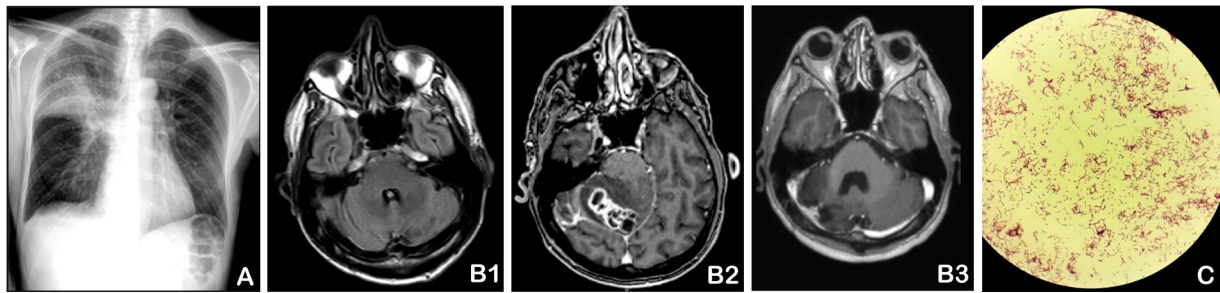
## 2. Materials and methods

### 2.1. Case illustration

We report a case successfully managed in our institution.

\* Corresponding author.

E-mail address: [nathan.beucler@neurochirurgie.fr](mailto:nathan.beucler@neurochirurgie.fr) (N. Beucler).



**Fig. 1.** This panel displays the course of a 55-year-old HIV positive non-compliant patient who was treated in our institution for disseminated nocardiosis. A. He presented lobar pneumonia which was treated with ceftriaxone, and lymphocytic meningitis with negative microbiological tests and a normal MRI of the brain (B1). Two months later, he presented with a cerebellar syndrome associated with an inflammatory reaction (CRP 16 mg/L) related to a (B2) multiloculated cerebellar abscess which was operated on. The microbiology report was consistent with (C) *Nocardia farcinica* and the patient was treated with a one-month course of linezolid and a six-months course of cotrimoxazole (B3). The follow-up MRI of the brain showed no evidence of relapse.

## 2.2. Database research

We conducted a systematic literature review focused on *N. farcinica* cerebral abscess on Medline database ([ncbi.nlm.nih.gov/pubmed/](http://ncbi.nlm.nih.gov/pubmed/)) from inception until January 2020. We used the advanced research mode with the following associations of Mesh terms: [{"nocardia" in the Title} and {"cerebral" or "brain" in the Title}] and [{"farcinica" in the Title of the Text} and {"cerebral" or "brain" or "abscess" in the Title or in the Text}].

## 2.3. Data extraction

All the articles included in the quantitative analysis were screened in a systematic manner and the following information was extracted as previously planned: author and year of publication; age and sex of the patient; underlying immunosuppressive condition and immunosuppressive therapies; presence of an inflammatory syndrome; neurological condition; the number and the location of the cerebral abscesses; the presence of a meningitis; the neurosurgical procedure choice; the other organ chosen for microbiological documentation; the antibiotic therapies used; the outcome. This work was conducted in compliance with the Preferred Reporting Items for Systematic reviews and Meta-Analyses (PRISMA guidelines) [6].

## 2.4. Statistical analysis

All statistical analyses were conducted using GraphPad Prism 7.0 software (GraphPad Software, Inc.). Categorical variables were presented as numbers and percentages, and continuous variables were presented as the mean  $\pm$  standard deviation. The significance of baseline differences was determined by the Chi<sup>2</sup> test for categorical values; a two-sided *P*-value  $\leq 0.5$  was considered to indicate statistical significance.

## 2.5. Primary and secondary endpoints

The primary endpoint of this study was to assess the optimal surgical strategy for patients suffering from *Nocardia farcinica* cerebral abscess. The secondary endpoints of the study were to review the other possible sites for microbiological documentation, to assess the optimal antibiotic therapy, and to review the different neuroimaging patterns of *Nocardia farcinica* associated cerebral abscess.

## 2.6. Patient's informed consent

Patient's informed written consent was obtained for this work. For retrospective review of the literature, formal consent is not required.

## 3. Case illustration

A non-compliant, HIV-positive 55-year-old male patient presented right superior lobar pneumonia (Fig. 1A) which was treated with ceftriaxone. He suffered from lymphocytic meningitis with negative microbiological tests afterwards and a normal brain MRI (Fig. 1B1). At that time, he presented humoral immunodeficiency with a CD4 count of 299 cells per mm<sup>3</sup>. An antiretroviral therapy with dolutegravir, emtricitabine and tenofovir was reintroduced.

Two months later, he was admitted in the emergency department of our facility for gait disturbance. Upon admission, clinical examination showed an isolated right cerebellar syndrome without any symptom of intracranial hypertension. There was no fever or meningismus. Laboratory tests revealed a mild elevation of C-reactive protein (CRP) (16.5 mg/L) with normal white blood cells (WBC) count (6.5 G/L). The magnetic resonance imaging (MRI) showed a single multiloculated lesion in the left cerebellum with center restricted diffusion and a ring-enhanced capsule after gadolinium injection (Fig. 1B2). Because of the high suspicion of cerebral abscess and the mass effect, the patient underwent urgent surgical excision. The lesion was found to be thick-walled and filled with green pus. A broad-spectrum antibiotic therapy with meropenem and cotrimoxazole was introduced. The microbiology report was consistent with *Nocardia farcinica* using MALDI-ToF mass spectrometry (Fig. 1C) [7]. It was sensitive to amoxicilline-clavulanate (2 mg/L), linezolid (<2 mg/L), imipenem/cilastatin (<1 mg/L), amikacin (0.5 mg/L), cotrimoxazole (<0.125 mg/L) and minocycline (1 mg/L); intermediate to meropenem (8 mg/L); and resistant to amoxicillin (>16 mg/L), vancomycin (>8 mg/L), ciprofloxacin (>2 mg/L), ertapenem (>2 mg/L), fosfomycin (>32 mg/L), clindamycin (>2 mg/L) and doxycycline (>8 mg/L). The full-body CT-scan did not show any visceral lesion. The antibiotic therapy was adapted with linezolid and cotrimoxazole for one month and then cotrimoxazole alone for 12 months. At the final follow-up, the patient was in a good neurological condition with a remaining slight cerebellar syndrome (modified Rankin scale 1) and the brain MRI showed no evidence of relapse (Fig. 1B3).

## 4. Literature review

### 4.1. Database research

The primary research yielded 374 articles and 250 articles after removal of duplicates. During the first screening, 13 articles were excluded because they were not written in English and 13 other articles because they were not found. Among the 224 remaining articles which were read entirely, 106 were excluded because of a wrong pathogen, 31 because they were not directly relevant to our subject and 29 because there was no cerebral involvement. Finally, we kept 58 articles for this review [5,8–10], among which 54 articles

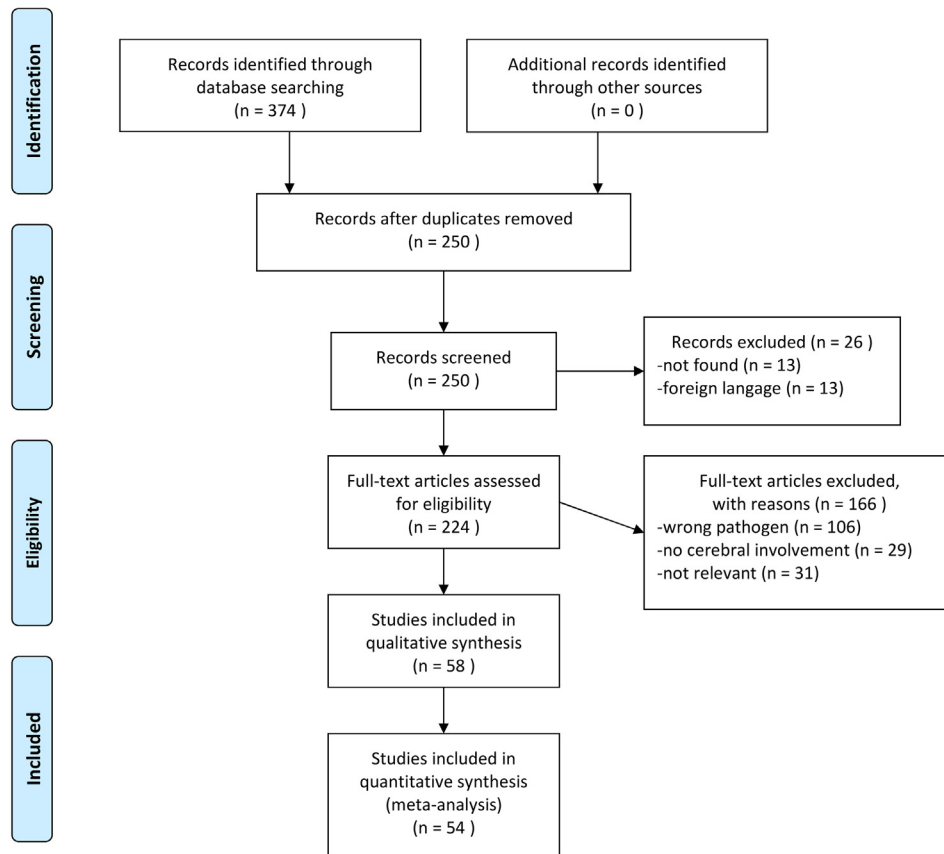


Fig. 2. Medline based systematic review on *Nocardia farcinica* cerebral abscess: PRISMA flowchart.

case reports (1 to 3 patients) were included in the quantitative analysis because of the presence of extractable individual data (Fig. 2, Online material Table S1)<sup>S1-S54</sup>.

#### 4.2. Epidemiology

A total of 58 patients were included in this review with a mean age ( $\pm$ SD) of  $56 \pm 16$  years-old and a male to female sex ratio of 1.85 for 1. Seventy-four percent of the patients ( $n=43$ ) were immunocompromised. Corticosteroids were responsible for 47% of the cases ( $n=27$ ), followed by chemotherapies and targeted therapies in 26% of the cases ( $n=15$ ). The most common immunosuppressive diseases were connective tissue diseases and vasculitis which accounted for 21% of the cases ( $n=12$ ), followed by diabetes in 15% of the cases ( $n=9$ ), organ transplant in 12% of the cases ( $n=7$ ) and malignancy in 12% of the cases ( $n=7$ ) (Table 1).

#### 4.3. Clinical presentation

Eighty-one percent of the patients ( $n=47$ ) presented neurological symptoms. The most commonly reported symptoms of central nervous system involvement were signs of intracranial hypertension in 50% of the cases ( $n=29$ ), focal signs in 50% of the cases ( $n=29$ ), seizures in 19% of the cases ( $n=11$ ). Nineteen percent of the patients ( $n=11$ ) presented with severe symptoms of intracranial hypertension (drowsiness or coma) and 9% of the patients presented with meningismus. Thirty-four percent of the patient

( $n=20$ ) presented with fever. The classic triad of fever, headaches and focal deficit was reported in only 7% of the patients ( $n=4$ ). A typical meningeal syndrome was reported in 5% of the cases ( $n=3$ ) and was related to the periventricular location of the abscess (Table 1).

Laboratory tests revealed elevated WBC count in 36% of the cases ( $n=21$ ) while it was reported as normal in 17% of the cases ( $n=10$ ); CRP was elevated in 19% of the cases ( $n=11$ ) and normal in 12% of the cases ( $n=7$ ).

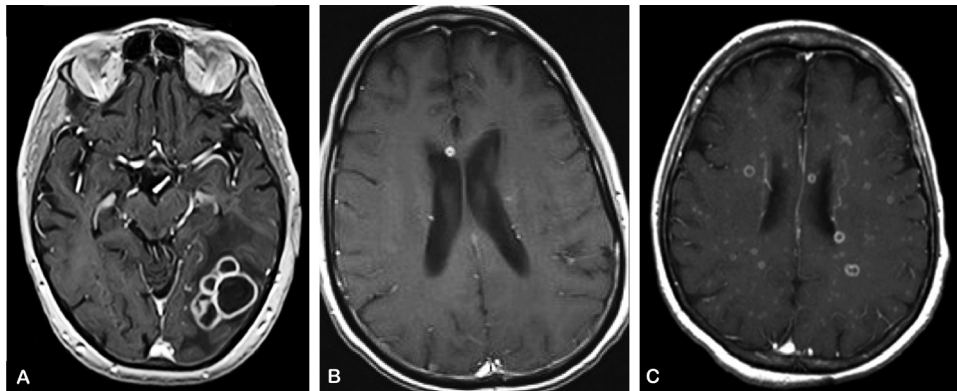
#### 4.4. Neuroimaging

*N. farcinica* central nervous involvement consisted in (Fig. 3, Table 1):

- a single abscess in 59% of the cases ( $n=34$ ). Fifty-two percent of the cases ( $n=30$ ) were supratentorial and 7% ( $n=4$ ) were located in the posterior fossa;
- among patients with a single abscess, three (5%) presented a single small periventricular abscess. These 3 patients presented with a clinical picture of meningitis including headaches, fever and a biological inflammatory syndrome, and their CSF culture from lumbar puncture was positive for *N. farcinica*;
- two abscesses in 9% of the cases ( $n=5$ );
- multiple abscesses in 28% of the cases ( $n=16$ );

**Table 1**  
Patients' characteristics.

Characteristic	Number	Percentage/standard deviation
Total patients	58	
Mean age	56	±16
Sex ratio ♂/♀	1.85/1	
Immunosuppression	43	74%
Corticosteroids	27	47%
Chemotherapy, targeted therapy	15	26%
Connective tissue disease, vasculitis, auto-immune disease	12	21%
Diabetes	9	15%
Organ transplant	7	12%
Haematological cancer	5	9%
Solid cancer	2	3%
Asthma	2	3%
Fever	20	34%
Neurological symptoms		
Symptoms of ICH	29	50%
Severe ICH with drowsiness	11	19%
Focal symptoms	29	50%
Seizures	11	19%
Meningismus	5	9%
Cerebral abscess		
Single	34	59%
Paraventricular with meningitis	3	5%
Two	5	9%
Multiple	16	28%
Infratentorial	12	21%
Multiloculated shape	31	53%
Unknown	3	5%



**Fig. 3.** Different patterns of *Nocardia farcinica* cerebral abscess on MRI. A. Typical single multiloculated abscess (courtesy of N BEUCLER et al., 2020 *Rev Neurol*, Elsevier). B. Periventricular abscess with meningitis (courtesy of TC WUERZ et al., 2013 *Can J Infect Dis Med Microbiol*, Hindawi). C. Multiple abscesses (courtesy of S PURI et al., 2018 *Am J Ophthalmol Case Rep*, Elsevier).

In 53% of the cases ( $n=31$ ), at least one of the abscesses presented with a “bunch of grapes-like” shape, a characteristic which has been reported as rather suggestive of *N. farcinica* related abscess in the literature. All the authors reported the lesions to be ring-enhanced after gadolinium injection. The majority of them reported large perilesional vasogenic cerebral edema<sup>S7,S10,S12,S14,S17,S18,S20,S22-S24,S27,S33,S37,S38,S44,S45,S47,S49-S51</sup>, with sometimes edema of an entire lobe<sup>S10,S27</sup>. Surprisingly, there were only few references to the restricted diffusion character of the center of the lesion in apparent diffusion coefficient (ADC) weighted imaging: three authors clearly reported restricted diffusion of a large abscess<sup>S22,S38,S54</sup> and one author reported restricted diffusion in a case of multiple small brain abscesses<sup>S48</sup>. One author reported elevated lipids and lactate concentration on spectroscopy MR which is suggestive of a brain abscess<sup>S34</sup>. Two authors reported hemorrhagic abscesses<sup>S13,S22</sup>. There was no reference to perfusion-weighted MRI in this review. One author reported leptomeningeal enhancement in a case of multiple cerebral abscesses<sup>S37</sup> but there was no patient suffering from empyema in this review. Another author reported a beginning ventriculitis in a case of wide parietal

multiloculated abscess extending to the ventricular trigone; in that case, the diagnosis was made with lumbar puncture<sup>S50</sup>.

Other infection sites included pseudotumoral visceral lesions in the kidneys<sup>S16</sup> and adrenal glands<sup>S22,S25</sup>, the skin<sup>S4,S25</sup>, the muscles<sup>S25,S29</sup>, the eye with choroiditis,<sup>S8</sup> retinal abscess<sup>S48</sup> or global eye involvement<sup>S18</sup>, spondylodiscitis<sup>S16,S42</sup>, arthritis<sup>S4</sup>, thyroid<sup>S16</sup> and one case of infective endocarditis<sup>S44</sup>.

#### 4.5. Microbiological documentation and neurosurgical procedure choice

Neurosurgical procedures were performed as follows (Tables 2a and 2b):

- forty-five percent of the patients ( $n=26$ ) underwent surgical excision of the abscess as a first-choice procedure. Eight percent of these patients ( $n=2$ ) required surgical revision (two surgical excisions) and 92% ( $n=24$ ) presented a favourable outcome;
- twenty-two percent of the patients ( $n=13$ ) underwent needle aspiration as a first-choice procedure, among which 31% ( $n=4$ )

**Table 2a**  
Neurosurgical procedures and other microbiological documentation sites.

Characteristics	Number	Percentage
Patients	58	
Neurosurgical procedure	42	72%
Surgical excision as a first choice	26	45%
Surgical revision	2	8%
Deceased	2	8%
Needle aspiration as a first choice	13	22%
Surgical revision	4	31%
Deceased	3	23%
Stereotactic biopsy as a first choice	3	5%
Surgical revision	0	0%
Deceased	1	33%
Other microbiological documentation	16	28%
Lumbar puncture (periventricular abscess)	3	5%
Blood cultures	3	5%
Lung	2	3%
Muscle	2	3%
Subcutaneous	2	1.5%
Visceral	2	3%
Chest wall	1	1.5%
Sputum	1	1.5%
Thyroid	1	1.5%
Eye enucleation	1	1.5%
Diagnosis at autopsy	2	3%

required a second procedure (two needle aspirations and two surgical excisions). Seventy-seven percent ( $n = 10$ ) presented a favourable outcome;

- five percent of the patients ( $n = 3$ ) underwent stereotactic biopsy;
- three percent of the patients ( $n = 2$ ) required an external ventricular drain for acute hydrocephalus, and it was followed in one patient by secondary hydrocephalus with implantation of a ventriculoperitoneal shunt.

The few authors who reported the intraoperative aspect of *N. farcinica* cerebral abscess described a thick-walled lesion filled with yellowish pus<sup>S10,S14,S23,S29,S33,S42,S45</sup>.

Patients with only one or two cerebral abscesses were operated on in 80% of the cases ( $n = 31/39$ ) and presented a favourable outcome in 84% of the cases ( $n = 26/31$ ). Patients with multiple abscesses were operated on in 50% of the cases ( $n = 8/16$ ); in such case, they presented a favourable outcome. The patients with multiple abscesses who were not operated on benefited from microbiological documentation in an extracerebral site ( $n = 7$ ) or at autopsy ( $n = 1$ ) with a fatality rate of 38% ( $n = 3/8$ ).

Twenty-eight percent of the patients ( $n = 16$ ) benefited from microbiological documentation in an extracerebral site, among

**Table 2b**  
Procedure choice depending on the number of cerebral abscesses.

	Single abscess	2 abscesses	Multiple abscesses	Unknown	Total
Surgical excision	18	3	4	1	26 (45%)
Favourable	17	2	4	1	24 (92%)
Death	1	1	0	0	2 (8%)
Needle aspiration	7	1	3	2	13 (22%)
Favourable	6	0	3	1	10 (77%)
Death	1	1	0	1	3 (23%)
Stereotactic biopsy	2	0	1	0	3 (5%)
Favourable	1	0	1	0	2 (67%)
Death	1	0	0	0	1 (33%)
Documentation from another organ	2	1	7	0	10 (17%)
Favourable	2	1	5	0	8 (80%)
Death	0	0	2	0	2 (20%)
Lumbar puncture for paraventricular abscess	3	0	0	0	3 (5%)
Favourable	2	0	0	0	2 (67%)
Death	1	0	0	0	1 (33%)
Autopsy	1	0	1	0	2 (3%)
Unknown	1				1 (1.5%)
<b>Total</b>	<b>34 (59%)</b>	<b>5 (9%)</b>	<b>16 (28%)</b>	<b>3 (5%)</b>	<b>58</b>

whom 63% ( $n = 10/16$ ) did not benefit from any neurosurgical procedure and were diagnosed with *N. farcinica* cerebral abscess based upon extracerebral samples exclusively. Among the patients who benefited from extracerebral documentation exclusively, 80% ( $n = 8/10$ ) presented a favourable outcome. Extracerebral documentation sites included CSF from lumbar culture in case of periventricular abscess with meningitis<sup>S31,S36,S50</sup>, lung biopsy<sup>S17,S36</sup> or culture of sputum<sup>S15</sup>, biopsy of pseudotumoral visceral abscess<sup>S22,S49</sup>, biopsy of subcutaneous abscess<sup>S25,S41</sup>, or chest wall<sup>S9</sup>, muscle abscess<sup>S29,S53</sup>, thyroid abscess<sup>S16</sup>, eye enucleation<sup>S18</sup>, and finally blood culture<sup>S4,S16,S37</sup>.

#### 4.6. Microbiological identification

Bacterial identification was reported in 38% of the patients ( $n = 22/58$ ). It was realized in 90% of the patients ( $n = 20$ ) with 16s ribosomal DeoxyRibonucleic Acid (rDNA) sequencing<sup>S11,S13,S15,S16,S19,S22-S24,S29,S31,S33,S34,S38,S39,S45,S46,S50,S53</sup>, in one patient with MultiLocus Sequence Analysis (MLSA)<sup>S36</sup>, and in one patient with MALDI-ToF mass spectrometry<sup>S43</sup>. In two patients, identification using mass spectrometry did not allow proper identification of the species and definitive identification with 16s rDNA sequencing was necessary<sup>S45</sup>. Of note, there was one case of multibacterial abscesses in a 53-year-old man suffering from chronic obstructive pulmonary disease<sup>S47</sup>. He benefited from surgical excision of one of his five abscesses which revealed *N. farcinica* and he was treated with imipenem, linezolid and cotrimoxazole. His neurological status worsened; thus, a second surgery was carried out revealing *Enterococcus faecium*, and vancomycin was added. The patient benefited from the surgical excision of the five abscesses and from a combined intravenous antibiotic therapy for 4 months, which was adapted with oral ciprofloxacin for one year.

#### 4.7. Medical management

*N. farcinica* displayed in vitro resistance to cotrimoxazole in ten percent of the cases ( $n = 6$ ) [11,12].<sup>S6,S20,S45,S52</sup>; however, this antibiotic was successfully employed in 45% of the cases ( $n = 26/58$ ) with a favourable outcome [5,10,11].<sup>S3,S7,S12,S14,S15,S18,S21-S25,S27-S29,S31,S33,S34,S36,S37,S44-S46,S48</sup>. The other efficient broad-spectrum antibiotics against *N. farcinica* were linezolid, amikacin, imipenem and meropenem. They were most of the time associated with cotrimoxazole during initial intravenous antibiotic therapy. *N. farcinica* strains were also most of the time susceptible to

amoxicillin-clavulanate [5,10]<sup>S10,S13,S15,S21,S22,S34,S36,S50</sup> and minocycline [10]<sup>S4,S10,S21,S34,S42</sup>. They were given alone, combined together or with cotrimoxazole as a long-term oral antibiotic therapy.

The reported side effects concerning cotrimoxazole included allergy in 7% of the cases ( $n = 4/58$ ) of patients<sup>S4,S14,S24,S28</sup>, thrombocytopenia or pancytopenia in 5% of the cases ( $n = 3/58$ )<sup>S27,S32,S51</sup>, and finally hyperkalemia<sup>S27</sup>. Two patients were switched to minocycline, one patient was switched to ciprofloxacin-sulfadiazine, and two patients benefited from desensitization. Imipenem was reported to cause seizures in one patient and was stopped<sup>S24</sup>.

## 5. Discussion

### 5.1. The importance and aggressiveness of *Nocardia farcinica* cerebral abscess

Recent case series oftentimes identify *N. farcinica* as one of the most frequently encountered *Nocardia* subspecies in human infection, along with *N. cyriacigeorgica* (formerly *N. asteroides* type VI [5,13]) and *N. nova* [5,10,14,15]. What is more, *N. farcinica* appears to present the highest tropism for CNS involvement among *Nocardia* subspecies [14]. Last, this review is in line with the literature which supports that *N. farcinica* could be the pathogen with the highest multiple-antibiotic-resistance profile among all *Nocardia* subspecies [5,10]. For the abovementioned reasons and to ensure some homogeneity in the present study, we purposely chose to focus this review on *N. farcinica* cerebral abscess. Therefore, this work is to be interpreted with caution in case of cerebral abscess caused by another *Nocardia* subspecies.

### 5.2. Previous series in the literature

Our series follows previous research concerning *N. farcinica* cerebral abscess regarding the patients' mean age around 57 years-old [16] and the sex ratio of two to three males for one female [8,10,16,17]. The patients in previous series were reported to be immunocompromised in two-third of the cases which is consistent with our findings [3,5,8–10,16,17]. The immunocompromised male patient around 60-years-old seems to represent the target population of *N. farcinica* cerebral abscess.

### 5.3. Cerebral nocardiosis, clinical presentation

Disseminated *N. farcinica* infection with cerebral abscess is a rare disease and thus an unusual diagnosis for most clinicians. Clinical presentation is comparable to that of a brain metastasis with symptoms of intracranial hypertension, focal deficits and seizures [18]. In one-third of the cases, the presence of fever and an inflammatory syndrome may help to evoke the diagnosis of cerebral abscess; however, the clinician should not rely on their presence considering their uncertain character [19].

### 5.4. Neuroimaging patterns as an orientation for microbiological documentation

*N. farcinica* cerebral abscess displays three different imaging patterns (Fig. 3). The most typical one is a single multiloculated "bunch of grapes" lesion with centre restricted diffusion on brain MRI which is present in half of the cases; more rarely, there may be two cerebral abscesses. Otherwise, *N. farcinica* cerebral involvement may result in multiple small cerebral abscesses which can also display restricted diffusion. Lastly, there can be a single small paraventricular abscess with a compelling meningeal syndrome;

in such case the abscess is believed to regularly release bacterial content within the ventricular system. This neuroimaging classification, which is illustrated in Fig. 3, serves a diagnosis and a therapeutic purpose:

- *N. farcinica* cerebral abscess carries significant morbidity and mortality rates. As such, it should be considered as a diagnostic emergency and the patients requiring a neurosurgical procedure because of a large or symptomatic multiloculated abscess should be referred promptly thanks to a "blink-of-the-eye" diagnosis;
- second, it appears that patients suffering from a single or two cerebral abscesses could be eligible for a neurosurgical procedure as part of the treatment. At the opposite, patients with multiple cerebral abscesses or with a small paraventricular abscess with meningitis don't usually require any neurosurgical procedure apart from a possible temporary external ventricular drain, and should benefit from microbiological documentation from another organ including lumbar puncture.

Multimodal MRI serves as a diagnostic orientation tool in such context [20]. In diffusion-weighted imaging, the center of brain abscesses in capsule stage usually displays lower ADC values compared to brain metastases, even necrotic ones. On the same way, the abscess' capsule displays lower relative cerebral blood flow (rCBV) values than the tumor's wall of brain metastases on perfusion-weighted MRI. Spectroscopy MR is neither sensitive nor specific to differentiate cerebral abscesses from brain metastases, although it may show a trend for different resonance peaks (mainly amino-acids, lipids and lactates).

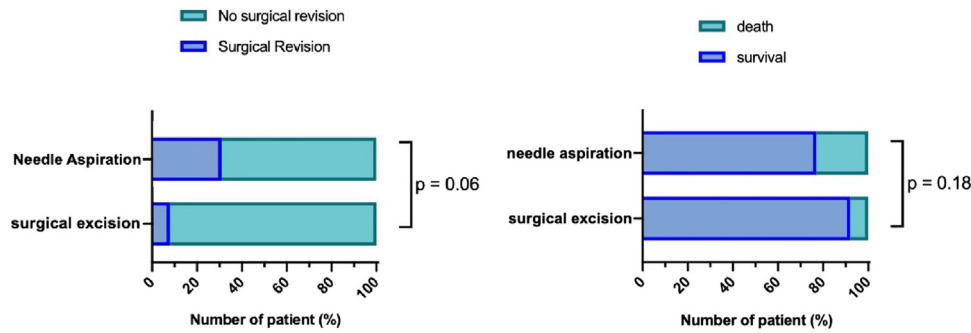
In the light of this review, *N. farcinica* cerebral abscess displays a ring-enhanced capsule, center restricted diffusion, and large perilesional vasogenic cerebral edema when multimodal MRI is carried out; these characteristics are MRI features highly suggestive of brain abscess. Thus, we consider multimodal MRI as essential, in addition to morphologic criteria such as the multiloculated character of the lesion, to give rise to the radiologic suspicion of *N. farcinica* and to hasten the necessary microbiological documentation<sup>S54</sup>. The analysis of perfusion-weighted imaging is of great support for the differential diagnosis with brain tumors and should be performed in a systematic way.

### 5.5. Microbiological documentation

Along with *N. brasiliensis* and *N. otitidiscaviarum*, *N. farcinica* often displays a high antibiotic resistance profile [4,13]. The clinician must look for the safest organ in order to obtain microbiological documentation. Thus, all the patients with suspected nocardiosis must benefit from prompt computed tomography of the thorax, abdomen and pelvis and brain MRI before any invasive procedure. Given its multiloculated shape and its association with pseudotumoral visceral lesions, *N. farcinica* cerebral abscess can be easily mistaken for a glioma<sup>S12,S21,S45</sup>, a brain metastasis<sup>S7,S12,S19,S24,S47</sup> or cerebral toxoplasmosis<sup>S19,S28</sup> particularly in case of HIV-positive patient. The case by Iannotti et al. concerning a 53-year-old man with history of smoking, who presented with a lung nodule and a temporo-parietal multiloculated lesion causing mixed aphasia is a concrete example of difficult differential diagnosis. Lung biopsy was negative for malignancy, and the patient underwent an awake surgery for removal of the lesion in eloquent speech area which was found to be a nocardial abscess<sup>S24</sup>.

### 5.6. Neurosurgical procedure choice

A neurosurgical procedure is necessary in the absence of documentation or in case of large symptomatic cerebral abscess with mass effect [3,9]; particular attention must be given to abscesses



**Fig. 4.** Left: comparison of the surgical revision rate between the surgical excision group and the needle aspiration group, and (right) comparison of the mortality rate between the surgical excision group and the needle aspiration group. Chi<sup>2</sup> test for categorical variables; a two-sided *P*-value  $\leq 0.05$  is considered to indicate statistical significance.

located in posterior fossa which can cause rapid posterior fossa hypertension and obstructive hydrocephalus. A consensual cut-off size of more than 2.5 cm is generally admitted for cerebral abscesses requiring surgery in addition to antibiotic therapy, regardless of the symptoms [21–24].

The prognosis of brain abscess has made tremendous progress with recent advances in neuroimaging, neurosurgical techniques, and antibiotic therapy [19,25]. Yet, the optimal strategy between needle aspiration and surgical excision is still a matter of debate. The procedure's choice remains at the discretion of the surgeon, taking into account the patient clinical status, the size of the abscess and the level of brain swelling and compression. Until the 1970s and the advent of computed tomography, needle aspiration of brain abscess was associated with high mortality rates. On the same way, open craniotomy for the surgical excision of cerebral abscess suffered from significant morbidity and mortality until the late 2000s with the development of microsurgical techniques and neuronavigation systems [26]. Nowadays, modern case series tend to prove that open craniotomy with surgical excision of the abscess may be beneficial both for the local control of the infection, with less abscess recurrence, and for antibiotic therapy duration [22,24]. Besides, some authors advocate open craniotomy for thick pus-filled or multiloculated abscesses [19,21].

For the abovementioned reasons, we believe that extracapsular one-piece excisional surgery can be beneficial for the local control of the infection in *N. farcinica* cerebral abscess which is generally thick-walled, multiloculated, and requires a long-term antibiotic therapy<sup>S1,S23,S37,S47,S54</sup>. In this series, the patients who benefited from surgical excision of the abscess presented a trend towards a lower recurrence rate (8% versus 31%,  $P=0.06$ ) and towards a lower mortality rate (8% versus 23%,  $P=0.18$ ) than the patients who benefited from needle aspiration (Fig. 4).

### 5.7. Cerebral nocardiosis, mortality

In this series, there was a mortality rate of 19% ( $n=11/58$ ) with a mean age of 59-years-old. Among these patients, only 55% were operated on ( $n=6/11$ ), most of the time in a less aggressive manner (three needle aspirations, two surgical excisions and one stereotactic biopsy). Sixty-three percent of these patient ( $n=7/11$ ) seemed to present poor prognosis factors such as posterior fossa abscess ( $n=3$ ), multiple abscesses ( $n=3$ ), deep abscesses located in the basal ganglia ( $n=2$ ), periventricular abscess with meningitis ( $n=1$ ) or extreme age ( $n=1$ , 91-years-old). These factors seemed quite similar to the ones included in the Graded Prognostic Assessment score for brain metastases [27], and could be of some help for the medical team in order to decide which patient is eligible for a neurosurgical procedure. Yet, because of the design of this study which lacks power, these considerations cannot be generalized.

### 5.8. Medical management

*N. farcinica* cerebral abscess is part of a disseminated disease. Respiratory support may be required in case of serious pulmonary infection, or in case of neurological impairment secondary to the abscess' mass effect of epilepsy. Apart for microbiological documentation, there was no need for surgery in pseudotumoral visceral lesions in this review.

*N. farcinica* cerebral abscess requires a combined intravenous antibiotic therapy during four to eight weeks followed by long-term oral antibiotic therapy for at least six months. In the light of the review, cotrimoxazole represents the first-choice antibiotic agent for the pathogen and can be used alone as a long-term oral antibiotic therapy. Some authors have raised a discrepancy between in vitro inefficiency of cotrimoxazole and favourable clinical course, and have advocated the use of cotrimoxazole for *N. farcinica* cerebral abscess regardless of its in vitro activity<sup>S39</sup>.

### 5.9. Limitations of the study

There were some limitations to this work. This was a retrospective study focused on case reports; consequently, there was a reporting bias in favour of the patients with a favourable outcome, and also a measurement bias during the collection of the information. A few case series could not be included in the quantitative analysis because of missing individual data with the loss of at least eight patients [5,8,9].

On the other hand, this was the largest series focused on *N. farcinica* cerebral abscess. Our data regarding surgical treatment and associated outcome were comparable to previously published series focused on cerebral abscess, and indicate a preference for surgical excision although this was not significant [19,22,24,25].

## 6. Conclusion

*N. farcinica* disseminated disease is a life-threatening infection which usually occurs in 60-years-old immunocompromised male patients. The brain is a frequent metastatic site of the infection, oftentimes in the form of a single thick-walled multiloculated abscess. Multimodal cerebral MRI with diffusion and perfusion-weighted imaging is necessary to give rise to the radiologic suspicion of brain abscess in patients with history of pneumonia. A neurosurgical procedure becomes mandatory in the absence of microbiological documentation or in case of a large or symptomatic abscess. In the light of this review, we would recommend aggressive surgical excision as a first-choice procedure considering the better local control of the infection and the rather good outcome of the patients. *N. farcinica* cerebral abscess is part of a systemic disease and requires multidisciplinary management and long-term antibiotic therapy with cotrimoxazole in order to achieve a favourable



outcome. Multicentric prospective trials will be very difficult to conduct on such a rare entity.

### Human and animal rights

The authors declare that the work described has been carried out in accordance with the Declaration of Helsinki of the World Medical Association revised in 2013 for experiments involving humans as well as in accordance with the EU Directive 2010/63/EU for animal experiments.

### Informed consent and patient details

The authors declare that they obtained a written informed consent from the patients and/or volunteers included in the article and that this report does not contain any personal information that could lead to their identification.

### Disclosure of interest

The authors declare that they have no competing interest.

### Funding

This work did not receive any grant from funding agencies in the public, commercial, or not-for-profit sectors.

### Author contributions

NB and HD conceptualized the article.  
NB, KF, AC, MM, SF, PS and HD participated to the collection of the data.  
NB, KF, AC, MM, SF, PS and HD participated to the analysis of the data.  
NB, KF, AC, MM, SF, PS and HD participated to the review of the literature.  
NB, KF, AC, MM, SF, PS and HD participated to the drafting of the manuscript.  
NB and HD participated to the critical revision of the manuscript.

### Acknowledgements

We thank Dr Aurore SELLIER, from the neurosurgery department of Sainte-Anne Military Teaching Hospital (Toulon, France), for her support in the statistical analyses.

### Appendix A. Supplementary data

Supplementary data associated with this article can be found, in the online version, at <https://doi.org/10.1016/j.neuchi.2021.04.022>.

### References

[1] Nocard E. Notes sur la maladie des boeufs de la Guadeloupe connue sous le nom de farcin. *Ann Inst Past* 1888;297–302.

[2] Filice G. Nocardiosis. *Respir Infect* 2001;(2):457–66.

[3] Anagnostou T, Arvanitis M, Kourkoumpetis TK, Desalermos A, Carneiro HA, Mylonakis E. Nocardiosis of the central nervous system: experience from a general hospital and review of 84 cases from the literature. *Medicine (Baltimore)* 2014;93(1):19–32.

[4] Lerner PI. Nocardiosis. *Clin Infect Dis* 1996;22(6):891–905.

[5] Wang H-L, Seo Y-H, LaSala PR, Tarrand JJ, Han XY. Nocardiosis in 132 patients with cancer. *Am J Clin Pathol* 2014;142(4):513–23.

[6] Moher D, Liberati A, Tetzlaff J, Altman DG, The PRISMA Group. Preferred reporting items for systematic reviews and meta-analyses: the PRISMA statement. *PLoS Med* 2009;6(7):e1000097.

[7] Seng P, Abat C, Rolain JM, et al. Identification of rare pathogenic bacteria in a clinical microbiology laboratory: impact of matrix-assisted laser desorption ionization-time of flight mass spectrometry. *J Clin Microbiol* 2013;51(7):2182–94.

[8] Farina C, Boiron P, Goglio A, Provost F. Human nocardiosis in Northern Italy from 1982 to 1992. *Scand J Infect Dis* 1995;27(1):23–7.

[9] Yildiz O, Alp E, Tokgoz B, et al. Nocardiosis in a teaching hospital in the Central Anatolia region of Turkey: treatment and outcome. *Clin Microbiol Infect* 2005;11(6):495–9.

[10] Kim YK, Sung H, Jung J, et al. Impact of immune status on the clinical characteristics and treatment outcomes of nocardiosis. *Diagn Microbiol Infect Dis* 2016;85(4):482–7.

[11] Shimada S, Iwai K. Subcutaneous abscess due to *Nocardia farcinica*. *Kansenshogaku Zasshi* 2010;84(2):206–9.

[12] Lerner PI. *Nocardia species*. 3rd ed New York: Churchill Livingstone; 1990. p. 891–903.

[13] Brown-Elliott BA, Brown JM, Conville PS, Wallace RJ. Clinical and laboratory features of the *Nocardia* spp. based on current molecular taxonomy. *Clin Microbiol Rev* 2006;19(2):259–82.

[14] Coussement J, Lebeaux D, van Delden C, et al. Nocardia infection in solid organ transplant recipients: a multicenter european case-control study. *Clin Infect Dis* 2016;63(3):338–45.

[15] Haussaire D, Fournier P-E, Djiguiba K, et al. Nocardiosis in the south of France over a 10-years period, 2004–2014. *Int J Infect Dis* 2017;57:13–20.

[16] Torres OH, Domingo P, Pericas R, Boiron P, Montiel JA, Vázquez G. Infection caused by *Nocardia farcinica*: case report and review. *Eur J Clin Microbiol Infect Dis* 2000;19(3):205–12.

[17] Budzik JM, Hosseini M, Mackinnon AC, Taxy JB. Disseminated *Nocardia farcinica*: literature review and fatal outcome in an immunocompetent patient. *Surg Infect* 2012;13(3):163–70.

[18] Posner JB. Clinical manifestations of brain metastasis. In: Weiss L, Gilbert HA, Posner JB, editors. *Brain metastasis*. Dordrecht: Springer Netherlands; 1980. p. 189–207 [cited 2020 Sep 27. Available from: [http://link.springer.com/10.1007/978-94-009-8799-9\\_11](http://link.springer.com/10.1007/978-94-009-8799-9_11)].

[19] Sonnevile R, Ruimy R, Benzonana N, et al. An update on bacterial brain abscess in immunocompetent patients. *Clin Microbiol Infect* 2017;23(9):614–20.

[20] Chiang I-C, Hsieh T-J, Chiu M-L, Liu G-C, Kuo Y-T, Lin W-C. Distinction between pyogenic brain abscess and necrotic brain tumour using 3-tesla MR spectroscopy, diffusion and perfusion imaging. *Br J Radiol* 2009;82(982):813–20.

[21] Miranda HA, Castellar Leones SM, Elzain MA, Moscote-Salazar LR. Brain abscess: current management. *J Neurosci Rural Pract* 2013;04(S 01):S67–81.

[22] Mut M, Hazer B, Narin F, Akalan N, Ozgen T. Aspiration or capsule excision? Analysis of treatment results for brain abscesses at single institute. *Turk Neurosurg* 2009;19(1):36–41.

[23] Rousseaux M, Lesoin F, Destee A, Jomin M, Petit H. Developments in the treatment and prognosis of multiple cerebral abscesses. *Neurosurgery* 1985;16(3):304–8.

[24] Sarmast AH, Showkat HI, Kirmani AR, et al. Aspiration versus excision: a single center experience of forty-seven patients with brain abscess over 10 years. *Neurol Med Chir (Tokyo)* 2012;52(10):724–30.

[25] Brouwer MC, Coutinho JM, van de Beek D. Clinical characteristics and outcome of brain abscess: systematic review and meta-analysis. *Neurology* 2014;82(9):806–13.

[26] Ratnaike TE, Das S, Gregson BA, Mendelow AD. A review of brain abscess surgical treatment – 78 years: aspiration versus excision. *World Neurosurg* 2011;76(5):431–6.

[27] Sperduto PW, Kased N, Roberge D, et al. Summary report on the graded prognostic assessment: an accurate and facile diagnosis-specific tool to estimate survival for patients with brain metastases. *J Clin Oncol* 2012;30(4):419–25.