



HAL
open science

Oestrus ovis conjunctival ophthalmomyiasis

M. Ahmed, F. Sardi, A. Ouadfel, H. Zemmouchi, E. Menu, D. Denis

► **To cite this version:**

M. Ahmed, F. Sardi, A. Ouadfel, H. Zemmouchi, E. Menu, et al.. Oestrus ovis conjunctival ophthalmomyiasis. *Journal Français d'Ophtalmologie*, 2022, 10.1016/j.jfo.2020.12.013 . hal-03678808

HAL Id: hal-03678808

<https://amu.hal.science/hal-03678808>

Submitted on 24 Jan 2023

HAL is a multi-disciplinary open access archive for the deposit and dissemination of scientific research documents, whether they are published or not. The documents may come from teaching and research institutions in France or abroad, or from public or private research centers.

L'archive ouverte pluridisciplinaire **HAL**, est destinée au dépôt et à la diffusion de documents scientifiques de niveau recherche, publiés ou non, émanant des établissements d'enseignement et de recherche français ou étrangers, des laboratoires publics ou privés.

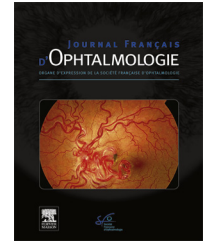


Disponible en ligne sur

ScienceDirect
www.sciencedirect.com

Elsevier Masson France

EM|consulte
www.em-consulte.com



LETTER TO THE EDITOR

Oestrus ovis conjunctival ophthalmomyiasis



Ophthalmomyiase conjonctivale à Oestrus ovis

Introduction

Human ophthalmomyiasis is generally a benign infection due to accidental parasitism of a larva of the order *Diptera*. Ophthalmomyiasis is qualified external when only superficial structures such as conjunctiva and cornea are involved; internal when the larvae manage to enter deeper structures (anterior chamber, choroid, vitreous body); orbital when orbital cavity is affected. In France, common reports happen in the South-Est of France as the disease is endemic in the Mediterranean basin. It is principally caused by *Oestrus ovis*, also called sheep nasal botfly, a fly depositing its larvae onto the eye after direct contact during late spring and summer. Because the fly naturally infects sheep and goats, human infections occur principally around rural areas, although urban cases have been described [1].

Case Presentation

In May 2020, a 46-year-old woman came to the emergency department of Hôpital Nord, Marseille, France, presenting with ocular pain and foreign body sensation. She reported ocular traumatism by penetration of a fly in her right eye few hours earlier while she was jogging in the hinterland of Marseille during sunset. The symptoms developed rapidly, and she could see small moving bodies in her right eye.

On examination, visual acuity was normal, slit-lamp examination showed a clear cornea, a normal conjunctiva on which white translucent larvae were moving toward the upper fornix fleeing the lamp light (Fig. 1), and a normal funduscopy. After local anesthesia, no mobility reduction of the larvae was noticed, and twenty-one larvae were removed using Bonn hook forceps. Specimens were sent to the Parasitology-Myology Laboratory of the Institut Hospitalo-Universitaire Méditerranée-Infection of Marseille. Microscopical examination of collected ectoparasites identified stage 1 *Oestrus ovis* larvae (L1). These whitish spindle larvae measure 1.5 mm. The morphological examination was consistent with the previous description [2] of the *Oestrus ovis* L1 as follows:

- a cephalic extremity with two buccal hooks;
- cuticular spines on each of the rings that make up their body;
- a posterior extremity with two tubercles (Fig. 2).

Treatment consisted of ocular wash twice a day and rifamycine eye drops four times a day. The patient was controlled 48 hours later and reported right eye lacrimation, nasal obstruction, rhinorrhea and sneezing. Visual acuity was unchanged and ophthalmological examination only showed follicular conjunctivitis on which no larva was found. Because of the rhinitis symptoms, a nasofibroscope was performed by an ENT physician on the same day and on the next one with no evidence of larvae. Despite the absence of evidence of nasal myiasis, one dose of ivermectin 200 µg/kg was prescribed.

One week later, ophthalmological and ENT examinations were normal.

Discussion

External ophthalmomyiasis is a cosmopolitan, rare and benign condition probably underestimated. Literature research found that between 1918 and 2017, 295 cases worldwide were reported [3]. The symptoms generally consist of ocular foreign body sensation, pain, redness and lacrimation [2]. Mechanical removal of all the larvae after local anesthesia is the main treatment. Although anesthesia is believed to slow the larvae, we did not see any changes in their mobility. Complications can happen if removal is not complete, allowing parasites to penetrate nasal fossae through lacrimal ducts or into the globe, leading to rhinitis or epistaxis in one hand and infectious uveitis in the other hand. This last complication can be sight threatening as the larvae might cause subretinal tracts in the retinal pigment epithelium in association with hemorrhages, exudative retinal detachment or even endophthalmitis [4].

Several fly species have been described causing ophthalmomyiasis, such as *Dermatobia* sp., *Gasterophilus* sp., *Cordylobia* sp., *Chrysomya*, sp. *Wohlfahrtia* sp., *Cochliomyia* sp., *Hypoderma* sp., and are the main differential diagnosis of *O. ovis* infection [5]. One other differential diagnosis consists of nematode infections, such as *Onchocerca volvulus* and *Loa loa*. In these cases, the diseases are transmitted through fly bites. During the human cycle, migration of the larvae or worms can lead to eye involvement: the parasites can be found under the conjunctiva, inside anterior chamber or even in the vitreous body [5]. Microscopic analysis of the maggots and PCR are helpful to set the diagnosis in doubt.

In this case, because the patient presented symptoms, which were compatible with nasal myiasis, we decided to introduce oral ivermectin 200 µg/kg as used to cure infected animals [6,7]. While we were writing this article, more cases presented to the Department of Ophthalmology,

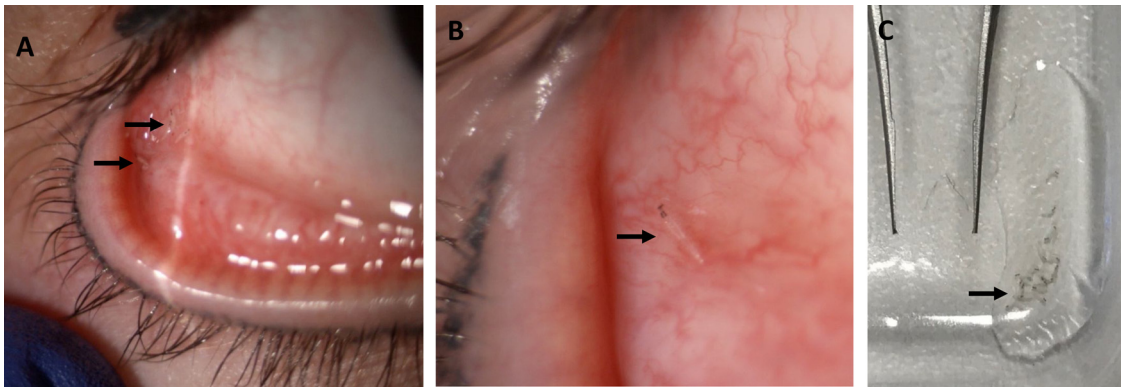


Figure 1. Clinical presentation of external ophthalmomyiasis showing larvae. A. Multiple white translucent larvae moving toward the upper conjunctival fornix after inferior eyelid eversion ($\times 10$ magnification). B. One larva in the inferior conjunctival fornix ($\times 16$ magnification). C. Aspect after removal using a Bonn hook forceps (smartphone photography).

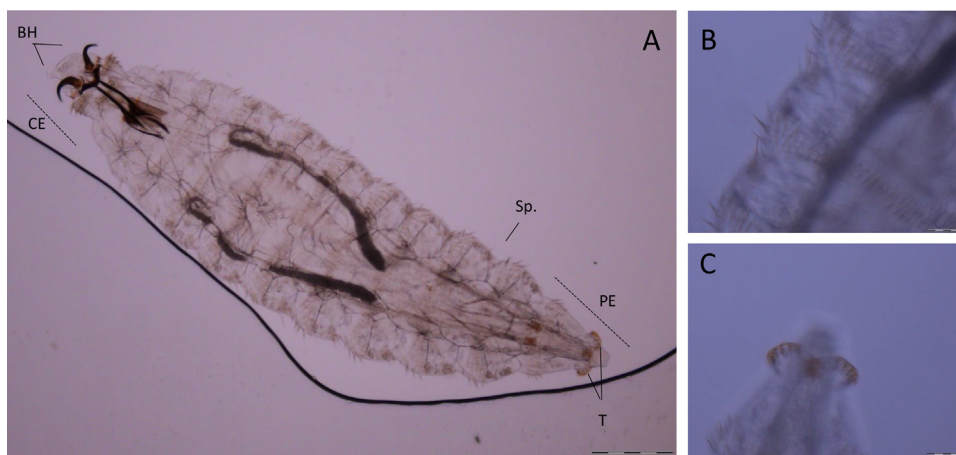


Figure 2. A. Microscopic observation of stage 1 *Oestrus ovis* larvae between slide and coverslip, using a $10\times$ objective (ce: cephalic extremity; BH: buccal hooks; PE: posterior extremity; T: tubercles; Sp.: spines.). B. Observation of spines throughout the body, using $100\times$ objective. C. Observation of the two tubercles on the posterior extremity, using $100\times$ objective.

whom one brought a larva expelled from its nasal fossae during sneezing, which happened to be *O. ovis* after analysis. This last patient was successfully treated with ivermectine too, and no adverse event was reported. Few reports described the use of ivermectine in order to treat ophthalmomyiasis [8,9], whereas its usage is easier by ENT physician for nasal myiasis as it is harder to remove all the larvae with nasofibroscope. One study even found that two doses of ivermectine were superior to manual extraction to treat nasal myiasis [10]. The authors suggest that ivermectine should be used in association with mechanical removal if there are symptoms compatible with rhinitis, impossibility to remove all the parasites or important infestation, such as this case with twenty-one larvae found.

Disclosure of interest

The authors declare that they have no competing interest.

References

- [1] Bonzon L, Toga I, Piarroux M, Piarroux R. Clustered cases of *Oestrus ovis* ophthalmomyiasis after 3-week festival, Marseille, France, 2013. *Emerg Infect Dis* 2015;21:375–7.
- [2] Anane S, Ben Hssine L. La myiase conjonctivale humaine à *Oestrus ovis* dans le sud tunisien. *Bull Soc Pathol Exot* 2010;103:299–304.
- [3] Basmaciyan L, Gabrielle P-H, Valot S, Sautour M, Buisson J-C, Creuzot-Garcher C, et al. *Oestrus ovis* external ophthalmomyiasis: a case report in Burgundy France. *BMC Ophthalmol* 2018;18:335.
- [4] Stagner AM, Jakobiec FA, Eagle RC, Charles NC. Infections of the eye and its adnexa. In: Kradin RL, editor. *Diagnostic pathology of infectious disease*. Second edition Elsevier; 2018. p. 648–85.
- [5] Malla N, Goyal K. Ocular Parasitic Infections – An Overview. *Adv Common Eye Infect* 2016, <http://dx.doi.org/10.5772/64137>.
- [6] Dorchies Ph, Alzieu JP, Cadiergues MC. Comparative curative and preventive efficacies of ivermectin and closantel on *Oestrus ovis* (Linné, 1758) in naturally infected sheep. *Vet Parasitol* 1997;72:179–84.
- [7] Lucientes J, Castillo JA, Ferrer LM, Peribáñez MA, Ferrer-Dufol M, Gracia-Salinas MJ. Efficacy of orally administered ivermectin against larval stages of *Oestrus ovis* in sheep. *Vet Parasitol* 1998;75:255–9.
- [8] Macdonald PJ, Chan C, Dickson J, Jean-Louis F, Heath A. Ophthalmomyiasis and nasal myiasis in New Zealand: a case series. *N Z Med J* 1999;112:445–7.

- [9] Taba KE, Vanchiere JA, Kavanaugh AS, Lusk JD, Smith MB. Successful treatment of ophthalmomyiasis interna posterior with ivermectin. *Retin Cases Brief Rep* 2012;6:91–4.
- [10] Sayeed A, Ahmed A, Sharma SC, Hasan SA, Ivermectin. A novel method of treatment of nasal and nasopharyngeal myiasis. *Indian J Otolaryngol Head Neck Surg* 2019;71:2019–24.

M. Ahmed^a, F. Sardi^b, A. Ouadfel^c, H. Zemmouchi^d, E. Menu^b, D. Denis^{a,*}

^a *Service d'ophtalmologie, hôpital Nord, centre hospitalier universitaire de l'hôpital Nord, chemin des Bourrely, 13015 Marseille, France*

^b *Université Aix-Marseille, IRD, APHM, MEPHI, IHU-Méditerranée Infection, 19-21, boulevard Jean-Moulin, 13005 Marseille, France*

^c *Service d'ophtalmologie, CHU Mohammed 6, Oujda, Morocco*

^d *Service d'ophtalmologie, centre hospitalier Henri-Duffaut, rue Raoul-Follereau, 84000 Avignon, France*

* Corresponding author.

E-mail address: daniele.denis@ap-hm.fr (D. Denis)
Available online 2 May 2022

<https://doi.org/10.1016/j.jfo.2020.12.013>

0181-5512/© 2021 Published by Elsevier Masson SAS.