



HAL
open science

Arcuate Fasciculus' middle and ventral temporal connections undercut by tract-tracing evidence

Yannick Becker, Kep Kee Loh, Olivier Coulon, Adrien Meguerditchian

► To cite this version:

Yannick Becker, Kep Kee Loh, Olivier Coulon, Adrien Meguerditchian. Arcuate Fasciculus' middle and ventral temporal connections undercut by tract-tracing evidence. *Brain - A Journal of Neurology*, 2022, pp.awac200. 10.1093/brain/awac200 . hal-03697244

HAL Id: hal-03697244

<https://amu.hal.science/hal-03697244v1>

Submitted on 16 Jun 2022

HAL is a multi-disciplinary open access archive for the deposit and dissemination of scientific research documents, whether they are published or not. The documents may come from teaching and research institutions in France or abroad, or from public or private research centers.

L'archive ouverte pluridisciplinaire **HAL**, est destinée au dépôt et à la diffusion de documents scientifiques de niveau recherche, publiés ou non, émanant des établissements d'enseignement et de recherche français ou étrangers, des laboratoires publics ou privés.

Arcuate Fasciculus' middle and ventral temporal connections undercut by tract-tracing evidence

Yannick Becker^{1,2}, Kep Kee Loh^{1,2}, Olivier Coulon², Adrien Meguerditchian^{1,3}

¹Laboratoire de Psychologie Cognitive, CNRS UMR 7290, Marseille, France

²Institut de Neurosciences de la Timone, Aix-Marseille Univ, CNRS UMR 7289, Marseille, France

³Station de Primatologie CNRS-CELPEDIA UAR846, 13790 Rousset, France

We are pleased to respond to the recent review article of Giampiccolo and Duffau (2022) published in *Brain* about the temporal terminations of the Arcuate Fasciculus (AF). The AF is regarded a major white matter pathway for language in the human brain¹. As such, there has been massive cross-disciplinary interest about the AF since its first discovery in the early 19th century. However, as highlighted in our recent review article², the anatomical definition of the Arcuate Fasciculus remains highly controversial, as its exact course and terminations, and how it differs between human versus nonhuman primate brains remain intensely debated in the literature.

Giampiccolo and Duffau³ had proposed a novel model of the AF's temporal connections based on recent evidence from clinical cases and direct electrical stimulation studies. Their model depicted more extensive AF temporal terminations that reach anterior-ventrally beyond the posterior superior temporal cortex, into the middle temporal gyrus, and the inferior/basal temporal cortex (Figure 1 left panel). While this model may have important clinical implications, it is based on methods that are limited in providing the "ground truth" delineation of the AF tract. Specifically, we contend that fundamental findings about the AF's temporal connections from monkey tract-tracing studies, the gold-standard methodology for detecting intercortical connections) are incongruent with Giampiccolo and Duffau's model³.

Precious knowledge about brain connections is derived from tract-tracing experiments in nonhuman primates, which many, including the authors themselves, acknowledge to be the gold-standard in the field⁴. Indeed, in contrast with other in-vivo techniques, the tract-tracing approach has the advantage to reveal mono-synaptic connections (i.e., direct, single-axonal connections from one neuron to another) between cortical areas, and is therefore, the only technique that can reveal the true course and terminations of a single continuous white matter tract, such as the AF. This method involves the injection of anatomical tracers into a living

brain, which are then transported by interconnecting axons from neurons in the injected site to other neurons. Critically, this is followed by histological analyses of the brain tissue post-mortem, in order to visualise the axons, and the cell bodies of the neurons that have been labelled by the injected tracers. Unfortunately, this technique, requiring both invasive in-vivo cortical injections, and the eventual sacrifice of the subject for post-mortem histological analyses, is virtually impossible to conduct in humans.

Based on tract-tracing experiments in macaque monkeys, the AF's temporal terminations rarely exceeds the posterior third of the superior temporal gyrus anteriorly (i.e., at the level of the Planum Temporale), and the ventral bank of the STS, ventrally (Figure 1 left panel⁴). Using dMRI tractography, recent researchers have performed the careful dissection of the human AF based on the macaque AF obtained via tract-tracing. This work had demonstrated that, in the human brain, the AF temporal terminations stay mostly in the posterior superior temporal gyrus/sulcus region (e.g.,⁵⁻⁸; Figure 1 left panel), which runs contrary to the revised model proposed by Giampiccolo and Duffau⁴ (Figure 1 right panel).

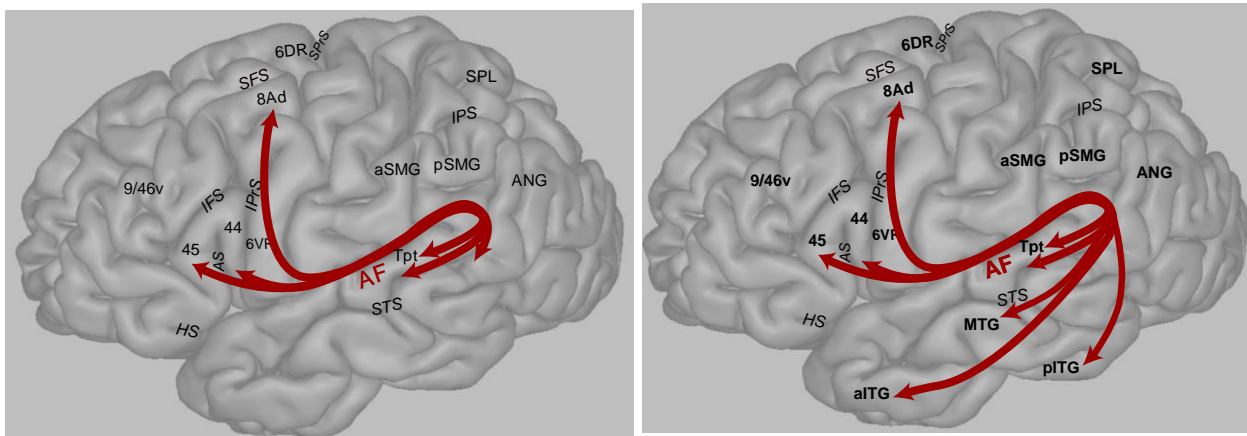


Figure 1 Contemporary Models of the AF fibre pathways in humans. *Left:* Macaque tract-tracing based human tractography model. Figure adapted from ², based on ⁴. *Right:* Giampiccolo and Duffau's model with extended temporal lobe terminations added onto the tract tracing model. AF=Arcuate Fasciculus; SFS=Superior Frontal Sulcus; SPrS=Superior Precentral Sulcus; IPrS=Inferior Precentral Sulcus; IFS=Inferior Frontal Sulcus; AS=Ascending branch of Sylvian Fissure; HS=Horizontal branch of Sylvian Fissure; IPS=Intra-Parietal Sulcus; Tpt=Temporal parietal area (BA22); aSMG=anterior Supra-Marginal Gyrus (BA40); pSMG=posterior Supra Marginal Gyrus (BA40); ANG=Angular Gyrus (BA39); SPL=Superior Parietal Lobule (BA7); MTG=Middle Temporal Gyrus; aITG=anterior Inferior Temporal Gyrus; pITG=posterior Inferior Temporal Gyrus

Without tract-tracing technique, the best modern-day approaches for delineating the human AF include dMRI tractography, blunt dissections, and direct electrical stimulation. Notably, Giampiccolo and Duffau³ had carefully derived their model from studies employing all these approaches. Nevertheless, we cannot ignore the fact that these methods do not allow the distinction of mono-synaptical from poly-synaptical connections (i.e., indirect connections that involve one or more interconnecting neurons). In other words, these methods are not able to disentangle the AF fibres from the other temporal fibre pathways that build synapses with the AF in the temporal lobe^{4, 9-10}. It is thus possible that the more anterior and ventral temporal gyrus terminations proposed by Giampiccolo and Duffau³, might not reflect monosynaptic connections from the AF, but interactions with between the AF and fibres from other temporal pathways. As such, we feel the authors should nuance their position that their revised AF model represents the true human AF and discuss the potential disagreements between their model and other recent models of the human AF that have been derived based on macaque tract tracing studies⁵⁻⁸.

In conclusion, the human AF model proposed by Giampiccolo and Duffau³ is based on the best available methods (dMRI tractography, electrical stimulation, blunt dissections) to study white matter connections in the human brain. These methods, unfortunately, do not warrant the detection of true monosynaptic connections, which is only possible using invasive tract-tracing techniques. Importantly, their model is incongruent with existing human AF models that are based on macaque tract-tracing knowledge⁴⁻⁸. As it stands, there is currently no method to determine which model depicts the true human AF, since tract-tracing studies are not possible in humans. Until that technology surfaces, the field is confronted with two competing hypotheses: 1) The human AF has indeed expanded anteriorly and ventrally into the middle and inferior temporal cortex as Giampiccolo and Duffau³ depicts; or 2) The human AF is homologous to that of the monkey AF, and Giampiccolo and Duffau's observations³ could be due to the fact that the human AF is entangled with other temporal tracts (e.g., the Inferior Longitudinal Fasciculus (ILF) Inferior Fronto-Occipital fasciculus (IFOF), the Middle Longitudinal Fasciculus (MdLF), Uncinate Fasciculus (UF), Extreme Capsule Fasciculus (ECF) etc.).

References:

1. Vavassori L, Sarubbo S, Petit L. Hodology of the superior longitudinal system of the human brain: a historical perspective, the current controversies, and a proposal. *Brain Struct Funct*. Published online April 21, 2021. doi:[10.1007/s00429-021-02265-0](https://doi.org/10.1007/s00429-021-02265-0)
2. Becker Y, Loh KK, Coulon O, Meguerditchian A. The Arcuate Fasciculus and language origins: Disentangling existing conceptions that influence evolutionary accounts. *Neuroscience & Biobehavioral Reviews*. 2022;134:104490. doi:[10.1016/j.neubiorev.2021.12.013](https://doi.org/10.1016/j.neubiorev.2021.12.013)
3. Giampiccolo D, Duffau H. Controversy over the temporal cortical terminations of the left arcuate fasciculus: a reappraisal. *Brain*. Published online February 10, 2022:awac057. doi:[10.1093/brain/awac057](https://doi.org/10.1093/brain/awac057)
4. Petrides M. *Neuroanatomy of Language Regions of the Human Brain*. First edition. Elsevier/AP, Academic Press is an imprint of Elsevier; 2014.
5. Barbeau EB, Descoteaux M, Petrides M. Dissociating the white matter tracts connecting the temporo-parietal cortical region with frontal cortex using diffusion tractography. *Scientific Reports*. 2020;10(1):8186. doi:[10.1038/s41598-020-64124-y](https://doi.org/10.1038/s41598-020-64124-y)
6. Frey S, Campbell JSW, Pike GB, Petrides M. Dissociating the Human Language Pathways with High Angular Resolution Diffusion Fiber Tractography. *J Neurosci*. 2008;28(45):11435-11444. doi:[10.1523/JNEUROSCI.2388-08.2008](https://doi.org/10.1523/JNEUROSCI.2388-08.2008)
7. Luo C, Makaretz S, Stepanovic M, et al. Middle longitudinal fascicle is associated with semantic processing deficits in primary progressive aphasia. *NeuroImage: Clinical*. 2020;25:102115. doi:[10.1016/j.nicl.2019.102115](https://doi.org/10.1016/j.nicl.2019.102115)
8. Makris N, Papadimitriou GM, Kaiser JR, Sorg S, Kennedy DN, Pandya DN. Delineation of the Middle Longitudinal Fascicle in Humans: A Quantitative, In Vivo, DT-MRI Study. *Cerebral Cortex*. 2009;19(4):777-785. doi:[10.1093/cercor/bhn124](https://doi.org/10.1093/cercor/bhn124)
9. Latini F, Trevisi G, Fahlström M, et al. New Insights Into the Anatomy, Connectivity and Clinical Implications of the Middle Longitudinal Fasciculus. *Front Neuroanat*. 2021;14:610324. doi:[10.3389/fnana.2020.610324](https://doi.org/10.3389/fnana.2020.610324)
10. Wang Y, Fernández-Miranda JC, Verstynen T, Pathak S, Schneider W, Yeh FC. Rethinking the Role of the Middle Longitudinal Fascicle in Language and Auditory Pathways. *Cerebral Cortex*. 2013;23(10):2347-2356. doi:[10.1093/cercor/bhs225](https://doi.org/10.1093/cercor/bhs225)