



Shoulder palsy following SARS-CoV-2 infection: two cases o typical Parsonage-Turner syndrome

Etienne Fortanier, Thomas Le Corroller, Marie Hocquart, Emilien Delmont, Shahram Attarian

► To cite this version:

Etienne Fortanier, Thomas Le Corroller, Marie Hocquart, Emilien Delmont, Shahram Attarian. Shoulder palsy following SARS-CoV-2 infection: two cases o typical Parsonage-Turner syndrome. European Journal of Neurology, 2022, 29 (8), pp.2548-2550. 10.1111/ene.15358 . hal-03780365

HAL Id: hal-03780365




<https://amu.hal.science/hal-03780365>

Submitted on 2 Mar 2023

HAL is a multi-disciplinary open access archive for the deposit and dissemination of scientific research documents, whether they are published or not. The documents may come from teaching and research institutions in France or abroad, or from public or private research centers.

L'archive ouverte pluridisciplinaire **HAL**, est destinée au dépôt et à la diffusion de documents scientifiques de niveau recherche, publiés ou non, émanant des établissements d'enseignement et de recherche français ou étrangers, des laboratoires publics ou privés.

Shoulder palsy following SARS-CoV-2 infection: two cases of typical Parsonage–Turner syndrome

Etienne Fortanier¹  | Thomas Le Corroller^{2,3} | Marie Hocquart⁴ | Emilien Delmont^{1,5}  | Shahram Attarian^{1,6} 

¹Reference Center for Neuromuscular Diseases and ALS, La Timone University Hospital, Aix-Marseille University, Marseille, France

²Radiology Department, APHM, Marseille, France

³Aix-Marseille University, CNRS, ISM UMR 7287, Marseille, France

⁴Aix-Marseille University, IRD, MEPHI, Marseille, France

⁵Aix-Marseille University, UMR 7286, Medicine Faculty, Marseille, France

⁶Aix-Marseille University, Inserm, GMGF, ERN-NMD, Marseille, France

Correspondence

Etienne Fortanier, Reference Center for Neuromuscular Diseases and ALS, La Timone University Hospital, Aix-Marseille University, 264 rue Saint Pierre, 13385 Marseille, France.
Email: etienne.fortanier@ap-hm.fr

Abstract

Background and purpose: Coronavirus disease 2019 (COVID-19) is now known to cause neurological complications in both the central and the peripheral nervous system. Two new cases of typical neuralgic amyotrophy or Parsonage–Turner (PT) syndrome following coronavirus 2 infection (SARS-CoV-2) are reported here with explicit electrophysiological and imaging pathological features, underlining the possible association between COVID-19 and PT syndrome.

Case reports: Case 1 was a 45-year-old schoolteacher presenting with acute pain in the right shoulder a few days after SARS-CoV-2 infection, with shoulder abduction and elbow flexion weakness. Needle electromyography showed a decrease in motor unit recruitment in the biceps brachii, and plexus magnetic resonance imaging (MRI) revealed a hyperintense signal involving the right C6 root and the superior truncus of the brachial plexus. Case 2 was a 21-year-old man hospitalized for dyspnea secondary to SARS-CoV-2 infection. Ten days after symptom onset, he presented right shoulder pain with difficulty in raising his right arm, revealing an isolated deficit of the serratus major muscle with a right scapula winging. Electrophysiological evaluation exhibited an isolated involvement of the long thoracic nerve with a neurogenic recruitment pattern in the serratus major muscle. Plexus MRI displayed a thickening and hyperintense signal involving the right long thoracic nerve.

Discussion: Parsonage–Turner syndrome triggered by SARS-CoV-2 seems to present clinical, electrophysiological and MRI characteristics similar to classic para-infectious PT syndrome, including the time frame between viral infection and neurological symptom onset.

Conclusion

SARS-CoV-2 might be a new infectious trigger of PT syndrome.

KEYWORDS

COVID-19, neuralgic amyotrophy, Parsonage–Turner syndrome, plexus MRI, SARS-CoV-2

INTRODUCTION

Neuralgic amyotrophy, also named Parsonage–Turner (PT) syndrome, is an acute painful monophasic peripheral nerve injury triggered by mechanical or infectious stress. In addition,

neuromuscular disorders such as Guillain–Barré syndrome [1] have been described in the setting of coronavirus disease 2019 (COVID-19).

Two acute painful shoulder weakness cases secondary to coronavirus 2 infection (SARS-CoV-2) are presented with

electrophysiological and plexus magnetic resonance imaging (MRI) abnormalities in favor of typical PT syndrome.

CASE DESCRIPTIONS

Case 1

A 45-year-old right-handed female schoolteacher was admitted for acute pain in the right shoulder, quickly followed by difficulty in raising her right arm. Her son was tested positive for SARS-CoV-2 infection 10 days before, and she also presented fever with a positive polymerase chain reaction nasopharyngeal swab test the same day.

Motor examination on the right side revealed weakness of shoulder abduction and elbow flexion (3/5 Medical Research Council grade). Right bicipital and brachioradialis reflexes were diminished. There was no other motor deficit, and sensory testing was strictly normal.

Spinal cord MRI and cerebrospinal fluid analyses were unremarkable. The electrophysiological evaluation performed 35 days after symptom onset showed preserved compound muscle action potential amplitudes in the right arm for the ulnar, median, axillary and musculocutaneous nerves and normal sensory evaluation including lateral and medial antebrachial cutaneous nerves. Electromyography showed acute denervation without spontaneous activity in the

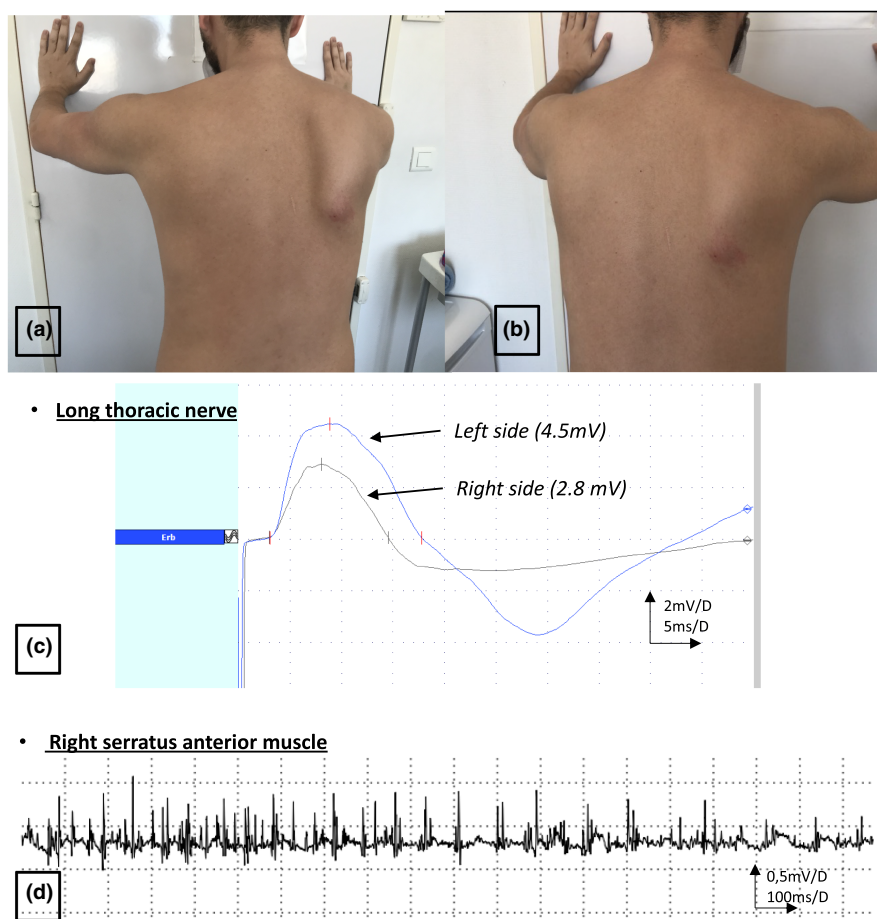
biceps brachi and the deltoid muscles. The plexus MRI revealed a persistent hyperintense signal involving the right C6 root and the superior truncus of the brachial plexus, without contrast enhancement. Other viral serologies (human immunodeficiency virus, cytomegalovirus, B19 parvovirus, hepatitis B, C and E) and antigangliosides antibodies were negative. She did not receive any treatment, and the evolution was favorable, with a complete disappearance of the symptoms 3 months later.

Case 2

A 21-year-old right-handed man complained of headache, nausea and fever. He was hospitalized 8 days later due to breathing difficulties. The polymerase chain reaction swab test was positive for SARS-CoV-2 infection.

Ten days after COVID-19 symptom onset, he presented with severe right shoulder pain, associated with difficulty in raising the right arm. Right shoulder computed tomography scan found no abnormality. The neurological evaluation found an isolated deficit of the serratus major muscle associated with a right scapula winging ([Figure 1a](#)). There was no sensory deficit, and the osteotendinous reflexes were all present.

Electrophysiological evaluation performed 5 days later showed an isolated involvement of the right long thoracic nerve with reduced



compound muscle action potential amplitudes compared to the left (2.8 vs. 4.5 mV, [Figure 1c](#)) and a neurogenic recruitment pattern in the right serratus muscle without spontaneous activity ([Figure 1d](#)). Motor and sensory evaluations were normal in ulnar, median, axillary, anterior interosseous, radial, lateral and medial antebrachial cutaneous nerves.

Plexus MRI showed a thickening and hyperintense signal involving the right long thoracic nerve within the scalenus medius muscle. Oral prednisone at 1 mg/kg was initiated for 7 days, followed by rapid tapering. Examination 4 months after symptom onset still showed an isolated partial deficit of the serratus major muscle with a slight improvement of the winged scapula ([Figure 1b](#)) but persistent pain in the right shoulder.

DISCUSSION

Coronavirus disease 2019 is now known to cause neurological complications in almost 9% of cases [2]. Two new cases of PT syndrome following SARS-CoV-2 infection with explicit electrophysiological and imaging pathological features are reported, underlining the possible association between COVID-19 and PT syndrome.

To our knowledge, only a few cases of PT syndrome in the setting of COVID-19 have been detailed so far in the literature [3–7]. Only two of these cases showed typical brachial plexus involvement [3,4]. Other previous reports consisted of a sole median nerve alteration [5], a pure sensory deficit with left lateral antebrachial cutaneous electrophysiological abnormalities [6] and an isolated weakness of the trapezius muscle [7].

The physiopathology of PT syndrome is not entirely understood. Molecular mimicry is suspected in PT syndrome following viral infections. As in these two cases, the time frame between viral infection and neurological symptoms is usually around 10 days, suggesting immune-mediated mechanisms triggered by the infection. A direct viral neuroinvasion has been suspected in cases where neurological symptoms occurred more rapidly during infection [3].

Our two cases do not allow us to conclude the exact relation between COVID-19 and PT syndrome, but the temporal relation between infection and neurological symptoms may suggest a para-infectious pathogenesis. More extensive case-control studies are now required to better understand the biological process leading to PT syndrome in such cases.

In conclusion, these two cases with classic clinical, MRI and electrophysiological findings are in favor of a typical PT syndrome triggered by SARS-CoV-2 infection.

CONFLICT OF INTEREST

The authors have no conflicts of interest to declare that are relevant to the content of this article.

AUTHOR CONTRIBUTIONS

Etienne Fortanier: Conceptualization (equal); investigation (lead); writing—original draft (lead); writing—review and editing (lead). Thomas Le Corroller: Data curation (equal); resources (equal); software (equal). Marie Hocquart: Data curation (equal); investigation (equal). Emilien Delmont: Conceptualization (equal); data curation (lead); formal analysis (lead); supervision (equal); writing—review and editing (equal). Shahram Attarian: Conceptualization (equal); supervision (lead); validation (equal); writing—review and editing (equal).

DATA AVAILABILITY STATEMENT

The data that support the findings of this study are available from the corresponding author upon reasonable request.

ORCID

Etienne Fortanier  <https://orcid.org/0000-0003-2797-9389>

Emilien Delmont  <https://orcid.org/0000-0002-5591-2774>

Shahram Attarian  <https://orcid.org/0000-0002-7211-4694>

REFERENCES

1. Abu-Rumeileh S, Abdelhak A, Foschi M, Tumani H, Otto M, Guillain-Barré syndrome spectrum associated with COVID-19: an up-to-date systematic review of 73 cases. *J Neurol*. 2021;268(4):1133–1170. doi: [10.1007/s00415-020-10124-x](https://doi.org/10.1007/s00415-020-10124-x)
2. Mao L, Jin H, Wang M, et al. Neurologic manifestations of hospitalized patients with coronavirus disease 2019 in Wuhan, China. *JAMA Neurol*. 2020;77(6):683–690. doi: [10.1001/jamaneurol.2020.1127](https://doi.org/10.1001/jamaneurol.2020.1127)
3. Ismail II, Abdelnabi EA, Al-Hashel JY, Alroughani R, Ahmed SF. Neuralgic amyotrophy associated with COVID-19 infection: a case report and review of the literature. *Neurol Sci*. 2021;42(6):2161–2165. doi: [10.1007/s10072-021-05197-z](https://doi.org/10.1007/s10072-021-05197-z)
4. Mitry MA, Collins LK, Kazam JJ, Kaicker S, Kovanlikaya A. Parsonage–Turner syndrome associated with SARS-CoV-2 (COVID-19) infection. *Clin Imaging*. 2021;72:8–10. doi: [10.1016/j.clinimag.2020.11.017](https://doi.org/10.1016/j.clinimag.2020.11.017)
5. Siepmann T, Kitzler HH, Lueck C, Platzek I, Reichmann H, Barlinn K. Neuralgic amyotrophy following infection with SARS-CoV-2. *Muscle Nerve*. 2020;62(4):E68–E70. doi: [10.1002/mus.27035](https://doi.org/10.1002/mus.27035)
6. Cacciavillani M, Salvalaggio A, Briani C. Pure sensory neuralgic amyotrophy in COVID-19 infection. *Muscle Nerve*. 2021;63(1):E7–E8.
7. Coll C, Tessier M, Vandendries C, Seror P. Neuralgic amyotrophy and COVID 19 infection: 2 cases of spinal accessory nerve palsy. *Joint Bone Spine*. 2021;88(5):105196.

How to cite this article: Fortanier E, Le Corroller T, Hocquart M, Delmont E, Attarian S. Shoulder palsy following SARS-CoV-2 infection: two cases of typical Parsonage–Turner syndrome. *Eur J Neurol*. 2022;29:2548–2550. doi: [10.1111/ene.15358](https://doi.org/10.1111/ene.15358)