



**HAL**  
open science

**Correspondence on: ‘Dupilumab as a novel  
steroid-sparing treatment for IgG 4 -related disease’ by  
Simpson et al**

Mikael Ebbo, Benjamin de Sainte-Marie, Romain Muller, Christelle  
Piperoglou, Aurélie Grados, Frédéric Vély, Nicolas Schleinitz

► **To cite this version:**

Mikael Ebbo, Benjamin de Sainte-Marie, Romain Muller, Christelle Piperoglou, Aurélie Grados, et al.. Correspondence on: ‘Dupilumab as a novel steroid-sparing treatment for IgG 4 -related disease’ by Simpson et al. *Annals of the Rheumatic Diseases*, 2022, 81 (2), pp.e26-e26. 10.1136/annrheumdis-2020-217010 . hal-03933642

**HAL Id: hal-03933642**

**<https://amu.hal.science/hal-03933642>**

Submitted on 10 Jan 2023

**HAL** is a multi-disciplinary open access archive for the deposit and dissemination of scientific research documents, whether they are published or not. The documents may come from teaching and research institutions in France or abroad, or from public or private research centers.

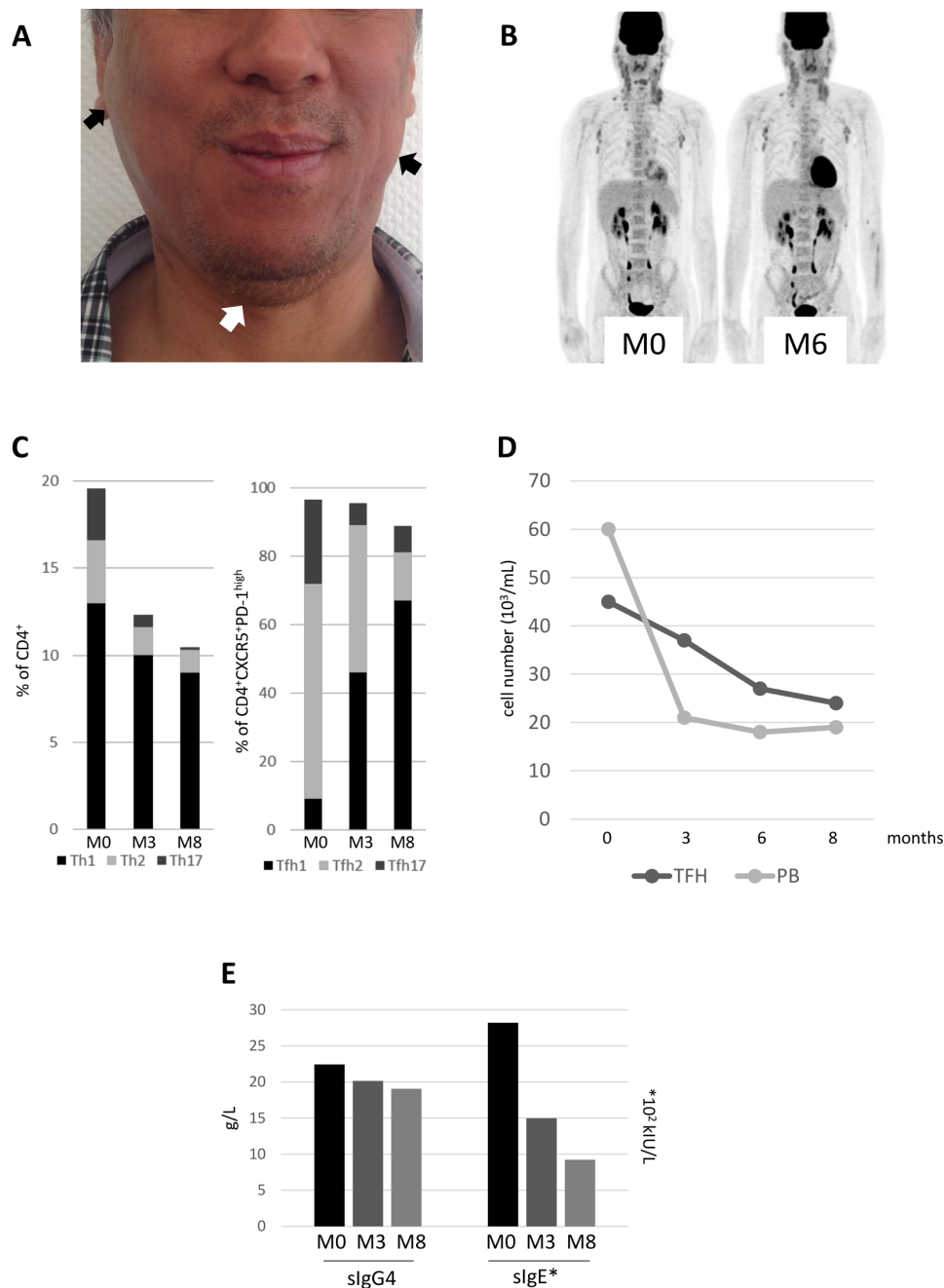
L’archive ouverte pluridisciplinaire **HAL**, est destinée au dépôt et à la diffusion de documents scientifiques de niveau recherche, publiés ou non, émanant des établissements d’enseignement et de recherche français ou étrangers, des laboratoires publics ou privés.

## Correspondence on: 'Dupilumab as a novel steroid-sparing treatment for IgG<sub>4</sub>-related disease' by Simpson *et al*

We read with interest the letter by Simpson *et al* reporting the use of dupilumab in a patient with IgG<sub>4</sub>-related disease (IgG<sub>4</sub>-RD).<sup>1</sup> Indeed blocking the IL-4/IL-13 pathway is tempting, considering

the roles of these cytokines and the physiopathological changes observed during IgG<sub>4</sub>-RD.<sup>2,3</sup>

We have also treated with dupilumab a 51-year-old man with IgG<sub>4</sub>-related dacryoadenitis and sialadenitis (bilateral lacrimal, parotid, sublingual and submandibular involvement, pattern of Mikulicz syndrome). Left submandibular salivary gland and two cervical lymph nodes biopsies concluded, respectively, to lymphoplasmacytic polyclonal infiltration and reactive hyperplasia.



**Figure 1** (A) Patient's initial clinical findings before dupilumab treatment showed bilateral parotid (black arrows), sublingual (white arrow), submandibular glands and cervical lymph nodes involvements. (B) <sup>18</sup>FDG-PET/CT scan before and 6 months after dupilumab treatment alone showed no improvement of salivary glands and lymph nodes involvements. (C) Proportion over time under dupilumab of T helper (Th)1 (IFN $\gamma$ <sup>+</sup>), Th2 (IL4<sup>+</sup>) and Th17 (IL17<sup>+</sup>) cells among T CD3<sup>+</sup>CD4<sup>+</sup> cells; and proportion over time under dupilumab of T follicular helper (Tfh)1 (CD4<sup>+</sup>CXCR5<sup>+</sup>PD-1<sup>high</sup>CXCR3<sup>+</sup>CCR6<sup>+</sup>), Tfh2 (CD4<sup>+</sup>CXCR5<sup>+</sup>PD-1<sup>high</sup>CXCR3<sup>+</sup>CCR6<sup>+</sup>) and Tfh17 (CD4<sup>+</sup>CXCR5<sup>+</sup>PD-1<sup>high</sup>CXCR3<sup>+</sup>CCR6<sup>+</sup>) cells among Tfh (CD4<sup>+</sup>CXCR5<sup>+</sup>PD-1<sup>high</sup>) cells. (D) Absolute plasmablast (PB) (CD19<sup>+</sup>CD27<sup>high</sup>CD38<sup>high</sup>) and Tfh (CD4<sup>+</sup>CXCR5<sup>+</sup>PD-1<sup>high</sup>) count (10<sup>3</sup>/mL) at baseline (month 0) and under dupilumab (months 3, 6 and 8). (E) Serum IgG<sub>4</sub> (g/L) and IgE (10<sup>2</sup> kIU/L) levels at baseline (month 0) and under dupilumab (months 3 and 8). IFN $\gamma$ , interferon gamma; IL4, interleukin-4.

## Correspondence

Immunohistochemistry was only available on lymph nodes, showing an IgG<sub>4</sub><sup>+</sup>/CD138<sup>+</sup> plasma cells ratio over 40% with 40 IgG<sub>4</sub><sup>+</sup> plasma cells/high power field. Serum IgG<sub>4</sub> and IgE levels were found to be 17.7 g/L (normal range <0.8 g/L) and 3499 kIU/L (normal range <100 kIU/L), respectively, with normal complete blood count, liver and renal function tests. According to the 2019 American College of Rheumatology/European League Against Rheumatism classification criteria for IgG<sub>4</sub>-RD, entry criteria were met, no exclusion criteria were present, and the total points score was 29 (≥20).<sup>4</sup> Clinical and radiological evaluation revealed no other IgG<sub>4</sub>-related involvement, except for cervical and axillary lymph nodes (figure 1A,B). The patient had cervical marked discomfort without sicca syndrome. Salivary glands and lymph nodes involvement improved after a 3 months steroid course but relapsed. A second course of steroids was associated with rituximab (two infusions of 1000 mg, 15 days apart) with clinical, biological (serum IgG<sub>4</sub> level reduced to 7.59 g/L) and radiological response, but a new relapse occurred 1 year later. Because the patient also presented chronic rhinosinusitis with nasal polyps, a medical history of asthma and urticarial manifestations, a treatment with dupilumab was introduced without any other treatment, with an initial 600 mg subcutaneous injection, followed by a 300 mg subcutaneous injection every other week for 8 months. Rapidly the patient reported improvement of allergic rhinitis manifestations, but after an 8 months treatment course with dupilumab, salivary gland and lymph nodes involvements remained unchanged on clinical and radiological evaluation (figure 1B). Blood evaluation showed under dupilumab a decrease of total T helper 2 cells, T follicular helper (Tfh) cells, Tfh2 cells and plasmablasts after 3 and 8 months of treatment (figure 1C,D). Serum IgE significantly declined, but serum IgG<sub>4</sub> only slightly decreased during the treatment (figure 1E).

Glucocorticoids are the first line agent for remission induction in patients with IgG<sub>4</sub>-RD, with a high rate of response but frequent relapse during tapering or after discontinuation.<sup>5</sup> Different maintenance therapy has been proposed, such as low-dose steroids, conventional steroid-sparing medications (azathioprine, mycophenolate mofetil, methotrexate) or rituximab, with different profiles of efficacy and side effects. In the case reported by Simpson *et al*, prednisone was administered initially during 2 months. We think that the initial clinical and biological response reported by Simpson *et al* could be attributable to steroids rather than to dupilumab, and that the radiological response presented at 12 months (and not assessed at 3 months) should be analysed cautiously. Indeed, in our patient, we observed no clinical nor radiological improvement after an 8-month course of dupilumab alone without steroids. However, we observed significant and interesting immunological improvements, with a marked decrease of Tfh2 cells and plasmablasts, which have been both correlated with disease activity,<sup>2 3 6</sup> despite the fact that serum IgG<sub>4</sub> remained fairly stable. We think that these observations taken together suggest that dupilumab could

be an interesting and well tolerated therapeutic approach in IgG<sub>4</sub>-RD, but rather as relapse-free maintenance therapy after induction treatment. This strategy should be further evaluated in a dedicated clinical trial.

Mikael Ebbo <sup>1,2</sup>, Benjamin De Sainte-Marie,<sup>1</sup> Romain Muller,<sup>1</sup> Christelle Piperoglou,<sup>3</sup> Aurélie Grados,<sup>4</sup> Frédéric Vély,<sup>2,3</sup> Nicolas Schleinitz<sup>1,2</sup>

<sup>1</sup>Internal Medicine, AP-HM, Hôpital de la Timone, Marseille, France

<sup>2</sup>Aix Marseille Univ, CNRS, INSERM, CIML, Marseille, France

<sup>3</sup>Immunology, AP-HM, Hôpital de la Timone, Marseille, France

<sup>4</sup>Internal Medicine, Centre hospitalier de Niort, Niort, France

**Correspondence to** Dr Mikael Ebbo, Internal Medicine, AP-HM, Hôpital de la Timone, Marseille, France; mikael.ebbo@ap-hm.fr

**Contributors** ME and NS: conceived the hypothesis, analysed data and drafted the manuscript. BDS-M, RM, AG and FV: analysed data, critically revised the manuscript and gave the final approval. CP: acquisition of data, critically revised the manuscript and gave the final approval.

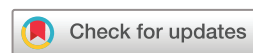**Funding** The authors have not declared a specific grant for this research from any funding agency in the public, commercial or not-for-profit sectors.

**Competing interests** None declared.

**Patient consent for publication** Not required.

**Provenance and peer review** Not commissioned; internally peer reviewed.

© Author(s) (or their employer(s)) 2022. No commercial re-use. See rights and permissions. Published by BMJ.



**To cite** Ebbo M, De Sainte-Marie B, Muller R, *et al*. *Ann Rheum Dis* 2022;**81**:e26.

Received 17 January 2020

Accepted 20 January 2020

Published Online First 29 January 2020



► <http://dx.doi.org/10.1136/annrheumdis-2020-217029>

*Ann Rheum Dis* 2022;**81**:e26. doi:10.1136/annrheumdis-2020-217010

#### ORCID iD

Mikael Ebbo <http://orcid.org/0000-0002-1179-8113>

#### REFERENCES

- 1 Simpson RS, Lau SKC, Lee JK. Dupilumab as a novel steroid-sparing treatment for IgG<sub>4</sub>-related disease. *Ann Rheum Dis* 2020;**79**:549–50.
- 2 Grados A, Ebbo M, Piperoglou C, *et al*. T cell polarization toward TH2/TFH2 and TH17/TFH17 in patients with IgG<sub>4</sub>-related disease. *Front Immunol* 2017;**13**:235.
- 3 Akiyama M, Suzuki K, Yamaoka K, *et al*. Number of circulating follicular helper 2 T cells correlates with IgG<sub>4</sub> and interleukin-4 levels and Plasmablast numbers in IgG<sub>4</sub>-related disease. *Arthritis Rheumatol* 2015;**67**:2476–81.
- 4 Wallace ZS, Naden RP, Chari S, *et al*. The 2019 American College of Rheumatology/ European League against rheumatism classification criteria for IgG<sub>4</sub>-related disease. *Ann Rheum Dis* 2020;**79**:77–87.
- 5 Khosroshahi A, Wallace ZS, Crowe JL, *et al*. International consensus guidance statement on the management and treatment of IgG<sub>4</sub>-related disease. *Arthritis Rheumatol* 2015;**67**:1688–99.
- 6 Wallace ZS, Mattoo H, Carruthers M, *et al*. Plasmablasts as a biomarker for IgG<sub>4</sub>-related disease, independent of serum IgG<sub>4</sub> concentrations. *Ann Rheum Dis* 2015;**74**:190–5.