



**HAL**  
open science

## Early dynamic changes within the spine following posterior fusion using hybrid instrumentation in adolescents with idiopathic scoliosis: a gait analysis study

Sébastien Pesenti, Solene Prost, Vincent Pomeroy, Guillaume Authier, Matthieu Severyns, Lionel Roscigni, Christophe Boulay, Benjamin Blondel, Jean-Luc Jouve

### ► To cite this version:

Sébastien Pesenti, Solene Prost, Vincent Pomeroy, Guillaume Authier, Matthieu Severyns, et al.. Early dynamic changes within the spine following posterior fusion using hybrid instrumentation in adolescents with idiopathic scoliosis: a gait analysis study. Archives of orthopaedic and traumatic surgery. Archiv fur orthopadische und Unfall-Chirurgie, 2022, 142 (12), pp.3613-3621. 10.1007/s00402-021-03956-3 . hal-03991637

**HAL Id: hal-03991637**

**<https://amu.hal.science/hal-03991637>**

Submitted on 12 Apr 2023

**HAL** is a multi-disciplinary open access archive for the deposit and dissemination of scientific research documents, whether they are published or not. The documents may come from teaching and research institutions in France or abroad, or from public or private research centers.

L'archive ouverte pluridisciplinaire **HAL**, est destinée au dépôt et à la diffusion de documents scientifiques de niveau recherche, publiés ou non, émanant des établissements d'enseignement et de recherche français ou étrangers, des laboratoires publics ou privés.

# Early dynamic changes within the spine following posterior fusion using hybrid instrumentation in adolescents with idiopathic scoliosis: a gait analysis study

Sébastien Pesenti<sup>1,2,3</sup>  · Solene Prost<sup>1,2,3</sup> · Vincent Pomeroy<sup>2</sup> · Guillaume Authier<sup>2</sup> · Matthieu Severyns<sup>1</sup> · Lionel Roscigni<sup>1,2</sup> · Christophe Boulay<sup>1,2,3</sup> · Benjamin Blondel<sup>1,2,3</sup> · Jean-Luc Jouve<sup>1,2</sup>

## Abstract

**Introduction** In adolescent idiopathic scoliosis (AIS) patients, mechanical consequences of posterior spinal fusion within the spine remain unclear. Through dynamic assessment, gait analysis could help elucidating this particular point. The aim of this study was to describe early changes within the spine following fusion with hybrid instrumentation in adolescents with idiopathic scoliosis, using gait analysis

**Materials and methods** We conducted a single-centre prospective study including AIS patients scheduled for posterior spinal fusion (PSF) using hybrid instrumentation with sublaminar bands. Patients underwent radiographic and gait analyses preoperatively and during early postoperative period. Among gait parameters, motion of cervicothoracic, thoracolumbar and lumbosacral junctions was measured in the three planes.

**Results** We included 55 patients (mean age 15 years, 84% girls). Fusion was performed on 12 levels and mean follow-up was 8 months. There was a moderately strong correlation between thoracolumbar sagittal motion and lumbosacral junction pre- and postoperatively ( $R = -0.6413$  and  $R = -0.7040$ , respectively, all  $p < 0.001$ ), meaning that the more thoracolumbar junction was in extension, the more lumbosacral extension movements decreased. There was a trend to significance between postoperative SVA change and thoracolumbar sagittal motion change ( $R = -0.2550$ ,  $p = 0.059$ ).

**Discussion** This is the first series reporting dynamic changes within the spine following PSF using hybrid instrumentation in AIS patients. PSF led to symmetrization of gait pattern. In the sagittal plane, we found that thoracolumbar extension within the fused area led to decreased extension at cervicothoracic and lumbosacral junctions. Even though consequences of such phenomenon are unclear, attention must be paid not to give a too posterior alignment when performing PSF for AIS patients.

**Keywords** Adolescent idiopathic scoliosis · Gait analysis · Posterior spinal fusion · Sublaminar bands · Hybrid instrumentation · Segmental analysis

## Introduction

Adolescent idiopathic scoliosis (AIS) is the most common spinal condition encountered in children and adolescents. It has been reported that 2–3% of the population was concerned by this three-dimensional spinal deformity [1]. Vertebral rotation is the princeps deformity, causing the classical S-shaped coronal deviation of the spine. Sagittal disorders are regularly seen, with frequent flattening of sagittal curvatures of the spine. AIS occurs during late childhood or adolescence, with a peak of progression during growth spurt. Nevertheless, it was reported that deformity can worsen during adulthood, especially when curve was very progressive during adolescence [2].

---

✉ Sébastien Pesenti  
seb.pesenti@gmail.com

<sup>1</sup> Pediatric Orthopedics, Timone Enfants, Aix Marseille University, 264 rue Saint Pierre, 13005 Marseille, France

<sup>2</sup> Gait Analysis Laboratory, Timone, Aix Marseille University, Marseille, France

<sup>3</sup> Orthopédie Infantile, CNRS, ISM, Aix-Marseille Université, Hôpital de La Timone, AP-HM, Marseille, France

If so, surgical treatment is recommended to prevent curve worsening.

To date, posterior spinal fusion (PSF) is the gold standard treatment for progressive AIS. In addition of obtaining intervertebral fusion, it mainly aims to correct spinal coronal deformity. However, it is known that it is of major importance to restore sagittal plane as well, as sagittal malalignment has been reported to be the most disabling condition in adults [3]. Long-term effects of spinal fusion are satisfying even if some authors have raised concerns about disc degeneration appearing on MRI, most of the time without clinical symptoms [4]. However, mechanical consequences of such treatment within the spine remain unclear. Static assessment with standard radiographs appears to be incomplete to investigate this particular area [5]. Moreover, some of major radiographic parameters, such as sagittal vertical axis, seem to be uncorrelated to daily-life spine functioning, and therefore, may be misleading when trying to understand dynamic consequences of spinal fusion.

During the past 3 decades, quantitative gait analysis has been largely developed. Several studies show its ability to describe trunk motion [6, 7]. Some authors have described gait impairment in AIS patients, either preoperatively or after spinal fusion [8–12]. But to the best of our knowledge, most of reported results used protocols considering the spine as a unique rigid segment, whereas in reality, this is a polyarticular chain. In 2012, we developed a gait analysis protocol able to catch motion within the spine by adding 4 markers to the classic Helen Hayes protocol [13]. This protocol has shown good reproducibility and reliability to classical radiographic parameters [14, 15].

Therefore, the aim of this study was to describe early changes within different spinal segments following spinal fusion with hybrid instrumentation in adolescents with idiopathic scoliosis, using gait analysis.

## Materials and methods

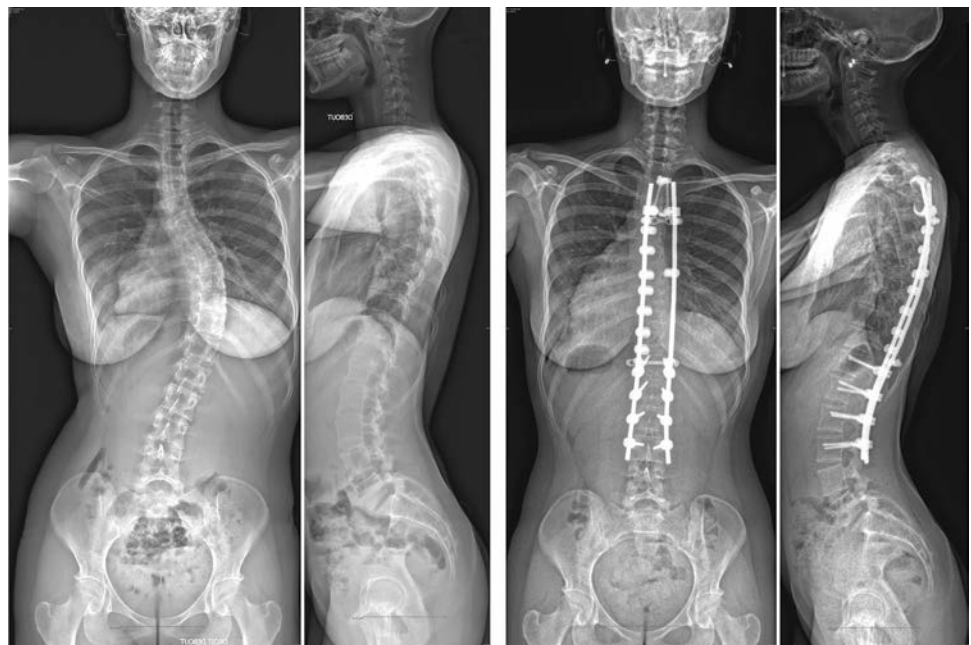
### Ethics statement and study design

From 2017 to 2019, we conducted a single-centre prospective study. Prior to inclusion, we obtained approval from our institutional ethics committee. Informed consent was obtained from patients and their legal representative. We enrolled patients aged under 18 years and scheduled for surgical correction of AIS. In our institution, protocol calls for surgery when Cobb angle is over  $45^\circ$  in the thoracic area and  $35^\circ$  in the lumbar area. Patients with previous spine surgery, history of major trauma or orthopaedic condition or transitional vertebrae were excluded from our study.

### Surgical procedure

Patients underwent surgical correction using posterior spinal fusion with hybrid instrumentation (Fig. 1). Distal limit of fusion was set at the stable vertebra. A standard midline posterior approach was performed. Bilateral lamino-laminar claw was set on the two upper instrumented vertebrae. Then pedicle screws were inserted in the lumbar area, and two 5.5 titanium rods were connected. In the thoracic area, sublaminar polyester bands were passed at every thoracic vertebra, connected to the concave rod and finally gradually tightened

**Fig. 1** Clinical example of a 16-year-old adolescent girl before (left) and after surgical correction using hybrid instrumentation (right). The surgery lead to an increase of thoracic kyphosis by  $20^\circ$  associated with a coronal correction rate of 74%



to pull the spine in a posteromedial direction (posteromedial translation technique). First erect was allowed from postoperative day 1 and early rehabilitation was started. Patients were not asked to wear a brace postoperatively.

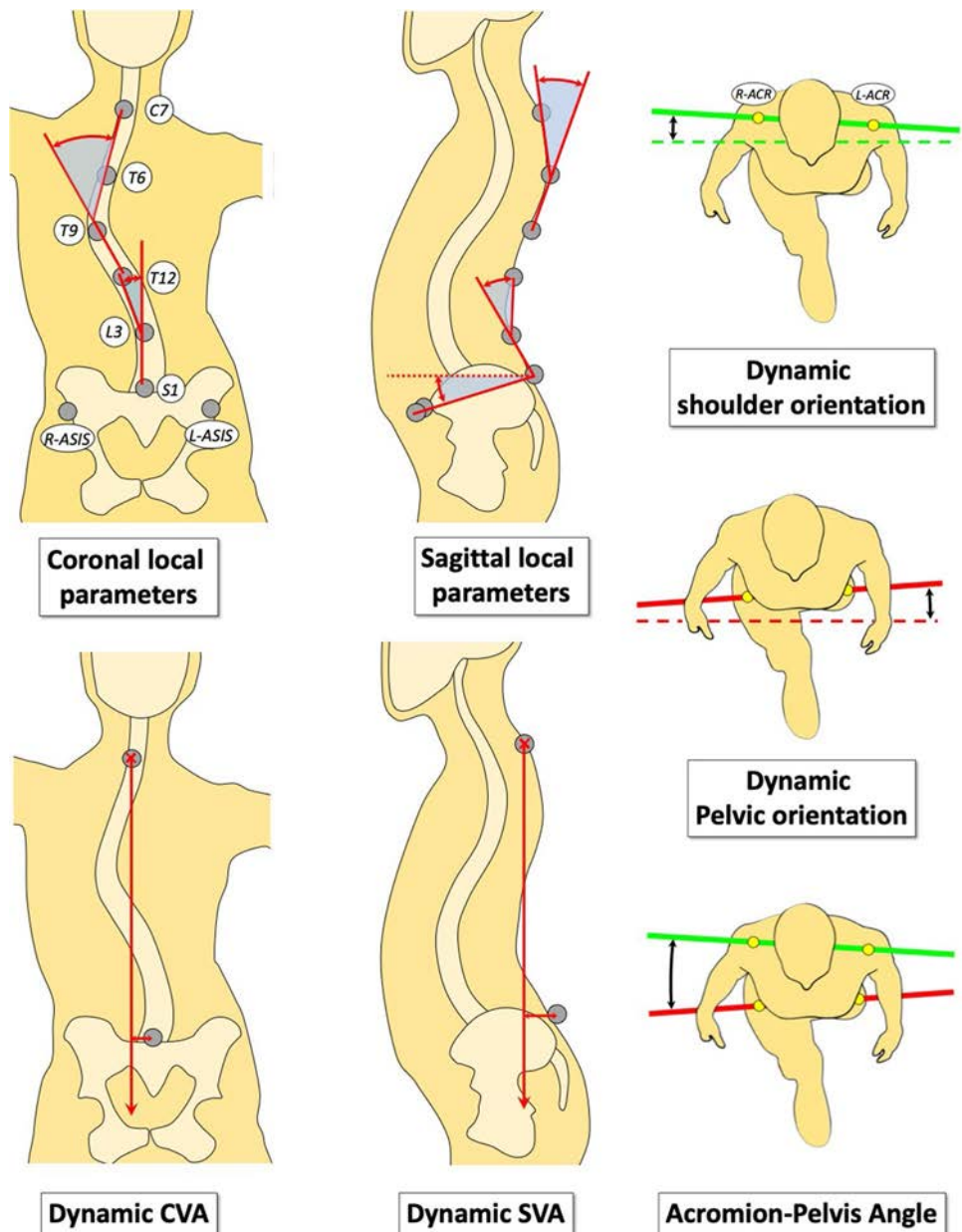
### Study protocol

Patients underwent radiographs and gait analysis the day before surgery and at early postoperative stage, between 3 and 12 months after surgery. Several parameters were measured on full standing anteroposterior and lateral radiographs. On AP view, we assessed Cobb angles, the Coronal Vertical Axis (CVA) and clavicle angle, and on lateral view, the Sagittal Vertical Axis (SVA), the C2–C7 cervical lordosis, the

T2–T12 thoracic kyphosis, the L1–S1 lumbar lordosis, the T10–L2 thoracolumbar lordosis and finally pelvic parameters (pelvic incidence, pelvic tilt and sacral slope).

Concerning gait analysis, we used the 36 marker-protocol we described in 2012, including 6 markers for spine assessment. Markers motion was caught by 6 HiRes infrared cameras. Patients were asked to walk barefoot on a 9-m walkway, at a self-selected speed. Several parameters were measured (Fig. 2). In the frontal plane, we measured Dynamic Thoracic and lumbar Cobb angle and Dynamic CVA. In the sagittal plane, we assessed Dynamic Thoracic kyphosis, Dynamic Lumbar lordosis, Dynamic Pelvic tilt and Dynamic SVA. Finally, in the transversal plane, we measured Dynamic Shoulder-line rotation, Dynamic Pelvic

**Fig. 2** Gait parameters calculating using the Blondel et al. protocol



rotation and Acromio-Pelvis Angle (APA). In addition, spine parameters were measured at the cervicothoracic (CTh), thoracolumbar (ThL) and lumbosacral (LS) junctions in the 3 planes of the space: coronal (lateral bending), sagittal (flexion–extension) and transversal (torsion). CTh was the relative motion of Vertex-C7 line with regards to C7–T12 line; ThL was the relative motion of C7–T12 line with regards to T12–S1 line; and LS was the relative motion of T12–S1 line with regards to the pelvis.

## Statistical analysis

Values are presented as means and ranges. As previously reported, there is no difference between right and left gait cycles for trunk parameters in AIS patients [16]. Therefore, by convention, gait parameters were measured at every percentage of the right gait cycle and averaged. For means interpretation, a value close to 0 reflected a symmetric gait pattern. The range of motion of gait parameters was calculated as the difference between the maximum and the minimum values that a parameter takes during a full gait cycle. Pre- to postoperative comparisons were performed using paired Student *t* tests. The influence of ThL extension on gait parameters was assessed using Pearson correlation tests. For statistical analyses, level of significance was set at 5% (i.e.  $p < 0.05$ ).

## Results

### Study population

During the inclusion period, we recruited 55 patients. There were 46 females (84%), mean age was 15.4 years ( $\pm 2$  years). According to Lenke classification [17], there were 41 main thoracic curves (Lenke 1 or 2) (75%), 9 main lumbar or thoracolumbar curves (Lenke 5) (16%) and 5 double major curves (Lenke 3 or 6) (9%). Overall, 23 patients had a lumbar modifier A (42%) and 32 a lumbar modifier B or C (58%). Mean follow-up was 7.7 months ( $\pm 3$  months) and the average number of level fused was 11.8 ( $\pm 2$ ). Concerning fusion levels, 49 patients (91%) had the upper instrumented vertebra (UIV) located at T5 or higher. The lower instrumented vertebra (LIV) was L1 in 5 patients (9%), L2 in 11 patients (20%), L3 in 30 patients (55%) and L4 in 9 patients (16%).

### Radiographic parameters

Radiographic data are summarized in Table 1. The main Cobb angle significantly improved from 60° to 23° ( $p < 0.001$ ), representing a mean correction rate of 62%. Thoracic kyphosis was restored from 25° preoperatively to 40° postoperatively ( $p < 0.001$ ).

**Table 1** Results from radiographic analysis

	Preop	Postop	<i>p</i>
CVA (absolute value)	13.5 ( $\pm 9.2$ )	11.2 ( $\pm 8$ )	0.071
Main Cobb angle	60.2 ( $\pm 12.8$ )	22.8 ( $\pm 8.1$ )	<b>&lt; 0.001</b>
Proximal curve Cobb angle	32.2 ( $\pm 10.8$ )	14.9 ( $\pm 10.7$ )	<b>&lt; 0.001</b>
Distal curve Cobb angle	35.8 ( $\pm 12.9$ )	18 ( $\pm 9.4$ )	<b>&lt; 0.001</b>
Clavicle angle	1.9 ( $\pm 1.7$ )	3.6 ( $\pm 2$ )	<b>&lt; 0.001</b>
SVA			
C2C7 lordosis*	- 9.1 ( $\pm 17$ )	6.4 ( $\pm 18.4$ )	<b>&lt; 0.001</b>
T2T12 kyphosis	24.6 ( $\pm 12.8$ )	40.3 ( $\pm 11.8$ )	<b>&lt; 0.001</b>
L1S1 lordosis	56.3 ( $\pm 12.5$ )	61.1 ( $\pm 9$ )	<b>0.001</b>
T10L2 lordosis	2 ( $\pm 12.6$ )	13.9 ( $\pm 8$ )	<b>&lt; 0.001</b>
Pelvic incidence	49.1 ( $\pm 10.4$ )	49.9 ( $\pm 11.1$ )	0.619
Pelvic tilt	5.7 ( $\pm 7.6$ )	6.4 ( $\pm 7.8$ )	0.246
Sacral slope	43.5 ( $\pm 9$ )	43.5 ( $\pm 7.8$ )	0.510

Bold values indicate statistical significance under 5%

\*Negative values indicate kyphosis

## Gait data

Results from gait analyses are presented in Tables 2 and 3.

### 1. Coronal plane

There was an improvement of trunk global balance during gait with a more symmetric gait pattern (decrease of mean dynamic CVA from 14 to 10 mm,  $p = 0.007$ ). Thoracic and lumbar dynamic Cobb angles improved. On the other hand, we found no change in shoulder line coronal inclination. Within the spine, PSF mainly lead to a symmetrization of coronal motion at LS junction (from 5.3 to 0.9°,  $p < 0.001$ ).

### 2. Sagittal plane

There was a significant decrease of trunk anterior tilt (SVA decrease from 45 to 39 mm,  $p = 0.036$ ). PSF led to a slight pelvic anteversion (9.9° vs. 11.3°,  $p = 0.012$ ). Within the spine, thoracolumbar junction showed less flexion than preoperatively (- 9.1 vs. - 6.5°,  $p = 0.005$ ). There was a significant negative correlation between thoracolumbar change and lumbosacral change ( $R = - 0.6158$ ,  $p < 0.001$ ), meaning that extension at the thoracolumbar junction led to flexion at the lumbosacral junction (Fig. 3). There was a strong correlation between thoracolumbar sagittal motion and lumbosacral junction pre and postoperatively ( $R = - 0.6413$  and  $R = - 0.7040$ , respectively, all  $p < 0.001$ ), meaning that the more thoracolumbar extension increased, the more lumbosacral extension decreased (Fig. 4). In a lesser proportion, the same relation was found between cervicothoracic and thoracolumbar junctions preoperatively ( $R = - 0.3963$ ,  $p = 0.002$ ). Of note, the relation was not significant anymore postoperatively ( $R = - 0.2092$ ,  $p = 0.112$ ). Finally,

**Table 2** Results of gait parameters statistical comparisons

	Preop	Postop	<i>p</i>
Dynamic CVA**	- 3 (± 18)	- 3 (± 11.8)	0.990
Dynamic CVA ( <i>absolute value</i> )	14.1 (± 11.4)	9.6 (± 7.8)	<b>0.007</b>
Dynamic shoulder line coronal inclination	0.3 (± 3.1)	0.2 (± 3.8)	0.905
Dynamic lumbar cobb angle**	- 8.3 (± 8.7)	0.4 (± 5.2)	< <b>0.001</b>
Dynamic thoracic cobb angle**	11.7 (± 12.3)	- 4.7 (± 7.1)	< <b>0.001</b>
Dynamic pelvis coronal inclination**	- 0.3 (± 1.8)	- 0.1 (± 1.5)	0.499
CTh coronal motion (inflexion) **	- 4 (± 5)	- 2.6 (± 4.2)	0.083
ThL coronal motion (inflexion) **	- 0.1 (± 1.5)	0.5 (± 0.8)	<b>0.010</b>
LS coronal motion (inflexion)	5.3 (± 4.1)	0.9 (± 3.2)	< <b>0.001</b>
Dynamic SVA	44.5 (± 24.7)	38.6 (± 20.1)	<b>0.036</b>
Dynamic lumbar lordosis	18.7 (± 6.5)	18.7 (± 5.8)	0.932
Dynamic thoracic kyphosis	28.5 (± 7.1)	26.8 (± 7.9)	0.119
Dynamic sagittal pelvic tilt	9.9 (± 5.3)	11.3 (± 4.6)	<b>0.012</b>
CTh sagittal motion (flexion–extension) *	- 5 (± 10)	- 6.5 (± 8.9)	0.257
ThL sagittal motion (flexion–extension) *	- 9.1 (± 8.9)	- 6.1 (± 7.6)	<b>0.005</b>
LS sagittal motion (flexion–extension) *	10.6 (± 7.7)	11.4 (± 7.4)	0.328
APA**	- 7.1 (± 5)	- 1.2 (± 4.3)	< <b>0.001</b>
Dynamic shoulder line rotation**	- 5.9 (± 5.2)	- 1 (± 4.4)	< <b>0.001</b>
Dynamic pelvis rotation**	- 1.2 (± 2.9)	- 0.2 (± 2.7)	<b>0.001</b>
CTh transversal motion (rotation)	3.9 (± 4.3)	1.3 (± 4.2)	< <b>0.001</b>
ThL transversal motion (rotation) **	- 2.2 (± 4.9)	4.4 (± 4.5)	< <b>0.001</b>
LS transversal motion (rotation) **	0.2 (± 4.3)	- 3.2 (± 3.6)	< <b>0.001</b>

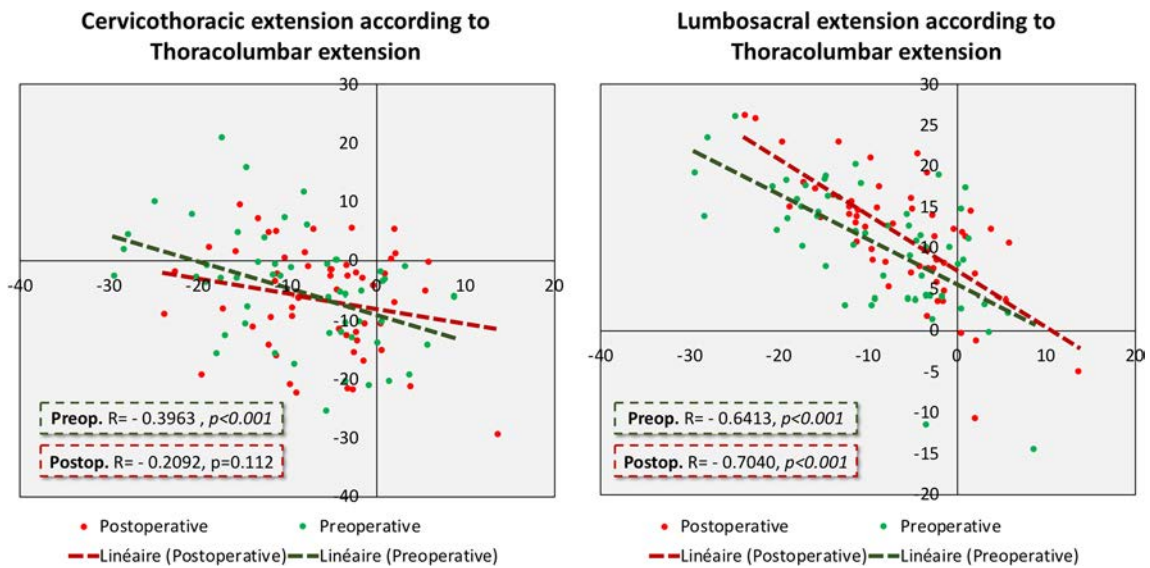
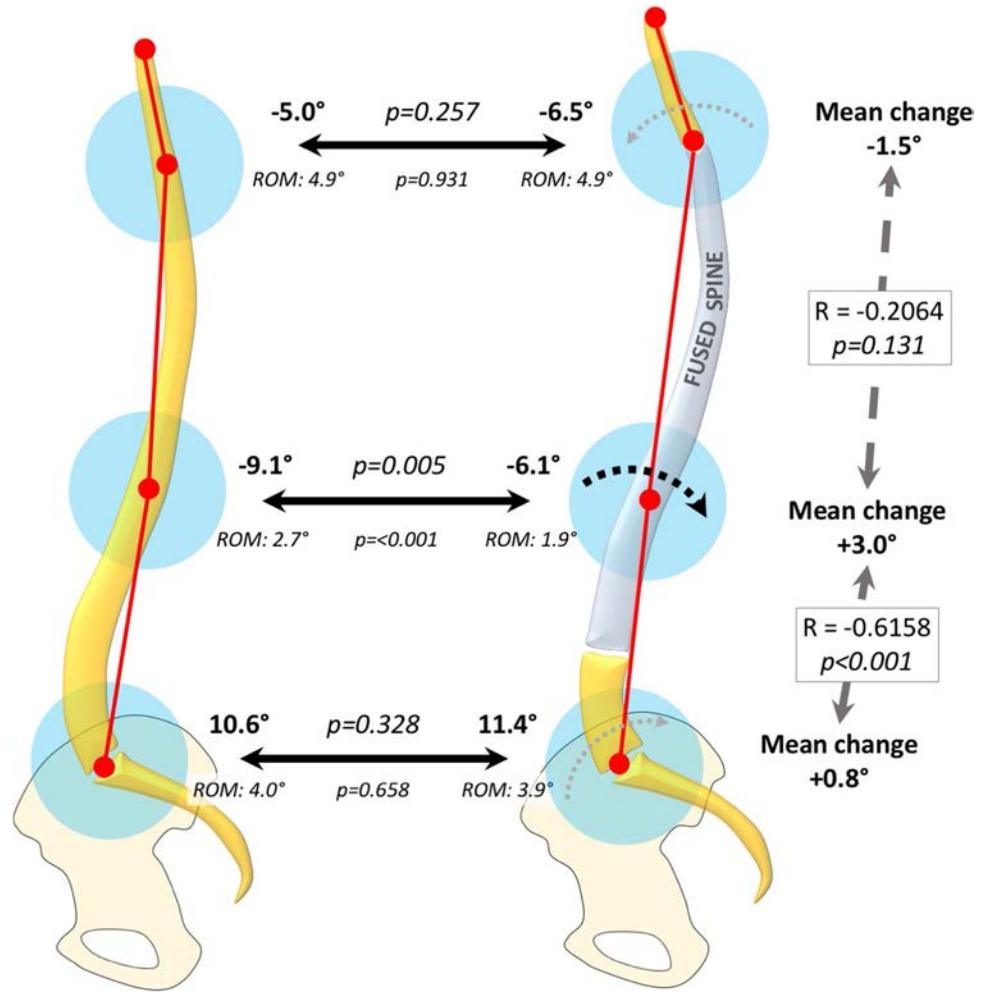
Bold values indicate statistical significance under 5%. \* Negative values indicate flexion. \*\* Negative values indicate deviation towards the left side

**Table 3** Range of motion (ROM) of gait parameters statistical comparisons

	Preop	Postop	<i>p</i>
Dynamic CVA ROM	26.4 (± 11.8)	21.5 (± 8.1)	<b>0.011</b>
Dynamic shoulder line coronal inclination	2.8 (± 1.5)	2.3 (± 1)	0.087
Dynamic thoracic Cobb ROM	7.3 (± 3.1)	5.1 (± 2.3)	< <b>0.001</b>
Dynamic lumbar Cobb ROM	6 (± 2)	5.8 (± 2.6)	0.833
Dynamic pelvis coronal inclination ROM	7.6 (± 2.8)	8.2 (± 3)	0.155
CTh coronal motion ROM (inflexion)	4.2 (± 2.3)	4.5 (± 2.1)	0.748
ThL coronal motion ROM (inflexion)	0.8 (± 0.7)	0.5 (± 0.4)	<b>0.029</b>
LS coronal motion ROM (inflexion)	10 (± 3.8)	7.6 (± 2.9)	<b>0.001</b>
Dynamic SVA ROM	24.9 (± 7.5)	27.2 (± 7.8)	0.072
Dynamic thoracic kyphosis ROM	4.5 (± 2.2)	2.2 (± 1.2)	< <b>0.001</b>
Dynamic lumbar lordosis ROM	4.7 (± 2.1)	3.7 (± 2.4)	<b>0.020</b>
Dynamic sagittal pelvic tilt ROM	2.9 (± 1.2)	2.9 (± 1)	0.973
CTh sagittal motion ROM (flexion–extension)	4.9 (± 3.1)	4.9 (± 2.7)	0.931
ThL sagittal motion ROM (flexion–extension)	2.7 (± 1.2)	1.9 (± 0.6)	< <b>0.001</b>
LS sagittal motion ROM (flexion–extension)	4 (± 1.6)	3.9 (± 1.3)	0.658
APA ROM	11.8 (± 4.7)	8.7 (± 3.4)	< <b>0.001</b>
Dynamic shoulder line rotation ROM	8 (± 2.8)	7.5 (± 2.5)	0.441
Dynamic pelvis rotation ROM	8.1 (± 3)	7.4 (± 3.1)	0.330
CTh transversal motion ROM (rotation)	4 (± 1.9)	3.7 (± 1.7)	0.186
ThL transversal motion ROM (rotation)	4.4 (± 1.9)	3.5 (± 1.4)	<b>0.003</b>
LS transversal motion ROM (rotation)	6.4 (± 2)	6.7 (± 1.9)	0.613

Bold values indicate statistical significance under 5%

**Fig. 3** Schematization of changes within the spine in the sagittal plane following spinal fusion



**Fig. 4** Influence of thoracolumbar junction sagittal motion and over and underlying junctions

there was a trend to significance between postoperative SVA change and thoracolumbar sagittal motion change ( $R = -0.2550, p = 0.059$ ), meaning that SVA tended to decrease when thoracolumbar junction was extended after fusion.

### 3. Transversal plane

All transversal parameters were significantly improved from a left-sided gait pattern to a symmetric gait pattern, with significant decrease of shoulder line and pelvis rotation and APA (Fig. 5).

### 4. Range of motion

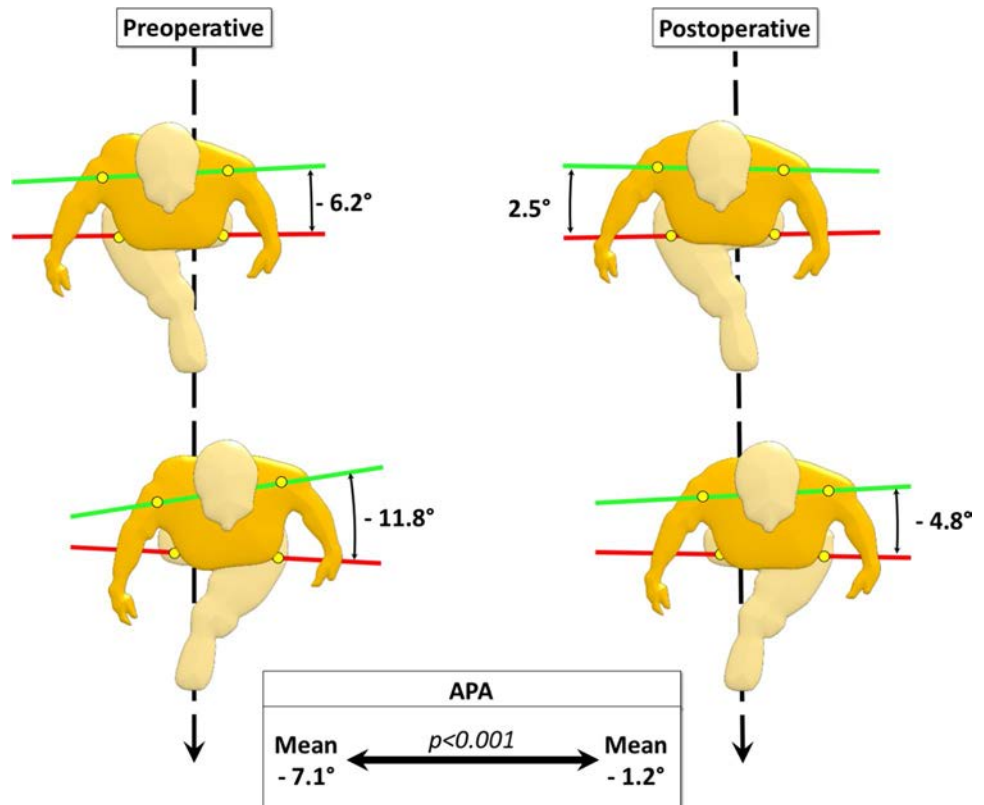
PSF led to global decrease of ROM (Table 3). This was particularly true in the thoracic area, with a decreased thoracic Cobb angle ROM (7.3 vs. 5.1°,  $p < 0.001$ ), dynamic thoracic kyphosis (4.5 vs. 2.2°,  $p < 0.001$ ) and APA ROM (11.8 vs. 8.7°,  $p < 0.001$ ). Logically, ThL junction ROM significantly decreased in all 3 planes.

improvement of kinematic parameters, especially in the transversal plane. Preoperatively, we found a typical AIS gait pattern, with the upper trunk rotated towards the left side reflected by negative APA and SL rotation. These results are consistent with previously published series [10, 12, 18–21]. Postoperatively, transverse plane kinematics were improved: APA and SL rotation were closest to 0 than preoperatively, being reflective of a symmetric gait pattern in the transversal plane. These results have been previously reported by some authors, but this is the first report of such results in hybrid technique. In the coronal plane, we found no improvement of global trunk balance. This is consistent with usual radiographic observations, as coronal balance improvement usually takes up to 2 years after surgery [22]. Our results suggest similar mechanisms for dynamic improvement. Indeed, we found a decreased lateral trunk imbalance but correction was incomplete and lateral imbalance remained. Longer follow-up will probably allow to prove coronal balance improvement, as shown by Lenke et al. with 2-year follow-up and Paul et al. who reported a decreased lateral excursion of the centre of mass following spinal fusion [23, 24]. In the sagittal plane, the main consequence of PSF was decreased anterior trunk tilt during gait, probably reflective of an “uncomfortable” gait due to stiffness secondary to surgery. However, it is difficult to know if this change in the sagittal motion is definitive. Indeed, the early follow-up makes that it is too early for the over

## Discussion

To the best of our knowledge, this is one of the largest series ever reported of postoperative analysis of AIS patients using gait analysis. Our results show that PSF led to significant

**Fig. 5** Improvement of transversal plane gait parameters following posterior spinal fusion





and underlying compensation mechanisms to occur. Further research involving patients with longer follow-up are necessary to understand how dynamic spinal balance will be modified by PSF.

To date, only few studies have reported consequences of PSF on gait in AIS patients [23–27]. Our results are quite in line with most of the previously reported series. Nevertheless, our protocol has the advantage of providing segmental assessment of the spine. At the cervicothoracic junction, there was a trend towards symmetric motion in coronal and transversal planes but no significant change in sagittal motion. At the thoracolumbar junction, we demonstrated changes in all the 3 planes, but the main changes occurred in the sagittal plane where decreased overall flexion of the spine was found. This was in line with our radiographic results, as in most of the cases, thoracolumbar junction was fused with more lordosis than at baseline. Of note, there was a clear relationship between thoracolumbar and lumbosacral junctions: thoracolumbar extension led to more lumbosacral flexion. Such phenomenon should call for further research, because of its potential implication in distal lumbar discs degeneration.

This was not true at the cervicothoracic junction postoperatively. However, thoracolumbar extension could become a concern as it could lead to compensatory cervicothoracic flexion. Our series taking place at the early postoperative stage could be the reason why this phenomenon was not observed here. Though, if confirmed, it could potentially be an explanation for mechanical complication such as proximal junctional kyphosis, which could appear as a compensatory mechanism for a too posterior sagittal alignment. However, this is purely hypothetical and further research should focus on shedding light on this point.

Our study has some limitations. First, we decided to include different scoliotic deformities, with thoracic and lumbar curves. This could be confusing, especially concerning coronal balance, as we previously demonstrated that thoracic and lumbar curves had opposite coronal imbalance. However, there were not enough lumbar curves in our series to perform subgroup analysis. On the other hand, we previously shown that transversal plane impairment was the same, wherever the curve was located. Second, the influence of LIV was not assessed because of the homogeneity of our population in terms of LIV location. In our cohort, LIV was relatively distal, which could be explained by the high proportion of Lumbar modifiers B or C. Multicentric study with more heterogeneity in LIV selection could help to shed light on this particular point.

In conclusion, this is the largest series reporting the results of gait analysis after PSF using hybrid instrumentation. We found significant improvement of gait parameters, especially in the transversal plane. However, this improvement occurred at the cost of decrease of range of motion

of the thoracic spine. PSF also led to decreased anterior trunk tilt, but so far, the consequences of this phenomenon remain unclear. Further investigation is clearly necessary to understand the influence of too posterior dynamic balance on functional results after PSF.

**Funding** No funding was received for this work.

## Declarations

**Conflict of interest** The authors declare they have no conflict of interest related to this work.

## References

1. Weinstein SL, Dolan LA, Cheng JCY et al (2008) Adolescent idiopathic scoliosis. *Lancet* (London, England) 371:1527–1537. [https://doi.org/10.1016/S0140-6736\(08\)60658-3](https://doi.org/10.1016/S0140-6736(08)60658-3)
2. Pesenti S, Jouve J-L, Morin C et al (2015) Evolution of adolescent idiopathic scoliosis: results of a multicenter study at 20 years' follow-up. *Orthop Traumatol Surg Res* 101:619–622. <https://doi.org/10.1016/j.otsr.2015.05.004>
3. Lafage V, Schwab F, Skalli W et al (2008) Standing balance and sagittal plane spinal deformity: analysis of spinopelvic and gravity line parameters. *Spine* (Phila Pa 1976) 33:1572–1578. <https://doi.org/10.1097/BRS.0b013e31817886a2>
4. Lykissas MG, Jain VV, Nathan ST et al (2013) Mid- to long-term outcomes in adolescent idiopathic scoliosis after instrumented posterior spinal fusion: a meta-analysis. *Spine* (Phila Pa 1976) 38:E113–E119. <https://doi.org/10.1097/BRS.0b013e31827ae3d0>
5. Pesenti S, Prost S, Pomero V et al (2020) Does static trunk motion analysis reflect its true position during daily activities in adolescent with idiopathic scoliosis? *Orthop Traumatol Surg Res*. <https://doi.org/10.1016/j.otsr.2019.12.023>
6. Ryan N, Bruno P (2017) Analysis of 3D multi-segment lumbar spine motion during gait and prone hip extension. *J Electromyogr Kinesiol* 33:111–117. <https://doi.org/10.1016/j.jelekin.2017.02.005>
7. Negrini S, Piovaneli B, Amici C et al (2016) Trunk motion analysis: a systematic review from a clinical and methodological perspective. *Eur J Phys Rehabil Med* 52:583–592
8. Mahaudens P, Banse X, Mousny M, Detrembleur C (2009) Gait in adolescent idiopathic scoliosis: kinematics and electromyographic analysis. *Eur Spine J* 18:512–521. <https://doi.org/10.1007/s00586-009-0899-7>
9. Syczewska M, Graff K, Kalinowska M et al (2012) Influence of the structural deformity of the spine on the gait pathology in scoliotic patients. *Gait Posture*. <https://doi.org/10.1016/j.gaitpost.2011.09.008>
10. Yang JH, Suh S-W, Sung PS, Park W-H (2013) Asymmetrical gait in adolescents with idiopathic scoliosis. *Eur Spine J* 22:2407–2413. <https://doi.org/10.1007/s00586-013-2845-y>
11. Kruger KM, Garman CMR, Krzak JJ et al (2018) Effects of spinal fusion for idiopathic scoliosis on lower body kinematics during gait. *Spine Deform* 6:441–447. <https://doi.org/10.1016/j.jspd.2017.12.008>
12. Pesenti S, Prost S, Pomero V et al (2019) Characterization of trunk motion in adolescents with right thoracic idiopathic scoliosis. *Eur Spine J* 28:2025–2033. <https://doi.org/10.1007/s00586-019-06067-1>

13. Blondel B, Pomero V, Moal B et al (2012) Sagittal spine posture assessment: feasibility of a protocol based on intersegmental moments. *Orthop Traumatol Surg Res* 98:109–113. <https://doi.org/10.1016/j.otsr.2011.12.001>
14. Blondel B, Viehweger E, Moal B et al (2015) Postural spinal balance defined by net intersegmental moments: results of a biomechanical approach and experimental errors measurement. *World J Orthop* 6:983–990. <https://doi.org/10.5312/wjo.v6.i11.983>
15. Pesenti S, Prost S, Blondel B et al (2019) Correlations linking static quantitative gait analysis parameters to radiographic parameters in adolescent idiopathic scoliosis. *Orthop Traumatol Surg Res* 105:541–545. <https://doi.org/10.1016/j.otsr.2018.09.024>
16. Pesenti S, Pomero V, Prost S et al (2020) Curve location influences spinal balance in coronal and sagittal planes but not transversal trunk motion in adolescents with idiopathic scoliosis: a prospective observational study. *Eur Spine J*. <https://doi.org/10.1007/s00586-020-06361-3>
17. Lenke LG (2005) Lenke classification system of adolescent idiopathic scoliosis: treatment recommendations. *Instr Course Lect* 54:537–542
18. Kramers-De Quervain IA, Müller R, Stacoff A et al (2004) Gait analysis in patients with idiopathic scoliosis. *Eur Spine J* 13:449–456. <https://doi.org/10.1007/s00586-003-0588-x>
19. Park HJ, Sim T, Suh SW et al (2016) Analysis of coordination between thoracic and pelvic kinematic movements during gait in adolescents with idiopathic scoliosis. *Eur Spine J*. <https://doi.org/10.1007/s00586-015-3931-0>
20. Nishida M, Nagura T, Fujita N et al (2017) Position of the major curve influences asymmetrical trunk kinematics during gait in adolescent idiopathic scoliosis. *Gait Posture* 51:142–148. <https://doi.org/10.1016/j.gaitpost.2016.10.004>
21. Wu K-W, Wang T-M, Hu C-C et al (2019) Postural adjustments in adolescent idiopathic thoracic scoliosis during walking. *Gait Posture* 68:423–429. <https://doi.org/10.1016/j.gaitpost.2018.12.024>
22. Jiang H, Shao W, Xu E et al (2018) Coronal imbalance after selective posterior thoracic fusion in patients with Lenke 1 and 2 adolescent idiopathic scoliosis. *Biomed Res Int* 2018:3476425. <https://doi.org/10.1155/2018/3476425>
23. Lenke LG, Engsberg JR, Ross SA et al (2001) Prospective dynamic functional evaluation of gait and spinal balance following spinal fusion in adolescent idiopathic scoliosis. *Spine (Phila Pa 1976)* 26:E330–E337
24. Paul JC, Patel A, Bianco K et al (2014) Gait stability improvement after fusion surgery for adolescent idiopathic scoliosis is influenced by corrective measures in coronal and sagittal planes. *Gait Posture* 40:510–515. <https://doi.org/10.1016/j.gaitpost.2014.06.006>
25. Mahaudens P, Detrembleur C, Mousny M, Banse X (2010) Gait in thoracolumbar/lumbar adolescent idiopathic scoliosis: effect of surgery on gait mechanisms. *Eur Spine J*. <https://doi.org/10.1007/s00586-010-1292-2>
26. Holewijn RM, Kingma I, de Kleuver M, Keijsers NLW (2018) Posterior spinal surgery for adolescent idiopathic scoliosis does not induce compensatory increases in distal adjacent segment motion: a prospective gait analysis study. *Spine J* 18:2213–2219. <https://doi.org/10.1016/j.spinee.2018.05.010>
27. Nishida M, Nagura T, Fujita N et al (2019) Spinal correction surgery improves asymmetrical trunk kinematics during gait in adolescent idiopathic scoliosis with thoracic major curve. *Eur Spine J* 28:619–626. <https://doi.org/10.1007/s00586-018-5741-7>