



HAL
open science

Grade III pivot shift as an early sign of knee decompensation in chronic ACL-injured knees with bimeniscal tears

Amanda Magosch, Christophe Jacquet, Christian Nuhrenborger, Caroline
Mouton, Romain Seil

► **To cite this version:**

Amanda Magosch, Christophe Jacquet, Christian Nuhrenborger, Caroline Mouton, Romain Seil. Grade III pivot shift as an early sign of knee decompensation in chronic ACL-injured knees with bimeniscal tears. *Knee Surgery, Sports Traumatology, Arthroscopy*, 2021, 30 (5), pp.1611-1619. 10.1007/s00167-021-06673-x . hal-03991653

HAL Id: hal-03991653

<https://amu.hal.science/hal-03991653>

Submitted on 9 Mar 2023

HAL is a multi-disciplinary open access archive for the deposit and dissemination of scientific research documents, whether they are published or not. The documents may come from teaching and research institutions in France or abroad, or from public or private research centers.

L'archive ouverte pluridisciplinaire **HAL**, est destinée au dépôt et à la diffusion de documents scientifiques de niveau recherche, publiés ou non, émanant des établissements d'enseignement et de recherche français ou étrangers, des laboratoires publics ou privés.

Grade III pivot shift as an early sign of knee decompensation in chronic ACL-injured knees with bimeniscal tears

Amanda Magosch¹ · Christophe Jacquet² · Christian Nührenbörger^{1,3} · Caroline Mouton^{1,3} · Romain Seil^{1,3,4} 

Abstract

Purpose To analyse possible associations between the preoperative pivot shift (PS) test and both patient and injury characteristics in anterior cruciate ligament (ACL)-injured knees, considering previously neglected meniscal injuries such as ramp and root tears. The hypothesis was that a preoperative grade III PS was associated with the amount of intra-articular soft-tissue damage and chronicity of the injury.

Methods The cohort involved 376 patients who underwent primary ACL reconstruction (239 males/137 females; median age 26). Patients were examined under anesthesia before surgery, using the PS test. During arthroscopy, intra-articular soft-tissue damage of the injured knee was classified as: (1) partial ACL tear; (2) complete isolated ACL tear; (3) complete ACL tear with one meniscus tear; and (4) complete ACL and bimeniscal tears. Chi-square and Mann–Whitney *U* tests were used to evaluate whether sex, age, body mass index, sport at injury, mechanism of injury, time from injury and intra-articular damage (structural damage of ACL and menisci) were associated with a grade III PS. Intra-articular damage was further analyzed for two sub-cohorts: acute (time from injury \leq 6 months) and chronic injuries ($>$ 6 months).

Results A grade III PS test was observed in 26% of patients. A significant association with PS grading was shown for age, time from injury and intra-articular soft-tissue damage ($p < 0.05$). Further analyses showed that grade III PS was associated with intra-articular damage in chronic injuries only ($p < 0.01$). In complete ACL and bimeniscal tears, grade III PS was more frequent in chronic (53%) than in acute knee injuries (26%; $p < 0.01$). Patients with chronic complete ACL and bimeniscal tears had a grade III PS 3.3 [1.3–8.2] times more often than patients in the acute sub-cohort.

Conclusion In ACL-injured patients, a preoperative grade III PS was mainly associated with a higher amount of intra-articular soft-tissue damage and chronicity of the injury. Patients with complete chronic ACL injuries and bimeniscal tears were more likely to have a preoperative grade III PS than their acute counterparts. This suggests that grade III PS may be an early sign of knee decompensation of dynamic rotational knee laxity in chronic ACL-injured knees with bimeniscal lesions.

Level of evidence Level III.

Keywords Pivot shift test · Rotatory laxity · Anterior cruciate ligament · Meniscus · Intra-articular soft-tissue damage · Knee decompensation

IQR	Inter quartile range
LM	Lateral meniscus
MM	Medial meniscus
MRI	Magnetic Resonance Imaging
ns	Not significant
PS	Pivot shift
TFI	Time from injury

Introduction

The pivot shift (PS) test is a common clinical sign used to assess the rotational laxity occurring in anterior cruciate ligament (ACL)-injured patients. It is known to be the most specific test for diagnosing ACL ruptures, especially under anesthesia [44]. Despite the recent development of objective and standardized evaluation methods, manual evaluation of the PS in four grades remains the gold standard [16, 17]. A preoperative grade III PS is associated with increased odds of ACL revision surgery [25]. Furthermore, the persistence or recurrence of a high-grade PS after ACL reconstruction is correlated with poor functional outcomes [3, 45]. Identifying and understanding the reason behind a preoperative high-grade PS is thus essential to the therapeutic decision-making process.

The exact origin and the evolution over time of a preoperative high-grade PS is still controversial and incompletely understood [14]. Recently, a multifactorial background, involving different anatomical structures, has been discussed [29, 37, 42]. The influence of the menisci as secondary stabilizers of the PS in ACL-deficient knees has specifically been investigated [24, 32]. Several studies have described the impact of posteromedial and posterolateral lesions of the menisci, such as ramp lesions and root tears, on rotational knee laxity [30, 38]. These types of tears are observed in a relevant number of ACL-injured patients [26], with a frequency of 8–42% for ramp lesions of the medial meniscus (MM) [4, 5] and 7–15% for posterolateral root tears [12, 35]. However, the influence of the total amount of meniscus injuries, including their more recently described variations like ramp or root tears, on the PS has never been investigated. Likewise, little is known about the evolution of the PS over time although it is well known that MM lesions increase with time from injury [7, 28], thus potentially leading to increased knee laxity.

The purpose of this study was to evaluate the relationship between the preoperative PS test and patient and injury characteristics in a series of ACL-injured patients, considering previously neglected meniscal injuries such as ramp and root tears. The hypothesis was that a preoperative grade III PS was associated with the magnitude of intra-articular soft-tissue damage (type of ACL injury and meniscus damage) and with chronicity of the ACL injury.

Materials and methods

Institutional Review Board (IRB) approval for the study protocol was given by the National Ethics Committee for Research in Luxembourg (Comité National d’Ethique de Recherche, notification number 201101/05). All patients gave their written informed consent to participate in the study.

Data were retrospectively extracted from an ongoing hospital-based register. This register collects data from a systematic and standardized follow-up set up for all patients with an ACL injury confirmed on Magnetic Resonance Imaging (MRI). Initially, 430 patients with primary ACL reconstruction performed by a single surgeon were extracted (Fig. 1). Patients were excluded if they had additional medial or lateral collateral ligament injuries requiring repair or reconstruction (2 patients), additional injury of the posterior cruciate ligament (2 patients), an ACL agenesis (6 patients), a mucoid degeneration of the ACL (1 patient), or an associated tibial fracture (1 patient). Furthermore, patients for whom the preoperative PS testing under anesthesia was not documented (42 patients) were excluded. The final study cohort involved 376 patients (239 males/137 females).

Patient and injury characteristics

Patient and injury characteristics included sex, age, and body mass index (BMI) as well as sports practice at injury, mechanism of injury, and time from injury (TFI) to surgery. Sports practice at injury was classified according to Grindem et al. [15] into: (1) Level I sport (football, basketball and handball), (2) Level II sport (skiing, volleyball, gymnastics, tennis), (3) Level III sport (swimming, running and cycling). Level III sports were grouped with non-sport-related injuries to avoid a small sample size. With regard to the mechanism of injury, a distinction was made between injuries involving contact with another person and non-contact injuries. TFI was divided into two categories in accordance with Magnussen et al. [24]: ≤ 6 months to define an acute ACL injury and > 6 months to define a chronic ACL injury. Table 1 shows the distribution of patient and injury characteristics in the final cohort.

Clinical examination and surgical procedure

For both knees, the PS test was performed under anesthesia before ACL reconstruction surgery [44, 45]. The test results were documented into four grades distinguishing between no subluxation (grade 0), slight slip or trace

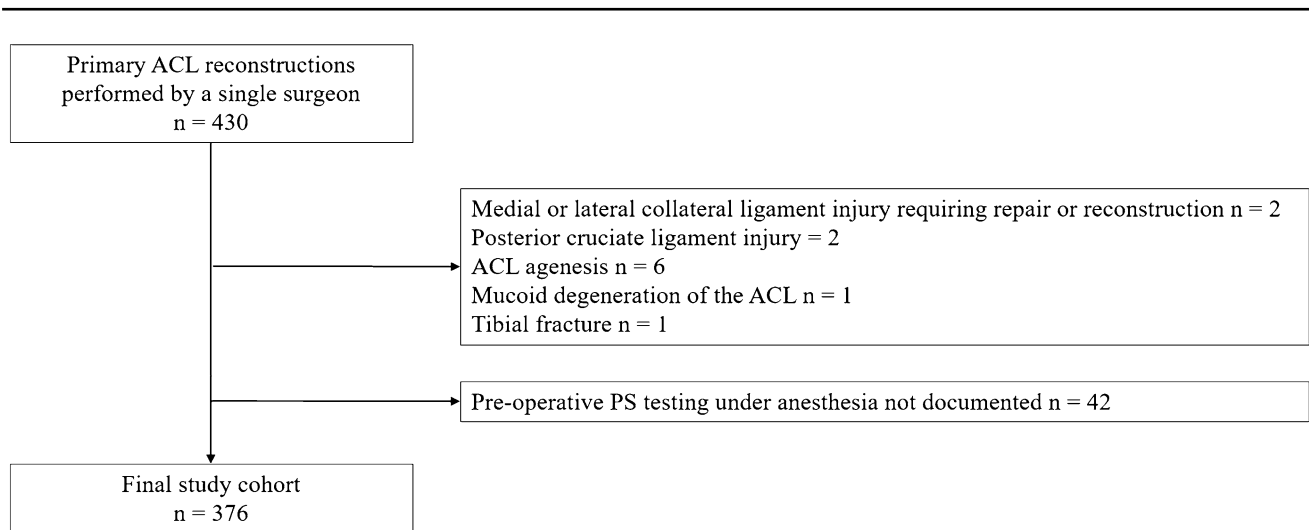


Fig. 1 Patient selection from the hospital-based register. *ACL* anterior cruciate ligament, *PS* pivot shift

Table 1 Patient and injury characteristics

Sex		
Male	239	64%
Female	137	36%
Age at surgery (years) ^a	26 (19–34)	
BMI (kg/m ²) ^a	24 (22–26)	
Sport at injury		
Level I	234	62%
Level II	99	26%
Level III/non-sport related	43	11%
Mechanism of injury		
Non-contact	283	75%
Contact	91	24%
Missing value	2	1%
Time between injury and surgery (days) ^a	145 (72–356)	

ACL anterior cruciate ligament, *BMI* body mass index, *IQR* interquartile range

^aValues are expressed as median (IQR)

(grade I), distinct subluxation and reduction (grade II) and pronounced subluxation and reduction (grade III) [16].

The surgical procedure was performed as previously described [26]. Before ACL reconstruction, a systematic inspection of the different structures of the knee was performed by the senior author through both an anterolateral and a posteromedial portal. The type of ACL rupture (partial or complete), and concomitant pathologies were documented. All types of meniscal tears including MM ramp lesions and posterolateral root tears [1, 19] and their locations (anterior horn, pars intermedia, posterior horn) were systematically investigated. An instability of the lateral meniscus (LM) posterior horn, as evaluated with a probe,

was also considered to be a lesion, as the cause is presumed to be a complex injury of anatomic compounds of the LM with surrounding structures [20, 40].

Classification of intra-articular soft-tissue damage

A primary distinction was made between partial and complete tears of the ACL. Anteromedial or posterolateral bundle conservations, as well as elongations of the ACL, were classified as partial ruptures [8]. All other types of ACL injuries were rated as complete ruptures and further divided according to the presence of additional meniscal tears. Isolated ACL injuries, in which both menisci appeared intact, were distinguished from injuries involving one meniscus (either medial or lateral) or both menisci. This resulted in four groups with an increasing level of intra-articular soft-tissue damage: (1) partial ACL tear; (2) complete isolated ACL tear; (3) complete ACL with one meniscus tear; and (4) complete ACL with bimeniscal tears.

Ninety-seven patients included in the final cohort displayed cartilage damage (grade 2 or higher according to the Outerbridge Classification of Chondral Lesions [35]) in at least one compartment of the knee. Overall additional surgical procedures to address the cartilage damage was limited to 13 patients (3.5%). For these reasons, these injuries were not further considered in the present study.

Statistical analyses

Statistical analyses were performed using version 26.0 of the SPSS software. A grade III PS test of the injured knee was rated as high-grade PS, while grades 0–II were aggregated as low-grade PS. To be able to detect a difference of 10% in the percentage of high-grade PS, with a statistical power of

80% and an alpha value of 5%, knowing that according to Magnussen et al. [24], the proportion of high-grade PS in a series of ACL-injured patients is 26.4%, a minimum sample size of 262 patients was required.

First, chi-squared tests with Bonferroni correction were used to determine whether the PS, distinguished as low-grade and high-grade, was associated with sex, sport at injury, mechanism of injury, TFI or intra-articular soft-tissue damage. Each expected cell count was checked to ensure it was greater than five. To estimate the effect size, phi was reported for 2×2 tables, while for larger tables Cramer's V was used [43]. Age at surgery and BMI were used as continuous variables. Normality of data was checked using the Kolmogorov–Smirnov test. As normality of data was not assumed, the Mann–Whitney *U* test was used to compare low-grade and high-grade PS for these variables. The correlation coefficient r^2 was calculated to estimate the effect size [43].

Since TFI is considered an important factor in the appearance of associated lesions in ACL-deficient knees [7, 24, 28], intra-articular damage was further analyzed for two sub-cohorts: patients with acute injury being operated on within 6 months of injury and patients with chronic injuries with greater than 6 months. Chi-square tests with Bonferroni correction were used to determine whether (1) the amount of intra-articular soft-tissue damage differed between the two sub-cohorts, and (2) the PS was associated with intra-articular damage in each sub-cohort. Odds ratio was computed for significant comparisons and reported with 95% CI (Confidence Interval). Significance was set at $p < 0.05$ for all analyses.

Results

Preoperative PS grades and arthroscopic findings are listed in Table 2. Intra-articular soft-tissue damage was distributed as follows: 44 partial ACL tears (11%); 89 complete isolated ACL tears (24%); 154 complete ACL tears with one meniscus tear (41%); and 89 complete ACL with bimeniscal tears (24%). Twenty-three out of 44 patients with partial ACL tears had an additional meniscus tear (5 with MM tear, 14 with LM tear, 4 with bimeniscal tear).

A preoperative grade III PS was observed in 26% ($n = 98$ out of 376 patients) of patients, while grades 0, I and II were documented for 74% ($n = 278$ out of 376 patients). A significant association was observed between grade III PS and younger age, chronic ACL injuries (TFI > 6 months) and intra-articular soft-tissue damage (Table 3). There was more preoperative grade III PS in complete ACL and bimeniscal tears (36%) compared to partial ACL tears (9%; $p < 0.05$; Fig. 2a).

Table 2 Preoperative pivot shift grades and intraoperative findings

Pivot shift grading		
Grade 0	28	7%
Grade I	103	27%
Grade II	147	39%
Grade III	98	26%
Intra-articular soft-tissue damage		
Partial ACL tear	44	11%
Complete isolated ACL tear	89	24%
Complete ACL with one meniscus tear	154	41%
Complete ACL and bimeniscal tears	89	24%
Additional meniscal injury		
None	110	29%
MM tear	69	18%
LM tear	104	28%
Bimeniscal tears	93	25%
Location of meniscus tear ^a		
MM posterior horn	150	40%
MM pars intermedia	62	16%
MM anterior horn	17	5%
MM unknown	9	2%
LM posterior horn	176	47%
LM pars intermedia	49	13%
LM anterior horn	11	3%
LM unknown	10	3%
Type of meniscal tear ^a		
MM ramp lesion	91	24%
LM root tear	70	19%
LM posterior horn instability	31	8%
Other types	177	47%

ACL anterior cruciate ligament, MM medial meniscus, LM lateral meniscus

^aPercentages are given per row as a proportion of the total cohort ($n = 376$)

Chronic ACL injuries displayed more MM tears (28%) than acute ACL injuries (11%) but fewer LM tears (22% in chronic and 32% in acute; $p < 0.01$). The overall distribution of intra-articular soft-tissue damage as classified in this study did not differ significantly between acute and chronic injuries (Table 4). The association between preoperative grade III PS and the magnitude of intra-articular damage was only confirmed in the sub-cohort of chronic ACL injuries ($p < 0.01$, Cramer $V = 0.277$; Fig. 2b). In complete ACL and bimeniscal tears, the presence of a grade III preoperative PS was significantly greater in chronic ACL injuries (53%) than in acute ACL injuries (26%, $p < 0.01$, Phi = 0.278; Fig. 2b). Patients with a chronic ACL injury associated with bimeniscal tears were 3.3 [95% CI 1.3–8.2] times more likely to have a preoperative grade III PS than patients with acute ACL injuries and comparable meniscus damage.

Table 3 Patient and injury characteristics according to preoperative pivot shift low- and high-grade

Characteristic	Low-grade (0–II) <i>n</i> = 278		High-grade (III) <i>n</i> = 98		<i>p</i> value	Effect size
Sex						
Male	177	74%	62	26%	<i>n.s.</i>	– 0.004
Female	101	74%	36	26%		
Age at surgery (years) ^a	26 (21–34)		24 (18–30)		0.028	0.013
BMI (kg/m ²) ^a	24 (22–26)		24 (21–26)		<i>n.s.</i>	<0.001
Sport at injury						
Level I	170	73%	64	27%	<i>n.s.</i>	0.088
Level II	79	80%	20	20%		
Level III/non-sport related	29	67%	14	33%		
Mechanism of injury ^b						
Non-contact	213	75%	70	25%	<i>n.s.</i>	0.048
Contact	64	70%	27	30%		
Time between injury and surgery						
≤ 6 months	168	79%	46	21%	0.020	0.120
> 6 months	110	68%	52	32%		
Intra-articular soft-tissue damage						
Partial ACL tear	40	91%	4	9%	0.011	0.172
Complete isolated ACL tear	67	75%	22	25%		
Complete ACL with one meniscus tear	114	74%	40	26%		
Complete ACL and bimeniscal tears	57	64%	32	36%		

ACL anterior cruciate ligament, *n.s.* not significant, *IQR* inter quartile range

^aValues are expressed as median (*IQR*)

^bMissing value (*n* = 2) excluded

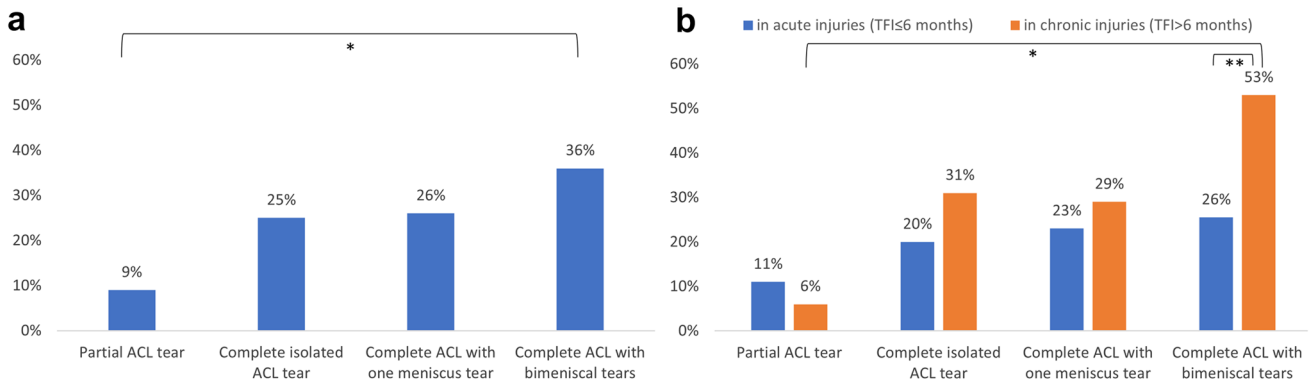


Fig. 2 Percentage of preoperative grade III pivot shift tests for classification of intra-articular soft-tissue damage in the total cohort (a) and the sub-cohorts of acute and chronic ACL injuries (b). **p* < 0.05; ***p* < 0.01. ACL anterior cruciate ligament, *TFI* time from injury

Table 4 Number and proportion of patients in each group of intra-articular soft-tissue damage in two sub-groups according to *TFI*

Intra-articular damages	Acute injury (<i>TFI</i> ≤ 6 months) <i>n</i> = 214		Chronic injury (<i>TFI</i> > 6 months) <i>n</i> = 162		<i>p</i> value	Effect size
Partial ACL tear	27	13%	17	10%	<i>n.s.</i>	0.074
Complete isolated ACL tear	50	23%	39	24%		
Complete ACL with one meniscus tear	82	38%	72	44%		
Complete ACL with bimeniscal tears	55	26%	34	21%		

ACL anterior cruciate ligament, *TFI* time from injury, *n.s.* not significant

Discussion

The most important finding of this study was that a preoperative grade III PS was associated with a higher amount of intra-articular soft-tissue damage and chronicity of the injury. Preoperative grade III PS was more frequent in patients with chronic ACL injuries displaying complete ACL and bimeniscal tears. This group of patients was 3.3 times more likely to have a preoperative grade III PS than their acute counterparts. This highlights the importance of considering both the intra-articular soft-tissue damage and the chronicity of an ACL injury in the therapeutic decision-making process. The findings suggest that a grade III pivot shift may be an early sign of knee decompensation of dynamic rotational knee laxity in chronic ACL-injured knees with bimeniscal lesions. To prevent this, early identification and close follow-up of injuries with important structural damage thus seems to be a key factor in patients in which an early ACL reconstruction and associated meniscal repair cannot be considered.

So far only few studies with large patient cohorts evaluated patient and injury characteristics in relation with the preoperative PS. Magnussen et al. [24] described increased odds for a preoperative high-grade PS in female patients and those aged under 20 in a series of more than 2300 patients. These findings could not be confirmed by Song et al., who could identify involvement in a pivoting sport at the time of injury as an independent risk factor for a preoperative high-grade PS [39]. While the results of the present study could not confirm an association of preoperative grade III PS with sex and sport at injury, a younger age was observed in patients with preoperative grade III PS. However, the small effect size ($r^2 = 0.01$) questions the clinical significance of this finding. One major reason for the observed discrepancies between studies may be related to patient selection. Song et al. [39] limited their analysis to acute ACL injuries (TFI to surgery was less than 3 weeks) while Magnussen et al. [24] and the present study included patients with both acute and chronic injuries. Magnussen et al. reported, that chronic ACL tears (TFI > 6 months) were three times as likely to have preoperative high-grade PS in comparison to acute ACL tears (TFI < 3 months) [24]. This was confirmed by the present study and is also in accordance with Nishida et al., who used a quantitative measurement for PS and described an increase in tibial acceleration in patients operated on more than 12 months after injury [33]. A similar association between excessive static anterior tibial translation on MRI and chronicity of the ACL tear has been previously demonstrated [27]. The increase in knee laxity over time may thus be an indicator of a progressive soft-tissue decompensation phenomenon in the knee joint after ACL injury.

Dynamic rotational laxity as expressed by the PS may not be present early after knee injury and develop over the following months [13, 36] but little is known about the spontaneous evolution of the PS over time in non-operated patients. This may be an early sign of knee decompensation, reflecting irreversible structural damage of the secondary stabilizers. It is well established that the occurrence of MM tears increases with time from injury to surgery [7, 28]. This was confirmed in the present study with 11% of MM tears in acute versus 28% in chronic injuries. Still, the overall distribution of intra-articular soft-tissue damage did not differ significantly between acute and chronic ACL injuries which may be related to the fact that the laterality of meniscal damage was not considered but only its total amount (one vs bimeniscal injury). While medial [24] and lateral meniscus tears [18, 24, 33, 39] have been shown to be associated with preoperative high-grade PS, previous authors did not investigate the total amount of structural soft-tissue damage; nor did they explicitly mention how meniscus tears were documented. It is therefore unclear whether they considered the full range of meniscus tears, including the frequently undiagnosed MM ramp lesions and posterolateral root tears. These should be systematically considered as they may play an important role in the presence or progressive appearance of a preoperative grade III PS.

In the present study, the proportion of preoperative grade III PS increased significantly with the amount of intra-articular soft-tissue damage; from 9% in partial ACL tears to 36% in complete ACL tears with bimeniscal tears. The present classification of structural soft-tissue damage was based on the hypothesis that the amount of injured intra-articular soft-tissue structures is related to the initial trauma energy, inducing a spectrum of injuries ranging from partial ACL to complete ACL tears and major bimeniscal damage, thus reflecting a real trauma cascade [34]. Complete ACL ruptures are indeed recognized to require higher forces at injury than partial ruptures [8–10]. Such correlations with the amount of energy at the initial impact have also previously been described for meniscus tears [6]. In partial ACL tears, although 23 out of 44 patients displayed an associated meniscus tear, the low percentage of preoperative grade III PS (9%) is likely to be due to the remaining fibers of the ACL, which provide residual stability to the knee [2, 21], rather than the menisci themselves. The higher percentage of grade III PS observed when bimeniscal tears were combined with complete ACL tears supports the hypothesis that meniscus tears were involved in the development of the PS [24, 30, 32, 38].

An important finding of the present study was the fact that the association between preoperative grade III PS and the magnitude of intra-articular damage mainly resulted from the sub-cohort of chronically ACL-injured patients. Patients with chronic complete ACL injuries combined

with bimeniscal tears, who represented a non-negligible proportion of our cohort (24%), displayed a preoperative grade III PS 3.3 times more often than patients with acute injuries and similar intra-articular damage. These results indicate that patients with acute complete ACL tears and bimeniscal tears should receive particular attention within the first months after the injury. They may indeed be at higher risk of undergoing later decompensation of rotational knee joint laxity once the injury becomes chronic, and for later failure of ACL reconstruction [23, 25]. A proper evaluation of intra-articular soft-tissue damage is thus critical to identify those patients who may benefit from an early ACL reconstruction as well as extensive meniscal repair, with the ultimate goal of achieving a complete anatomical restoration of the injured intra-articular soft tissues.

This study is not without limitations. Since only statistical relationships were shown, causality cannot be concluded. The PS test was evaluated manually and the quantification remains subjective and examiner-dependent. However, despite the recent development of objective and standardized evaluation methods, clinical examination of the PS remains the gold standard [17]. The main strength of this study was the combination of ACL injury and concomitant single or bimeniscal tears with a thorough diagnostic examination. The majority of meniscal tears involved posterior horns so that analyzing in depth the location and size of tears would have led to underpowered analyses, although the authors recognize that these parameters may also have an influence on the presence of a preoperative high-grade PS. Injuries to the anterolateral capsular structures and Kaplan fibers were not considered, although there is evidence that they play a role in rotational laxity [22]. Anatomical factors such as bone morphology and generalized ligamentous laxity, for which a relationship with the PS has previously been described [11, 24, 31, 41], were also not evaluated. However, this series of 376 primary ACL reconstructions considered all types of known meniscal tears, including the often undiagnosed or underestimated MM ramp lesions and posterolateral root tears. The thorough determination of meniscus status provides additional evidence to the impact of meniscus injuries on the etiology of the PS, especially in chronic ACL injuries. Further studies are needed to evaluate the influence of specific types of meniscal tears and other extra- (anterolateral capsular structures, Kaplan fibers) or intra-articular injuries (posterolateral tibial plateau or lateral condylar impression fractures) as well as many other factors, including constitutional laxity and bony morphology to better understand the precise determinants of the PS and the possible later decompensation phenomenon that may occur in ACL-injured knee joints.

Conclusion

A preoperative grade III PS was mainly associated with a higher amount of intra-articular soft-tissue damage within the knee and the chronicity of the ACL injury. Patients with chronic ACL injuries displaying complete ACL and bimeniscal tears were more likely to have a preoperative grade III PS than their acute counterparts. The findings suggest that grade III PS may be an early sign of knee decompensation of dynamic rotational knee laxity in chronic ACL-injured knees with bimeniscal lesions. To prevent this, early identification and close follow-up of injuries with important structural soft-tissue damage thus may be a key factor in patients in which an early ACL reconstruction and associated meniscal repair cannot be considered.

Author contributions All authors contributed equally to the study.

Funding None.

Declarations

Conflict of interest None.

Ethical approval National Ethics Committee for Research (No. 201101/05).

Informed consent All patients signed an informed consent to participate in the study.

References

1. Anderson AF, Irrgang JJ, Dunn W, Beaufils P, Cohen M, Cole BJ et al (2011) Interobserver reliability of the International Society of Arthroscopy, Knee Surgery and Orthopaedic Sports Medicine (ISAKOS) classification of meniscal tears. *Am J Sports Med* 39:926–932
2. Araki D, Kuroda R, Matsushita T, Matsumoto T, Kubo S, Nagamune K et al (2013) Biomechanical analysis of the knee with partial anterior cruciate ligament disruption: quantitative evaluation using an electromagnetic measurement system. *Arthroscopy* 29:1053–1062
3. Ayeni OR, Chahal M, Tran MN, Sprague S (2012) Pivot shift as an outcome measure for ACL reconstruction: a systematic review. *Knee Surg Sports Traumatol Arthrosc* 20:767–777
4. Balazs GC, Greditzer HG, Wang D, Marom N, Potter HG, Marx RG et al (2019) Ramp lesions of the medial meniscus in patients undergoing primary and revision ACL reconstruction: prevalence and risk factors. *Orthop J Sports Med* 7:2325967119843509
5. Bumberger A, Koller U, Hofbauer M, Tiefenboeck TM, Hajdu S, Windhager R et al (2020) Ramp lesions are frequently missed in ACL-deficient knees and should be repaired in case of instability. *Knee Surg Sports Traumatol Arthrosc* 28:840–854
6. Chang H, Zheng Z, Shao D, Yu Y, Hou Z, Zhang Y (2018) Incidence and radiological predictors of concomitant meniscal and

- cruciate ligament injuries in operative tibial plateau fractures: a prospective diagnostic study. *Sci Rep* 8:13317
7. Chavez A, Jimenez AE, Riepen D, Schell B, Khazzam M, Coyner KJ (2020) Anterior cruciate ligament tears: the impact of increased time from injury to surgery on intra-articular lesions. *Orthop J Sports Med* 8:2325967120967120
 8. Colombet P, Dejour D, Panisset JC, Siebold R, French Arthroscopy Society (2010) Current concept of partial anterior cruciate ligament ruptures. *Orthop Traumatol Surg Res* 96:S109-118
 9. DeFranco MJ, Bach BR Jr (2009) A comprehensive review of partial anterior cruciate ligament tears. *J Bone Joint Surg Am* 91:198-208
 10. Dejour D, Ntgiopoulos PG, Saggin PR, Panisset JC (2013) The diagnostic value of clinical tests, magnetic resonance imaging, and instrumented laxity in the differentiation of complete versus partial anterior cruciate ligament tears. *Arthroscopy* 29:491-499
 11. Dejour D, Pungitore M, Valluy J, Nover L, Saffarini M, Demey G (2019) Preoperative laxity in ACL-deficient knees increases with posterior tibial slope and medial meniscal tears. *Knee Surg Sports Traumatol Arthrosc* 27:564-572
 12. Feucht MJ, Bigdon S, Mehl J, Bode G, Muller-Lantzsch C, Sudkamp NP et al (2015) Risk factors for posterior lateral meniscus root tears in anterior cruciate ligament injuries. *Knee Surg Sports Traumatol Arthrosc* 23:140-145
 13. Frobell RB, Roos EM, Roos HP, Ranstam J, Lohmander LS (2010) A randomized trial of treatment for acute anterior cruciate ligament tears. *N Engl J Med* 363:331-342
 14. Fu FH, Herbst E (2016) Editorial commentary: the pivot-shift phenomenon is multifactorial. *Arthroscopy* 32:1063-1064
 15. Grindem H, Eitzen I, Engebretsen L, Snyder-Mackler L, Risberg MA (2014) Nonsurgical or surgical treatment of ACL injuries: knee function, sports participation, and knee reinjury: the Delaware-Oslo ACL cohort study. *J Bone Joint Surg Am* 96:1233-1241
 16. Hefti F, Muller W, Jakob RP, Staubli HU (1993) Evaluation of knee ligament injuries with the IKDC form. *Knee Surg Sports Traumatol Arthrosc* 1:226-234
 17. Horvath A, Meredith SJ, Nishida K, Hoshino Y, Musahl V (2020) Objectifying the pivot shift test. *Sports Med Arthrosc Rev* 28:36-40
 18. Hoshino Y, Miyaji N, Nishida K, Nishizawa Y, Araki D, Kanzaki N et al (2019) The concomitant lateral meniscus injury increased the pivot shift in the anterior cruciate ligament-injured knee. *Knee Surg Sports Traumatol Arthrosc* 27:646-651
 19. Kopf S, Beaufils P, Hirschmann MT, Rotigliano N, Ollivier M, Pereira H et al (2020) Management of traumatic meniscus tears: the 2019 ESSKA meniscus consensus. *Knee Surg Sports Traumatol Arthrosc* 28:1177-1194
 20. Laver L, Hoffmann A, Spalding T, Mouton C, Seil R (2017) Hypermobile lateral meniscus. *Arthroscopie* 30:100-107
 21. Lintner DM, Kamaric E, Moseley JB, Noble PC (1995) Partial tears of the anterior cruciate ligament. Are they clinically detectable? *Am J Sports Med* 23:111-118
 22. Lobenhoffer P, Posel P, Witt S, Piehler J, Wirth CJ (1987) Distal femoral fixation of the iliotibial tract. *Arch Orthop Trauma Surg* 106:285-290
 23. Magnussen RA, Reinke EK, Huston LJ, MOON Group, Hewett TE, Spindler KP (2016) Effect of high-grade preoperative knee laxity on anterior cruciate ligament reconstruction outcomes. *Am J Sports Med* 44:3077-3082
 24. Magnussen RA, Reinke EK, Huston LJ, MOON Group, Hewett TE, Spindler KP (2016) Factors associated with high-grade laxity, pivot shift, and anterior drawer at the time of anterior cruciate ligament reconstruction. *Arthroscopy* 32:1080-1085
 25. Magnussen RA, Reinke EK, Huston LJ, MOON Knee Group, Hewett TE, Spindler KP et al (2018) Effect of high-grade preoperative knee laxity on 6-year anterior cruciate ligament reconstruction outcomes. *Am J Sports Med* 46:2865-2872
 26. Magosch A, Mouton C, Nuhrenborger C, Seil R (2020) Medial meniscus ramp and lateral meniscus posterior root lesions are present in more than a third of primary and revision ACL reconstructions. *Knee Surg Sports Traumatol Arthrosc*. <https://doi.org/10.1007/s00167-020-06352-3>
 27. McDonald LS, van der List JP, Jones KJ, Zuiderbaan HA, Nguyen JT, Potter HG et al (2017) Passive anterior tibial subluxation in the setting of anterior cruciate ligament injuries: a comparative analysis of ligament-deficient states. *Am J Sports Med* 45:1537-1546
 28. Mehl J, Otto A, Baldino JB, Achtnich A, Akoto R, Imhoff AB et al (2019) The ACL-deficient knee and the prevalence of meniscus and cartilage lesions: a systematic review and meta-analysis (CRD42017076897). *Arch Orthop Trauma Surg* 139:819-841
 29. Monaco E, Maestri B, Labianca L, Speranza A, Kelly MJ, D'Arrigo C et al (2010) Navigated knee kinematics after tear of the ACL and its secondary restraints: preliminary results. *Orthopedics* 33:87-93
 30. Mouton C, Magosch A, Pape D, Hoffmann A, Nuhrenborger C, Seil R (2020) Ramp lesions of the medial meniscus are associated with a higher grade of dynamic rotatory laxity in ACL-injured patients in comparison to patients with an isolated injury. *Knee Surg Sports Traumatol Arthrosc* 28:1023-1028
 31. Musahl V, Ayeni OR, Citak M, Irrgang JJ, Pearle AD, Wickiewicz TL (2010) The influence of bony morphology on the magnitude of the pivot shift. *Knee Surg Sports Traumatol Arthrosc* 18:1232-1238
 32. Musahl V, Rahnama-Azar AA, Costello J, Arner JW, Fu FH, Hoshino Y et al (2016) The influence of meniscal and anterolateral capsular injury on knee laxity in patients with anterior cruciate ligament injuries. *Am J Sports Med* 44:3126-3131
 33. Nishida K, Matsushita T, Hoshino Y, Araki D, Matsumoto T, Niikura T et al (2020) The influences of chronicity and meniscal injuries on pivot shift in anterior cruciate ligament-deficient knees: quantitative evaluation using an electromagnetic measurement system. *Arthroscopy* 36:1398-1406
 34. Petersen W (2012) Does ACL reconstruction lead to degenerative joint disease or does it prevent osteoarthritis? How to read science. *Arthroscopy* 28:448-450
 35. Praz C, Vieira TD, Saithna A, Rosentiel N, Kandhari V, Nogueira H et al (2019) Risk factors for lateral meniscus posterior root tears in the anterior cruciate ligament-injured knee: an epidemiological analysis of 3956 patients from the SANTI Study Group. *Am J Sports Med* 47:598-605
 36. Pujol N, Colombet P, Cucurulo T, Graveleau N, Hulet C, Panisset JC et al (2012) Natural history of partial anterior cruciate ligament tears: a systematic literature review. *Orthop Traumatol Surg Res* 98:S160-164
 37. Smith PA, Thomas DM, Pomajzl RJ, Bley JA, Pfeiffer FM, Cook JL (2019) A Biomechanical study of the role of the anterolateral ligament and the deep iliotibial band for control of a simulated pivot shift with comparison of minimally invasive extra-articular anterolateral tendon graft reconstruction versus modified Lemaire reconstruction after anterior cruciate ligament reconstruction. *Arthroscopy* 35:1473-1483
 38. Song GY, Zhang H, Liu X, Zhang J, Xue Z, Qian Y et al (2017) Complete posterolateral meniscal root tear is associated with high-grade pivot-shift phenomenon in noncontact anterior cruciate ligament injuries. *Knee Surg Sports Traumatol Arthrosc* 25:1030-1037
 39. Song GY, Zhang H, Wang QQ, Zhang J, Li Y, Feng H (2016) Risk factors associated with grade 3 pivot shift after acute anterior cruciate ligament injuries. *Am J Sports Med* 44:362-369
 40. Steinbacher G, Alentorn-Geli E, Alvarado-Calderon M, Barastegui D, Alvarez-Diaz P, Cugat R (2019) Meniscal fixation is a

-
- successful treatment for hypermobile lateral meniscus in soccer players. *Knee Surg Sports Traumatol Arthrosc* 27:354–360
41. Sundemo D, Blom A, Hoshino Y, Kuroda R, Lopomo NF, Zaffagnini S et al (2018) Correlation between quantitative pivot shift and generalized joint laxity: a prospective multicenter study of ACL ruptures. *Knee Surg Sports Traumatol Arthrosc* 26:2362–2370
42. Tanaka M, Vyas D, Moloney G, Bedi A, Pearle AD, Musahl V (2012) What does it take to have a high-grade pivot shift? *Knee Surg Sports Traumatol Arthrosc* 20:737–742
43. Tomczak M, Tomczak E (2014) The need to report effect size estimates revisited. An overview of some recommended measures of effect size. *Trends Sport Sci* 21:19–25
44. van Eck CF, van den Bekerom MP, Fu FH, Poolman RW, Kerkhoffs GM (2013) Methods to diagnose acute anterior cruciate ligament rupture: a meta-analysis of physical examinations with and without anaesthesia. *Knee Surg Sports Traumatol Arthrosc* 21:1895–1903
45. Vaudreuil NJ, Rothrauff BB, de Sa D, Musahl V (2019) The pivot shift: current experimental methodology and clinical utility for anterior cruciate ligament rupture and associated injury. *Curr Rev Musculoskelet Med* 12:41–49