



HAL
open science

NAPB and developmental and epileptic encephalopathy: Description of the electroclinical profile associated with a novel pathogenic variant

Cécile Mignon-ravix, Florence Riccardi, Géraldine Daquin, Pierre Cacciagli,
Sylvie Lamoureux-toth, Laurent Villard, Nathalie Villeneuve, Florence
Molinari

► To cite this version:

Cécile Mignon-ravix, Florence Riccardi, Géraldine Daquin, Pierre Cacciagli, Sylvie Lamoureux-toth, et al.. NAPB and developmental and epileptic encephalopathy: Description of the electroclinical profile associated with a novel pathogenic variant. *Epilepsia*, 2023, 10.1111/epi.17603 . hal-04072437

HAL Id: hal-04072437

<https://amu.hal.science/hal-04072437>

Submitted on 18 Apr 2023

HAL is a multi-disciplinary open access archive for the deposit and dissemination of scientific research documents, whether they are published or not. The documents may come from teaching and research institutions in France or abroad, or from public or private research centers.

L'archive ouverte pluridisciplinaire **HAL**, est destinée au dépôt et à la diffusion de documents scientifiques de niveau recherche, publiés ou non, émanant des établissements d'enseignement et de recherche français ou étrangers, des laboratoires publics ou privés.



Distributed under a Creative Commons Attribution 4.0 International License

BRIEF COMMUNICATION

NAPB and developmental and epileptic encephalopathy: Description of the electroclinical profile associated with a novel pathogenic variant

Cécile Mignon-Ravix¹ | Florence Riccardi^{1,2} | Géraldine Daquin³ | Pierre Cacciagli⁴ | Sylvie Lamoureux-Toth⁵ | Laurent Villard^{1,6}  | Nathalie Villeneuve⁷ | Florence Molinari¹ 

¹Aix-Marseille Univ, INSERM, MMG, Marseille, France

²Département de Génétique Médicale, CHITS, Hôpital Ste Musse, Toulon, France

³AP-HM, Hôpital Timone Enfants, Service de Neurophysiologie Clinique, Marseille, France

⁴Biological Resources Center, CRB, Assistance Publique des Hôpitaux de Marseille, Marseille, France

⁵Centre Hospitalier Avignon, Service de Pédiatrie, Avignon, France

⁶AP-HM, Hôpital Timone Enfants, Service de Génétique Médicale, Marseille, France

⁷AP-HM, Hôpital Timone Enfants, Service de Neurologie Pédiatrique, Marseille, France

Correspondence

Nathalie Villeneuve, AP-HM, Hôpital Timone Enfants, Service de Neurologie Pédiatrique, Marseille, France.

Email: nathalie.villeneuve@ap-hm.fr

Florence Molinari, Aix-Marseille Univ, INSERM, MMG, Marseille, France.

Email: florence.molinari@inserm.fr

Funding information

A*Midex, Grant/Award Number: AMX-19-IET-004; Agence Nationale de la Recherche, Grant/Award Number: ANR-17-EURE-0029

Abstract

Developmental and epileptic encephalopathies (DEE) are a group of neurodevelopmental disorders characterized by epileptic seizures associated with developmental delay or regression. DEE are genetically heterogeneous, and the proteins involved play roles in multiple pathways such as synaptic transmission, metabolism, neuronal development or maturation, transcriptional regulation, and intracellular trafficking. We performed whole exome sequencing on a consanguineous family with three children presenting an early onset (<6 months) with clusters of seizures characterized by oculomotor and vegetative manifestations, with an occipital origin. Before 1 year of age, interictal electroencephalographic recordings were well organized and neurodevelopment was unremarkable. Then, a severe regression occurred. We identified a novel homozygous protein-truncating variant in the *NAPB* (N-ethylmaleimide-sensitive fusion [NSF] attachment protein beta) gene that encodes the β SNAP protein, a key regulator of NSF–adenosine triphosphatase. This enzyme is essential for synaptic transmission by disassembling and recycling proteins of the SNARE complex. Here, we describe the electroclinical profile of each patient during the disease course. Our findings strengthen the association between biallelic variants in *NAPB* and DEE and refine the associated phenotype. We suggest including this gene in the targeted epilepsy gene panels used for routine diagnosis of unexplained epilepsy.

KEYWORDS

developmental and epileptic encephalopathies, electroencephalogram, *NAPB* seizures, SNAP SNARE, whole exome sequencing

This is an open access article under the terms of the [Creative Commons Attribution-NonCommercial-NoDerivs](https://creativecommons.org/licenses/by-nc-nd/4.0/) License, which permits use and distribution in any medium, provided the original work is properly cited, the use is non-commercial and no modifications or adaptations are made.

© 2023 The Authors. *Epilepsia* published by Wiley Periodicals LLC on behalf of International League Against Epilepsy.

1 | INTRODUCTION

Developmental and epileptic encephalopathies (DEE) refer to a group of neurodevelopmental disorders characterized by epileptic seizures, often intractable, a severe developmental delay or regression, and a poor prognosis. With the development of next generation sequencing, DEE were shown to have a strong but highly heterogeneous genetic basis.¹

Neurotransmitter release at synapses is ensured by the fusion of presynaptic vesicles mediated by the soluble N-ethylmaleimide-sensitive fusion (NSF) protein attachment protein receptor (SNARE) complex following Ca^{2+} ion increase. After fusion, the SNARE complex disassembly relies on the NSF-adenosine triphosphatase (ATPase) associated with soluble NSF attachment protein (SNAP) adaptor proteins.² A large number of pathogenic variants have been described in proteins composing the SNARE complex and were shown to result in several neurodevelopmental syndromes including DEE.³ Recently, homozygous splice or protein-truncating variants have been described in the *NAPB* (NSF attachment protein beta; MIM#611270) gene, encoding the β SNAP protein, in four patients from three independent families presenting DEE (DEE107, MIM#620033).⁴⁻⁶ Here, we describe a consanguineous family composed of three siblings with early onset epilepsy and no specific interictal electroencephalogram (EEG) abnormalities. At the beginning of the second year of age, a developmental regression was observed leading to severe intellectual disability. Using whole exome sequencing (WES), we identified a novel homozygous deletion in the *NAPB* gene. The description of the electroclinical profile of each patient in this family allows refinement of the phenotype associated with pathogenic variants in this gene and confirmation of its involvement in DEE.

2 | PATIENTS AND METHODS

2.1 | Patients

Individuals who participated in this study were identified and clinically characterized in Marseille University Hospital (Hôpital d'Enfants de La Timone). DNA from participating family members was extracted from peripheral blood lymphocytes, stored, and delivered by the Biological Resources Center of La Timone Marseille Public University Hospital, according to the French regulation (CRB AP-HM Biobank; NF S96-900 & ISO 9001 v2015 certifications).

2.2 | Whole exome sequencing

WES was performed on the two affected brothers (II.3 and II.5), their father (I.1), and a nonaffected brother (II.1) using Twist Human Core Exome kit (Twist Bioscience) on an Illumina platform (CeGaT). For more details, see Appendix S1. Sequencing data were analyzed according to an autosomal recessive inheritance pattern. We selected variants that (1) affected the protein sequence, (2) had a minor allele frequency < .1% in the gnomAD database, (3) were predicted to be pathogenic or likely pathogenic by at least 3 of 5 in silico prediction programs, and (4) were expressed in cerebral tissue. Validation and segregation analysis of the *NAPB* variant was done using Sanger sequencing (data not shown).

3 | RESULTS

3.1 | Clinical case descriptions

The three affected children (II.2, 3, and 5) were born after a normal pregnancy from consanguineous healthy parents (Figure 1A). Two other siblings (II.1 and II.4) are healthy, with no history of seizures, epilepsy, or intellectual disability.

The clinical phenotype of the three affected patients evolved in three main phases. The first phase was an early onset epilepsy characterized by clusters of seizures starting at 1, 4, and 2 months of age for Patients II.2, 3, and 5 respectively (Table 1). Seizures had a low frequency (1–2 clusters per month) and were characterized by vegetative signs, few behavioral (wandering eyes, tonic upper limb extension, chewing, behavioral arrest) or motor symptoms (tonic upper limb extension), and facial erythrosis or cyanosis. Interictal EEGs were well organized for age, with rare posterior anomalies (II.2: from 1 to 18 months, Figure S1A; II.3: from 3 to 8 months, Figure S1B; II.5: from 6 to 12 months, Figure S1C). Initial neurodevelopment was unremarkable for the three affected children. The second phase started at approximately 7–10 months of age with an increase in seizure duration (1–3 min) and frequency (1–8 per day). Ictal EEG started with focal posterior spike discharges followed by suprasylvian propagation (Figure 1). At the end of the seizure, discharge frequency decreased, with few impacts on the contralateral hemisphere (Figure 1). Interictal awake EEG recordings showed subnormal background activity (5–6 Hz, Figure S1A). During sleep, spikes or polyspikes were observed, followed by slow waves mainly in posterior regions (Figure S1). At the beginning of the second year, all children showed neurodevelopmental regression, mainly on social aspects.

The last phase began at approximately 3 years of age, with a modification of seizures that became mainly

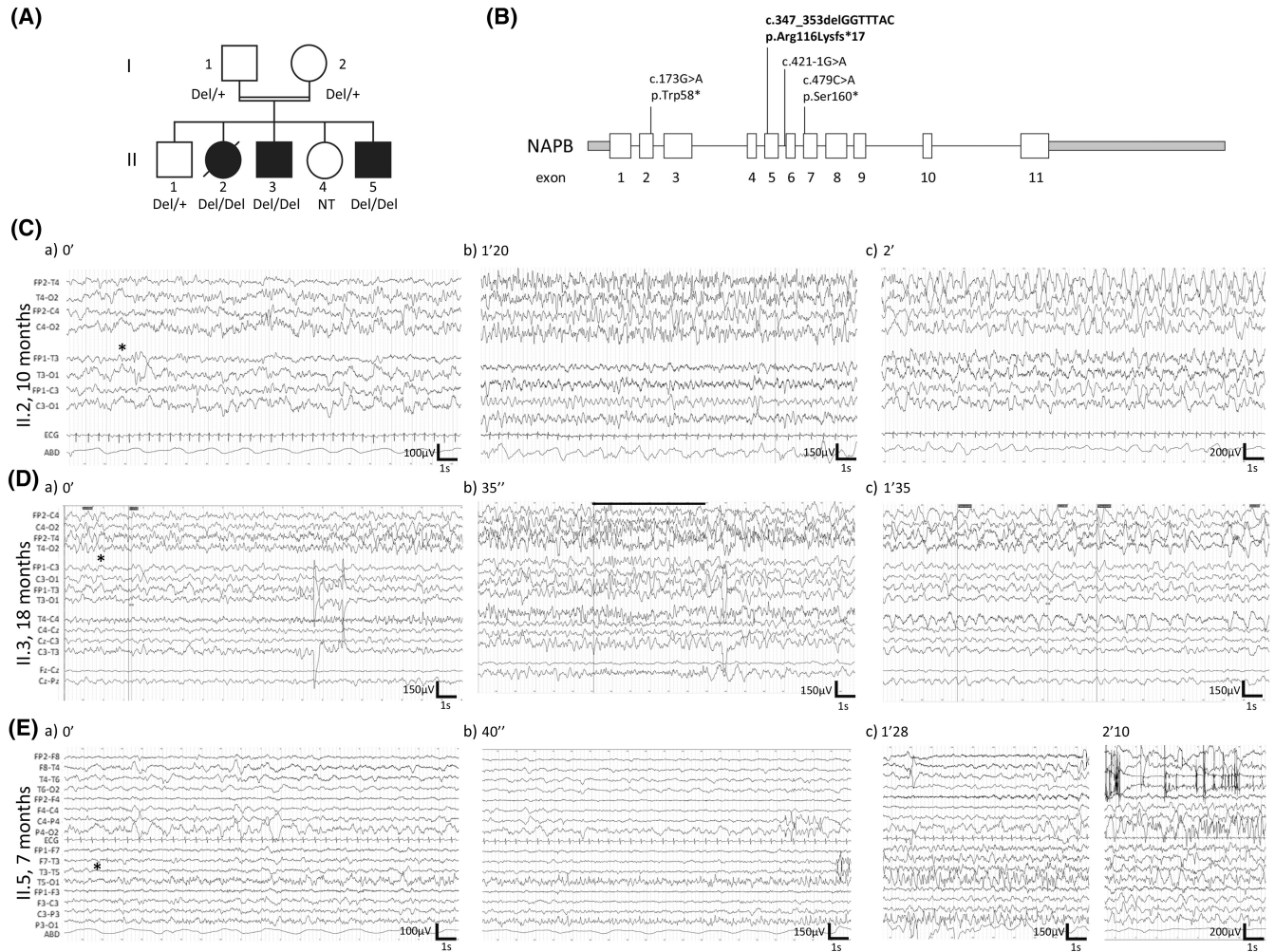


FIGURE 1 *NAPB* variant and associated electroencephalogram (EEG) description. (A) Family pedigree and genetic characteristics of individuals carrying the variant c.347_353delGGTTTAC in *NAPB* (NM_022080). Affected siblings (solid symbols) carry a homozygous deletion. +, wild-type allele; Del, deleted allele; NT, not tested. (B) Schematic representation of *NAPB* gene showing exons (white boxes), introns (black lines), and non-coding region (gray boxes). Localization of *NAPB* variants identified in our family (bold) and previously reported cases are shown. (C–E) Ictal video-EEG description of the three patients, at the beginning (a, *), during (b), and at the end of the seizure (c). Seizures were recorded awake at 10, 18, and 7 months for II.2 (C), II.3 (D), and II.5 (E), respectively. (C) Seizure lasts 3 min and starts with a right posterior subclinical discharge (1 min, 5 Hz, θ) getting richer in spikes (asterisk, Ca). Then, the discharge spreads to the entire right hemisphere, mixed with some slow waves with no impact on the left hemisphere (Cb). Finally, slow waves propagate to the left hemisphere (Cc). (D) Seizure lasts 1 min and 50 s and starts with a right temporal spike discharge (asterisk, Da), followed by a rapid suprasylvian discharge lasting 6 s (black line, Db). At the end of the seizure, diffuse bilateral slow 1.5-Hz (δ) waves predominate in the right anterior (Dc). (E) Seizure begins with a left posterior fast discharge, slowing into a spike discharge involving the left temporal area (Ea,b). At 2 min 10 s, the left posterior discharge stops, and a right posterior spike discharge appears (Ec). The end of the seizure recording is disturbed by artifact in the right suprasylvian (Ec). Times and scale are indicated for each recording. Low pass filter: 70 Hz. ECG, electrocardiogram.

nocturnal and occurred monthly. Interictal EEG recordings during sleep were disorganized, with paroxysmal abnormalities characterized by slow spikes-and-waves (Figure S1A,B).

At last evaluation, all affected children had a global neurodevelopmental disorder with delayed (II.2 and II.5) or unacquired walking (II.3), and severe language and social communication impairment. The affected girl II.2 died at 5.5 years of age from sudden unexpected death in epilepsy (SUDEP) during sleep. The youngest affected boy

presented an autism spectrum disorder associated with visual self-stimulation and stereotypies. Extensive metabolic workup and magnetic resonance imaging performed for each individual were normal (Table 1).

3.2 | Sequencing results

A targeted gene panel containing 144 genes known to be involved in epileptic syndromes (Table S1) was sequenced

TABLE 1 Summary of genetic data and clinical characteristics of patients with *NAPB* variants.

Pedigree ID	Family described here	
	II.2, deceased at 5.5 years	II.3
Sex, age at last evaluation	Female, 5 years and 3 months	Male, 11 years
Parental consanguinity	+	+
<i>NAPB</i> variant	chr20-23375625-TGTAAACC-T NM_022080:c.347_353delGGTTTAC, p.(Arg116Lysfs*19)	
ACMG classification	Likely pathogenic	
Birth		
Gestational age	40 weeks	40 weeks
Length, cm	53	Normal
Weight, g	4060	Normal
Head circumference, cm	36	Normal
Measurements at last evaluation		
Height, cm	112.5	142
Weight, kg	21.5	34
Head circumference, cm	51	50.8
Development		
Initial development	Normal psychomotor acquisition Sitting, 9 months	Normal psychomotor acquisition Sitting, 9 months Walk with assistance, 15 months
Developmental regression	Yes, at 15 months	Yes, at 18 months
Global development	Delayed Walk at 21 months Absence of language No self-feeding	Delayed After regression: no sitting or walking Absence of language No self-feeding
Intellectual disability	Severe	Severe
Social communication	–	–
Autism spectrum disorder	+	(+)
Neurological findings		
Seizures, onset	+, at 1 month	+, at 4 months
Seizure Type/Frequency	<ul style="list-style-type: none"> Onset: focal seizures characterized by a right or a left tonic extension with cyanosis <10 months: focal seizures characterized by behavioral arrest, cyanosis, and tonic extension of the upper limbs (2 clusters per month) 1–3 years: focal seizures with increased frequency (8–10 seizures per day) >3 years: monthly nocturnal generalized seizures characterized by bilateral clonic-tonic jerks 	<ul style="list-style-type: none"> Onset: focal seizures characterized by right or left clonic jerks (5–15 min) without cyanosis (low frequency) 9 months: focal seizures characterized by arrest of activity with erythrosis followed by right or left tonic extension of upper limbs, increasing frequency 1–4 years: focal seizures characterized by staring, uncontrollable eye movements from right to left, facial erythrosis, fast jerking of the upper limbs (1 per day to 1 per month) >4 years: nocturnal generalized seizures (1 or 2 per year)
AED treatment	CBZ, VPA, CLB, TPM	PB, VPA, TPM, CLB
Brain MRI, age	Normal (10 months)	Normal (2 years)

Abbreviations: –, absence; +, presence; ACMG, American College of Medical Genetics and Genomics; AED, antiepileptic drug; CBZ, carbamazepine; CLB, clobazam; DZP, diazepam; FDS, Focal dyscognitive seizures; GTCS, generalized tonic-clonic/bilateral convulsive seizures; LEV, levetiracetam; MRI, magnetic resonance imaging; NA, not available; PB, phenobarbital; PHT, phenytoin; TPM, topiramate; VPA, valproate.

II.5	Family described in Conroy et al. ⁴	Family described in Reuter et al., ⁵ ER53330	Family described in Zhao et al. ⁶	
			II.1	II.2
Male, 4 years	Female, 6 years	Male, not indicated	Female, 13 years	Male, 8 years
+	+	+	–	–
	chr20-23370665-G-T NM_022080: c.479C>A, (p.Ser160*)	chr20-23383635-C-T NM_022080 c.173G>A (p.Trp58*)	chr20-23370902-C-T NM_022080.3:c.421-1G>A	
	Likely pathogenic	Likely pathogenic	Likely pathogenic	
40 weeks	Full term	NA	37 weeks	38 weeks
50		NA	Normal	Normal
4070	3100	NA	Normal	Normal
37		NA	<–3 SD	NA
87 (+2 SD)			140 (–2 SD)	110 cm (–3 SD)
14.8 (+2.5 SD)			31.5 (–2 SD)	16.5 (–3 SD)
47.8	Progressive microcephaly	Microcephaly		Microcephaly (<–3 SD)
Normal psychomotor acquisition Sitting, 9 months				
Yes, at 15 months	Yes, at 8 months	NA	Yes, at 8 months	NA
Delayed	Delayed	NA	Delayed	Delayed
Walk at 2 years	Sitting with support		Walk unsteadily	No walking
Absence of language	Walk with assistance		Absence of language	Absence of language
No self-feeding	Absence of language		No self-feeding	No self-feeding
	No self-feeding			
Severe	Severe	+	Severe	Severe
–	NA	NA	NA	NA
+	NA	NA	NA	NA
+, at 2 months	+, at 5 months	+, NA	+, at 6 months	+, at 2 months
<ul style="list-style-type: none"> Onset: focal seizures characterized by unilateral right or left clonic jerks with rare cyanosis (1 cluster per month) 7–12 months: focal seizures characterized by eye deviation, erythrosis, slight cyanosis, increasing frequency 1–3 years: longer focal seizures with eye deviation, lip and face cyanosis but no shaking or tonus modification (1–7 seizures per day) >3 years: rare nocturnal generalized seizures (1 or 2 per year) 	<ul style="list-style-type: none"> Onset: tonic-clonic, right side (4 per day) 8–24 months: brief focal and GTCS, FDS (daily, with some free days) 2–4 years: FDS and tonic seizures, occasional motor involvement (daily) 5 years: flurries of focal clonic or myoclonic, right side (occasionally) 6 years: Nocturnal tonic and FDS (decreased frequency) 		<ul style="list-style-type: none"> 7 years: multifocal epileptic encephalopathy 	
CBZ, PB, DZP	VPA, PHT (seizure reduction), CBZ (replace PHT) TPM at 8 months; stopped GTCS. 3rd year: LEV (replace CBZ)	NA	NA	NA
Normal (2 months)	Normal (2 years)	NA	Normal (7 years)	NA

for each individual. A de novo missense variant located in exon 7 of the *SCN8A* (sodium voltage-gated channel, alpha subunit 8) gene was identified in Patient II.2 (Hg19 chr12:52094949G>C:NM_014191:c.950G>C:p.[Gly317Ala]).⁷ This variant was absent from the gnomAD (v2.1.1) and ClinVar databases, and was predicted to be damaging by 18 prediction tools out of 20 (<https://varso.me.com/>).⁸ Because this variant was absent from her affected siblings, exome sequencing was performed on the two affected boys (II.3 and II.5), their healthy brother (II.1) and father (I.1) to identify other pathogenic variants. Because of consanguinity, we focused our analysis on a recessive mode of inheritance, and variant filtering was performed as described in the methods. We found a homozygous 7-base-pair deletion in the two affected brothers, located in exon 5 of the *NAPB* gene (Hg19 chr20:23375625TGTAAC>T:NM_022080:c.347_353del:p.[Arg120Lysfs*19]; Figure 1B, Figure S2). We confirmed using sanger sequencing that this protein-truncating variant (PTV), which affects all *NAPB* isoforms, was homozygous for their affected sister (II.2), and heterozygous for both parents and their healthy child (II.1). It has never been described in the literature^{4–6} or gnomAD (v2.1.1), ClinVar, or LOVD (v3.0) databases (Figure 1A,B). No other homozygous or compound heterozygous variants that could explain the clinical phenotype were identified (Tables S2 and S3).

4 | DISCUSSION

This report of three additional patients strongly supports the gene–disease association between *NAPB* and DEE. Seven patients from four independent families have now been described with homozygous PTV (nonsense or splicing variants) in *NAPB* (Figure 1B, Table 1). All patients presented with early onset seizures (before 6 months of age) associated with a global neurodevelopmental disorder characterized by developmental regression at approximately 15 months of age leading to severe intellectual disability with language and social impairment. Noticeably, patients do not present any dysmorphic features or cerebral malformations and microcephaly is not always present (Table 1). Based on the 2022 International League Against Epilepsy classification, this syndrome is part of the DEE group.⁹ In this group, many syndromes show abnormal interictal epileptiform discharges such as suppression burst, multifocal discharges, or excessive slowing. Patients with an *NAPB* variant show very few interictal abnormalities, even when seizure frequency increases and developmental regression sets in. In the DEE group, only Dravet syndrome (DS) and the *CDKL5*-related epilepsy present frequent seizures with a normal interictal

EEG at the beginning of epilepsy. However, in DS, developmental progress slows at the end of the second year of age, whereas *NAPB* patients show developmental regression at the beginning of the second year.^{9,10} Moreover, we do not observe seizures triggered by fever, nor myoclonic or atypical absence seizures, which are often present in DS.⁹ Interestingly, increase of seizure frequency in *NAPB* patients is not linked to a seizure type modification or to occurrence of spasms, as it can be observed in *STXB1*-related epilepsy,^{11,12} nor to a profound EEG alteration. The *NAPB* epilepsy etiology is specific, with three successive stages: (1) early epilepsy onset with tonic focal seizures associated with facial erythrosis or cyanosis and normal neurodevelopment, (2) increased tonic seizure frequency and developmental regression, and (3) epileptic encephalopathy with nocturnal seizures.

Affected girl II.2 presented an earlier seizure onset (1 month) compared to her brothers and premature death at age 5.5 years from SUDEP during sleep. In addition to the PTV in *NAPB*, she had a likely pathogenic de novo variant in *SCN8A*. This gene encodes the Nav1.6 voltage-dependent sodium channel that initiates membrane depolarization for the generation of action potential. Pathogenic variants in *SCN8A* cause several neurological diseases, including DEE (MIM#614558).¹³ Usually, patients with *SCN8A*-related epilepsy respond well to sodium channel blockers such as carbamazepine (CBZ). Here, the patient's seizures were well controlled by valproate but CBZ had no effect (Table 1).⁷ At this stage, only functional studies on the *SCN8A* variant p.(Gly317Ala) could help to reveal precisely how it could contribute to the patient's clinical features. The cumulative effect of two variants in two epilepsy-related genes could explain the earlier onset of seizures and death.

NAPA and *NAPB* encode the alpha and beta SNAP proteins (α/β SNAP), two highly homologous cofactors of NSF-ATPase. This enzyme is essential for synaptic transmission, because it disassembles and recycles proteins of the SNARE complex.¹⁴ *NAPA* is ubiquitously expressed in mammals (Figure S3),¹⁵ and the knockout (KO) mouse model is embryonically lethal.¹⁶ The natural hypomorphic mouse model HYH (hydrocephalus with hop gait) contains a homozygous recessive missense mutation (p.M105I) in *Napa* resulting in decreased α Snap protein expression without affecting its function.^{14,16} These mice show a smaller cerebral cortex associated with an alteration of the neuronal cell fate but no epilepsy,¹⁶ synaptic transmission, or plasticity alterations.¹⁴ *NAPB* is almost exclusively expressed in the postnatal brain (Figure S3),^{14,15} and the β Snap-KO mice develop spontaneous recurrent epileptic seizures at postnatal day 11 (P11) followed by ataxia that could lead to death.¹⁴ Brain morphology is normal, and expression of the other SNARE proteins is unchanged. Basic

synaptic transmission and short-term plasticity in autaptic hippocampal neurons is normal together with synapses number.¹⁴ β SNAP has been less studied than α SNAP, but in vitro studies showed that α - and β SNAP have equivalent function, leading to the hypothesis that α SNAP could compensate for β SNAP absence.^{14,17} However, despite *NAPA* expression in the brain,^{15,16} the β Snap-KO develops recurrent epileptic seizures, suggesting that this compensation is no longer sufficient from P11 onward. The α - and β SNAP proteins are involved in the recycling of the SNARE protein complex to release them for a next round of docking and fusion events. If β SNAP is no longer available, recycling of the SNARE proteins could be disturbed, leading to a decrease of the synaptic vesicle fusion and to a decrease of neurotransmitter release, particularly during sustained neuronal stimulation. This mechanism has been suggested in epileptic encephalopathy linked to SNARE proteins, named “SNAREopathies,” mainly for *STXBP1*, *SNAP25*, and *STX1B*.³

In conclusion, the description of a fourth family that associates DEE and *NAPB* variants strongly supports that *NAPB* is a novel DEE-related gene. An extended study of the β Snap-KO mice and in vitro analyses of induced pluripotent stem-derived neurons¹⁸ would help to better understand the pathophysiological mechanism involved in *NAPB*-related DEE. Because multigene panels are still often used as first-tier testing,^{19,20} we suggest including *NAPB* but strongly recommend using exome and genome sequencing to identify and describe more *NAPB* patients and better understand the associated phenotypes.

AUTHOR CONTRIBUTIONS

Cécile Mignon-Ravix, Laurent Villard, and Florence Molinari designed the experiments, interpreted data, and wrote the initial manuscript. Cécile Mignon-Ravix analyzed and interpreted WES data and performed validation of variants. Cécile Mignon-Ravix, Nathalie Villeneuve, and Florence Molinari designed figures and tables. Florence Riccardi, Sylvie Lamoureux-Toth, and Nathalie Villeneuve performed clinical follow-up of the family. Géraldine Daquin, Sylvie Lamoureux-Toth, and Nathalie Villeneuve performed and interpreted EEG recording. Pierre Cacciagli extracted, stored, and delivered DNA from participating family members. All authors contributed to and revised the manuscript.

ACKNOWLEDGMENTS

We are grateful to all family members who participated in this study. We thank the Genomics and Bioinformatics Platform of the Marseille Medical Genetics Center for their support and Auriane Caurette for technical assistance. This work was supported by Institut National de la Santé et de la Recherche Médicale, Aix-Marseille University,

and Assistance Publique des Hôpitaux de Marseille. F.R. has received 1-year financial support from the NeuroMarseille Institute through the French government program Investissements d'Avenir, Initiative d'Excellence d'Aix-Marseille Université via A*Midex funding (AMX-19-IET-004), and ANR (ANR-17-EURE-0029) for this work.

CONFLICT OF INTEREST STATEMENT

None of the authors has any conflict of interest to disclose. We confirm that we have read the Journal's position on issues involved in ethical publication and affirm that this report is consistent with those guidelines.

ORCID

Laurent Villard  <https://orcid.org/0000-0001-6657-5008>

Florence Molinari  <https://orcid.org/0000-0001-5111-7215>

REFERENCES

1. Hebbar M, Mefford HC. Recent advances in epilepsy genomics and genetic testing. *F1000Res*. 2020;9:F1000 Faculty Rev-185.
2. Sudhof TC. The synaptic vesicle cycle. *Annu Rev Neurosci*. 2004;27:509–47.
3. Verhage M, Sørensen JB. SNAREopathies: diversity in mechanisms and symptoms. *Neuron*. 2020;107:22–37.
4. Conroy J, Allen NM, Gorman KM, Shahwan A, Ennis S, Lynch SA, et al. *NAPB* – a novel SNARE-associated protein for early-onset epileptic encephalopathy. *Clin Genet*. 2016;89:E1–3.
5. Reuter MS, Tawamie H, Buchert R, Hosny Gebriel O, Froukh T, Thiel C, et al. Diagnostic yield and novel candidate genes by exome sequencing in 152 consanguineous families with neurodevelopmental disorders. *JAMA Psychiat*. 2017;74:293–9.
6. Zhao X, Wang Y, Cai A, Mei S, Liu N, Kong X. A novel *NAPB* splicing mutation identified by trio-based exome sequencing is associated with early-onset epileptic encephalopathy. *Eur J Med Genet*. 2021;64:104101.
7. Denis J, Villeneuve N, Cacciagli P, Mignon-Ravix C, Lacoste C, Lefranc J, et al. Clinical study of 19 patients with *SCN8A*-related epilepsy: two modes of onset regarding EEG and seizures. *Epilepsia*. 2019;60:845–56.
8. Kopanos C, Tsiolkas V, Kouris A, Chapple CE, Albarca Aguilera M, Meyer R, et al. VarSome: the human genomic variant search engine. *Bioinformatics*. 2019;35:1978–80.
9. Zuberi SM, Wirrell E, Yozawitz E, Wilmshurst JM, Specchio N, Riney K, et al. ILAE classification and definition of epilepsy syndromes with onset in neonates and infants: position statement by the ILAE task force on nosology and definitions. *Epilepsia*. 2022;63:1349–97.
10. Villeneuve N, Laguitton V, Viellard M, Lépine A, Chabrol B, Dravet C, et al. Cognitive and adaptive evaluation of 21 consecutive patients with Dravet syndrome. *Epilepsy Behav*. 2014;31:143–8.
11. Balagura G, Xian J, Riva A, Marchese F, Ben Zeev B, Rios L, et al. Epilepsy course and developmental trajectories in *STXBP1*-DEE. *Neurol Genet*. 2022;8:e676.

12. Di Meglio C, Lesca G, Villeneuve N, Lacoste C, Abidi A, Cacciagli P, et al. Epileptic patients with de novo STXBP1 mutations: key clinical features based on 24 cases. *Epilepsia*. 2015;56:1931–40.
13. Talwar D, Hammer MF. SCN8A epilepsy, developmental encephalopathy, and related disorders. *Pediatr Neurol*. 2021;122:76–83.
14. Buralossi A, Jung S, Meyer G, Jockusch WJ, Jahn O, Taschenberger H, et al. SNARE protein recycling by α SNAP and β SNAP supports synaptic vesicle priming. *Neuron*. 2010;68:473–87.
15. Whiteheart SW, Griff IC, Brunner M, Clary DO, Mayer T, Buhrow SA, et al. SNAP family of NSF attachment proteins includes a brain-specific isoform. *Nature*. 1993;362:353–5.
16. Chae TH, Kim S, Marz KE, Hanson PI, Walsh CA. The hyh mutation uncovers roles for alpha Snap in apical protein localization and control of neural cell fate. *Nat Genet*. 2004;36:264–70.
17. Sudlow AW, McFerran BW, Bodill H, Barnard RJ, Morgan A, Burgoyne RD. Similar effects of alpha- and beta-SNAP on Ca(2+)-regulated exocytosis. *FEBS Lett*. 1996;393:185–8.
18. Ali G, Habbab W, Alkhadairi G, Al-Shaban FA, Stanton LW. Generation of induced pluripotent stem cell lines from nonaffected parents and monozygotic triplets affected with autism spectrum disorder and epilepsy. *Stem Cell Res*. 2022;65:102943.
19. Sheidley BR, Malinowski J, Bergner AL, Bier L, Gloss DS, Mu W, et al. Genetic testing for the epilepsies: a systematic review. *Epilepsia*. 2022;63:375–87.
20. Smith L, Malinowski J, Ceulemans S, Peck K, Walton N, Sheidley BR, et al. Genetic testing and counseling for the unexplained epilepsies: an evidence-based practice guideline of the National Society of genetic counselors. *J Genet Couns*. 2022;32:266–80. <https://doi.org/10.1002/jgc4.1646>

SUPPORTING INFORMATION

Additional supporting information can be found online in the Supporting Information section at the end of this article.

How to cite this article: Mignon-Ravix C, Riccardi F, Daquin G, Cacciagli P, Lamoureux-Toth S, Villard L, et al. *NAPB* and developmental and epileptic encephalopathy: Description of the electroclinical profile associated with a novel pathogenic variant. *Epilepsia*. 2023;00:1–8. <https://doi.org/10.1111/epi.17603>