



HAL
open science

Monkeypox clinical disease: Literature review and a tool proposal for the monitoring of cases and contacts

Emilie Javelle, Cécile Ficko, Hélène Savini, Marie Mura, Olivier Ferraris, Jean Nicolas Tournier, Franck de Laval

► To cite this version:

Emilie Javelle, Cécile Ficko, Hélène Savini, Marie Mura, Olivier Ferraris, et al.. Monkeypox clinical disease: Literature review and a tool proposal for the monitoring of cases and contacts. *Travel Medicine and Infectious Disease*, 2023, 52, pp.102559. 10.1016/j.tmaid.2023.102559 . hal-04082411

HAL Id: hal-04082411

<https://amu.hal.science/hal-04082411>

Submitted on 18 Jul 2023

HAL is a multi-disciplinary open access archive for the deposit and dissemination of scientific research documents, whether they are published or not. The documents may come from teaching and research institutions in France or abroad, or from public or private research centers.

L'archive ouverte pluridisciplinaire **HAL**, est destinée au dépôt et à la diffusion de documents scientifiques de niveau recherche, publiés ou non, émanant des établissements d'enseignement et de recherche français ou étrangers, des laboratoires publics ou privés.



Distributed under a Creative Commons Attribution 4.0 International License



Monkeypox clinical disease: Literature review and a tool proposal for the monitoring of cases and contacts

Emilie Javelle^{a,b,c,*}, Cécile Ficko^{d,e}, Hélène Savini^{b,c}, Marie Mura^{f,g}, Olivier Ferraris^{f,h}, Jean Nicolas Tournier^{e,f,g}, Franck de Laval^{i,j}

^a Institut de Recherche Biomédicale des Armées IRBA, Microbiology and Infectious Diseases Department, Marseille, France

^b Aix Marseille Univ, IRD, AP-HM, SSA, VITROME, Marseille, France

^c Laveran Military Teaching Hospital, Marseille, France

^d Bégin Military Teaching Hospital, Saint-Mandé, France

^e Ecole Du Val-de-Grâce, Paris, France

^f Institut de Recherche Biomédicale des Armées IRBA, Microbiology and Infectious Diseases Department, Brétigny-sur-Orge, France

^g Institut Pasteur, Innovation Lab: Vaccines, Paris, France

^h CNR-LE National Reference Center-expert Laboratory Orthopoxvirus, IRBA, Brétigny-sur-Orge, France

ⁱ Service de Santé des Armées SSA, French Armed Forces Center for Epidemiology and Public Health CESPA, Marseille, France

^j Aix Marseille University, INSERM, IRD, Sciences Economiques Sociales de La Santé & Traitement de L'Information Médicale SESSTIM, Marseille, France

ARTICLE INFO

Keywords:

Clinical questionnaire
Follow-up
Surveillance
Outbreak
Epidemic
Emergence

ABSTRACT

The human monkeypox disease has mainly been described in Western and Central Africa. Since May 2022, the monkeypox virus has been spreading worldwide in a new epidemiological pattern, where cases result from person-to-person transmission, and develop clinically milder or less typical illness than during previous outbreaks in endemic areas. The newly-emerging monkeypox disease needs to be described over the long term, to improve cases definitions, to implement prompt control measures against epidemics, and to provide supportive care. Hence, we first conducted a review of historical and recent outbreaks to define the full clinical spectrum of the monkeypox disease and its course known so far. Then, we built a self-administrated questionnaire collecting daily symptoms of the monkeypox infection to follow cases and their contacts, even remotely. This tool will assist in the management of cases, the surveillance of contacts, and the conduct of clinical studies.

1. Introduction

Since early May 2022, the monkeypox virus (MPXV) has been emerging worldwide. As of October 15, 2022, 73,426 cases have been confirmed in 110 countries [1]. Transmission of MPXV is documented through contact with lesions, contaminated materials, or respiratory droplets. Yet, the recent rapid increase in the number of cases worldwide without links to endemic areas, suggests the start and the means of the virus' spread were not detected [2]. Facing any newly-emerging infectious disease, key knowledge is required to implement a global efficient control strategy. In a public health view, definitions of cases must be continuously updated to enhance their sensitivity [3–8]. In that aim, atypical and mild forms, which escape classical definitions and lead to the under-detection of cases, must be identified. Moreover, given imprecisions on the period and routs of contagiousness, clinical signs must be thoroughly monitored to decide for discontinuation of isolation

precautions [9]. Besides, characterizing the population at-risk of infection, determining the incubation periods and the chronology of symptoms, help to identify secondary cases and to prevent from further transmission. In clinical practice, the whole clinical spectrum and course of the illness must be assessed, as well as its complications, mortality rates and sequelae. Clinical warning signs and risk factors of severe disease must be identified to assist in the decision to administer specific treatments and to target preventive measures such as vaccination. Lastly, in low-resource settings, or in order to limit the risk of nosocomial transmission and to prevent from overwhelming healthcare facility, out-patient management may be preferably implemented with periodic medical teleconsulting.

In response to the ongoing multistate outbreak of MPX, we developed a self-administrated questionnaire to monitor daily symptoms of MPX cases and contacts, based on a literature review on the historical and current clinical MPX disease. This easy-to-use tool should be helpful to manage patients and their contacts over an extended period, and to

* Corresponding author. IHU Méditerranée Infection, 19-21 boulevard Jean Moulin, 13005, Marseille, France.

E-mail address: emilie.javelle@gmail.com (E. Javelle).

<https://doi.org/10.1016/j.tmaid.2023.102559>

Received 2 July 2022; Received in revised form 26 October 2022; Accepted 17 February 2023

Available online 22 February 2023

1477-8939/© 2023 The Authors. Published by Elsevier Ltd. This is an open access article under the CC BY license (<http://creativecommons.org/licenses/by/4.0/>).

| Abbreviations | |
|---------------|----------------------------------|
| DRC | Democratic Republic of the Congo |
| HIV | human immunodeficiency virus |
| HSV | Herpes Simplex Virus |
| IQR | interquartile range |
| MPX | monkeypox |
| MPXV | monkeypox virus |
| MSM | men who have sex with men |
| PCR | Polymerase Chain Reaction |
| STI | sexually transmitted infections |
| VZV | Varicella-Zoster Virus |

conduct long-term prospective studies to address remaining gaps in our understanding of the emerging MPX disease.

2. Methods

A prospective systematic literature search was started on June 1, 2022 in MEDLINE® (PubMed), using the following terms: “clinical” AND “monkeypox” AND “human”. No date range was specified. A first selection was performed based on titles, excluding non-clinical studies. Then, articles were screened on the abstract content and excluded when out of the scope. Studies, case reports, case series and reviews were

included. Articles in English and French were reviewed. Of the full-text articles assessed for eligibility, some were rejected due to study quality or inaccessibility. The review was complemented with papers from hand searches of references listed in articles. Finally, we reiterated the research while reviewing the article on the October 15, 2022 to include the most recent peer-reviewed cohort studies and relevant case reports. The flowchart of the review was built on the model of the PRISMA 2020 flow diagram [10]. All included articles were reviewed to list exhaustively clinical signs, complications, mortality rates and sequelae reported associated with MPX disease. Features identified through the literature review were integrated into the monitoring grid, which was illustrated with pictures acquired from one consenting patient and from the license free images database Shutterstock.

3. Results

3.1. Clinical review

Ultimately, 80 published articles were reviewed (Fig. 1), including 28 articles from past epidemics in Western and Central Africa since 1970; 8 articles from occasional transmission in non-endemic countries occurring between 2003 and 2019; 30 articles presenting cases of the ongoing multi countries outbreak; and 14 reviews or meta-analyses (Appendix). The incubation period ranged from 4 days [11,12], to a maximum of 24 days [13,14]. Based on the first 18 cases identified in May 2022 in Netherland, the mean incubation period was estimated 8.5 days, 95% credible interval [6.6–10.9] [15]. Further series in 2022

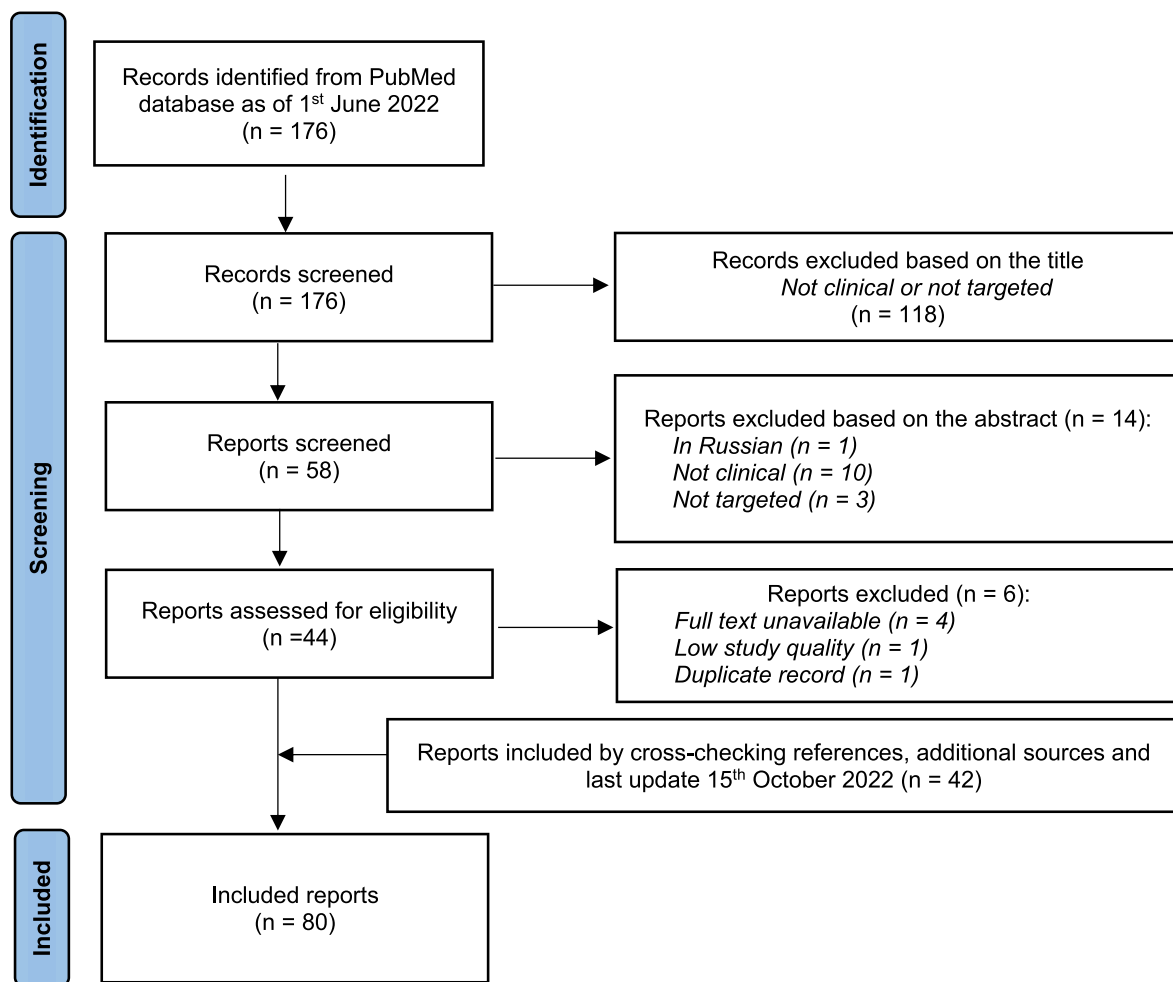


Fig. 1. Literature search and study selection, adapted from “PRISMA 2020 flow diagram for new systematic reviews, which included searches of databases and registers only”.

reported a median incubation period of 11 days, interquartile range between the 75th and 25th percentile (IQR) [11–16,16]; of 7 days, IQR [5–10,17] or 7 days, range [3–18,18–20]; and of 6 days, IQR [3–8,19] or 6 days, IQR [4–9,20]. Across all records reviewed, the uncomplicated MPX disease lasted between 14 and 28 days (Appendix). All the clinical features ever reported are listed in the Table 1. Frequencies of symptoms and their evolution through epidemics are discussed in the text and detailed in the Appendix. The generally low quality of historical studies, mainly due to small sample sizes or methods of recruiting subjects, made unreliable incidences calculation and comparison, as illustrated by recent meta-analyses which included very few reports [21,22].

3.1.1. The classical eruptive MPX disease

The “typical” disease reported in historical series, was characterized by a three-day prodromal often-febrile illness before the eruption. Associated signs may include malaise, various aches and pains, and respiratory or digestive symptoms (Table 1 and Appendix). Lymph nodes enlargement was observed in up to 90% of MPX cases, and may concern all palpable lymphatic areas, with a potential mass effect [5, 23–25]. Skin lesions developed more or less simultaneously and evolved together at the same rate through macules, papules, vesicles, and pustules before umbilicating, drying, and desquamating over a course of two or three weeks. Lesions were most prominent on the head and extremities with a classical centrifugal distribution. Lesions size varied from 0,1 to 1 cm in diameter, but may be over 2 cm, notably in people living with human immunodeficiency virus (HIV) [26]. In the 70s, three stages of the disease based on the severity of rash were identified: mild illness (less than 25 lesions, with no incapacity, not usually requiring

medical care), moderate disease (more than 25 lesions, with moderate incapacity, usually requiring medical care), and severe disease (more than 100 lesions, severe incapacity, requiring medical care) [27,28]. Later on, a “serious” stage also named “extremely grave”, with more than 250 lesions was added, and the triad of fever intensity, rash burden, and degree of prostration was used as a measure of overall MPX illness severity [13]. Lesions could be deep-seated or superficial [4,27], and may involve the entire body, notably the palms and soles (50–90%), and all mucosal membranes. Generalization of the rash occurred within a few days, but sometimes new lesions appeared afterwards [25]. Focal areas of hemorrhage or necrosis in skin lesions were punctually reported, and hemorrhagic pustules were observed in 13% of cases during the Nigerian outbreak in 2017 [25,26,29]. Pruritus has been reported with a frequency ranging from 0 to 75% [30,31]; while alopecia has been occasionally described [32]. Lesions on mucous membranes were frequent (around 70%), predominantly in the mouth and oropharynx with rare buccal bleeding [33,34]. Conversely, in Nigeria, skin rashes dominated on the genitalia (68% of cases) and genital ulcers occurred in all patients infected with HIV [26].

3.1.2. Atypical or mild forms

Before 2022, divergent clinical presentations between African and non-African outbreaks had been highlighted, that could be related to the mode and source of transmission, the age of population, the ethnic groups, the virulence of the viral strain, nutritional or medical status, access to medical care, and the prevalence of prior smallpox vaccination [35,36]. Importantly, routes of infection and exposure settings may influence the incubation period, illness manifestations and progression

Table 1

Clinical signs of MPX disease, reported as of October 15, 2022.

| SKIN | MUCOUS MEMBRANES | LYMPH NODES | OTHERS | COMPLICATIONS | SEQUELAE |
|---|--|--|--|--|---|
| Localized or generalized, from 1 to more than 250 lesions | Conjunctive, cornea, eyelid involvement | Submaxillar, post auricular, cervical, axillar, inguinal | Fever | Fever rebound | Pigmentation disorders |
| Scalp involvement | Mouth, tongue, oropharynx, tonsils, involvement | Unilateral or bilateral enlargement | Chills, sweats, shivering | Skin or soft-tissue local infection (abscess, erysipelas, cellulitis, gangrene) | Scars |
| Palms and soles involvement | External genitalia, pelvis involvement | Swelling without redness | Asthenia, exhaustion | Necrosis, eschar, loss of skin tissue | Pitted scars |
| No skin area spared | Rectum, anus, perianal region, involvement | Swelling with redness and warmth | Anorexia | Dysphagia, swallowing problems, inability to eat or drink | Pockmarks |
| Macules, redness, exanthema | Redness, enanthema, hyperaemia | Firm and tender swelling | General malaise | Dehydration | Atrophic scars |
| Papules | Vesicles | Pain | Sore throat, odynophagia | Severe pain | Hypertrophic scars, keloids |
| Pustules | Ulcers | Compression | Headache | Disabilities, bed-ridden | Patchy alopecia |
| Vesicles | Sores | Obstruction | Backache | Loss of vision | Weak vision, blindness |
| Ulcerations | Fissures (e.g. perleche; palpebral, folds or anal fissure) | | Myalgia, arthralgia | Dysuria, difficulties in urination | Contracture or deformity of muscles after ulcer's healing |
| Haemorrhagic lesions | Crusts | | Nasal congestion or runny nose | Difficulties in defecation, purulent or bloody stools | Sadness, depressed mood |
| Necrotic lesions | White patches, opacities, thrush | | Cough with or without sputum | Paraphimosis or phimosis | Physical disability |
| Crusts, scabs | Oedema, swelling | | Sneeze | Signs of concomitant infection with bacteria or virus | |
| Itching | Pain, tenesmus | | Chest tightness | Shortness of breath, difficulty breathing, polypnea | |
| Swelling | | | Diarrhea, nausea, vomiting | Somnolence, obnubilation, prostration | |
| Pain | | | Abdominal pain | Seizures, muscle rigidity, limb weakness, neural palsy | |
| | | | Rectal pain | Mood disturbance | |
| | | | Sensitivity to light/ photophobia | Miscarriage, spontaneous abortion, premature rupture of membrane, or fetal death | |
| | | | Neck stiffness | Bleeding | |
| | | | Irritability, listlessness, distress, lethargy | Low blood pressure, septic shock, multiorgan failure | |

[13,37]. Mainly, milder and atypical expression in young adults were highlighted during the first outbreaks in non-endemic regions [35, 38–41]. First, the typical generalized rash with centrifugal distribution of skin lesions was observed in less than a half of the US cases in 2003, 47% of cases having less than 25 skin lesions [29]. Second, the pleiomorphism of skin lesions (i.e. different stages in the evolution), was previously reported in a low frequency (10–37%) [5,23,26,29,34,42, 43]. However, it was observed in all cases in the UK in 2017 [38]. Third, lymphadenopathy were generally less frequent (around 50%) than in African series [40,44,45], as well as oral and ocular lesions [14,29,38].

In the first cases reported in 2022, skin rash was predominantly asynchronous and distributed in the pelvic, genital and perianal areas, while extra-inguinal lymph nodes were observed in less than 20% of cases [12,22,44]. Since then, series have highlighted the primarily occurrence of cases within the men who have sex with men (MSM) community (92–98%), and have confirmed the unusual prominent involvement of the anogenital region (33–94%) combined with an atypical or even absent invasive phase [17–20,46–50]. Notably, proctitis, as well as anal and rectal ulcers or fistula, with pain that may require intravenous morphine, were very evocative of MPX [17,18,46, 51,52]. Other highly prevalent conditions in current MPX cases include HIV infection (prevalence up to 52% in series), prior history of other sexually transmitted infections (STI), and multiple sexual partners [17, 18,46,47,49,53–55]. The MPX disease most likely starts at the site of inoculation [13,14,20,46], so that the onset of the rash on the face is not an absolute rule [16,19,35,46–49]. Notably, initial or exclusive genital and/or anorectal rash was highly frequent in patients reporting receptive anal sex, supposing MPX acquisition through sexual contacts [11, 12,17,40,41,44,46,56–59,59]. Besides, sexual transmission was suspected during the 2017-outbreak in Nigeria, through close skin to skin contact during sexual intercourse, or due to MPXV transmission via genital secretions [60]. Moreover, a genital reservoir of the virus was hypothesized in a UK-case presenting relapse of genital MPX 75 days after the illness onset and shortly after a sexual intercourse [38]. In the current epidemic, MPXV DNA has been detected in seminal fluid [40,58, 61,62], and MPXV has been punctually cultured from semen samples, indicating possible viral shedding [63,64], but additional evidence for semen infectivity are required [65]. Likewise, oropharyngeal symptoms, including pharyngitis, epiglottitis, odynophagia, and oral or tonsillar lesions were reported in up to 40% of patients in 2022 [19,46,66], and tonsillitis has been associated with receptive oral sex [17,48,49,66]. In the largest series of the ongoing outbreak, eyes involvement was occasionally reported with a prevalence below 3%, and conjunctivitis or keratitis mostly resulted from dissemination of a palpebral lesion [18–20,48,54,67,68]. Thus the rare occurrence of ocular complications is likely to be related to the poor involvement of the facial area [18–20, 48,49]. Currently, “atypical” cutaneous signs are paradoxically mainly observed, including erythematous macular rash, uni- or pauci-lesional presentation, asynchronous and polymorphic appearance, eruption in several flare-ups or secondarily generalized [16,18–20,46–48,50,69]. Unlike historical descriptions, typical papular lesions, palmoplantar area involvement and enlarged painful lymph nodes are uncommon, while lymphadenopathy are almost never generalized but rather satellite of skin lesions [12,17–20,46,47].

3.1.3. Asymptomatic MPX infections

Few cases without skin lesions have been reported in literature before 2022, but this is directly linked to the screening strategy in endemic countries, which relies on clinical definitions of suspected cases, so that only persons presenting with a vesiculopustular rash were tested for MPX. Basically, an eruptive forms of the disease exist and could have been underdiagnosed [18,29,39,42,70]. During epidemics in the Democratic Republic of the Congo (DRC, ex Zaire) in the 80s, 3% of the unvaccinated contacts who had no history of skin rash, had positive serological results for MPX [71]. In 2022, among asymptomatic MSM routinely screened for bacterial STI, 6% were tested positive for MPXV

infection by polymerase chain reaction (PCR) [63,72,73]. In a French series of MPX cases, 5% were asymptomatic and not vaccinated against smallpox, being tested due to recent high-risk exposure [46]. These data rise concerns on subclinical MPXV infections and their potential contagiousness [40,69].

3.1.4. Severity and complications

Defects in the protective barriers of skin and mucosa, vomiting, diarrhea, or difficulties in drinking and eating due to oropharyngeal lesions, may induce dehydration and protein loss [20,74,75]. In all series, superinfections were the most frequent complications, including cellulitis, abscess, gangrene, or bloodstream bacterial infections (Appendix). Deep tissue viral abscess without communication with superficial lesions was also described [38,42]. Parotiditis, otitis and mastoiditis were anecdotally noticed [30,76]. Ocular lesions may complicate in keratitis with ulcers and corneal opacities impairing the vision [19,67,68]. The anogenital involvement described in 2022 may result in penile edema with (para)phimosis; and in proctitis with severe pain, rectal bleeding, purulent or bloody stools, even leading to rectal perforation [17,46,48,51,55,77]. Bronchopneumonia, either due to the virus or to secondary bacterial infections, was the most fatal complication with 65% mortality rate in Africa [24,71,78]. Meningoencephalitis was previously reported in young children and HIV-immunosuppressed patients [26,42]. Incidence was usually reported to be less than 1%, but can be estimated 2% during the 2003-outbreak in the USA (1/53), and 1.2% (3/244) during the 2017 epidemic in Nigeria with a mortality of 67% (2/3) [26,79,80]. The American case occurred in a 6-year-old girl presenting seizures with somnolence at day 6 of an acute infection with MPXV. Magnetic resonance imaging (MRI) revealed diffuse cortical, thalamic, and brain stem edema, meningeal enhancement, and left thalamic and right parietal signal abnormality; electroencephalogram showed diffuse slowing with no epileptiform activity; cerebrospinal fluid (CSF) revealed pleocytosis, normal levels of protein and glucose, with negative orthopox PCR and viral culture, but robust orthopoxvirus-reactive immunoglobulins M [25]. In 2022, two young healthy men presented encephalomyelitis within 5 and 9 days of illness onset. Both patients had extremities weakness and sphincter disorders, one of the two required intensive care. The MRI showed features of acute disseminated encephalomyelitis and CSF was lymphocytic with negative MPXV PCR, and no serology was performed on CSF. The underlying mechanism might represent either MPXV invasion of the central nervous system, or a parainfectious autoimmune process triggered by the systemic infection [81]. In the current epidemic, post-MPX Bell’s palsy [19], and myopericarditis with a favorable outcome have been reported [18,82].

The MPX is commonly reported as non-hemorrhagic disease [4]. However we found reports of African cases presenting only 10–20 skin lesions progressing to death after bleedings [34]. Moreover, MPX was suspected in two hemorrhagic fevers in the Central African Republic [83], and hemorrhagic forms of the disease have been described in animals [84]. Besides, two MPX acute hepatitis cases with bleeding resulting in death were reported. The two cases had mild skin features, but severe pharyngitis and lymphadenopathy. Post mortem histological analysis confirmed viral replication inside the liver [34]. Hypertransaminasemia was a common biological feature during MPX illness in the USA in 2003, and may have concerned more than half of the cases during previous outbreaks with alanine transaminase levels up to 15 times the normal value [29,85]; but has not been highlighted during the current outbreak.

3.1.5. Lethality

Case fatality rate was around 3% in West Africa and 10% in Central Africa (Appendix). Lethality as high as 25% (3/12) was reported during an outbreak in Central African Republic in 2015 [86], but mild cases might have easily remained undetected and unreported. According to a recent meta-analysis, across all countries, the pooled estimate case

fatality rate was calculated 8.7% [87]. Another systematic review including 12 studies from 1980 to 2022, found 35% of patients required hospitalization and 4% of them had fatal outcomes [21]. However, data on the current epidemic alone are much more reassuring. As of October 15, 2022, 29 deaths have been reported worldwide (lethality 0,04%), half of them from African countries [1]; and hospitalization rates reported in non-endemic countries are between 2% and 13%, with the highest being among persons leaving with HIV infection [16,16–18,41,44,46–48,54,77,88].

3.1.6. Factors of severity and warning signs

The former West African clade of MPXV, now subdivided into the two clades IIa and IIb, appears to cause less severe disease compared to the Congo Basin clade, newly named clade I [36]. But most of historical clinical series lack virological data. In a series from DRC, probably due to the clade I of the virus, MPX severity correlated with young age, lack of vaccination against smallpox, nutritional, and immunologic/concurrent disease status [24].

First, children have been historically associated with a higher likelihood of severe disease and mortality than adults [31,89], and complications occurred in 20% of the US pediatric cases in 2003 [9].

Secondly, historical studies suggest that smallpox vaccination lessened the risk of MPX infection and illness severity, particularly within 20 years of vaccination [90]. But these findings were not further investigated. In addition, routine prophylactic smallpox vaccination ceased worldwide in 1980, so that vaccination status and age are two related variables in studies. If vaccines based on the vaccinia virus are expected to remain highly cross-reactive against the circulating MPXV [91], however, the post-vaccinal immunity might have waned over time. In the USA in 2003, no significant differences in serious clinical conditions or complications was observed between unvaccinated individuals and those vaccinated in childhood [14,29], and the same was true in 2022 [20]. All large series in 2022 have reported MPX disease in previously or recently vaccinated persons, who represented up to 25% of the cases [17,77]. Preexposure vaccination is recommended in at-risk populations as a 2-dose series delivered 28 days apart, and post-exposure vaccination is recommended within 4 days, but may be extended up to 14 days [91–93]. In the UK in 2019, vaccine administration 6 days after the last exposure did not protect a contact-case against MPX acquisition [38]. In 2022, one French cohort reported that 1.5% of 264 MPX cases had received early post-exposure immunization with the IMVANEX vaccine; and in one American study, of 339 MPX cases with vaccination status available, 3% had received one dose of the JYNNEOS vaccine during the current outbreak [19,55]. All these data suggest that one dose of a replication-deficient live vaccinia virus vaccine is not sufficient to confer full protection against MPX. However, importantly, no severe cases had a history of vaccination against smallpox (Appendix), and we have no data on the number of cases prevented by the vaccination, so that we cannot conclude on its effect [94].

Third, co-morbidities that can depress immune response and increase vulnerability are suspected to play a role in severe MPX [9]. In Nigeria in 2017, HIV co-infected cases significantly had more prolonged illness, larger lesions, and higher rates of both secondary bacterial skin infections and genital ulcers [26,60], and deaths occurred among untreated patients with features of acquired immune deficiency syndrome [31]. Nevertheless, HIV status was unreported in previous African studies. In the 2022 outbreak in non-endemic countries, disseminated forms of the disease were occasionally observed in HIV-patients [53,54]. A severe disseminated MPX clinical presentation evolved to multiple organ dysfunction and death within 3 weeks in a dramatically immunosuppressed Brazilian patient with HIV infection (50 CD4 cells per μL), who was under chemotherapy for a diffuse large B-cell lymphoma with metastases to the spine, skull, and liver [75]. In the USA and UK, a higher proportion of persons with HIV infection was hospitalized, and patients with unsuppressed HIV viral load were more likely to be

symptomatic, notably they experienced more rectal bleeding and purulent or bloody stools [48,54]. But overall, disease severity was not found significantly enhanced in persons with MPX and HIV infection, as most of them were virologically well controlled with a great CD4 cell-count [16,18,20,47,48,53,54].

Lastly, whether severity increases with pregnancy as for smallpox is unknown. Vertical transmission has been documented and maternal MPX may result in miscarriage, spontaneous abortion or fetal death without apparent correlation with severity of maternal disease [31,89,95]. Regarding the delivery plan for women with active MPX, nothing is known about the possibility of perinatal monkeypox transmission and the protective effect of cesarean delivery.

It is noteworthy that disease severity does not appear to be associated with generation of transmission, i.e. secondary-cases are not more severe than primary case [78], as seen in the current large-scale epidemic. However, parental or complex exposures may result in more severe expression than non-invasive routes [13,16]. Concerning warning clinical signs, in DRC, secondary fever occurred in 37% of cases, and was associated with a more severe disease course in the 80s [24]. In 2003, in the USA, nausea or vomiting and mouth sores were independently associated with a hospitalization of more than 48 h, and patients younger than 18 were more likely to be hospitalized in an intensive care unit [29]. Hospitalization for over 48 h, dysphagia, hypoxemia, and mouth sores with dysphagia, were associated on bivariate analysis with disease severity (but not on multivariate analysis) [29]. Severe pharyngitis was notified in cases with encephalitis and acute hepatitis [25,34], and during disseminated severe MPX disease [75], but was not reported in the two cases of encephalomyelitis in 2022 [81].

3.1.7. Convalescence and sequelae

Cosmetic sequelae, including scars and pigmentation disorders, and more rarely alopecia, might last for months or years [25,26,28,42,50]. Bacterial superinfection may contribute to scarring. Impaired vision or blindness was the major permanent damage occurring in up to 10% of historical MPX cases, versus less than 0.3% in 2022 [19,28,42]. The two young adults presenting encephalomyelitis associated with MPX during the current epidemic still required assistive walking device several weeks after [81].

3.1.8. Alternative diagnoses

One issue is that MPX may be misdiagnosed as other eruptive diseases. Alternative diagnoses include non-exhaustively: infections with viruses of the *Herpesvirus* genus, i.e. varicella-zoster virus (VZV) and Herpes Simplex Virus (HSV), measles, bacterial skin infections, disseminated gonococcus infection, primary or secondary syphilis, lymphogranuloma venereum and HIV [96]. In a retrospective study in DRC, 3% of cases clinically diagnosed as typical chickenpox, and 6% of cases with undiagnosed rash, were laboratory confirmed MPX cases. The most important clinical signs supporting a correct diagnosis of MPX were the presence of lymphadenopathy, pre-eruptive fever, and slower maturation of skin lesions [23]. Authors highlighted that clinical criterion to differentiate chickenpox from smallpox were not valuable to strictly differentiate from MPX, notably “cropping” of the varicella rash. In a study evaluating case definitions, the monomorphism of lesions was not significantly discriminant between MPX and varicella, whereas cough, lymph nodes, mouth ulcers, sore throat, malaise, asthenia, conjunctivitis, genital lesions, and bedridden were [5]. Moreover, varicella coinfections in patients with acute MPX have been well documented in DRC since 2006 (13% of MPX cases) and in Nigeria [60,97,98]. Coinfections resulted in a less clinically apparent disease than MPX alone but more than varicella [97,98]. Mechanisms could be the cocirculation of the two viruses, or the possibility that MPXV triggers VZV reactivation resulting in herpes zoster. In the current context of MPX emergence, regarding the lack of pathognomonic clinical signs and the reports of co-infections with VZV and STI [11,16,17,46,47,60,88], a positive diagnosis for varicella or any eruptive STI is not sufficient to

rule out the diagnosis of MPX in cases with compatible clinical or epidemiologic features.

3.2. Proposal for a clinical recording tool

Based on the Table, we developed a grid of MPX symptoms to be daily evaluated by the patient over a 28-day period for their presence by ticking the box or by scoring (Fig. 2). We identified seven stages of lesions development, from total absence (score = 0) to scars (score = 6). Patients may display the overall distribution of lesions and swellings on human body diagrams. Free text fields are provided to collect new symptoms and disease burden and clinical pictures can be added. Patients can complete and transmit the sheet in a dematerialized form or via digital tools, e.g. app-based version could be developed in this purpose and would potentially be even more user-friendly. We suggest combining instruments to measure patients' perceived physical and mental health over time. Validated self-administrated health-related quality of life questionnaires and free-form text can be used to assess the functional status of patients related to the illness and the isolation. Importantly a 34-year-old man with acute MPX died by suicide [26] and low mood concerned 43% of the UK cases [38]. In case of persisting symptoms or impairment at day 28, we suggest to continue the self-monitoring. As observed during chikungunya or coronavirus diseases, MPX may have long-term symptoms and/or psychological burden.

4. Discussion

Before the MPX disease newly emerged in 2022, descriptive studies

conducted in Central and Western Africa had provided most of our understanding. Historically, MPX cases were reported clinically similar, but more severe in DRC than in West Africa [31,99]. Since then, this difference has been linked to the existence of two distinct viral clades, which have been respectively named clade I and clade IIa [36,100]. Over the period 2003–2019, imported MPX cases were described in the USA [79,101,102], Israel [103], Singapore [104] and the United Kingdom, where a limited onward transmission occurred [38,105]. These MPX cases in non-endemic countries differed in some clinical aspect and transmission routs. Since early May 2022, MPX has been worldwide reemerging in a new epidemiological pattern, involving exclusive human-to-human transmission related to sexual contacts. Phylogenetic analysis has revealed an evolution of the West African virus since 2017, so that MPXV strains from 2017, 2018 and 2022 have been grouped into a new clade IIb [106]. In the current multistate outbreak, infected cases develop unusual and milder clinical presentation, which seems to start and predominate at the anogenital site of the virus inoculation and may evolves in several stages over a period of 2–4 weeks [16,20]. Most of the data are derived from retrospective observational studies of MPX cases attending medical centers or sexual health clinics, lacking a longitudinal follow-up, while clinical presentation varied greatly according to the stages of MPX infection at the time of testing [47]. Hence, the contemporary clinical picture of MPX requires further characterization. Prospective long-term studies, involving primary care, are needed to define the full spectrum and course of the disease. Importantly, the effect of preventive measures, such as the protection of previous or post-exposure vaccination against MPXV infection, need to be prospectively evaluated [107]. Moreover, during epidemics of newly emerging highly contagious pathogens, the

MONKEYPOX FOLLOW-UP: DAILY COLLECTION OF CLINICAL SIGNS
To be completed every day by the patient during 28 days

NAME: DATE OF BIRTH:
 FIRST NAME: I AM A CONTACT CASE → DATE OF THE LAST AT-RISK CONTACT:
 PHONE NUMBER: I AM SYMPTOMATIC → DATE OF THE FIRST SYMPTOMS:
 I AM VACCINATED AGAINST SMALLPOX → DATE:

Give this form to your doctor available by:
 → Phone:
 → Email:
 The form will be implemented in your medical file. If you do not want this form to be analyzed for studies, check here:

*0 is the minimum (no pain) and 10 is the maximum (worst pain ever)

Fill out the table below and the 2 figures to the right. Bring your form to the medical visits. Write your free comments and/or add photos following the sheet.

| D = day | D0 | D1 | D2 | D3 | D4 | D5 | D6 | D7 | D8 | D9 | D10 | D11 | D12 | D13 | D14 | D15 | D16 | D17 | D18 | D19 | D20 | D21 | D28 | |
|---|----|----|----|----|----|----|----|----|----|----|-----|-----|-----|-----|-----|-----|-----|-----|-----|-----|-----|-----|-----|--|
| Write the dates D0, D7, D14, D21 | | | | | | | | | | | | | | | | | | | | | | | | |
| Body weight | | | | | | | | | | | | | | | | | | | | | | | | |
| Temperature, indicate the value | | | | | | | | | | | | | | | | | | | | | | | | |
| Physical pain score from 0 to 10* | | | | | | | | | | | | | | | | | | | | | | | | |
| Anxiety or sadness from 0 to 10* | | | | | | | | | | | | | | | | | | | | | | | | |
| Skin lesions: indicate in the box: Total count of lesions → AND The score(s) from 0 to 6 → | | | | | | | | | | | | | | | | | | | | | | | | |
| Corresponding to the aspects of the lesions present that day: use the stages of lesions development depicted on the right; if different stages are observed, list all separated by a comma. | | | | | | | | | | | | | | | | | | | | | | | | |
| Each day, put an X in the box of the symptoms you have: | | | | | | | | | | | | | | | | | | | | | | | | |
| Swelling + locate on the figure 1 | | | | | | | | | | | | | | | | | | | | | | | | |
| Itching | | | | | | | | | | | | | | | | | | | | | | | | |
| Genital lesion | | | | | | | | | | | | | | | | | | | | | | | | |
| Anal lesion | | | | | | | | | | | | | | | | | | | | | | | | |
| Oral lesion | | | | | | | | | | | | | | | | | | | | | | | | |
| Hair loss | | | | | | | | | | | | | | | | | | | | | | | | |
| Red eyes | | | | | | | | | | | | | | | | | | | | | | | | |
| Sensitivity to light | | | | | | | | | | | | | | | | | | | | | | | | |
| Visual disorders, vision loss | | | | | | | | | | | | | | | | | | | | | | | | |
| Sore throat | | | | | | | | | | | | | | | | | | | | | | | | |
| Difficulties when swallowing | | | | | | | | | | | | | | | | | | | | | | | | |
| Fatigue | | | | | | | | | | | | | | | | | | | | | | | | |
| Headache | | | | | | | | | | | | | | | | | | | | | | | | |
| Muscle aches | | | | | | | | | | | | | | | | | | | | | | | | |
| Joint aches | | | | | | | | | | | | | | | | | | | | | | | | |
| Backache | | | | | | | | | | | | | | | | | | | | | | | | |
| Cough | | | | | | | | | | | | | | | | | | | | | | | | |
| Difficulty breathing | | | | | | | | | | | | | | | | | | | | | | | | |
| Nausea or vomiting | | | | | | | | | | | | | | | | | | | | | | | | |
| Abdominal or anal pain | | | | | | | | | | | | | | | | | | | | | | | | |
| Difficulties in urinating | | | | | | | | | | | | | | | | | | | | | | | | |
| Inability to eat or drink | | | | | | | | | | | | | | | | | | | | | | | | |
| Bed-ridden | | | | | | | | | | | | | | | | | | | | | | | | |
| Bleeding (precise where) | | | | | | | | | | | | | | | | | | | | | | | | |
| Other symptoms, precise below and use the back of the sheet if necessary: | | | | | | | | | | | | | | | | | | | | | | | | |

1. Swelling or lumps under skin (lymph nodes)

FRONT BACK

| | | |
|---|---|--|
| 0 | No skin lesions | |
| 1 | Rash or macule (flat red area) | |
| 2 | Papules : button-like dome-shaped lesions without fluid | |
| 3 | Vesicles (small blister) or pustules (bumps containing fluid) | |
| 4 | Ulcerations or umbilications (depression in the center) | |
| 5 | Crusts, scabs | |
| 6 | Fall of scabs, scars and/or areas of lighter or darker skin | |

2. Lesions on skin, scalp, mouth, genitalia
Color or hatch areas with lesions:

FRONT BACK

genitalia buttocks

Soles of the feet Top of the feet

Left Right Left Right

Left Right Left Right

Palms of the hands Top of the hands

Give this form to your doctor available by:
 → Phone:
 → Email:
 The form will be implemented in your medical file. If you do not want this form to be analyzed for studies, check here:

*0 is the minimum (no pain) and 10 is the maximum (worst pain ever)

Fig. 2. Self-collection form of clinical signs for the monitoring of MPX cases and contacts.

monitoring of cases and the contact tracing are challenging and resource-intensive. To address these issues, we proposed an international self-questionnaire for in and outpatients, time-saving for the clinician, who can, in a single glance, assess the progression and the burden of the MPX disease. For educational and validity purposes, we encourage physicians to occasionally fill-in the form with the patient. Importantly, criteria of severe disease and main complications known to-date are apparent. The clinical form is useable by parents or relatives to monitor children. It is also useable for active or passive daily contact monitoring by public health authorities over and beyond the recommended period of 21 days since the last at-risk contact. The daily record of signs allows to measure case intervals (i.e., the number of days between exposure and symptom onsets in secondary cases). This tool will enhance contact's awareness to detect prodromal signs and subclinical disease for prompt diagnostic testing and isolation. In addition to the practical aspect, the grid can be adapted for research purposes, in accordance with bioethics laws and with patient consent, for instance to implement cohort studies, to assess post-exposure vaccination effect on the clinical disease presentation, or to correlate the chronology of symptoms with viral and immunological kinetics. This tool can be translated into local languages and can be updated in the light of developments in knowledge or changes in the affected population.

More generally, we argue for the use of self-monitoring instruments to involve patient and contacts cases in their management, to improve their follow-up, to spare time in the implementation of contact tracing around a new patient, especially during epidemics, and to better characterize newly emerging infectious diseases in their full clinical spectrum and course.

Funding

This research did not receive any specific grant from funding agencies in the public, commercial, or not-for-profit sectors.

CRediT authorship contribution statement

Emilie Javelle: Conceptualization, Methodology, Investigation, Writing – original draft. **Cécile Ficko:** Conceptualization, Writing – review & editing. **Hélène Savini:** Resources, Writing – review & editing. **Marie Mura:** Validation, Writing – review & editing. **Olivier Ferraris:** Investigation, Validation, Writing – review & editing. **Jean Nicolas Tournier:** Conceptualization, Validation, Writing – review & editing. **Franck de Laval:** Conceptualization, Methodology, Supervision, Writing – review & editing. All authors reviewed and approved the final version.

Declaration of competing interest

We declare no competing interest.

Acknowledgement

Authors are deeply grateful to Professor Fabrice Simon for his valuable and kind teachings, and would like to pay him a posthumous tribute. Fabrice will remain in our memories and our works.

Appendix A. Supplementary data

Supplementary data to this article can be found online at <https://doi.org/10.1016/j.tmaid.2023.102559>.

References

- [1] Mathieu E, Spooner F, Dattani S, Ritchie H, Roser M. Mpx (monkeypox). 2022. Published online at OurWorldInData.org. Retrieved from: <https://ourworldindata.org/monkeypox> [Online Resource].

- [2] Chmel M, Bartoš O, Kabíčková H, Pajer P, Kubíčková P, Novotná I, et al. Retrospective analysis revealed an april occurrence of monkeypox in the Czech republic. *Viruses* 2022;14:1773. <https://doi.org/10.3390/v14081773>.
- [3] Centers for Disease Control and Prevention (CDC). Case definitions for use in the 2022 monkeypox response. published online June 3, 2022. <https://www.cdc.gov/poxvirus/monkeypox/clinicians/case-definition.html>. [Accessed 4 June 2022].
- [4] Di Giulio DB, Eckburg PB. Human monkeypox: an emerging zoonosis. *Lancet Infect Dis* 2004;4:15–25. [https://doi.org/10.1016/S1473-3099\(03\)00856-9](https://doi.org/10.1016/S1473-3099(03)00856-9).
- [5] Osadebe L, Hughes CM, Shongo Lushima R, Kabamba J, Nguete B, Malekani J, et al. Enhanced case definitions for surveillance of human monkeypox in the Democratic Republic of Congo. *PLoS Negl Trop Dis* 2017;11:e0005857. <https://doi.org/10.1371/journal.pntd.0005857>.
- [6] Perez Duque M, Ribeiro S, Martins JV, Casaca P, Leite PP, Tavares M, et al. Ongoing monkeypox virus outbreak, Portugal, 29 April to 23 May 2022. *Euro Surveill* 2022;27. <https://doi.org/10.2807/1560-7917.ES.2022.27.22.2200424>.
- [7] Pan D, Sze S, Nazareth J, Martin CA, Al-Oraibi A, Baggaley RF, et al. Monkeypox in the UK: arguments for a broader case definition. *Lancet* 2022. [https://doi.org/10.1016/S0140-6736\(22\)01101-1](https://doi.org/10.1016/S0140-6736(22)01101-1). S0140-6736(22)01101-1.
- [8] Mande G, Akonda I, De Wegheleire A, Brosius I, Liesenborghs L, Bottieau E, et al. Enhanced surveillance of monkeypox in Bas-Uélé, Democratic Republic of Congo: the limitations of symptom-based case definitions. *Int J Infect Dis* 2022;122: 647–55. <https://doi.org/10.1016/j.ijid.2022.06.060>.
- [9] Brown K, Leggat PA. Human monkeypox: current state of knowledge and implications for the future. *Trop Med Infect Dis* 2016;1:E8. <https://doi.org/10.3390/tropicalmed1010008>.
- [10] Page MJ, McKenzie JE, Bossuyt PM, Boutron I, Hoffmann TC, Mulrow CD, et al. The PRISMA 2020 statement: an updated guideline for reporting systematic reviews. *BMJ* 2021;372:n71. <https://doi.org/10.1136/bmj.n71>.
- [11] Davido B, D'anglejan E, Jourdan J, Robinault A, Davido G. Monkeypox 2022 outbreak: cases with exclusive genital lesions. *J Travel Med* 2022. <https://doi.org/10.1093/jtm/taac077>. taac077.
- [12] Minhaj FS, Ogale YP, Whitehill F, Schultz J, Foote M, Davidson W, et al. Monkeypox outbreak - nine states, may 2022. *MMWR Morb Mortal Wkly Rep* 2022;71:764–9. <https://doi.org/10.15585/mmwr.mm7123e1>.
- [13] Reynolds MG, Yorita KL, Kuehnert MJ, Davidson WB, Huhn GD, Holman RC, et al. Clinical manifestations of human monkeypox influenced by route of infection. *J Infect Dis* 2006;194:773–80. <https://doi.org/10.1086/505880>.
- [14] Reed KD, Melski JW, Graham MB, Regnery RL, Sotir MJ, Wegner MV, et al. The detection of monkeypox in humans in the Western Hemisphere. *N Engl J Med* 2004;350:342–50. <https://doi.org/10.1056/NEJMoa032299>.
- [15] Miura F, van Ewijk CE, Backer JA, Xiridou M, Franz E, Op de Coul E, et al. Estimated incubation period for monkeypox cases confirmed in The Netherlands. *Euro Surveill* May 2022;27. <https://doi.org/10.2807/1560-7917.ES.2022.27.24.2200448>. 2022.
- [16] Moschese D, Pozza G, Giacomelli A, Mileto D, Cossu MV, Beltrami M, et al. Natural history of human Monkeypox in individuals attending a sexual health clinic in Milan, Italy. *J Infect* 2022. <https://doi.org/10.1016/j.jinf.2022.08.019>. S0163-4453(22)00503-00505.
- [17] Tarín-Vicente EJ, Alemany A, Agud-Dios M, Ubals M, Suñer C, Antón A, et al. Clinical presentation and virological assessment of confirmed human monkeypox virus cases in Spain: a prospective observational cohort study. *Lancet* 2022;400: 661–9. [https://doi.org/10.1016/S0140-6736\(22\)01436-2](https://doi.org/10.1016/S0140-6736(22)01436-2).
- [18] Thornhill JP, Barkati S, Walmsley S, Rockstroh J, Antinori A, Harrison LB, et al. Monkeypox virus infection in humans across 16 countries - april-june 2022. *N Engl J Med* 2022;387:679–91. <https://doi.org/10.1056/NEJMoa2207323>.
- [19] Mailhe M, Beaumont A-L, Thy M, Le Pluart D, Perrineau S, Houhou-Fidouh N, et al. Clinical characteristics of ambulatory and hospitalized patients with monkeypox virus infection: an observational cohort study. *Clin Microbiol Infect* 2022. <https://doi.org/10.1016/j.cmi.2022.08.012>. S1198-743X(22)00428-1.
- [20] Català A, Clavo-Escribano P, Riera-Monroig J, Martín-Ezquerro G, Fernandez-Gonzalez P, Revelles-Peñas L, et al. Monkeypox outbreak in Spain: clinical and epidemiological findings in a prospective cross-sectional study of 185 cases. *Br J Dermatol* 2022. <https://doi.org/10.1111/bjd.21790>.
- [21] Benites-Zapata VA, Ulloque-Badaracco JR, Alarcon-Braga EA, Hernandez-Bustamante EA, Mosquera-Rojas MD, Bonilla-Aldana DK, et al. Clinical features, hospitalisation and deaths associated with monkeypox: a systematic review and meta-analysis. *Ann Clin Microbiol Antimicrob* 2022;21:36. <https://doi.org/10.1186/s12941-022-00527-1>.
- [22] Jezek Z, Szczeniowski M, Paluku KM, Mutombo M, Grab B. Human monkeypox: confusion with chickenpox. *Acta Trop* 1988;45:297–307.
- [23] Damon IK. Status of human monkeypox: clinical disease, epidemiology and research. *Vaccine* 2011;29(Suppl 4):D54–9. <https://doi.org/10.1016/j.vaccine.2011.04.014>.
- [24] Sejvar JJ, Chowdhury Y, Schomogyi M, Stevens J, Patel J, Karem K, et al. Human monkeypox infection: a family cluster in the midwestern United States. *J Infect Dis* 2004;190:1833–40. <https://doi.org/10.1086/425039>.
- [25] Ogoina D, Iroezindu M, James HI, Oladokun R, Yinka-Ogunleye A, Wakama P, et al. Clinical course and outcome of human monkeypox in Nigeria. *Clin Infect Dis* 2020;71. <https://doi.org/10.1093/cid/ciaa143>. e210–4.
- [26] Foster SO, Brink EW, Hutchins DL, Pifer JM, Lourie B, Moser CR, et al. Human monkeypox. *Bull World Health Organ* 1972;46:569–76.
- [27] Breman JG, Kalisa-Ruti, Steniowski MV, Zanotto E, Gromyko AI, Arita I. Human monkeypox, 1970–79. *Bull World Health Organ* 1980;58:165–82.
- [28] Huhn GD, Bauer AM, Yorita K, Graham MB, Sejvar J, Likos A, et al. Clinical characteristics of human monkeypox, and risk factors for severe disease. *Clinical Infectious Diseases* 2005;41:1742–51. <https://doi.org/10.1086/498115>.

- [78] Reynolds MG, McCollum AM, Nguete B, Shongo Lushima R, Petersen BW. Improving the care and treatment of monkeypox patients in low-resource settings: applying evidence from contemporary biomedical and smallpox biodefense research. *Viruses* 2017;9:380. <https://doi.org/10.3390/v9120380>.
- [79] Centers for Disease Control and Prevention (CDC). Multistate outbreak of monkeypox—Illinois, Indiana, and Wisconsin, 2003. *MMWR Morb Mortal Wkly Rep* 2003;52:537–40.
- [80] Sklenovská N, Van Ranst M. Emergence of monkeypox as the most important orthopoxvirus infection in humans. *Front Public Health* 2018;6:241. <https://doi.org/10.3389/fpubh.2018.00241>.
- [81] Pastula DM, Copeland MJ, Hannan MC, Rapaka S, Kitani T, Kleiner E, et al. Two cases of monkeypox-associated encephalomyelitis - Colorado and the District of Columbia, July-August 2022. *MMWR Morb Mortal Wkly Rep* 2022;71:1212–5. <https://doi.org/10.15585/mmwr.mm7138e1>.
- [82] Tan DHS, Jaeranny S, Li M, Sukhdeo SS, Monge JC, Callejas MF, et al. Atypical clinical presentation of monkeypox complicated by myopericarditis. *Open Forum Infect Dis* 2022;9:ofac394. <https://doi.org/10.1093/ofid/ofac394>.
- [83] Froeschl G, Kayembe PK. Pox-like lesions and haemorrhagic fever in two concurrent cases in the Central African Republic: case investigation and management in difficult circumstances. *Pan Afr Med J* 2015;22:23. <https://doi.org/10.11604/pamj.2015.22.23.6620>.
- [84] Parker S, Nuara A, Buller RML, Schultz DA. Human monkeypox: an emerging zoonotic disease. *Future Microbiol* 2007;2:17–34. <https://doi.org/10.2217/17460913.2.1.17>.
- [85] Joob B, Wiwanitkit V. Magnitude of increased alanine transaminase level: a summary on 21 monkeypox cases. *Clin Lab* 2022;68. <https://doi.org/10.7754/Clin.Lab.2021.220535>.
- [86] Kalthan E, Dondo-Fongbia JP, Yambele S, Dieu-Creer LR, Zepio R, Pamatika CM. Epidémie de 12 cas de maladie à virus monkeypox dans le district de Bangassou en République Centrafricaine en décembre 2015. *Bull Soc Pathol Exot* 2016;109:358–63. <https://doi.org/10.1007/s13149-016-0516-z>.
- [87] Bunge EM, Hoet B, Chen L, Lienert F, Weidenthaler H, Baer LR, et al. The changing epidemiology of human monkeypox—a potential threat? A systematic review. *PLOS Neglected Tropical Diseases* 2022;16:e0010141. <https://doi.org/10.1371/journal.pntd.0010141>.
- [88] Bízová B, Veselý D, Trojáněk M, Rob F. Coinfection of syphilis and monkeypox in HIV positive man in Prague, Czech Republic. *Travel Med Infect Dis* 2022:102368. <https://doi.org/10.1016/j.tmaid.2022.102368>.
- [89] Mbala PK, Huggins JW, Riu-Rovira T, Ahuka SM, Mulembakani P, Rimoin AW, et al. Maternal and fetal outcomes among pregnant women with human monkeypox infection in the democratic republic of Congo. *J Infect Dis* 2017;216:824–8. <https://doi.org/10.1093/infdis/jix260>.
- [90] Mukinda VB, Mwema G, Kilundu M, Heymann DL, Khan AS, Esposito JJ. Re-emergence of human monkeypox in Zaire in 1996. Monkeypox epidemiologic working group. *Lancet* 1997;349:1449–50. [https://doi.org/10.1016/s0140-6736\(05\)63725-7](https://doi.org/10.1016/s0140-6736(05)63725-7).
- [91] Ahmed SF, Sohail MS, Quadeer AA, McKay MR. Vaccinia-virus-based vaccines are expected to elicit highly cross-reactive immunity to the 2022 monkeypox virus. *Viruses* 2022;14:1960. <https://doi.org/10.3390/v14091960>.
- [92] Vaughan A, Aarons E, Astbury J, Brooks T, Chand M, Flegg P, et al. Human-to-human transmission of monkeypox virus, United Kingdom. *Emerg Infect Dis* October 2018;26(4):782–5. <https://doi.org/10.3201/eid2604.191164>. 2020.
- [93] Rao AK. Use of JYNNEOS (smallpox and monkeypox vaccine, live, nonreplicating) for preexposure vaccination of persons at risk for occupational exposure to orthopoxviruses: recommendations of the advisory committee on immunization practices — United States, 2022. *MMWR Morb Mortal Wkly Rep* 2022;71. <https://doi.org/10.15585/mmwr.mm7122e1>.
- [94] Moschese D, Farinacci D, Pozza G, Ciccullo A, Cossu MV, Giacomelli A, et al. Is smallpox vaccination protective against human monkeypox? *J Med Virol* 2022. <https://doi.org/10.1002/jmv.28077>.
- [95] Jamieson DJ, Cono J, Richards CL, Treadwell TA. The role of the obstetrician-gynecologist in emerging infectious diseases: monkeypox and pregnancy. *Obstet Gynecol* 2004;103:754–6. <https://doi.org/10.1097/01.AOG.0000114987.76424.6d>.
- [96] Koh XQ, Chio MTW, Tan M, Leo YS, Chan RKW. Global monkeypox outbreak 2022: first case series in Singapore. *Ann Acad Med Singap* 2022;51:462–72.
- [97] Hoff NA, Morier DS, Kisalu NK, Johnston SC, Doshi RH, Hensley LE, et al. Varicella coinfection in patients with active monkeypox in the democratic republic of the Congo. *Ecohealth* 2017;14:564–74. <https://doi.org/10.1007/s10393-017-1266-5>.
- [98] Hughes CM, Liu L, Davidson WB, Radford KW, Wilkins K, Monroe B, et al. A tale of two viruses: coinfections of monkeypox and varicella zoster virus in the democratic republic of Congo. *Am J Trop Med Hyg* 2020;104:604–11. <https://doi.org/10.4269/ajtmh.20-0589>.
- [99] Quarleri J, Delpino MV, Galvan V. Monkeypox: considerations for the understanding and containment of the current outbreak in non-endemic countries. *Geroscience* 2022. <https://doi.org/10.1007/s11357-022-00611-6>.
- [100] Formenty P, Muntasir MO, Damon I, Chowdhary V, Opoka ML, Monimart C, et al. Human monkeypox outbreak caused by novel virus belonging to Congo Basin clade, Sudan. *Emerg Infect Dis* 2005;16:1539–45. <https://doi.org/10.3201/eid1610.100713>. 2010.
- [101] Costello V, Sowash M, Gaur A, Cardis M, Pasięka H, Wortmann G, et al. Imported monkeypox from international traveler, Maryland, USA. *Emerg Infect Dis* 2021;28:1002–5. <https://doi.org/10.3201/eid2805.220292>. 2022.
- [102] Rao AK, Schulte J, Chen T-H, Hughes CM, Davidson W, Neff JM, et al. Monkeypox in a traveler returning from Nigeria — Dallas, Texas. *MMWR Morb Mortal Wkly Rep* July 2021;71:509–16. <https://doi.org/10.15585/mmwr.mm7114a1>. 2022.
- [103] Erez N, Achdout H, Milrot E, Schwartz Y, Wiener-Well Y, Paran N, et al. Diagnosis of imported monkeypox, Israel, 2018. *Emerg Infect Dis* 2019;25:980–3. <https://doi.org/10.3201/eid2505.190076>.
- [104] Yong SEF, Ng OT, Ho ZJM, Mak TM, Marimuthu K, Vasoo S, et al. Imported monkeypox, Singapore. *Emerg Infect Dis* 2020;26:1826–30. <https://doi.org/10.3201/eid2608.191387>.
- [105] Hobson G, Adamson J, Adler H, Firth R, Gould S, Houlihan C, et al. Family cluster of three cases of monkeypox imported from Nigeria to the United Kingdom, May 2021. *Euro Surveill* 2021;26:2100745. <https://doi.org/10.2807/1560-7917.ES.2021.26.32.2100745>.
- [106] Happi C, Adetifa I, Mbala P, Njouom R, Nakoune E, Happi A, et al. Urgent need for a non-discriminatory and non-stigmatizing nomenclature for monkeypox virus. *PLOS Biology* 2022;20:e3001769. <https://doi.org/10.1371/journal.pbio.3001769>.
- [107] Keckler MS, Reynolds MG, Damon IK, Karem KL. The effects of post-exposure smallpox vaccination on clinical disease presentation: addressing the data gaps between historical epidemiology and modern surrogate model data. *Vaccine* 2013;31:5192–201. <https://doi.org/10.1016/j.vaccine.2013.08.039>.