



HAL
open science

Deficient anterior pituitary with common variable immune deficiency (DAVID syndrome): a new case and literature reports

Thi Thom Mac, Frédéric Castinetti, Celine Bar, Sophie Julia, Marlene Pasquet, Pauline Romanet, Alexandru Saveanu, Gregory Mougel, Teddy Fauquier, Nicolas Jullien, et al.

► To cite this version:

Thi Thom Mac, Frédéric Castinetti, Celine Bar, Sophie Julia, Marlene Pasquet, et al.. Deficient anterior pituitary with common variable immune deficiency (DAVID syndrome): a new case and literature reports. *Journal of Neuroendocrinology*, 2023, 10.1111/jne.13287 . hal-04254098

HAL Id: hal-04254098

<https://amu.hal.science/hal-04254098>

Submitted on 26 Oct 2023

HAL is a multi-disciplinary open access archive for the deposit and dissemination of scientific research documents, whether they are published or not. The documents may come from teaching and research institutions in France or abroad, or from public or private research centers.

L'archive ouverte pluridisciplinaire **HAL**, est destinée au dépôt et à la diffusion de documents scientifiques de niveau recherche, publiés ou non, émanant des établissements d'enseignement et de recherche français ou étrangers, des laboratoires publics ou privés.

Deficient anterior pituitary with common variable immune deficiency (DAVID syndrome): a new case and literature reports

Thi Thom Mac^{1,2}  | Frederic Castinetti^{1,3}  | Céline Bar⁴ | Sophie Julia⁵ |
Marlene Pasquet⁶ | Pauline Romanet^{1,7} | Alexandru Saveanu^{1,7} |
Gregory Mougel^{1,7} | Teddy Fauquier¹ | Nicolas Jullien⁸ | Anne Barlier^{1,7} |
Rachel Reynaud^{1,9} | Thierry Brue^{1,3} 

¹Aix Marseille University, UMR1251, MMG – Marseille Medical Genetics – MarMaRa Institute, Faculty of Medicine, Marseille, France

²Endocrinology Department, Hanoi Medical University Hospital, Hanoi, Vietnam

³Endocrinology Department, Conception Hospital – APHM, Marseille, France

⁴Department of Endocrinology and Metabolic Diseases, Children's Hospital, Toulouse Cedex 9, France

⁵Department of Medical Genetics, Purpan Hospital, Pavillon Lefèbvre, Place du Docteur Baylac, Toulouse Cedex 9, France

⁶Department of Hematology Oncology Immunology, Children's Hospital, Toulouse Cedex 9, France

⁷Department of Molecular Biology, Conception Hospital – APHM, Marseille, France

⁸INP – Institute of Neurophysiopathology, UMR 7051, Faculty of Medicine, Marseille, France

⁹Multidisciplinary Pediatrics Department, Timone Hospital, Marseille, France

Correspondence

Thierry Brue, Hôpital de la Conception, 147 Boulevard Baille 13005, Marseille, France. Email: thierry.brue@ap-hm.fr

Funding information

ADEREM; Institut Marseille maladies rares MARMARA

Abstract

Deficient anterior pituitary with common variable immune deficiency (DAVID) syndrome is a rare condition characterized by adrenocorticotrophic hormone (ACTH) deficiency and primary hypogammaglobulinemia. It is due to heterozygous mutations of the nuclear factor kappa-B subunit 2 (*NFKB2*) gene. Only a few isolated cases have been reported since its first description by our team. Through the international multi-center GENHYPOPIT network, we identified a new case of DAVID syndrome. We then conducted an extensive review of the DAVID syndrome cases published from 2012 to 2022. A 7-year-old boy was diagnosed with symptomatic hypoglycemia revealing ACTH deficiency. Laboratory tests showed asymptomatic hypogammaglobulinemia. He harbored a heterozygous point mutation in *NFKB2* gene (c.2600C > T, p.Ala867Val). His management included hydrocortisone replacement treatment, and he also received subcutaneous immunoglobulins during the Covid-19 pandemic. We analyzed 28 cases of DAVID syndrome with ACTH deficiency. ACTH deficiency was the only hormone deficiency in 79% of patients, but some patients harbored growth hormone (GH) and thyroid stimulating hormone (TSH) deficiencies. The first presenting symptoms were sinus/pulmonary infections (82%, mean age of 3 years) and alopecia (mean age of 4.7 years). ACTH deficiency was the third presenting condition (mean age at diagnosis of 8.6 years). All patients had hypogammaglobulinemia (decreased IgA and IgM levels), and 57% of patients had at least one autoimmune manifestation. Heterozygous mutations at the 3' end of the *NFKB2* gene, coding for the C-terminal domain of the protein, were identified in all cases. Better knowledge of DAVID syndrome will help clinicians make an early diagnosis to avoid life-threatening complications.

KEYWORDS

anterior pituitary deficiency, corticotroph deficiency, CVID, hypogammaglobulinemia, *NFKB2* mutations

1 | INTRODUCTION

Deficient anterior pituitary with variable immune deficiency (DAVID) syndrome (OMIM#, 615577) is a rare, autosomal dominant condition, characterized by association of adrenocorticotrophic hormone (ACTH) deficiency, ectodermal dysplasia, and primary hypogammaglobulinemia.¹ This disorder was first described in 2012 by our group in four children from three unrelated families with a previous diagnosis of common variable immunodeficiency (CVID), who presented severe hypoglycemia due to ACTH deficiency.¹ Later, DAVID syndrome was found by us and others to be due to heterozygous pathogenic variants in the nuclear factor kappa-B subunit 2 (*NFKB2*) gene.^{2,3} While CVID and related autoimmune consequences can be explained by known functions of this gene on the immune system,⁴ the mechanism of the anterior pituitary deficiency caused by *NFKB2* mutants remains unknown. In these studies, the majority of patients described were single cases and, to date, a total of 27 cases of DAVID syndrome with ACTH deficiency, variable immune deficiency, and confirmed mutations of *NFKB2* gene have been reported worldwide. The aims of this study were:

1. To describe a new case of DAVID syndrome in a 7-year-old boy who presented with severe hypoglycemia and hypogammaglobulinemia.
2. To better characterize the association of CVID and endocrine deficiency, by reviewing all cases of ACTH deficiency due to DAVID syndrome published in the literature from 2012 to 2022.

2 | PATIENTS AND METHODS

The index case was recruited within the GENHYPOPIT network^{5,6} on the basis of the association of an anterior pituitary deficiency and CVID. In parallel, we conducted a review of 18 publications with 27 case reports of anterior pituitary deficiency in the setting of DAVID syndrome.

Patients selected for the present analysis should fulfil all three of the following inclusion criteria:

1. ACTH deficiency based on low plasma cortisol levels and inappropriately low ACTH level.
2. Diagnosis of CVID with confirmed hypogammaglobulinemia with decrease in serum immunoglobulin A (IgA) levels and IgM, or IgG; poor response to vaccines.
3. Molecular analysis revealing *NFKB2* mutation (NM_001322934).

Written informed consent was obtained from the patients and the family as part of their genetic and clinical data analyses studies.

3 | RESULTS

3.1 | Clinical presentation of the case

We describe a new family with a patient presenting with DAVID syndrome as defined by combined variable immunodeficiency (CVID)

associated with anterior pituitary deficiency including ACTH deficiency. The patient was a 6-year-old boy of European descent with normal growth and development. He had no severe infections during infancy. He was the second child of unrelated parents. There was a family history of autoimmune diseases on the maternal side: Psoriasisiform dermatitis in the mother, Hashimoto's thyroiditis in the maternal grand-mother, and granulomatosis with polyangiitis (Wegener's disease) in the maternal grand-father.

The first symptom appeared at 6 years of age when the boy was seen with a history of tiredness and weight loss of 6 kg in 6 months. He complained of nausea and loss of appetite. Routine laboratory testing (not including ACTH or cortisol) was normal at that time. At 7 years of age, the patient was admitted to an emergency department for hypoglycemia. Initial physical examination was unremarkable, with 90th percentile for height and weight. Blood pressure and electrolytes were normal. Hormonal investigations revealed undetectable serum cortisol with low ACTH (<2 pg/mL) confirming ACTH deficiency (Table 1). He was placed on replacement treatment with hydrocortisone 10 mg/m²/day. Thyroid function evaluation displayed increased thyroid stimulating hormone (TSH) on two distinct measurements, but anti-thyroperoxidase and anti-thyroglobulin antibodies were negative. L-thyroxine replacement therapy was initiated shortly thereafter. Other pituitary hormones were within normal limits as well as insulin-like growth factor-1 (IGF-1: 190 ng/mL, normal for age: 54–312 ng/mL). Pituitary magnetic resonance imaging (MRI) showed pituitary hypoplasia (Figure 1A). Immunological evaluation revealed decreased levels of serum immunoglobulin A (IgA), IgM and IgG (Table 1). Antibody titers to previously administered pneumococcal vaccine were protective. A protective but nonrobust response to tetanus and hemophilus influenzae type b vaccines was found (Table 1). After initiation of hydrocortisone replacement therapy, no further episodes of hypoglycemia occurred. The boy was doing well at a medical follow-up performed at 10 years of age. However, during the Covid-19 pandemic in 2021, due to worsening hypogammaglobulinemia, the patient was initiated on subcutaneous immunoglobulins.

His mother (A2) had psoriasisiform dermatitis since the age of 4 years but had no history of recurrent or severe infections despite deficiencies in lymphocyte B (0%) and lymphocyte T central memory (0%) (data not shown). She also had decreased IgG4 levels with normal vaccination responses as shown by antibody titers (Table 1). At endocrine testing, she had normal pituitary function (Table 1). The patient's brother and father had an unremarkable phenotype.

Direct Sanger sequencing of the *NFKB2* gene was performed on the patient and his parents using the AB-350xL Dx Genetic Analyzer (Applied Biosystems). Results showed that the patient and his mother had the same heterozygous missense *NFKB2* mutation (c.2600C > T; p.Ala867Val) within exon 23 (Figure 1B, C). This mutation affects the C-terminus of the precursor protein *NFKB2* p100. The father had no mutation of this gene, and the brother was not available for sequencing.

TABLE 1 Immunological profile and endocrine analysis in the index patient and his mother.

Parameter	Patient A1	Mother A2	Reference range children/adults
Sex	Male	Female	
Age at diagnosis	7 yr	41 yr	
Infections	Normal	Normal	
Clinical features	ACTH deficiency	Psoriasisiform dermatitis	
Immunological values			
IgG, g/L	4.16	6.81	4.6–16.8/7.0–16.0
- IgG1	1.98	Normal	5–13
- IgG2	1.37	Normal	1.5–6
- IgG3	0.28	Normal	0.2–1.5
- IgG4	<0.005	IgG4 Deficiency	0.1–2
IgA, g/L	0.27	0.51	0.3–2.7/0.7–4.0
IgM, g/L	0.32	0.92	0.4–2.5/0.4–2.8
Vaccination responses			
Pneumococcal IgG2, mg/L	47.27	Normal	>15
Tetanus IgG, IU/mL	6.19	Normal	>1
Hemophilus influenza type b IgG, mg/L	0.21	Normal	>1
Lymphocyte	3000	1711	1900–3700/1200–3600
Hormonal values			
ACTH, pg/mL	<2	41 (1 h insulin tolerance test)	5–46/9–52
Cortisol, mg/dL	Undetectable 08:00 a.m.	17.8 (1 h insulin tolerance test)	5–25/5–23
IGF-1, ng/mL	190	211	54–312/49–240
FT4, pg/mL	8.3–9	10.5	10–21/9–25
TSH, mIU/mL	8.8–9.1	1.53	0.8–6.0/0.4–4.2
PRL, ng/mL	34	11.2	5–20/ < 25

Abbreviations: ACTH, adrenocorticotropic hormone; Ig, immunoglobulin; IGF-1, insulin-like growth factor-1; FT4, free thyroxine 4; NA, not available; TSH, thyroid stimulating hormone; PRL, prolactin; yr, years.

3.2 | DAVID syndrome: A literature review

3.2.1 | Clinical presentation and diagnosis of DAVID syndrome

We performed an extensive analysis of the literature and identified 28 cases of DAVID syndrome (with our case), who had ACTH deficiency, hypogammaglobulinemia and *NFKB2* mutations^{1–3,7–21} (Table 2). It is important to emphasize that the definition of DAVID syndrome includes ACTH deficiency, which means that the same *NFKB2* mutation could lead to DAVID syndrome or to a complex phenotype including immune deficiency, but without pituitary deficiency, even in the same family, suggesting an incomplete penetrance. This was for instance the case in our family: while the mother and the son were presenting with the same mutation, only the son was considered as having DAVID syndrome as the mother had a normal pituitary evaluation. The 28 cases included 13 females and 15 males. Patients presented with heterogeneous clinical phenotypes, ranging from asymptomatic to life threatening opportunistic infections. Typically, diagnosis of DAVID syndrome was performed in a child with recurrent

respiratory infections followed by ectodermal dysplasia and the presence of symptomatic hypoglycemia.

Clinical manifestations of DAVID syndrome are summarized in Figure 2.

3.2.2 | Infections

In most patients (23/28, 82%) recurrent sinus and/or pulmonary infections represented the first symptoms of the disease, occurring at a mean age of 3 ± 1.9 years (median 2 years), leading to the diagnosis of CVID, usually before the onset of signs of ACTH deficiency (Table 2). In five patients (including our case, 5/28, 18%), severe hypoglycemia was the first symptom, leading to the diagnosis of ACTH deficiency, two to four years before the diagnosis of CVID; to the best of our knowledge, these five patients had no history of recurrent infections in previous years.

Lower respiratory infections were described in 17/23 patients (74%), due to viral infections such as cytomegalovirus (CMV) in three patients, and Epstein–Barr virus (EBV) in one

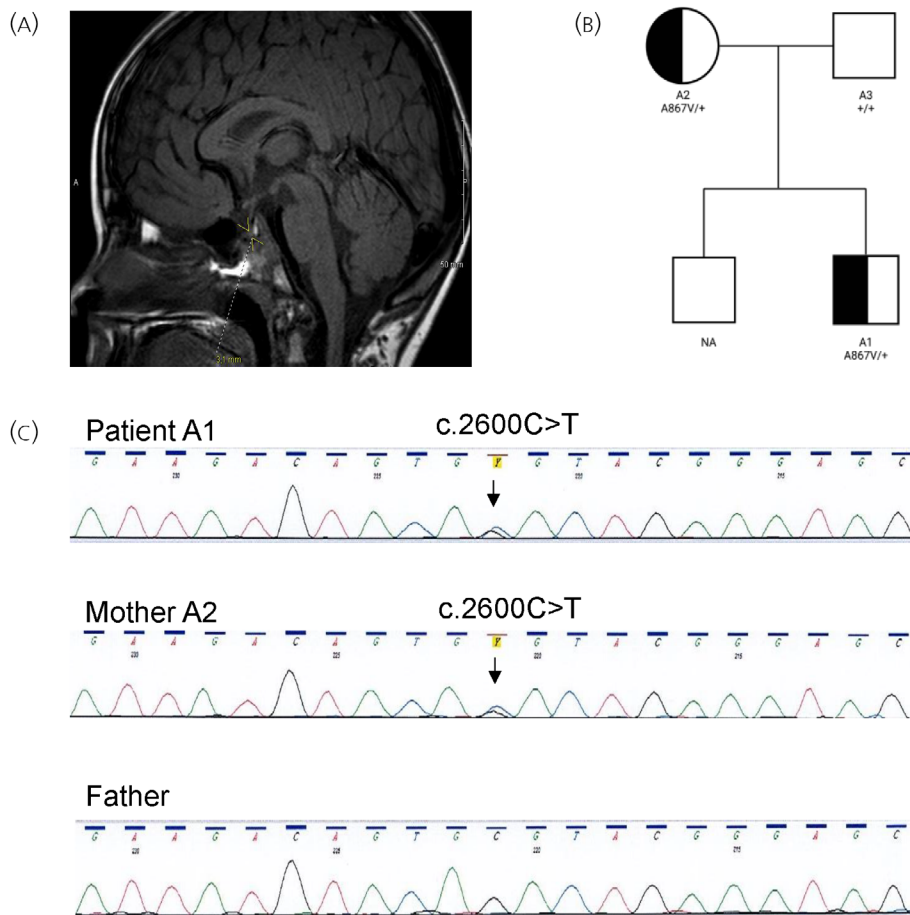


FIGURE 1 (A) T1 sagittal pituitary magnetic resonance imaging (MRI) of patient at age 7 years revealed pituitary hypoplasia. (B) Pedigree of the newly reported patient with deficient anterior pituitary with common variable immune deficiency (DAVID) syndrome. Males are represented by squares, females by circles. (C) Sanger sequencing of the patient and his parents showing heterozygous *NFKB2* mutation c.2600C > T (p.Ala867Val) in the patient and his mother.

patient; bacterial infections (mycobacteria and *Hemophilus influenzae* type b) were seen in two patients, and fungal pneumonia (*pneumocystis jirovecii*) in two patients. Upper respiratory infections were found in 17/23 patients (74%), such as sinusitis and otitis media.

Skin infections were reported in 10/23 patients (43%), due to herpes simplex virus (HSV) in six patients or varicella zoster virus (VZV) in four patients. *Giardia* infection was observed in two patients.

Severe or systemic bacterial infections, such as septicemia, were observed in three patients, meningoen­cephalitis in four patients, and pericarditis in one patient.

3.2.3 | Immune phenotype

The immunological analysis of patients is detailed on Table S1. All patients had CVID with hypogammaglobulinemia: IgA and IgM deficiencies in 100%, and 24/26 patients (92%) were reported to also have low IgG. Mean age at CVID diagnosis was 7.8 ± 6.4 years (range 1–30 years).

Concerning autoimmunity, 16/28 patients (57%) presented with at least one autoimmune manifestation (Table S1). Alopecia was noted in 12/27 patients (44%), with mean age at onset of 4.7 ± 3.5 years (range

1–11 years). Trachyonychia was present in 9/27 (33%) patients. Other autoimmune manifestations were reported, such as thyroiditis (4), psoriasisiform dermatitis (2), vitiligo (1), vasculitis-like lesions (1), as well as idiopathic thrombocytopenic purpura (1), arthritis (1), autoimmune enteropathy (1) and asthma (8) (Table S1). Autoantibodies were found in 8/28 patients (28%), mainly anti-thyroperoxidase antibodies (5 patients).

Specific responses to antigens were impaired with low titers against tetanus in 6/11 (55%), diphtheria in 3/6 (50%), pneumococcus in 5/10 (50%), and *Hemophilus influenzae* type b in 4/6 (67%) patients (data not shown). B cell numbers were low in 13/25 (52%). B cell differentiation was impaired in most patients with an increase of naïve B cells in 7/12 (58%), or reduced switched memory B cells in 15/15 (100%). T cell numbers were elevated in 10/21 (48%). Natural killer (NK) cell numbers were decreased in 7/19 (37%) reported cases (data not shown).

3.2.4 | Anterior pituitary deficiency

All patients had ACTH deficiency, confirmed by undetectable or extremely low serum cortisol levels ($<1 \mu\text{g/dL}$) with undetectable or low ACTH ($<5 \text{ pg/mL}$). Overall, 79% of patients had isolated ACTH

TABLE 2 Clinical presentation of one case index and 27 reported cases of DAVID syndrome.

Patient N ^o , Sex	Author, Year, Reference	Age of onset ACTH deficiency	Other pituitary deficiency	Pituitary MRI	PID age	Infections
1, F (A1)	Quentien et al., 2012 ¹	15 yr	No	Normal	8 yr	PI, septicemia, septic shock, BD
2, M (C1)	Quentien et al., 2012 ¹	9 yr	GH (partial) – TSH, 9 yr	Hypoplasia	4 yr	Meningoencephalitis, bacterial PI, BD
3, F (B1)	Quentien et al., 2012 ¹	5 yr	No	Hypoplasia, thin stalk	3 yr	PI, pneumococcal bacteremia, severe VZV
4, F	Chen et al., 2013 ²	NA	No	NA	30 yr	Viral PI, upper RI sinusitis, HSV, giardia
5, F	Chen et al., 2013 ²	NA	No	NA	6 yr	Recurrent upper RI, PI, OM, HSV, giardia
6, M	Chen et al., 2013 ²	NA	No	T1CM, pituitary NA	3.5 yr	Recurrent upper RI, PI, OM, HSV labialis
7, M	Chen et al., 2013 ²	16 yr	No	T1CM, pituitary NA	10 yr	Recurrent upper RI, OM, PI, aseptic meningitis
8, M (D1)	Brue et al., 2014 ³	7 yr	TSH, 15 yr	Hypoplasia	1.5 yr	Normal
9, F	Liu et al., 2014 ⁷	9 yr	No	NA	9 yr	Severe VZV, mycobacterial PI
10, M	Lougaris et al., 2015 ⁸	4 yr	TSH	NA	1.3 yr	Upper RI
11, F	Shi et al., 2016 ⁹	16 yr	No	Normal	18 yr	Recurrent upper RI, PI, oral candidiasis
12, F	Maccari et al., 2017 ¹⁰	NA	No	NA	16 yr	Pericarditis, upper RI OM, PI, sinusitis
13, F	Maccari et al., 2017 ¹⁰	2 yr	No	NA	2 yr	Upper RI, OM, PI CMV, EBV, Toxoplasma encephalitis
14, M	Lal et al., 2017 ¹¹	7 yr	GH, 10 yr	Hypoplasia	11 yr	Upper RI OM, no severe infections
15, M	Kuehnet al., 2017 ¹²	8 yr	GH, 10 yr	NA	10 yr	Normal
16, F	Montin et al., 2018 ¹³	12 yr	No	NA	6 yr	Recurrent upper RI, PI
17, M	Montin et al., 2018 ¹³	6 yr	No	NA	1 yr	Normal
18, M	Montin et al., 2018 ¹³	10 yr	GH – TSH	NA	6 yr	Recurrent upper RI
19, F	Nagai et al., 2019 ¹⁴	School age	No	NA	School age	Normal
20, M	Xiao et al., 2019 ¹⁵	11 yr	No	Normal	11 yr	Recurrent PI, diarrhea
21, M	Klemann et al., 2019 ¹⁶	NA	No	NA	6 yr	Recurrent upper RI, HSV
22, M	Klemann et al., 2019 ¹⁶	8 yr	No	Normal	7 yr	Recurrent upper RI, HSV, PI CMV
23, M	Nasomyontet al., 2019 ¹⁷	4.5 yr	No	Normal	1 yr	Upper RI, PI
24, F	Aird et al., 2019 ¹⁸	9 yr	No	Normal	6 yr	Systemic CMV, recurrent upper RI, PI Pj
25, M	Nogueira et al., 2020 ¹⁹	9 yr	No	Hypoplasia, thin stalk	3 yr	Parotiditis, VZV
26, F	Bienias et al., 2021 ²⁰	9 yr	No	NA	15 yr	Recurrent upper RI, GI, HSV, Hib, PI Pj
27, F	Kwiatkowski et al., 2022 ²¹	5 yr	No	NA	7 yr	Upper RI, VZV, meningoencephalitis
28, M	Current	7 yr	No	Hypoplasia	7 yr	Normal

Abbreviations: ACTH, adrenocorticotropic hormone; BD, bronchial dilatation; CMV, cytomegaly virus; DAVID, deficient anterior pituitary with common variable immune deficiency; EBV, Epstein Barr virus; F, female; GH, growth hormone; GI, gastrointestinal infection; Hib, hemophilus influenzae type b; HSV, herpes simplex virus; M, male; NA, not available; OM, otitis media; PID, primary immunodeficiency; PI, pulmonary infection; Pj, pneumocystis jirovecii; RI, respiratory infection; TSH, thyroid stimulating hormone; T1CM, type 1 Chiari malformation; yr, years; VZV, varicella zoster virus.

deficiency, with a mean age at diagnosis of ACTH deficiency of 8.6 ± 3.7 years (range 2–16 years). Two patients had ACTH deficiency associated with growth hormone (GH) deficiency (7%), two associated

with TSH deficiency (7%) and two associated with both deficiencies (7%) (Figure 3). Age at diagnosis of GH deficiency was 9–10 years, at the same time as ACTH deficiency or 2–3 years later. One patient

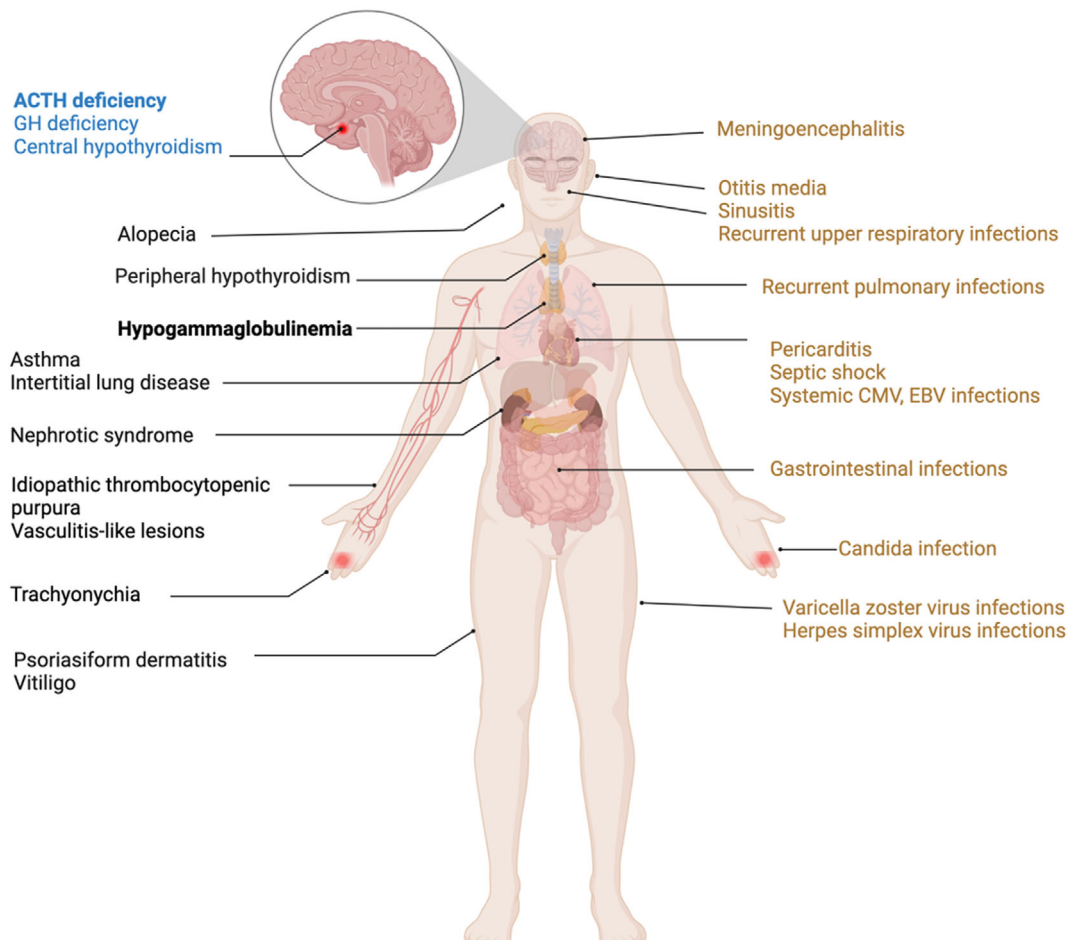


FIGURE 2 Clinical manifestations of deficient anterior pituitary with common variable immune deficiency (DAVID) syndrome.

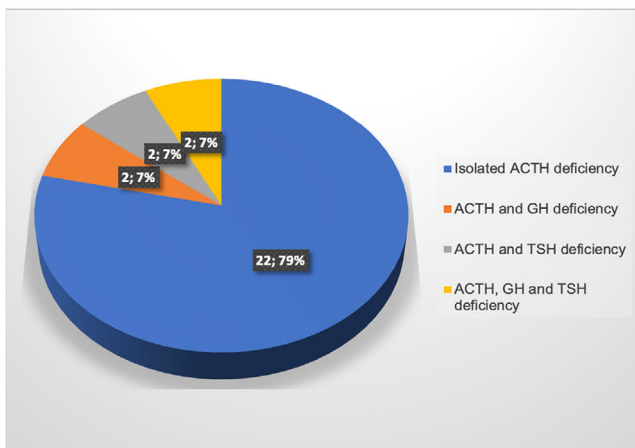


FIGURE 3 Anterior pituitary deficiency in deficient anterior pituitary with common variable immune deficiency (DAVID) syndrome.

showed a partial GH deficiency at age 9 years, with a low IGF-1 (38 ng/mL, normal range 67–405 ng/mL) and a subnormal GH response (peak, 13 mIU/L) to a glucagon-propranolol stimulation test (normal >20 mIU/L). The patient was treated by GH replacement

therapy, until growth was completed; however, IGF-1 remained low at 17 years (169 ng/mL), indicating persistent partial GH deficiency. Two patients showed TSH deficiency with a low FT4 (8.4 pg/mL, normal range, 9.3–16 pg/mL) and normal TSH; L-thyroxine was started. Prolactin (PRL), follicle stimulating hormone (FSH) and luteinizing hormone (LH) were normal in three patients tested. In many cases, pubertal status could not be evaluated as the patients were reported before pubertal age. Antipituitary antibodies were absent in six patients who had testing performed. MRI revealed a pituitary hypoplasia or small adenohypophysis in 6/14 (43%) patients, normal pituitary in 6/14 (43%), and type 1 Chiari malformation in 2/14 (14%) (Table 2). Other neurological findings were developmental delay and aseptic meningitis in a single patient.

3.2.5 | Genetics of DAVID syndrome

All patients had heterozygous mutations at the 3' end of the *NFKB2* gene, coding for the C-terminal domain of the protein. The most frequent mutation was the nonsense variant c.2557C > A, p.Arg853* (11/28, 39%), the second one was a frameshift mutation c.2564del, p.Lys855Serfs*8 (3/28, 11%). All other mutations

FIGURE 4 Schematic view of *NFKB2* p100 with the Rel homology domain (RHD), helix-turn-helix motif (HTH), ankyrin repeat domain (ARD), processing inhibitory domain (PID), death domain (DD) indicated by gray boxes. The C-terminus of p100 bears critical S866 and S870 phosphorylation sites (P), and the K855 ubiquitination site (U). Distribution of *NFKB2* mutations in 28 patients with deficient anterior pituitary with common variable immune deficiency (DAVID) syndrome are shown as different colors, each point corresponds to a mutation found in one patient.

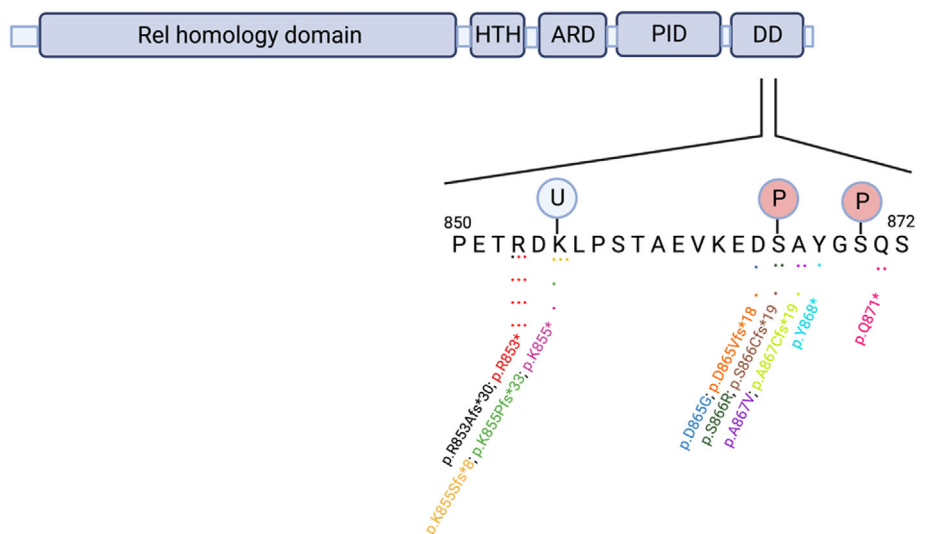


TABLE 3 Genetic data of one case index and 27 reported cases of deficient anterior pituitary with common variable immune deficiency (DAVID) syndrome.

Patient N°, Sex	Author, Year, Reference	<i>NFKB2</i> mutation (NM_001322934)	Exon	Nature	Classification ^a
1, F	Brue et al., 2014 ³	c.2600C > T, p.Ala867Val	23	Missense	Likely pathogenic
2, M	Brue et al., 2014 ³	c.2556_2563del, p.Arg853Alafs*30	22	Frameshift	Pathogenic
3, F	Brue et al., 2014 ³	c.2594 A > G, p.Asp865Gly	23	Missense	Pathogenic
4, F	Chen et al., 2013 ²	c.2564del, p.Lys855Serfs*8	22	Frameshift	Pathogenic
5, F	Chen et al., 2013 ²	c.2564del, p.Lys855Serfs*8	22	Frameshift	Pathogenic
6, M	Chen et al., 2013 ²	c.2564del, p.Lys855Serfs*8	22	Frameshift	Pathogenic
7, M	Chen et al., 2013 ²	c.2557C > T, p.Arg853 ^a	22	Nonsense	Pathogenic
8, M	Brue et al., 2014 ³	c.2557C > T, p.Arg853 ^a	22	Nonsense	Pathogenic
9, F	Liu et al., 2014 ⁷	c.2594_2601del, p.Asp865Valfs*18	23	Frameshift	Pathogenic
10, M	Lougaris et al., 2015 ⁸	c.2557C > T, p.Arg853 ^a	22	Nonsense	Pathogenic
11, F	Shi et al., 2016 ⁹	c.2563A > T, p.Lys855 ^a	22	Nonsense	Pathogenic
12, F	Maccari et al., 2017 ¹⁰	c.2557C > T, p.Arg853 ^a	22	Nonsense	Pathogenic
13, F	Maccari et al., 2017 ¹⁰	c.2557C > T, p.Arg853 ^a	22	Nonsense	Pathogenic
14, M	Lal et al., 2017 ¹¹	c.2596 A > C, p.Ser866Arg	23	Missense	Pathogenic
15, M	Kuehn et al., 2017 ¹²	c.2596A > C, p.Ser866Arg	23	Missense	Pathogenic
16, F	Montinet et al., 2018 ¹³	c.2557C > T, p.Arg853 ^a	22	Nonsense	Pathogenic
17, M	Montinet et al., 2018 ¹³	c.2557C > T, p.Arg853 ^a	22	Nonsense	Pathogenic
18, M	Montinet et al., 2018 ¹³	c.2557C > T, p.Arg853 ^a	22	Nonsense	Pathogenic
19, F	Nagai et al., 2019 ¹⁴	c.2557C > T, p.Arg853 ^a	22	Nonsense	Pathogenic
20, M	Xiao et al., 2019 ¹⁵	c.2604_2605delinsA, p.Tyr868 ^a	23	Nonsense	Pathogenic
21, M	Klemann et al., 2019 ¹⁶	c.2611C > T, p.Gln871 ^a	23	Nonsense	Pathogenic
22, M	Klemann et al., 2019 ¹⁶	c.2596_2597del, p.Ser866Cysfs*19	23	Frameshift	Likely pathogenic
23, M	Nasomyont et al., 2019 ¹⁷	c.2598dup, p.Ala867Cysfs*19	23	Frameshift	Pathogenic
24, F	Aird et al., 2019 ¹⁸	c.2611C > T, p.Gln871 ^a	23	Nonsense	Pathogenic
25, M	Nogueira et al., 2020 ¹⁹	c.2557C > A, p.Arg853 ^a	22	Nonsense	Pathogenic
26, F	Bieniaset al., 2021 ²⁰	c.2556_2562dup, p.Lys855Profs*33	22	Frameshift	Pathogenic
27, F	Kwiatkowski et al., 2022 ²¹	c.2557C > T, p.Arg853 ^a	22	Nonsense	Pathogenic
28, M	Current	c.2600C > T, p.Ala867Val	23	Missense	Likely pathogenic

Abbreviations: F, female; M, male.

^aAccording to the ACMG-AMP guidelines.³⁷

were identified in only one patient, except the missense variant c.2600C > T, p.Ala867Val; c.2596A > C, p.Ser866Arg and the non-sense variant c.2611C > T, p.Gln871* (2/28) (Figure 4 and Table 3). Finally, different types of *NFKB2* pathogenic variants were reported in DAVID syndrome patients, including nonsense (15/28), missense (5/28) and frameshift (8/28) mutations in exons 22 and 23 (17 in exon 22 and 11 in exon 23) (Table 3). The transmission pattern in DAVID syndrome was autosomal dominant; however, it was suggested as de novo in several cases.

4 | DISCUSSION

DAVID syndrome (OMIM#, 615577) is defined by the association of CVID and anterior pituitary deficiencies, mainly ACTH deficiency. Currently, the pathophysiological mechanisms leading to this association remain unclear. First, most DAVID syndrome patients present with respiratory infections (82%); it is the first presenting symptom at a median age of 2 years, typical of immunodeficiency. Patients present with childhood-onset recurrent infections associated with hypogammaglobulinemia and decreased numbers of B cell memory switched lymphocytes. The pathophysiological explanation is clear for this aspect of the disease since the nuclear factor kappa B (NF- κ B) signaling pathway is a key regulator of the immune system. It regulates lymphocyte development, cell proliferation, inflammation and immune responses. Heterozygous mutations in the C-terminal region of *NFKB2* lead to the disruption of both non- and canonical pathways.^{4,12,22} Heterozygous *NFKB2* C-terminal mutations locate adjacent to the Lys855 ubiquitination, Ser866 or Ser870 phosphorylation sites, protect mutant protein from proteasomal degradation, cause defective processing of p100 to p52, and result in reduced translocation of p52 to the nucleus.^{2,7,10,12,22,23} In mouse models, deletion of *NFKB2* causes abnormal germinal center B cell formation and differentiation.²⁴

The second main disease associated with DAVID syndrome is ACTH deficiency which is reported in the majority of patients (79%). In the cohort analyzed here, it was actually the third manifestation. ACTH deficiency was indeed seen a few years after the diagnosis of immunodeficiency and alopecia (usually diagnosed by age 4), with a median age at diagnosis of 8.6 years. Interestingly, Klemann et al. reviewed 50 cases of primary immunodeficiency associated with *NFKB2* pathogenic variants (irrespective of the endocrine phenotype): 21 of them (44%) presented with ACTH deficiency.¹⁶ The mechanisms of ACTH deficiency remain speculative. Even if the roles of *NFKB2* suggest a hypothesis of autoimmunity, there are several pieces of evidence against this hypothesis. First, DAVID syndrome is less prevalent in women than in men (sex ratio, 15 males and 13 females), opposite to what is observed in autoimmune diseases.²⁵ Second, antipituitary antibodies were negative in the six investigated patients reported in the literature.^{1,26} Third, the phenotype of patients with DAVID syndrome does not match with lymphocytic hypophysitis: the mean age at diagnosis is lower (34 years for women and 44.7 for men lymphocytic hypophysitis²⁷ vs. 8.6 ± 3.7 years for DAVID, respectively); the spectrum of pituitary deficiency is different (isolated ACTH deficiency

is observed in less than 10% of patients with lymphocytic hypophysitis²⁸ while it is present in the majority of DAVID patients); the pituitary is usually hypoplastic or normal in DAVID, while it is enlarged in lymphocytic hypophysitis.²⁷ Finally, patients with autoimmune syndromes due to *NFKB1* or *AIRE* pathogenic variants do not present with ACTH deficiency.^{29,30} Considering that *NFKB2* deficiency might not induce an autoimmune disease of the pituitary, a tempting hypothesis could be a role during the development of the pituitary. However, this developmental hypothesis has yet to be supported by experimental evidence. The murine model is not contributive as it does not replicate the human phenotype: indeed, studies in the Lym1 mouse model carrying homozygous nonsense variants *NFKB2* (p.Y868*) showed normal pituitary functions.³ However, expression of *NFKB2* has been found in the adult mouse anterior pituitary and in the developing human pituitary.^{3,31}

The association of immune disorders and cortisol deficiency lead to a severe phenotype in terms of risks of infections and adrenal crises, both being at risk of lethal outcomes. To assess the severity of DAVID syndrome, we first used the severity scoring system proposed by Petersheim et al.³² For this score, not all criteria were evaluated in the patients of our cohort (for example antibody responses, lymphocytes, memory T and/or B cells were not available for many patients in the literature). We thus applied the ectodermal dysplasia criteria for patients in our cohort with a score from 0 (normal), 1 (trachyonychia/nails or alopecia/hair) or 2 (both trachyonychia and alopecia). We then used the DAVID severity score based on the CVID disease severity score (CDSS) proposed by Ameratunga.³³ To simplify this CDSS instrument, we calculated the most severe infectious condition of patients in our cohort with a score of normal (0), mild (1), moderate (5) or severe (10). ACTH deficiency was considered of moderate severity (5). We tried to determine whether gender could modify the severity of DAVID syndrome in our patients. Our results showed that the severity score was significantly greater in females than males in our cohort ($p = .04$) (Figure S1). However, the ectodermal dysplasia criteria did not show any significant difference between males and females (Figure S1). These results should be considered with caution as we used simplified scores due to the lack of literature data. While it seems that infectious status might be more severe in women, further research will have to be made on this specific point. When comparing the total score of the 28 patients reported in this review to 29 patients with *NFKB2* mutation without ACTH deficiency,¹⁶ we observed that DAVID syndrome patients had more severe infections and had higher scores of severity of ectodermal dysplasia as compared to patients without pituitary deficiency (Figure S2), suggesting the need for early diagnosis of ACTH deficiency in CVID patients. As both diseases can be diagnosed concomitantly or asynchronously, it is important to define some criteria in favor of a potential diagnosis of DAVID syndrome. DAVID syndrome should be suspected in case of isolated signs of ACTH deficiency such as hypoglycemia (5 cases without a history of infections and a delayed 2–4 years diagnosis of CVID), or in case of combined pituitary hormone deficiency with GH and/or TSH deficiency (21% cases). CVID should thus be screened in patients with isolated ACTH and combined pituitary deficiencies. Early diagnosis of

CVID in patients with ACTH deficiency would help early prevention by vaccines, and/or replacement treatment with immunoglobulins.^{34,35} As an example, the recent coronavirus 2 (SARS-CoV-2) pandemic emphasized the need for these patients to be adequately diagnosed and treated.³⁶

5 | CONCLUSION

In conclusion, we report a new patient presenting with DAVID syndrome due to a loss of function pathogenic variant of *NFKB2*. This adds to the few cases reported in the literature, emphasizing the frequent association between hypogammaglobulinemia, alopecia and ACTH deficiency. Given the fact that these three diseases can occur asynchronously, we suggest that *NFKB2* variant should be looked for in any patient with constitutional ACTH deficiency, in addition to screening for autoimmune status. On the other hand, we also recommend that patients with *NFKB2* variants be regularly screened for anterior hypopituitarism, as deficiency can happen later than hypogammaglobulinemia, and ACTH deficiency might worsen the prognosis if left undiagnosed.

AUTHOR CONTRIBUTIONS

Thi Thom Mac: Conceptualization; data curation; formal analysis; investigation; methodology; validation; visualization; writing – original draft; writing – review and editing. **Frederic Castinetti:** Conceptualization; methodology; project administration; supervision; validation; writing – original draft; writing – review and editing. **Celine Bar:** Investigation. **Sophie Julia:** Investigation. **Marlene Pasquet:** Investigation. **Pauline Romanet:** Investigation; writing – review and editing. **Alexandru Saveanu:** Investigation; writing – review and editing. **Gregory Mougel:** Investigation. **Teddy Fauquier:** Visualization. **Nicolas Jullien:** Visualization. **Anne Barlier:** Investigation. **Rachel Reynaud:** Investigation; methodology. **Thierry Brue:** Conceptualization; methodology; project administration; supervision; validation; writing – original draft; writing – review and editing.

ACKNOWLEDGMENT

This study was supported by the ADEREM (Association pour le Développement de la Recherche Médicale au CHU de Marseille).

CONFLICT OF INTEREST STATEMENT

The authors have nothing to disclose.

PEER REVIEW

The peer review history for this article is available at <https://www.webofscience.com/api/gateway/wos/peer-review/10.1111/jne.13287>.

DATA AVAILABILITY STATEMENT

The data generated by this study are available from the corresponding author upon reasonable request.

ORCID

Thi Thom Mac  <https://orcid.org/0000-0002-3746-2669>

Frederic Castinetti  <https://orcid.org/0000-0002-1808-8800>

Thierry Brue  <https://orcid.org/0000-0001-8482-6691>

REFERENCES

1. Quentien MH, Delemer B, Papadimitriou DT, et al. Deficit in anterior pituitary function and variable immune deficiency (DAVID) in children presenting with Adrenocorticotropin deficiency and severe infections. *J Clin Endocrinol Metab.* 2012;97(1):E121-E128. doi:10.1210/jc.2011-0407
2. Chen K, Coonrod EM, Kumánovics A, et al. Germline mutations in *NFKB2* implicate the noncanonical NF- κ B pathway in the pathogenesis of common variable immunodeficiency. *Am J Hum Genet.* 2013; 93(5):812-824. doi:10.1016/j.ajhg.2013.09.009
3. Brue T, Quentien MH, Khetchoumian K, et al. Mutations in *NFKB2* and potential genetic heterogeneity in patients with DAVID syndrome, having variable endocrine and immune deficiencies. *BMC Med Genet.* 2014;15:139. doi:10.1186/s12881-014-0139-9
4. Wirasinha RC, Davies AR, Srivastava M, et al. *Nfkb2* variants reveal a p100-degradation threshold that defines autoimmune susceptibility. *J Exp Med.* 2021;218(2):e20200476. doi:10.1084/jem.20200476
5. Jullien N, Saveanu A, Vergier J, et al. Clinical lessons learned in constitutional hypopituitarism from two decades of experience in a large international cohort. *Clin Endocrinol (Oxf).* 2021;94(2):277-289. doi:10.1111/cen.14355
6. Reynaud R, Gueydan M, Saveanu A, et al. Genetic screening of combined pituitary hormone deficiency: experience in 195 patients. *J Clin Endocrinol Metab.* 2006;91(9):3329-3336. doi:10.1210/jc.2005-2173
7. Liu Y, Hanson S, Gurugama P, Jones A, Clark B, Ibrahim MAA. Novel *NFKB2* mutation in early-onset CVID. *J Clin Immunol.* 2014;34(6): 686-690. doi:10.1007/s10875-014-0064-x
8. Lougaris V, Tabellini G, Vitali M, et al. Defective natural killer-cell cytotoxic activity in *NFKB2*-mutated CVID-like disease. *J Allergy Clin Immunol.* 2015;135(6):1641-1643. doi:10.1016/j.jaci.2014.11.038
9. Shi C, Wang F, Tong A, et al. *NFKB2* mutation in common variable immunodeficiency and isolated adrenocorticotrophic hormone deficiency: a case report and review of literature. *Medicine (Baltimore).* 2016;95(40):e5081. doi:10.1097/MD.0000000000005081
10. Maccari ME, Scarselli A, Di Cesare S, et al. Severe toxoplasma gondii infection in a member of a *NFKB2*-deficient family with T and B cell dysfunction. *Clin Immunol.* 2017;183:273-277. doi:10.1016/j.clim.2017.09.011
11. Lal RA, Bachrach LK, Hoffman AR, et al. A case report of hypoglycemia and Hypogammaglobulinemia: DAVID syndrome in a patient with a novel *NFKB2* mutation. *J Clin Endocrinol Metab.* 2017;102(7):2127-2130. doi:10.1210/jc.2017-00341
12. Kuehn HS, Niemela JE, Sreedhara K, et al. Novel nonsense gain-of-function *NFKB2* mutations associated with a combined immunodeficiency phenotype. *Blood.* 2017;130(13):1553-1564. doi:10.1182/blood-2017-05-782177
13. Montin D, Licciardi F, Giorgio E, et al. Functional evaluation of natural killer cell cytotoxic activity in *NFKB2*-mutated patients. *Immunol Lett.* 2018;194:40-43. doi:10.1016/j.imlet.2017.12.006
14. Nagai M, Imai Y, Yamanishi K. Psoriasisform dermatitis associated with common variable immunodeficiency 10 due to an Arg853* mutation in the *NFKB2* gene. *J Dermatol.* 2019;46(1):e24-e26. doi:10.1111/1346-8138.14524
15. Xiao B, Fang D, Liu H, Wang L, Qiu W. A novel *NFKB2* mutation in a Chinese patient with DAVID syndrome. *Gene.* 2019;687:319-322. doi:10.1016/j.gene.2018.12.050
16. Klemann C, Camacho-Ordóñez N, Yang L, et al. Clinical and immunological phenotype of patients with primary immunodeficiency due to

- damaging mutations in NFKB2. *Front Immunol.* 2019;10:297. doi:10.3389/fimmu.2019.00297
17. Nasomyont N, Lindsley AW, Assa'ad A, et al. Central diabetes insipidus in a patient with NFKB2 mutation: expanding the endocrine phenotype in DAVID syndrome. *J Clin Endocrinol Metab.* 2019;104(9):4051-4057. doi:10.1210/jc.2019-00469
 18. Aird A, Lagos M, Vargas-Hernández A, et al. Novel heterozygous mutation in NFKB2 is associated with early onset CVID and a functional defect in NK cells complicated by disseminated CMV infection and severe nephrotic syndrome. *Front Pediatr.* 2019;7:303. doi:10.3389/fped.2019.00303
 19. Nogueira M, Pinheiro M, Maia R, et al. Symptomatic hypoglycemia in a child with common variable immunodeficiency: deficient anterior pituitary with variable immune deficiency (DAVID) syndrome. *Clin Pediatr Endocrinol.* 2020;29(3):111-113. doi:10.1297/cpe.29.111
 20. Bienias M, Gabrielyan A, Geberzahn L, et al. More severe than CVID: combined immunodeficiency due to a novel NFKB2 mutation. Atanaskovic-Markovic M, ed. *Pediatr Allergy Immunol.* 2021;32(4):793-797. doi:10.1111/pai.13441
 21. Kwiatkowski V, Thanaputkaiporn N, Poowuttikul P. NFKB2 mutation in 2 siblings with DAVID syndrome and CVID with variable presentations. *J Allergy Clin Immunol.* 2022;149(2):AB27. doi:10.1016/j.jaci.2021.12.123
 22. Lee CE, Fulcher DA, Whittle B, et al. Autosomal-dominant B-cell deficiency with alopecia due to a mutation in NFKB2 that results in non-processable p100. *Blood.* 2014;124(19):2964-2972. doi:10.1182/blood-2014-06-578542
 23. Lindsley AW, Qian Y, Valencia CA, Shah K, Zhang K, Assa'ad A. Combined immune deficiency in a patient with a novel NFKB2 mutation. *J Clin Immunol.* 2014;34(8):910-915. doi:10.1007/s10875-014-0095-3
 24. Carragher D, Johal R, Button A, et al. A stroma-derived defect in NFKB2^{-/-} mice causes impaired lymph node development and lymphocyte recruitment. *J Immunol.* 2004;173(4):2271-2279. doi:10.4049/jimmunol.173.4.2271
 25. Cincinelli G, Generali E, Dudam R, Ravindran V, Selmi C. Why women or why not men? Sex and autoimmune diseases. *Indian J Rheumatol.* 2018;13:44. doi:10.4103/injr.injr_1_18
 26. Caturegli P, Lupi I, Landek-Salgado M, Kimura H, Rose NR. Pituitary autoimmunity: 30 years later. *Autoimmun Rev.* 2008;7(8):631-637. doi:10.1016/j.autrev.2008.04.016
 27. Naran J, Can AS. Lymphocytic Hypophysitis. *StatPearls Publishing*; 2022. Accessed July 26, 2022 <http://www.ncbi.nlm.nih.gov/books/NBK562255/>
 28. Honegger J, Schlaffer S, Menzel C, et al. Diagnosis of primary Hypophysitis in Germany. *J Clin Endocrinol Metab.* 2015;100(10):3841-3849. doi:10.1210/jc.2015-2152
 29. Yoshioka T, Nishikomori R, Hara J, et al. Autosomal dominant anhidrotic ectodermal dysplasia with immunodeficiency caused by a novel NFKBIA mutation, p.Ser36Tyr, presents with mild ectodermal dysplasia and non-infectious systemic inflammation. *J Clin Immunol.* 2013;33(7):1165-1174. doi:10.1007/s10875-013-9924-z
 30. Ferré EMN, Schmitt MM, Lionakis MS. Autoimmune Polyendocrinopathy-candidiasis-ectodermal dystrophy. *Front Pediatr.* 2021;9:723532. doi:10.3389/fped.2021.723532
 31. Zhang S, Cui Y, Ma X, et al. Single-cell transcriptomics identifies divergent developmental lineage trajectories during human pituitary development. *Nat Commun.* 2020;11(1):5275. doi:10.1038/s41467-020-19012-4
 32. Petersheim D, Massaad MJ, Lee S, et al. Mechanisms of genotype-phenotype correlation in autosomal dominant anhidrotic ectodermal dysplasia with immune deficiency. *J Allergy Clin Immunol.* 2018;141(3):1060-1073.e3. doi:10.1016/j.jaci.2017.05.030
 33. Ameratunga R. Assessing disease severity in common variable immunodeficiency disorders (CVID) and CVID-like disorders. *Front Immunol.* 2018;9:2130. doi:10.3389/fimmu.2018.02130
 34. Orange JS, Ballou M, Stiehm ER, et al. Use and interpretation of diagnostic vaccination in primary immunodeficiency: a working group report of the basic and clinical immunology interest section of the American Academy of Allergy, Asthma & Immunology. *J Allergy Clin Immunol.* 2012;130(3, Supplement):S1-S24. doi:10.1016/j.jaci.2012.07.002
 35. European consensus proposal for immunoglobulin therapies – Sewell – 2014 – European Journal of Immunology – Wiley Online Library. Accessed November 20, 2022. <https://onlinelibrary.wiley.com/doi/full/10.1002/eji.201444700>
 36. Piano Mortari E, Pulvirenti F. COVID-19 infection and vaccination in immunodeficiency. *Clin Exp Immunol.* 2022;209(3):259-261. doi:10.1093/cei/uxac080
 37. Richards S, Aziz N, Bale S, et al. Standards and guidelines for the interpretation of sequence variants: a joint consensus recommendation of the American College of Medical Genetics and Genomics and the Association for Molecular Pathology. *Genet Med #Ff J Am Coll Med Genet.* 2015;17(5):405-424. doi:10.1038/gim.2015.30